

OPIS PRZYPADKU  
CASE REPORT**DIAGNOSTIC ERRORS DURING INTRAMEDULLAR PROCESSES****BŁĘDY DIAGNOSTYCZNE W TRAKCIE OCENY PROCESÓW  
WEWNĄTRZRDZENIOWYCH****Kateryna Tarianyk, Natalia Lytvynenko, Tetiana Purdenko, Viktoriia Hladka**

DEPARTMENT OF NERVOUS DISEASES WITH NEUROSURGERY AND MEDICAL GENETICS, UKRAINIAN MEDICAL STOMATOLOGICAL ACADEMY, POLTAVA, UKRAINE

**ABSTRACT**

**Introduction:** The article describes a clinical case of a malignant tumor of the brain and spinal cord with metastasis, which remained undetected for many years and was treated as syringomyelia. Long-term exhausting examinations of the brain and spinal cord, dynamic follow-up of medical specialists, and repeated surgical interventions on the spine helped to differentiate this process and make the correct diagnosis.

**The aim:** The objectives of the present paper are to analyze the existing classifications of syringomyelia; to examine its etiology, pathogenesis, diagnostic approaches and treatment tactics; to present a clinical case of a malignant tumor of the brain and spinal cord with metastasis, which was misdiagnosed as syringomyelia.

**Materials and methods:** The authors analyzed the existing classifications of syringomyelia and studied its etiology, pathogenesis, diagnostic approaches and treatment tactics using the method of content analysis, analytical comparative and contrastive methods.

**Clinical case:** The described clinical case is a variant of the course of syringomyelia, associated with the spinal cord tumor, namely, in particular, anaplastic ependymoma. For a long time, the process remained undetected, despite the long-term examination and drainage of the syringomyelic cavity. Analyzing this case, it is highly important to pay attention to careful history collection, examination of the patient, analysis of the occurrence of certain disorders in order to conduct the neuroimaging examinations in time.

**Conclusions:** Favorable outcome of the disease is directly related to the diagnosis at early stages, especially in young people, the clinical variant of the process, progression of the course, the degree of involvement of various parts of the nervous system and extraneural formations, the severity of the lesion. The treatment tactics and the ability to restore the functions will depend on all these factors.

**KEY WORDS:** intramedullary tumor, syringomyelia, syringobulbia, ependymoma

Wiad Lek 2019, 72, 1, 129-132

**INTRODUCTION**

Syringomyelia is a chronic, poli-etiological disease, characterized by the progressive development of longitudinal cavities in the spinal cord, which are filled with liquor or a liquid close to it in composition [1-3]. In all conditions, in which syringomyelia develops, there is at least a partial blockage of the normal circulation of cerebrospinal fluid. Based on this feature, the following classification of syringomyelia was proposed, according to Barnett (1973) [4,5]:

1. Communicating syringomyelia with subarachnoid space. It is associated with the anomaly of the craniovertebral junction. The sunken cerebellar tonsils impede the free flow of cerebrospinal fluid from the skull into the spinal canal. It is associated with diseases of the base of the skull (basal arachnoiditis, cysts and tumors of the posterior cranial fossa).
2. Post-traumatic syringomyelia: the syringomyelic cyst occurs at the site of injury and then spreads to other segments of the spinal cord.
3. Syringomyelia as a consequence of spinal arachnoiditis and arachnopathy.
4. Syringomyelia, associated with the spinal cord tumors.
5. Syringomyelia, caused by compression of the spinal

cord by non-tumor etiology formations (herniation of cervical discs, large demyelination foci in the spinal cord in multiple sclerosis, etc.).

6. Idiopathic syringomyelia – the causes of development are unknown.

*Analysis of recent research and publications.* In 2000, T. Milhorat suggested a classification of syringomyelia based on MRI and morphological data [6-10]. He identified 3 types of lesions: 1. Communicating central channel syringomyelia, 2. Non-communicating central channel syringomyelia, 3. Non-communicating extracanal syringomyelia.

According to this classification, communicating syringomyelia constitutes 10–15% of all observations and, as a rule, it is combined with Chiari anomaly of type 2, hydrocephalus, and Dandy–Walker anomaly.

Non-communicating syringomyelia (75% of observations) is combined with Chiari anomaly of type 1 and basilar impression, as well as various causes of impaired patency of the subarachnoid spaces at the level of the spinal canal (injuries and degenerative stenosis of the cervical spine, tumors, etc.).

Non-communicating extracanal syringomyelia (10%) is a consequence of injuries and circulatory disorders in the

spinal cord with the primary formation of a cyst in the area of damage to the brain substance and its gradual spread along the spinal cord.

*Etiology and pathogenesis.* An important role in the development of the disease belongs to the defect in the embryonic development of the nervous tissue, which during the development of the organism is manifested by the dysraphic state (status dysraphicus). As a result of endogenous (heredity) and exogenous (trauma, intoxication) influences, the internal defect manifests itself, turning into a disease [1,3].

Among the cranial factors of syringomyelia development, the most common are congenital lesions of the cranio-cervical region (Chiari malformations (CM), types 1 and 2, basilar impression, Dandy-Walker anomaly, small posterior cranial fossa (PCF)), less common are arachnopathies, tumors of PCF and supratentorial tumors; spinal etiological factors of syringomyelia are caused by: malformations (diastematomyelia, "tight filum terminale syndrome", spina bifida), tumors, arachnopathies, degenerative diseases of the spine, multiple sclerosis.

The manifestations of syringomyelia, the onset of the disease regardless of age, different types of the course, the absence of pathognomy signs in the early stages of the disease, lead to the need to differentiate this disease from neurological disorders in which syringomyelic syndrome may be observed, namely:

1. Hematomyelia (after a traumatic injury, there are symptoms characteristic of syringomyelia, and then their regression occurs).
2. Chronic poliomyelitis (sensitive and autonomic disorders are not characteristic).
3. Amyotrophic lateral sclerosis (no sensitivity disorders).
4. Brachioneuritis (the progressive course is not characteristic, dissociated type of sensitivity disorders).
5. Intramedullary tumor (accompanied by the signs of spinal cord compression with minor trophic and autonomic disorders).
6. Leprosy (no signs of central lesion of lower extremities, segmental-dissociated type of sensitivity disorder, positive Hansen's bacillus).
7. Spinal amyotrophic syphilis (mixed signs of paralysis only in the lower limbs, dissociated sensory disturbances, positive reaction and Argyll Robertson symptom).
8. Myelodysplasia (disrupted sensitivity only in the lower extremities, there is no progressive course, mild paresis is characteristic).
9. Denny – Brown sensory neuropathy.
10. Disturbances of spinal blood circulation.

*Diagnostic approaches:* The most accurate diagnosis of syringomyelia is performed using spinal MRI or myelography. Radiography is used as an auxiliary method, because it will determine disorders of the bone structure, but will not detect cavities in the spinal cord. Electroneuromyography will clarify the nature of the sensitivity disorder and the level of damage.

*Treatment.* At the initial stages of the disease, radiotherapy is considered the most favorable method, which slows down the progression of the process, reducing the severity of sensitive and trophic disorders [3, 16, 17].

In advanced cases, radioactive phosphorus (P2), which has beta radiation, and radioactive iodine (I131), which has beta and gamma radiation, are used to treat syringomyelia. [18].

A relatively new method in the treatment of syringomyelia is neostigmine therapy, which improves the conduction of nerve impulses. It allows to temporarily improve the neuromuscular conduction, a combination of such therapy with UHF or radon baths is possible [3,19,20].

Surgical treatment for syringomyelia is indicated for detection of voids that block the subarachnoid space in the spine, as well as in congenital disorders of cerebrospinal fluid outflow from the brain. Surgical treatment can eliminate cysts, as well as correct the defects of the spine resulting from the disease [14, 17, 18].

Another method of surgical intervention is drainage of cystic formations, that is, removal of excess fluid from the cavities.

There have been attempts of surgical treatment of syringomyelia by transplantation of embryonic nerve tissue [18–20].

In our report, we will present a clinical case of the intramedullary tumor, which remained undetected for a long time and was treated as syringomyelia.

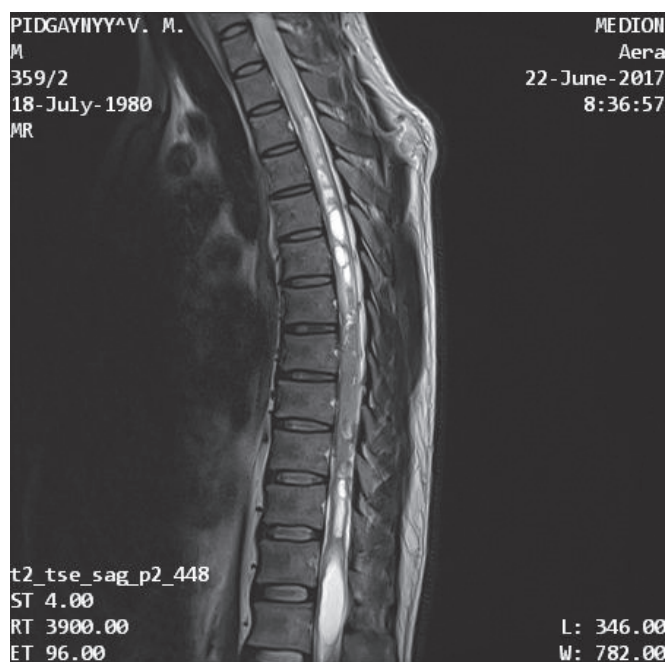
## CLINICAL CASE

Patient S., aged 39, an employee, presented with complaints of decreased sensitivity of the left half of the body, pain in the lumbar spine, radiating to the lower limbs, weakness in the right leg, grogginess, straining effort in urination.

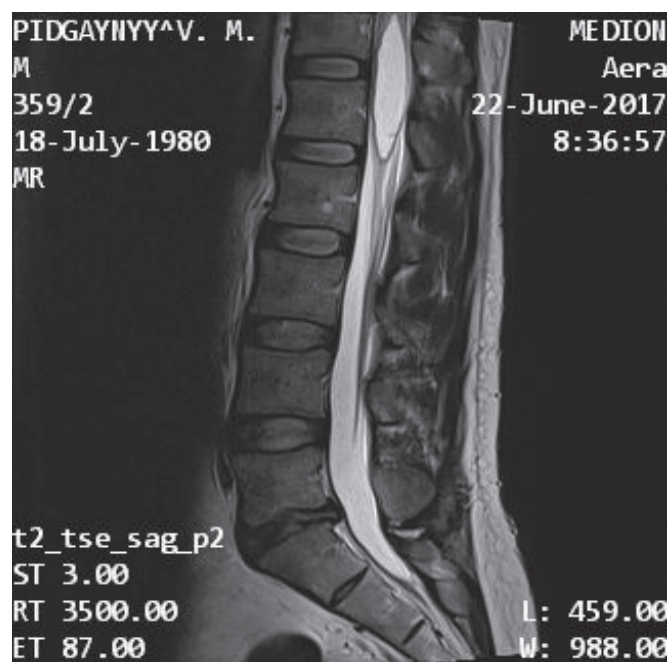
He noted the first episodes of the disease 10 years ago, when he first noticed the decreased sensitivity in the left half of the body, and did not seek medical help. In May 2015, pain in the neck and left arm increased, the MRI scan (0.3 T) of the cervical and thoracic spine was conducted, the patient was examined by the neurosurgeon, and the following diagnosis was made: "Osteochondrosis of the cervical and thoracic spine, hernia of C5-C6, C6-C7 intervertebral discs with relative stenosis of the spinal canal at the level of C5-C6, C6-C7". The patient was prescribed therapy (vitamins, chondroprotectors, vascular medications).

In June 2015, after physical exertion, complaints of disrupted sensitivity in the shoulder and upper limb to the left increased. On this occasion, the patient consulted the neurologist, the MRI scan (1.5 T) of the cervical and thoracic spine was conducted with intravenous contrasting. The signs of intramedullary cystic formation of the spinal cord at the cervical level and cystic solid formation in the thoracic region at the level of Th1-L1 vertebrae were detected. The patient was referred for consultation and treatment to A.P. Romodanov Institute of Neurosurgery, where the following diagnosis was made: "Idiopathic syringomyelia, cervico-thoracic form". The patient was hospitalized (vascular and restorative therapy).

After discharge, the patient continued to work at the place of residence for the next 2 years. The state remained at the same level. In October 2016, the patient once again consulted A.P. Romodanov Institute of Neurosurgery of the National Academy of Medical Sciences of Ukraine. After consultation, dynamic observation was recommended.



**Fig. 1.** MRI with contrast enhancement of the cervical and thoracic spine.



**Fig. 2.** MRI with contrast enhancement of the lumbar spinal cord.

In June 2017, the patient began to complain of weakness in the lower extremities, more to the right, grogginess, numbness of the left half of the body, straining effort in urination, periodic pain in the thoracic and lumbar spine. The MRI scan of the thoracic and lumbosacral spine was conducted with intravenous contrasting. According to the data obtained from MRI images, the progression of the process was revealed in the form of increased size of cavities, the lower pole of the cystic formation - at the level of L1-L2, the combination of syringomyelia with a voluminous formation is not excluded.

After consultation, the patient was diagnosed with syringomyelia, cervico-thoracic and lumbar form, syringobulbia, with disrupted sensitivity of the “half-jacket” type to the left; myeloradiculopathy syndrome, with moderate lower paraparesis, with an emphasis to the right, moderate pain syndrome, musculo-tonic syndrome, neurotrophic syndrome, sensory ataxia against the background of osteochondrosis, deforming spondylosis, disc protrusion at C3-C4 and C5-S6, C6-C7, hernias of L5-S1 with right-sided lumbar ischialgia. The patient was prescribed conservative treatment; he was independently seeking treatment, consulting doctors from other institutions in Ukraine, Belarus and Germany.

In July 2017, the patient underwent surgical intervention at the Institute of Neurosurgery (Kyiv) – removal of the intramedullary spinal cord cyst at the L1-L2 level, drainage of the cavity. Laminectomy of L1 with subsequent dynamic observation.

In October 2017, due to increased weakness in the legs, disrupted sensitivity in the anogenital area and legs, the patient consulted A.P. Romodanov Institute of Neurosurgery of the National Academy of Medical Sciences of Ukraine.

From the life history: the patient denies TB, typhus, malaria, sexually transmitted diseases, Botkin’s disease, hemotransfusion, HIV, injuries. The patient is married, has a daughter. All relatives are healthy.

*Objectively:* the general condition is relatively satisfactory. Normal nutrition. The skin and visible mucous membranes are pale pink, clean. Peripheral lymph nodes are not enlarged. Vesicular breathing in the lungs, no wheezing. The activity of the heart is rhythmic, the tones are clear. BP is 120/70 mm Hg; pulse - 68 per 1 min. The abdomen is soft, painless on palpation. *In the neurological status:* the patient is conscious; oriented in place, time and self. Emotionally labile. Palpebral fissures S = D, pupils are equal. No nystagmus. Asymmetry of the nasolabial folds, the left corner of the mouth is drooping. The tongue is in the middle line. Barre’s test – lower positive to the right. Reduced muscle strength in the right leg to 3 points, in the left – up to 4 points. Tendon and periosteal reflexes from the hands of D > S, high, with extended reflexogenic zones. Knee and Achilles reflexes are high, D > S. No abdominal reflexes. There are no pathological stop signs on both sides. Long back muscles are strained along all parts of the spine, painfulness of the paravertebral points in the cervical, thoracic and lumbosacral spine. Lasègue symptom 45 ° to the right. The temperature sensitivity of the left half of the body is disrupted according to the “half-jacket” type in the anogenital zone. Loss of deep sensitivity in the fingers of both feet. FTN is performed indistinctly from two sides. HTS is performed with omissions and intention from both sides. Pelvic disorders by the urinary retention type. No dysraphic status.

On MRI of the cervico-thoracic and lumbar spine with contrasting, there is an intramedullary formation consisting of solid and cystic areas. A solid area – is over the bodies of the Th7-Th9 vertebrae, 6.8 cm long, 1.3 cm wide, it has an iso-intensive soft tissue MR signal. The cystic areas are located above and below it, the lower pole is at the L1 vertebra level, the width at the L1 vertebra level is up to 1.1 cm. The dimensions of the pathological area after contrasting are 0.83 × 0.93 × 6.0 cm, the cystic areas do not accumulate the contrast

medium. Degenerative changes in the thoracic spine, hernial protrusion of the intervertebral disk in the C6-C7 segment, cystic formation of the spinal cord, the upper pole is located at the level of the craniovertebral junction (Fig. 1 and Fig. 2).

**Conclusion:** MR signs of intramedullary cystic solid formation of the spinal cord in the thoracic spine at the level of Th1-L1 vertebrae, the lower pole at the level of the L1-L2 segments (possible combination of syringomyelia with a voluminous formation), osteochondrosis of intervertebral disks of the thoracic spine.

General clinical test: no abnormalities.

In October 2017, the patient underwent surgical treatment – laminectomy of Th8-Th10, subtotal removal of the tumor at this level. A few days later, the results of histopathological study of the tumor were as follows: anaplastic ependymoma. On the 10th day, the patient was discharged from the hospital with improvement.

After the surgical treatment, the patient underwent active rehabilitation at the place of residence. He moves indoors using walkers, notes anesthesia in the anogenital zone, lower spastic paraparesis. The patient takes anticholinesterase medications, muscle relaxants. Initially, an improvement was noted, and afterwards – increasing paraparesis.

The described clinical case is a variant of the course of syringomyelia, associated with the spinal cord tumor, namely, in particular, anaplastic ependymoma. For a long time, the process remained undetected, despite the long-term examination and drainage of the syringomyelic cavity. Analyzing this case, it is highly important to pay attention to careful history collection, examination of the patient, analysis of the occurrence of certain disorders in order to conduct the neuroimaging examinations in time.

## CONCLUSIONS

Favorable outcome of the disease is directly related to the diagnosis at early stages, especially in young people, the clinical variant of the process, progression of the course, the degree of involvement of various parts of the nervous system and extraneural formations, the severity of the lesion. The treatment tactics and the ability to restore the functions will depend on all these factors.

## REFERENCES

- Ivanova M.F., Simonyan V.A., Muradyan I.E., Zinov'yeva N.N. Siringomiyeliya i yeyo maski. *Mezhdunarodnyy nevrologicheskii zhurnal*. №5(51). 2012: 76-82.
- Davletshina R.I., Mendeleovich Ye.G. Techeniye siringomiyelii s nachalom v zrelom vozraste. *Prakticheskaya meditsina*. №1-2(69). T.1. 2013: 32-35.
- Tondiy O.L., Zaval'naya O.P., Teslenko O.B., Sushko S.P., Merkulova V.V. Siringomiyeliya. Etiopatogenez. Klinika. Diagnostika. Lecheniye. *Skhidno-yevropeyskiy zhurnal vnutrishnoy meditsini*. T.2. 2015: 61-69.
- Barnett H.J.M. Syringomyelia associated with spinal arachnoiditis, in Barnett H.J.M., Foster J.B., Hudgson P. (eds.). *Syringomyelia*. London: WB Saunders; 1973: 220-244.
- Barnett H.J.M., Jousse A.T., Ball M.J. Pathology and pathogenesis of progressive cystic myelopathy as a late sequel to spinal cord injury, in Barnett H.J.M., Foster J.B., Hudgson P. (eds.). *Syringomyelia*. London: WB Saunders; 1973: 179-219.
- Milhorat T.H., Capocelli A.L. Jr, Anzil A.P. et al. Pathological basis of spinal cord cavitation in syringomyelia: analysis of 105 autopsy cases. *J Neurosurg*. 82.1995: 802-812.
- Milhorat T.H., Johnson R.W., Milhorat R.H., et al: Clinicopathological correlations in syringomyelia using axial magnetic resonance imaging. *Neurosurgery*. 37.1995: 206-213.
- Milhorat T.H., Johnson W.D., Miller J.I. et al. Surgical treatment of syringomyelia based on magnetic resonance imaging criteria. *Neurosurgery*. 31. 1992: 231-245.
- Milhorat T.H., Kotzen R.M., Anzil A.P. Stenosis of central canal of spinal cord in man: incidence and pathological findings in 232 autopsy cases. *J Neurosurg*. 80. 1994: 716-722.
- Milhorat T.H., Nobandegani F., Miller J.I., et al: Noncommunicating syringomyelia following occlusion of central canal in rats. *Experimental model and histological findings*. *J Neurosurg*. 78. 1993: 274-279.
- Blagodatskiy M.D., Larionov S.N., Sufianov A.A. Mal'formatsiya Arnol'da – Kiari i siringomiyeliya: metod. rek. Irkutsk; 1995: 242.
- Yelmanova T.V. Vrozhdenyye anomalii golovnogo i spinnogo mozga: kliniko-diagnosticheskiy aspekt. *Spravochnik vracha obshchey praktiki*. № 7. 2010: 22-38.
- Tambiyeva M.A., Shevchenko P.P. Siringomiyeliya: Sovremennyye metody diagnostiki i lecheniya. *Mezhdunarodnyy studencheskiy nauchnyy vestnik*. № 2-19. 2015: 107-108.
- Hardwidge C. Syringomyelia. *Neurosurgery*. V. 140. 1996: 685-690.
- Metcalfe R.A., Johnston R.A. Craniocervical Anomalies and Non-traumatic syringomyelia. *Spinal Cord Disease*. London; 1997: 275-295.
- Owler B.K., Halmagyi G.M., Brennan J., Besser M. Syringomyelia with Chiari malformation: 3 unusual cases with implications for pathogenesis. *Acta Neurochir (Wien)*. № 146. 2004: 1137-1143.
- Kopanitsa V.V. Gidrosiringomiyeliya (etiopatogenez, klinika, neyrokhirurgicheskiye aspekty lecheniya). *Ukrains'kiy medichniy chasopis*. № 6. 2000: 92-97.
- Gorbach I.N. Diferentsiatsiya v nevrologii. *Bolezni: spravochnoye posobiye*. Mn.: Novoye znaniye; 2002: 478 s.
- Lemann-Khorn F., Ludolf A. Lecheniye zabozevaniy nervnoy sistemy. *Pod red. O.S. Levina*. M.: MEDpress.inform; 2005: 528 s.
- Sufianov A.A. Vozmozhnosti khirurgicheskogo lecheniya siringomiyelii putom transplantatsii embrional'noy nervnoy tkani. *Dis. kand. S.-Peterburg*; 1994: 192 s.

### Authors' contributions:

According to the order of the Authorship.

### Conflict of interest:

The Authors declare no conflict of interest.

## CORRESPONDING AUTHOR

**Kateryna Tarianyk**

Department of Nervous Diseases with  
Neurosurgery and Medical Genetics,  
Ukrainian Medical Stomatological Academy,  
23 Shevchenko Str., 36011, Poltava, Ukraine  
tel: +380669226575  
e-mail: tkapol@gmail.com

**Received:** 06.08.2018

**Accepted:** 03.12.2018