



# Wiadomości Lekarskie

Official journal of the Polish Medical Association



Memory of  
dr Władysław  
Biegański

VOLUME LXXIII, ISSUE 12 PART 1, DECEMBER 2020

Since 1928

---



ALUNA Publishing House

Wiadomości Lekarskie is abstracted and indexed in: PUBMED/MEDLINE, SCOPUS, EMBASE, INDEX COPERNICUS, POLISH MINISTRY OF SCIENCE AND HIGHER EDUCATION, POLISH MEDICAL BIBLIOGRAPHY

Copyright: © ALUNA Publishing House.

Articles published on-line and available in open access are published under Creative Commons Attribution-Non Commercial-No Derivatives 4.0 International (CC BY-NC-ND 4.0) allowing to download articles and share them with others as long as they credit the authors and the publisher, but without permission to change them in any way or use them commercially.

## **Wiadomości Lekarskie monthly journal**

**You can order the subscription for the journal from Wydawnictwo Aluna by:**

prenumerata@wydawnictwo-aluna.pl  
Wydawnictwo Aluna  
Z.M. Przesmyckiego 29  
05-510 Konstancin-Jeziorna  
Poland

Place a written order first.

If you need, ask for an invoice.

Payment should be done to the following account of the Publisher:

**account number for Polish customers (PLN):**

82 1940 1076 3010 7407 0000 0000

Credit Agricole Bank Polska S. A., SWIFT: AGRIPPLR

**account number for foreign customers (EURO):**

57 2490 0005 0000 4600 7604 3035

Alior Bank S. A.: SWIFT: ALBPPLPW

Subscription of twelve consecutive issues (1-12):

Customers in Poland: 360 PLN/year

Customers from other countries: 320 EURO/year



# Wiadomości Lekarskie

**Editor in-Chief:**

Prof. Władysław Pierzchała

**Deputy Editor in-Chief:**

Prof. Aleksander Sieroń

**Statistical Editor:**

Dr Lesia Rudenko

**Managing Editor:**

Agnieszka Rosa – amarosa@wp.pl

**International Editorial Office:**

Lesia Rudenko (editor) – l.rudenko@wydawnictwo-aluna.pl

Nina Radchenko (editor's assistant)

– n.radchenko@wydawnictwo-aluna.pl

**Polish Medical Association (Polskie Towarzystwo Lekarskie):**

Prof. Waldemar Kostewicz – President PTL

Prof. Jerzy Woy-Wojciechowski – Honorary President PTL

Prof. Tadeusz Petelenz

---

**International Editorial Board – in-Chief:**

Marek Rudnicki

Chicago, USA

**International Editorial Board – Members:**

Kris Bankiewicz	San Francisco, USA	George Krol	New York, USA
Christopher Bara	Hannover, Germany	Krzysztof Łabuzek	Katowice, Poland
Krzysztof Bielecki	Warsaw, Poland	Henryk Majchrzak	Katowice, Poland
Zana Bumbuliene	Vilnius, Lithuania	Ewa Małecka-Tendera	Katowice, Poland
Ryszarda Chazan	Warsaw, Poland	Stella Nowicki	Memphis, USA
Stanislav Czudek	Ostrava, Czech Republic	Alfred Patyk	Gottingen, Germany
Jacek Dubiel	Cracow, Poland	Palmira Petrova	Yakutsk, Russia
Zbigniew Gasior	Katowice, Poland	Krystyna Pierzchała	Katowice, Poland
Andrzej Gładysz	Wroclaw, Poland	Tadeusz Płusa	Warsaw, Poland
Nataliya Gutorova	Kharkiv, Ukraine	Waldemar Priebe	Houston, USA
Marek Hartleb	Katowice, Poland	Maria Siemionow	Chicago, USA
Roman Jaeschke	Hamilton, Canada	Vladyslav Smiiianov	Sumy, Ukraine
Andrzej Jakubowiak	Chicago, USA	Tomasz Szczepański	Katowice, Poland
Oleksandr Katrushov	Poltava, Ukraine	Andrzej Witek	Katowice, Poland
Peter Konturek	Saalfeld, Germany	Zbigniew Wszolek	Jacksonville, USA
Jerzy Korewicki	Warsaw, Poland	Vyacheslav Zhdan	Poltava, Ukraine
Jan Kotarski	Lublin, Poland	Jan Zejda	Katowice, Poland

---

**Distribution and Subscriptions:**

Bartosz Guterman prenumerata@wydawnictwo-aluna.pl

**Graphic design / production:**

Grzegorz Sztank

www.red-studio.eu

**Publisher:**

ALUNA Publishing House

ul. Przesmyckiego 29,

05-510 Konstancin – Jeziorna

www.wydawnictwo-aluna.pl

www.wiadomoscilekarskie.pl

www.wiadlek.pl

## FOR AUTHORS

1. The monthly "Wiadomości Lekarskie" Journal is the official journal of the Polish Medical Association. Original studies, review papers as well as case reports are published.
2. The publication of the manuscript in "Wiadomości Lekarskie" is paid. The cost of publishing the manuscript is PLN 1,000 plus 23% VAT (for foreign authors: since July 2021 - 250 Euro). If the first author of the manuscript is a member of the Editorial Board or a team of journal reviewers, we do not charge a fee for printing the manuscript, and if she or he is the next co-author – the fee is PLN 500 plus 23% VAT. The publisher issues invoices. The fee should be paid after receiving positive reviews, and before publishing the manuscript. Membership of the Polish Medical Association with documented paid membership fees for the last 3 years is also the exempt from publication fee.
3. Only papers in English are accepted for publication. The editors can help in finding the right person for translation or proofreading.
4. Papers should be sent to the editor via the editorial panel (Editorial System), available on the journal's website at <https://www.wiadlek.pl>. In order to submit an article, free registration in the system is necessary. After registration, the author should follow the instructions on the computer screen.
5. All editorial work is under control and using the editorial panel. This applies in particular to sending manuscripts, correspondence between the editor and author and the review process. In special cases, the editor may agree to contact outside the panel, especially in case of technical problems.
6. Acceptable formats for individual elements of the article are as follows:
  - A) Content of the article – doc, docx, rtf, odt.
  - B) Tables – doc, docx, rtf, odt
  - C) Figures – JPG, GIF, TIF, PNG with a resolution of at least 300 dpi
  - D) Captions for figures and tables.
 These elements are sent to the editor separately using the editorial panel. References and article metadata such as titles, keywords, abstracts etc. are supplemented by the author manually in the editorial panel in appropriate places.
7. The volume of original papers – including figures and references – must not exceed 21,600 characters (12 pages of typescript), and review papers – up to 28,800 characters (16 pages).
8. The original manuscript should have the following structure: Introduction, Aims, Material and methods, Results, Discussion and Conclusions which cannot be a summary of the manuscript.
9. When using abbreviations, it is necessary to provide the full wording at the first time they are used.
10. In experimental manuscripts in which studies on humans or animals have been carried out, as well as in clinical studies, information about obtaining the consent of the Ethics Committee should be included.
11. The Editorial Board follow the principles contained in the Helsinki Declaration as well as in the Interdisciplinary Principles and Guidelines for the Use of Animals in Research, Testing and Education, published by the New York Academy of Sciences Ad Hoc Committee on Animal Research. All papers relating to animals or humans must comply with ethical principles set out by the Ethics Committee.
12. The abstract should contain 150-250 words. Abstracts of original, both clinical and experimental, papers should have the following structure: Aims, Material and methods, Results, Conclusions. Do not use abbreviations in the title or the abstract. The abstract is pasted or rewritten by the authors into the appropriate field in the application form in the editorial panel.
13. Keywords (3-5) should be given according to MeSH (Medical Subject Headings Index Medicus catalogs – <http://www.nlm.nih.gov/mesh/MBrowser.html>). Keywords cannot be a repetition of the title of the manuscript.
14. Illustrative material may be black and white or color photographs, clearly contrasting or drawings carefully made on a white background. With the exception of selected issues, the Journal is printed in shades of gray (black and white illustrations).
15. The content of the figures, if present (e.g. on the charts), should also be in English
16. Links to all tables and figures (round brackets) as well as references (square brackets) the author must place in the text of the article.
17. Only references to which the author refers in the text should be included in the list of references ordered by citation. There should be no more than 30 items in original papers and no more than 40 items in review papers. Each item should contain: last names of all authors, first letters of first names, the title of the manuscript, the abbreviation of the journal title (according to Index Medicus), year, number, start and end page. For book items, please provide: author's (authors') last name, first letter of the first name, chapter title, book title, publisher, place and year of publication. It is allowed to cite websites with the URL and date of use of the article, and if possible the last names of the authors. Each literature item should have a reference in the text of the manuscript placed in square brackets, e.g. [1], [3-6]. Items should be organized as presented in Annex 1 to these Regulations.
18. When submitting the article to the editor, the authors encloses a statement that the work was not published or submitted for publication in another journal and that they take full responsibility for its content, and the information that may indicate a conflict of interest, such as:
  1. financial dependencies (employment, paid expertise, consulting, ownership of shares, fees),
  2. personal dependencies,
  3. academic and other competition that may affect the substantive side of the work,
  4. sponsorship of all or part of the research at the stage of design, collection, analysis and interpretation of data, or report writing.
19. The authors in the editorial panel define their contribution to the formation of scientific work according to the following key:
  - A – Work concept and design
  - B – Data collection and analysis
  - C – Responsibility for statistical analysis
  - D – Writing the article
  - E – Critical review
  - F – Final approval of the article.
20. In the editorial panel along with the affiliation, the author also gives her or his ORCID number.
21. The Journal is reviewed in double, blind review mode. The submitted papers are evaluated by two independent reviewers and then qualified for publishing by the Editor-in-Chief. Reviews are anonymous. The authors receive critical reviews with a request to correct the manuscript or with a decision not to qualify it for publishing. The procedure for reviewing articles is in line with the recommendations of the Ministry of Science and Higher Education contained in the paper "Good practices in review procedures in science" (Warsaw 2011). Detailed rules for dealing with improper publishing practices are in line with COPE guidelines. The publishing review rules are in the Review Rules section.
22. Each manuscript is subject to verification in the anti-plagiarism system.
23. Manuscripts are sent for the author's approval. The author's corrections should be sent within the time limit indicated in the system. No response within the given deadline is tantamount to the author's acceptance of the submitted material. In special cases, it is possible to set dates individually.
24. Acceptance of the manuscript for publishing means the transfer of copyright to the Aluna Publishing House (Aluna Anna Łuczynska, NIP 5251624918).
25. Articles published on-line and available in open access are published under Creative Commons Attribution-Non Commercial-No Derivatives 4.0 International (CC BY-NC-ND 4.0) allowing to download articles and share them with others as long as they credit the authors and the publisher, but without permission to change them in any way or use them commercially.
26. The authors receive a free PDF of the issue in which their manuscript is enclosed, and on request – a printed copy. The printed copy is sent to the address indicated by the authors as the correspondence address.
27. Manuscripts not concordant with the above instructions will be returned to be corrected.
28. The editors do not return papers which have not been commissioned.
29. The editors take no responsibility for the contents of the advertisements.



## CONTENTS

### ORIGINAL ARTICLES

- Aidyn G. Salmanov, Taras P. Bondar, Yaroslav V. Shkorbotun, Evelina A. Chumak, Volodymyr O. Shkorbotun, Olena V. Dementieva, Vadim V. Pererva  
PREVALENCE OF NASAL CARRIAGE OF METHICILLIN-RESISTANT STAPHYLOCOCCUS AUREUS AMONG HEALTHCARE WORKERS IN THE DEPARTMENTS  
OF OTORINOLARYNGOLOGY AND DENTISTRY IN KYIV, UKRAINE 2563
- Anatoly A. Avramenko  
INFLUENCE OF PECULIARITIES OF ANATOMICAL STRUCTURE (SHAPE) OF DUODENAL BULB ON THE MECHANISM OF FORMATION OF "KISSING" ULCERS  
OF PATIENTS WITH CHRONIC NON-ATROPHIC GASTRITIS 2568
- Marlena Kwiatkowska, Inga Chomicka, Jolanta Malyszko  
COMPARISON OF MOLECULAR AND SEROLOGICAL TESTS FOR SEVERE ACUTE RESPIRATORY SYNDROME CORONAVIRUS 2 (SARS-COV-2)  
IN POST-EXPOSURE EMPLOYEES OF THE NEPHROLOGY DEPARTMENT 2572
- Viktoria V. Alekseeva, Alina S. Nechiporenko, Andrii V. Lupyr, Nadiia O. Yurevych, Vitaliy V. Gargin  
A METHOD OF COMPLEX EVALUATION OF MORPHOLOGICAL STRUCTURE OF OSTIOMEATAL COMPLEX COMPONENTS, LOWER WALL OF MAXILLARY  
AND FRONTAL SINUSES 2676
- Lyudmyla V. Pakharenko, Yuri P. Vdovichenko, Nataliia Ya. Kurtash, Iryna O. Basiuha, Inna V. Kravchuk, Volodymyr D. Vorobii, Olena M. Kusa  
ESTRADIOL BLOOD LEVEL AND ESRT GENE POLYMORPHISM IN WOMEN WITH PREMENSTRUAL SYNDROME 2581
- Khrystyna R. Boriak, Lyudmyla E. Vesnina  
RELATIONSHIP OF THE EATING BEHAVIOR FEATURES WITH ANTHROPOMETRIC INDICATORS AND ENERGY VALUE OF THE DIET IN YOUNG PEOPLE  
WITH NORMAL WEIGHT AND OVERWEIGHT 2586
- Tetiana I. Nimtsovykh, Anatolii M. Kravchenko, Olha Yu. Mishcheniuk, Tamara Ya. Chursina, Kyrylo O. Mikhaliev, Viktor P. Polovyi  
VISIT-TO-VISIT BLOOD PRESSURE VARIABILITY AND TARGET ORGAN DAMAGE IN RURAL DWELLERS WITH UNCOMPLICATED ARTERIAL HYPERTENSION 2591
- Piotr Szolc, Łukasz Niewiara, Marta Kawulak, Kornelia Szkodoń, Elżbieta Ostrowska-Kaim, Marcin Nosal, Marcin Krzanowski, Krzysztof Zmudka,  
Jacek Legutko, Bartłomiej Guzik  
NEUTROPHIL-LYMPHOCYTE RATIO AND PLATELET-LYMPHOCYTE RATIO AS PREDICTORS OF CORONARY MICROCIRCULATORY DISEASE OCCURRENCE  
AND OUTCOME IN PATIENTS WITH CHRONIC CORONARY SYNDROME AND NO SIGNIFICANT CORONARY ARTERY STENOSIS 2598
- Olena L. Zolotukhina, Iuliia G. Romanova, Tetyana O. Pyndus, Georgy O. Romanov, Iryna M. Tkachenko  
EVALUATION OF EFFECTIVENESS OF TREATMENT-AND-PROPHYLACTIC COMPLEX IN TOBACCO-ADDICTED PATIENTS WITH CHRONIC GENERALIZED  
PERIODONTITIS ON THE BACKGROUND OF CHRONIC HYPERACID GASTRITIS 2607
- Oleksij P. Kostyrenko, Nataliia I. Vynnyk, Mykhailo M. Koptev, Petro A. Hasiuk, Maksym I. Skrypnyk, Alevtyna M. Bilous, Serhii A. Proskurnya  
DENTAL CROWN BIOMINERALIZATION DURING ITS HISTOGENESIS 2612
- Olha M. Arustamian, Volodymyr S. Tkachyshyn, Vitalii E. Kondratiuk, Nataliia Yu. Tkachyshyna, Oleksandr Yu. Aleksiichuk, Irina V. Dumka  
INFLUENCE OF ADVERSE PRODUCTION FACTORS ON CEREBRAL HEMODYNAMIC IN LOCOMOTIVE DRIVERS 2617
- Nikolay A. Scherbina, Liliia V. Potapova, Shcherbyna Irina N. Scherbina, Oksana P. Lipko, Olga V. Mertsalova, Anastasiia A. Chekhunova  
MODERN METHODS OF COMPLEX CORRECTION OF PSYCHOSOMATIC DISORDERS IN PATIENTS WITH EXTERNAL GENITAL ENDOMETRIOSIS 2623
- Monika Białkowska, Tomasz Stołtny, Jarosław Pasek, Michał Mielnik, Karol Szyluk, Kamil Baczyński, Robert Hawranek, Aleksandra Koczy-Baron,  
Sławomir Kasperczyk, Grzegorz Cieślak, Bogdan Koczy  
THE INFLUENCE OF HIP ARTHROPLASTY ON HEALTH RELATED QUALITY OF LIFE IN MALE POPULATION WITH OSTEOARTHRITIS HIP DISEASE 2627
- Iryna V. Redka, Oksana Ya. Mikhalchuk, Zhanna V. Sotnikova-Meleshkina  
ELECTROENCEPHALOGRAPHIC MONITORING OF THE BRAIN FUNCTIONAL CONDITION IN MODERN UKRAINIAN SCHOOLCHILDREN 2634
- Oleksii O. Holubenko, Anatolii F. Levytskyi, Oleksandr V. Karabenyuk  
RESULTS OF TREATMENT OF IDIOPATHIC CONGENITAL CLUBFOOT IN CHILDREN: A 3-YEAR FOLLOW UP STUDY 2640

Tamara M. Pasiieshvili, Natalia M. Zhelezniakova, Lyudmila M. Pasiyeshvili, Olga M. Kovalyova TOTAL ANTIOXIDANT ACTIVITY AND MANGANESE SUPEROXIDE DISMUTASE IN COMORBIDITY OF GASTROESOPHAGEAL REFLUX DISEASE AND AUTOIMMUNE THYROIDITIS IN STUDENT POPULATION	2644
Svitlana P. Yarova, Sergii O. Turchenko, Iryna M. Tkachenko, Yuriy Yu. Yarov ANALYSIS OF THE DYNAMICS OF FUNCTIONAL OCCLUSION INDICATORS IN THE CONSTRUCTION OF OCCLUSION SURFACES OF ORTHOPEDIC STRUCTURES	2651
Svitlana P. Palamar, Halyna O. Vaskivska, Liudmyla L. Nezhyva, Liudmyla A. Nazarenko, Serhii S. Terekhov FORMATION OF EDUCATIONAL AND COGNITIVE COMPETENCY OF JUNIOR SPECIALISTS IN THE PROCESS OF SELF-EDUCATIONAL ACTIVITY: EXPERIENCIAL ASPECT	2657
Nataliia O. Riabushko, Roman M. Riabushko, Mykola M. Riabushko, Olena B. Riabushko ASSESSMENT OF QUALITY OF LIFE OF PATIENTS AFTER SURGERY MADE BY THE IN-HOUSE DEVICES AND METHODS	2664
Yevhenii S. Khilnich, Vadym Yu. Davydenko, Ivan I. Starchenko, Mykhailo Ya. Nidzelskyi, Hanna M. Davydenko, Viktor V. Kuznetsov THE EFFECT OF MONOMER OF REMOVABLE DENTURE BASE RESIN ON THE STRUCTURAL ORGANIZATION OF THE GLANDULAR ZONE OF ALBINO RAT HARD PALATE IN THE EXPERIMENT	2667
<b>REVIEW ARTICLES</b>	
Oleksandr A. Halushko, Maryna A. Trishchynska, Tetiana M. Povietkina, Marianna V. Boliuk DIABETES MELLITUS IN COVID-19 PATIENTS: VERDICT OR NOT?	2672
Monika Adamczyk- Sowa, Barbara Gębka- Kępińska, Michał Kępiński MULTIPLE SCLEROSIS – RISK FACTORS	2677
Lyubov V. Smaglyuk, Maryna V. Trofymenko, Alevtyna M. Bilous MODERN ASPECTS IN DIAGNOSIS OF TONGUE`S PARAFUNCTIONS (LITERATURE REWIEV)	2683
<b>CASE STUDY</b>	
Liudmyla A. Vygivska, Olena A. Yakovenko, Evgen V. Blagoveschenskiy, Yevheniia M. Babadzhanian, Lesia A. Rudenko, Kyrylo V. Yakovenko CURRENT STATE OF THE PROBLEM OF ABNORMAL INVASION OF THE PLACENTA IN OBSTETRICS	2688

## ORIGINAL ARTICLE

# THE EFFECT OF MONOMER OF REMOVABLE DENTURE BASE RESIN ON THE STRUCTURAL ORGANIZATION OF THE GLANDULAR ZONE OF ALBINO RAT HARD PALATE IN THE EXPERIMENT

10.36740/WLek202012120

**Yevhenii S. Khilinich, Vadym Yu. Davydenko, Ivan I. Starchenko, Mykhailo Ya. Nidzelskyi, Hanna M. Davydenko, Viktor V. Kuznetsov**

UKRAINIAN MEDICAL STOMATOLOGICAL ACADEMY, POLTAVA, UKRAINE

## ABSTRACT

**The aim:** The paper presents the findings of the study of the 3 month-long effect of the monomer of the "Ftorax" denture base acrylic resin on the structural organization of the mucous membrane and the condition of the salivary glands of the albino rats' hard palate during the experiment.

**Materials and methods:** To achieve this goal, experimental studies involved mature rats, whose hard palate mucosa was smeared with 2% aqueous solution of the monomer of the "Ftorax" denture base acrylic resin twice a day in the morning and evening. The animals were sacrificed on day 30 of the experiment and following 3 months.

**Results:** The findings of the studies of the structural organization of the mucous membrane and the analysis of the micropreparations of the mucous membrane of the hard palate of the animals of Group III have revealed substantial pathological changes both in the covering epithelium and in the lamina propria. The comparison between the intact animals and group of animals subjected to the 3 month-long effect of the monomer showed a significant thickening of the epithelial layer; a decrease in the mitotic index in the basal layer; impaired stratification of the cellular elements of the spinous layer; manifestations of exudative purulent inflammation, cystic and sclerotic changes in the excretory ducts; increase in the amount of connective tissue in the lobules of the salivary glands; decrease in the volume of the secretory parenchyma.

**Conclusions:** Based on the findings of the study we can conclude that the prolonged effect of the monomer of the denture base acrylic resins leads to disorder of the structural organization of the glandular zone of the hard palate; in its submucous layer the total volume of the salivary glands decreases, which, in turn, significantly reduces secretion and leads to hyposalivation.

**KEY WORDS:** structural organization, hard palate, salivary glands, secretion, monomer

Wiad Lek. 2020;73(12 p. I):2667-2671

## INTRODUCTION

Many studies have been devoted to the negative effect of the monomer of removable laminar denture base acrylic resins on the oral tissues [1, 2, 3, 4]. The authors have proved by evidence that the residual monomer, released into the oral fluid in the first months of denture wear, leads to significant lesions in the oral cavity. Our previous studies have established that the residual monomer led to disintegration of the taste receptors of the tongue, resulting in altered gustation [5, 6].

The oral cavity, oral fluid, prosthetic bed, removable laminar dentures is the unified system that ensures complete chewing and, therefore, it is important to study the effect of the monomer on the salivary glands of the oral cavity, especially the minor palatine ones, which are almost completely covered by the base of the maxillary removable dentures. However, the effect of the removable laminar denture bases, including the residual monomer, on the state of the minor salivary glands, which play an important role in maintaining the balance in the oral cavity, is poorly studied to date.

Our previous publications presented the findings of the studies of the state and structural organization of the mu-

cous membrane of the hard palate of rats subjected to the 30-day-long effect of the monomer of denture acrylic resin during the experiment [7]. The follow-up experiment and observations will present the findings of the study of the longer effect of the monomer on the mucous membrane of the hard palate and minor salivary glands.

## THE AIM

To study the 3 month-long effect of the monomer of the "Ftorax" denture base acrylic resin on the structural organization of the mucous membrane and the state of the salivary glands of the albino rats' hard palate in the experiment.

## MATERIALS AND METHODS

19 laboratory Wistar rats, aged 1 to 1.5 years, were involved into the experimental study, carried out in the vivarium of the Ukrainian Medical Stomatological Academy. The animals were assigned into 3 groups: Group I (control; n=5) involved intact animals; Group II (n= 7) involved animals, subjected to the 30-day-long effect of the monomer on the

mucous membrane of the hard palate; Group III ( $n=7$ ) involved animals, subjected to the 3-month-long effect of the monomer on the hard palate mucosa.

The contact was simulated by the smearing of the hard palate mucosa with 2% aqueous solution of the monomer of the "Ftorax" denture base acrylic resin twice a day in the morning and evening. The animals were sacrificed on day 30 of the experiment and following 3 months.

All studies were conducted in compliance with the rules of humane treatment of animals according to the requirements of the Tokyo Declaration of the World Medical Association and the general ethical principles of working with experimental animals, which were approved by the first National Bioethics Congress [8]. The Commission on Biomedical Ethics of the Ukrainian Medical Stomatological Academy has granted permission for experimental studies, as they meet the moral and ethical standards and basic provisions of the Council of Europe Convention on Human Rights and Biomedicine (minutes of the commission meeting as of 22.02.2018 No.162).

After euthanasia, each animal underwent removal of the hard palate, followed by division of the latter into two parts along the midline. One of the obtained fragments of the hard palate, together with the bone base, after 24-hour fixation in neutral 10% formalin, was decalcified for 2-4 weeks, after which it was possible to obtain histological sections from the objects that contained bone tissue [9].

In the second fragment, the mucosa with the submucous layer was separated from the bone tissue using the lid scalpel under the control of a binocular magnifier. The fragments of the soft tissue were fixed in an upright state in neutral 10% formalin for 1-2 days.

The obtained samples, after conventional dehydration were embedded into liquid paraffin using the "Microm" station for paraffin blocks embedding. Sections of 5  $\mu\text{m}$  thick were obtained from the paraffin blocks on the "Leica" rotary microtome and stained with haematoxylin-eosin, using the conventional technique [10].

Visualization and imaging of the micropreparations was made by the Olympus BX-41 microscope equipped with digital microphoto attachment and licensed software package.

## RESULTS

The findings of the studies of the structural organization of the mucous membrane and the analysis of the micropreparations of the mucous membrane of the hard palate of the animals of Group III have revealed substantial pathological changes both in the covering epithelium and in the lamina propria of the mucous membrane. The comparison between the intact animals and group of animals, subjected to the 3 month-long effect of the monomer, showed a significant thickening of the epithelial layer, accounted on the average to  $210 \pm 9,4 \mu\text{m}$ . Notably, all observations have shown that the epithelial layer was characterized by significant variations of this parameter in different areas, leading to alternating areas with dramatically increased epithelium thickening and areas of its thinning, with the latter occupying small area.

Similar to the previous experimental group, the cells of the basal layer were arranged in a single layer, the areas with two- and three-layer arrangement of epitheliocytes were rather rare. The morphometry has established that the mitotic index in the basal layer decreased significantly compared with the previous experimental group, accounting to 17%.

No significant changes in the spinous layer of the covering epithelium have been noted compared with experimental Group II. Periodically, keratin cysts were formed, epithelial cells with the signs of hydropic dystrophy were found in slightly larger amount, and intraepithelial leukocytes were also visualized among the epitheliocytes of the basal and spinous layers.

Admittedly, impaired stratification of the cellular elements and prominent polymorphism, manifested by both altered tinctorial properties of the epithelial cells and some deviations from the typical size and shape of the latter, as well as the increase in the number of dystrophically altered epitheliocytes should be considered as a distinctive feature of the structural organization of the spinous layer of the covering epithelium in the above group of the experimental animals.

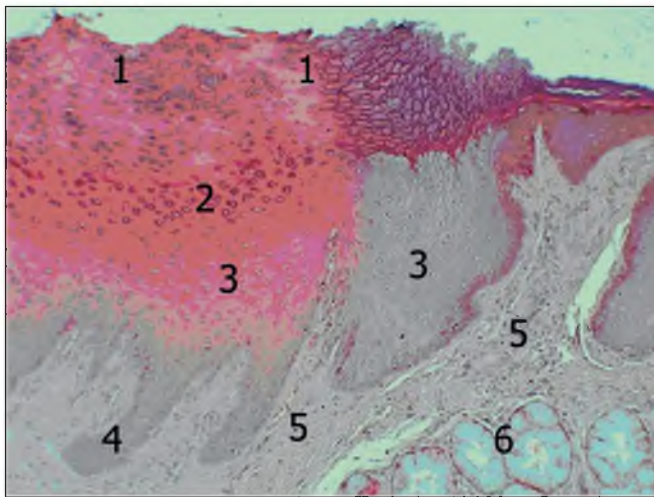
The granular layer was intact, and, similar to the above-mentioned group, was represented by several layers of the oblate cells with the presence of fine granules of keratohyalin in the cytoplasm of the latter (Fig. 1).

The corneous layer was slightly thickened and according to the measurements, the thickness of the latter was  $44 \pm 2,1 \mu\text{m}$  compared with experimental Group II. A distinctive feature in the structure of the corneous layer of the covering epithelium in the animals of this experimental group was the presence of significant lengthy areas in which, in addition to the typical horny plates, the deformed epitheliocytes with pyknotically altered, often fragmented nuclei, were visualized (Figure 1).

The described areas, which were most often identified in the zones of thickening of the covering epithelium, indicated about the disorder of keratinization process of the incomplete keratinization type. These changes cannot be fully regarded as a full-fledged manifestation of the compensatory-adaptive response, since in this case no formation of a continuous "horny shield" was noted with any significant barrier structure for the penetration of pathogenic chemical agent into the lamina propria of the mucous membrane. However, the changes described above probably indicate the onset of the phase of depletion of the compensatory mechanism, which was formed earlier.

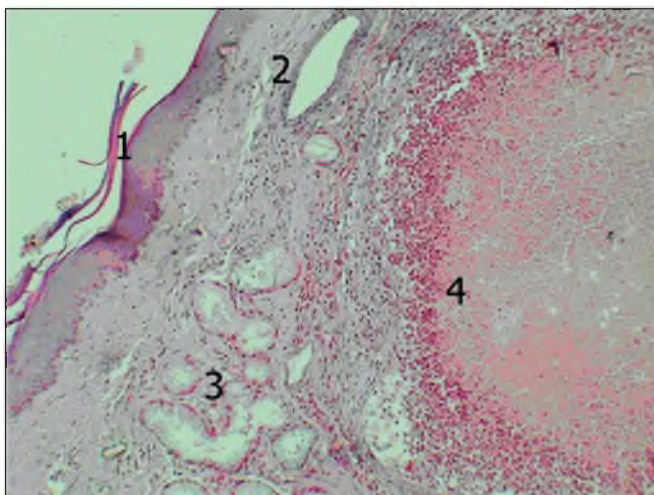
Noteworthy, a larger number of observations showed epithelial complexes quite variable in size, which were rather deeply immersed into connective tissue of the lamina propria of the mucous membrane and have no visible relationship with the layer of covering epithelium. These structures were presented by acanthotic bands of the covering epithelium, as evidenced by the data obtained in the study of serial histological sections. In turn, the formation of such structures indicates a disorder of epithelial proliferation, when no formation of a continuous epithelial layer occurs, which may be associated both with the effect of external stimuli and pathological changes in the underlying connective tissue.





**Fig. 1.** Mucous membrane of the glandular zone of the hard palate (experimental Group III). H&E stain. Lens: 10×magnification, ocular lens: 10×magnification.

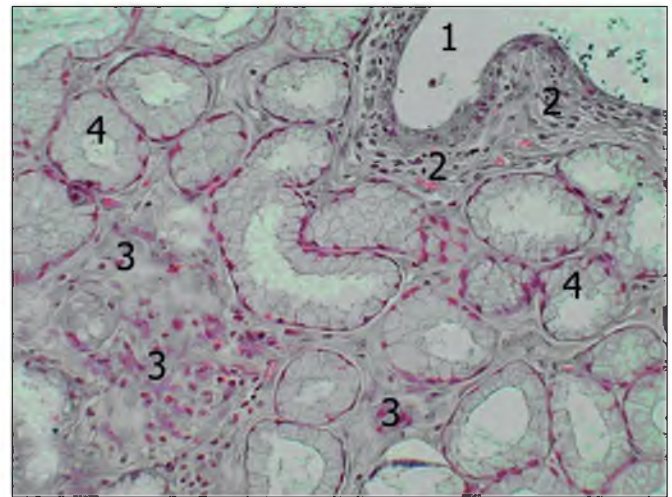
1 – corneous layer; 2 – glandular layer; 3 – spinous layer with altered tinctorial properties; 4 – acanthotic bands; 5 – papillary layer of the lamina propria of the mucous membrane; 6 – acini of the palatine salivary glands.



**Fig. 2.** Mucous membrane of the glandular zone of the hard palate (experimental Group III). H&E stain. Lens: 10×magnification, ocular lens: 10×magnification.

1 – covering epithelium; 2 – dilated excretory duct of the palatine salivary gland; 3 – acini of the salivary glands; 4 – acute abscess in the lamina propria of the mucous membrane

Pathological changes found in the lamina propria of the mucous membrane of the hard palate can be regarded as confirmation of this assumption. First of all, it should be noted that extensive orbicular necrotic areas were noted in the lamina propria of experimental animals of Group III, which occupied both papillary and reticular layers, abundantly infiltrated with neutrophilic polymorphonuclear leukocytes; some of them were destroyed. The described picture corresponds to the onset of acute abscess, which is one of the morphological forms of manifestation of exudative purulent inflammation (Figure 2).



**Fig. 3.** Palatine salivary gland (experimental Group II). H&E stain. Lens: 25×magnification, ocular lens: 10×magnification.

1 – dilated excretory duct; 2 – proliferation of the connective tissue and cellular infiltration around the excretory duct; 3 – proliferation of the connective tissue and cellular infiltration in the glandular lobules; 4 – acini.

We hypothesize that origination of acute abscesses in the lamina propria of the mucous membrane should be regarded as the complication, primarily associated with the weakening of the barrier properties of the covering epithelium, which greatly facilitates the contact penetration of pathogenic microflora from the oral cavity into the connective tissue of the lamina propria of the mucous membrane.

Obviously, purulent inflammatory lesions described above are associated with a decrease in both local and general immunity due to the long-term adverse effects of the chemical agent on the body of experimental animals.

In other cases, in the papillary layer of the lamina propria, changes typical of the chronic inflammatory process were noted, manifested by moderate vascular plethora, presence of diffuse cellular infiltrates with a predominance of lymphocytes and plasma cells. Significant amount of eosinophilic leukocytes were also found in the inflammatory infiltrates. Flattening and deformation of connective tissue papillae, containing homogeneous cell-free zones, were often found, which indicated the development of sclerotic and atrophic processes.

Changes in the reticular layer of the lamina propria were almost similar to the previous experimental group and were characterized by the significant amount of diffuse infiltration of cellular elements of the monocyte-macrophage type, lymphocytes, plasma cells, neutrophils and eosinophilic leukocytes. Periodically, in the deeper segments of the reticular layer, the areas with increased amount of mostly mature fibroblasts were found. Probably, this circumstance may indicate the initiation of the process of collagenation, which is known to underlie sclerotic changes.

Marked changes, compared with the previous experimental group, were found in the palatine salivary glands. Thus, first of all, the presence of significantly expanded areas with a prominent flattening of the epithelial lining in the larger excretory ducts was noteworthy (Figure 3).

Apparently, the cystic alterations found in the excretory ducts were primarily caused by inflammation, as evidenced by the presence of cellular infiltrates in the periductal connective tissue. At the same time, in all cases the apparent thickening of the layers of connective tissue around larger and medium-sized excretory ducts was prominent, indicating the development of sclerotic processes in the salivary glands that can lead to mechanical compression of the ducts with formation of cysts more proximal to a compression site.

The findings of the morphometric studies have revealed increased amount of connective tissue in the lobules of the salivary glands, accounting for 73%; the relative volume of the secretory parenchyma was accounted for 27%.

In the acini of the salivary glands the number of secretory epitheliocytes with altered tinctorial properties increased, compared with the previously described experimental group, which may indirectly indicate a decrease in their secretory activity.

In general, in the submucous layer of the hard palate, the total volume of the salivary glands was 67.6%, which is significantly less than in the previous experimental group. The volume of the connective tissue accounted for the remaining 32.4%.

## DISCUSSION

It has been established that prolonged action of the monomer of the denture base acrylic resin adversely affects the structural organization of the glandular zone of the hard palate of albino rats. Following the 3 month-period, the experimental animals showed substantial pathological changes both in the covering epithelium and in the lamina propria of the mucous membrane, namely, origination of acanthotic bands, indicating a disorder of epithelial proliferation, when no formation of a continuous epithelial layer occurs; the presence of extensive necrotic areas in the lamina propria of some experimental animals, infiltrated with neutrophilic polymorphonuclear leukocytes. Some of the leukocytes were destroyed, indicating the onset of acute abscess, which is one of the morphological forms of manifestation of exudative purulent inflammation.

The findings of the study have found that inflammation becomes chronic within 3 months, leading to the changes in the salivary glands of the hard palate that are manifested by the cysts, formed in the excretory ducts. We hypothesized that the formation of such cysts was mainly caused by inflammatory changes in the ducts, mechanical deformation, accompanied by a narrowing of the lumen of the latter, as well as changes in the physicochemical properties of the product of secretion.

Many researchers report on the onset of pathological lesions in the hard palate mucosa, and especially in the minor salivary glands, under the impact of various factors [4, 11, 12]. The findings of their studies have found that the action of residual monomer leads to dilatation of the excretory ducts of minor salivary glands, destructive changes in the glands, which, in turn, reduces their secre-

tory activity; the ratio of the parenchyma to the stroma of salivary glands changes. Similar changes in the secretory activity of the salivary glands were reported by other authors [13], who proved that the phenomena of galvanosis lead to its significant reduce.

## CONCLUSIONS

1. The prolonged effect of the monomer of the "Ftorax" denture base acrylic resin on the rat hard palate mucosa leads to a significant pathological processes, namely, thickening of the epithelial layer; a decrease in the mitotic index in the basal layer; impaired stratification of the cellular elements of the spinous layer and the events of their polymorphism; the onset of acute abscesses in the lamina propria of the mucous membrane as the manifestations of exudative purulent inflammation.
2. 3 month-long effect of the monomer leads to a significant pathological lesions in the palatine salivary glands, namely, cystic and sclerotic changes in the excretory ducts; increased amount of connective tissue in the lobules of the salivary glands; decrease in the volume of the secretory parenchyma; decrease in secretory activity of palatine salivary glands due to increased amount of secretory epitheliocytes with altered tinctorial properties.
3. In general, in the submucous layer of the hard palate, the total volume of the salivary glands was significantly reduced, accounting for 67.6%.

## REFERENCES

1. Bykov I.M., Akopova L.V., Skorikova L.A. Biokhimicheskiye pokazateli gomeostaza i biotsinoza polosti rta u patsiyentov s protezным stomatitom [Biochemical indicators of oral cavity homeostasis and biocinosis in patients with prosthetic stomatitis]. *International Journal of Applied and Basic Research*. 2015; 3: 517-523. (in Russian).
2. Senchakovych YU.V., Yeroshenko H.A., Kazakova K.S., Bilash S.M. Vplyv metakrylatu na funktsiyu slynykh zaloz [The effect of methacrylate on the function of the salivary glands]. *The world of medicine and biology*. 2014; 1 (43): 181-185. (in Ukrainian).
3. Pervov Yu.Yu. Vliyaniye s'yemnykh akrilovykh zubnykh protezov na immunny gomeostaz slizistoy obolochki polosti rta v zavisimosti ot primenyayemykh materialov i konstruksiy [The effect of removable acrylic dentures on the immune homeostasis of the oral mucosa depending on the materials and structures used]. *Kazan Medical Journal*. 2012; 93 (2): 227-230. (in Russian).
4. Romanova Yu. G. Vliyaniye patologicheskogo narusheniya gomeostaticheskikh sistem polosti rta na sroki adaptatsii k s'yemnym akrilovym zubnym protezam [Influence of pathological disorders of homeostatic systems of the oral cavity on the timing of adaptation to removable acrylic dentures]. *Reaching the biology of medicine*. 2012; 2 (20): 54-57. (in Russian).
5. Davydenko V.Yu. Vplyv zalyshkovoho monomera bazysiv znimnykh plastyinkovykh proteziv na stan smakovykh retseptoriv ta smakovu chutlyvist' [Influence of residual monomer of removable plate prosthesis bases on the state of taste receptors and taste sensitivity]. "Medical science in health care practice": materials of the all-Ukrainian scientific-practical conference. Poltava, 2015:7. (in Ukrainian).

6. Davydenko V, Starchenko I, Davydenko A, Trufanova V, Kuznetsov V. The impact of the acrylic monomer on the morphological structure of rat lingual mucosa. *Georgian medical news*. 2018;5(278):146–151.
7. Khilinich Ye., Starchenko I, Davydenko V, Nidzelskiy M, Davydenko G. Condition and structural organization of the glandular area mucous membrane of albino rat hard plate under the 30-day-long effect of acrylic monomer. *World of medicine and biology*. 2020;1(71):216–220.
8. Obshchiye eticheskiye printsipy raboty s eksperimental'nymi zhivotnymi pri provedenii meditsinskikh biologicheskikh issledovaniy [General ethical principles of working with experimental animals in medical biological research]. *Natsional'niy kongress z bioetiki (Kiev, 17-20 veresnya 2001r.)*. Journal of the National Academy of Medical Sciences of Ukraine. 2001; 7(4):814-816. (in Russian).
9. Korzhavskiy D. E., Gilyarov A. V. *Osnovy gistologicheskoy tekhniki [Fundamentals of histological techniques]*. SPb. : SpetsLit. 2010:95. (in Russian).
10. Bagriy MM, Dibrova VA, Popadynets OG, Grishchuk MI. *Metodyky morfolohichnykh doslidzen' [Methods of morphological research]*. Vinnytsia: New book. 2016:328. (in Ukrainian).
11. Senchakovich Yu.V., Kazakova KS, Yeroshenko GA. Suchasni pohlyady na prychny dysfunktsiyi slyunnykh zaloz [Modern views on the causes of salivary gland dysfunction]. *The world of medicine and biology*. 2013; 9 (4-1):112 – 116. (in Ukrainian).
12. Sherstyuk O.A., Svintsitskaya N.L., Pilyugin A.V. *Issledovaniye stromy, parenkhimy i ikh vzaimootnosheniy v malykh slyunnykh zhelezakh cheloveka [Study of the stroma, parenchyma and their relationship in the small salivary glands of a person]*. *Ukrainian morphological almanac*. 2010; 3:156-157. (in Russian).
13. Timofeev A.A. *Sekretornaya funktsiya bol'shikh i malykh slyunnykh zhelez pri gal'vanizme i gal'vanoze [The secretory function of large and small salivary glands in galvanism and galvanosis]*. *Modern dentistry*. 2013; 3: 72–76. (in Russian).

*The paper has been written within the research scientific work, entitled “The effect of dental constructs and material on the prosthetic bed and adaptive abilities of the body”, State registration No. 0116U004188, performed at the Department of Postgraduate Education of Prosthodontists of Ukrainian Medical Stomatological Academy.*

#### **ORCID and contributionship:**

*Yevhenii S. Khilinich: 0000-0001-7970-944X<sup>D</sup>*  
*Vadym Yu. Davydenko: 0000-0002-4231-7343<sup>B</sup>*  
*Ivan I. Starchenko: 0000-0002-6666-1448<sup>E</sup>*  
*Mykhailo Ya. Nidzelskiy: 0000-0002-5629-0719<sup>F</sup>*  
*Hanna M. Davydenko: 0000-0001-6219-2376<sup>A</sup>*  
*Viktor V. Kuznetsov: 0000-0002-6707-830X<sup>C</sup>*

#### **Conflict of interest:**

*The Authors declare no conflict of interest*

---

#### **CORRESPONDING AUTHOR**

##### **Vadym Yu. Davydenko**

Department of Postgraduate Education of Prosthodontists  
 Ukrainian Medical Stomatological Academy  
 St. Shevchenka 23, Poltava, Ukraine  
 tel: +380507321085  
 e-mail: davydenko.a24@gmail.com

**Received:** 21.08.2020

**Accepted:** 27.11.2020

---

**A** – Work concept and design, **B** – Data collection and analysis, **C** – Responsibility for statistical analysis, **D** – Writing the article, **E** – Critical review, **F** – Final approval of the article