

## ORIGINAL ARTICLE

# MORPHOMETRIC FEATURES OF THE STRUCTURAL COMPONENTS OF THE HEMOMICROCIRCULATORY BED IN THE PERIVULNAR REGION OF THE CAECUM IN WOUND DEFECT SUTURED WITH POLYFILAMENT SUTURE MATERIAL

DOI: 10.36740/WLek202106118

Olena M. Pronina<sup>1</sup>, Serhii M. Bilash<sup>1</sup>, Mykola M. Kobeniak<sup>1</sup>, Mykhailo M. Koptev<sup>1</sup>, Angelina V. Pirog-Zakaznikova<sup>1</sup>, Valentyna V. Onipko<sup>2</sup>, Volodymyr I. Ischenko<sup>2</sup>

<sup>1</sup>POLTAVA STATE MEDICAL UNIVERSITY, POLTAVA, UKRAINE

<sup>2</sup>POLTAVA V. G. KOROLENKO NATIONAL PEDAGOGICAL UNIVERSITY, POLTAVA, UKRAINE

## ABSTRACT

**The aim:** The study focuses on the morphometric features specification concerning the structural components of the hemomicrocirculatory bed of the perivulnar region of the cecum in rabbits when suturing a wound defect with synthetic polyfilament surgical suture Vicryl.

**Materials and methods:** The research was carried out on rabbits (n = 30: 5 animals made up the control group and 25 animals made up the experimental group) and included surgery based on the method of surgical intervention on the large intestine patented by the authors, which was performed in the conditions of the operating room at the Department of Clinical Anatomy and Operative Surgery. When determining the main morphometric parameters, we took biopsy specimens of the cecum and used paraffin and epoxy resin embedding considering the generally accepted methods.

**Results:** The study determined that the implantation of Vicryl surgical suture material in the tissues of the cecum became a trigger for the formation of active inflammatory focus and occurrence of leukocyte infiltrate in the perivulnar region.

**Conclusions:** Arterioles, as a resistive link, capillaries, as an exchange link and venules, as a capacitive link in the hemomicrocirculatory bed, actively participate in response to the inflammatory process and formation of a connective tissue scar. The process of structural organization of microvessels begins in the formed granulation tissue in the perivulnar region of the cecum starting from the 14th day of the experiment.

**KEY WORDS:** cecum, vicryl, hemomicrocirculatory bed

Wiad Lek. 2021;74(6):1382-1388

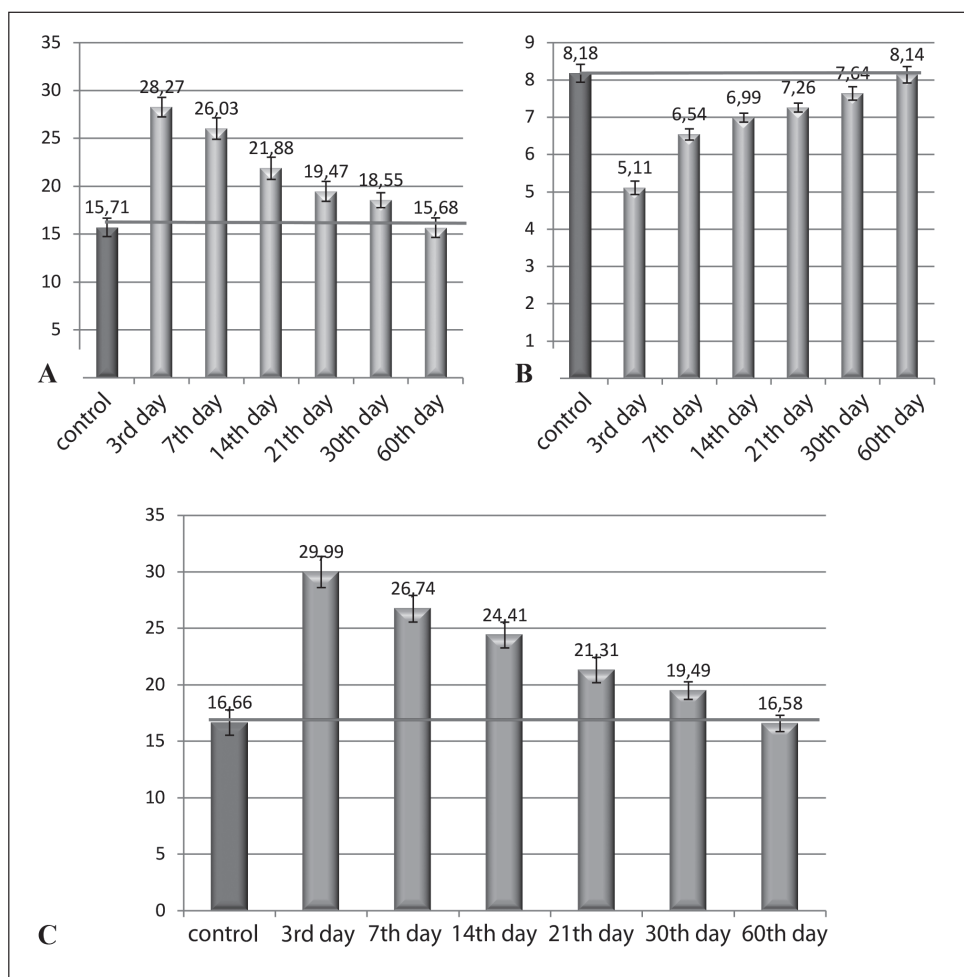
## INTRODUCTION

Diseases of the digestive system, in particular the large intestine, are quite common nowadays and, unfortunately, their prevalence is steadily growing [1, 2]. A number of factors such as lifestyle, nutrition, environmental pollution, various endogenous and exogenous factors [3, 4] can cause such changes. Colon cancer has also been diagnosed on a large scale. All of the above forms of the large intestine diseases are among the most relevant problems in modern surgical practice and require a prompt solution [5]. The issues on selection of surgical suture material, expediency of its use in one case or another, timing of resorption, value of morphometric parameters, as well as time of healing and scar formation arise quite often. Therefore, these issues are relevant nowadays, considering the prevalence of chronic inflammatory diseases, cancer pathologies and surgical interventions on the intestines. Based on 2018 data, the world statistics informs us that over the past 100 years, oncopathology has shifted from

tenth to second place in terms of morbidity and mortality, second only to diseases of the cardiovascular system. According to the WHO data, by 2030 year, cancer mortality will increase by 45%, compared to 2007 level. Ukraine ranks second in Europe in terms of cancer prevalence. Cancer of intestine and its various departments amounts to 60% among the nosological forms of oncopathology and is one of the most common, both in men and women [6]. Therefore, the issue on suture material selection for minimizing postoperative complications is relevant and currently important.

## THE AIM

The study was aimed at specifying the morphometric features of the structural components of the hemomicrocirculatory bed in the perivulnar part of the cecum in rabbits when suturing a wound defect with synthetic polyfilament surgical suture Vicryl.



**Fig. 1.** Morphometric characteristics of the average total diameters in the hemomicrocirculatory bed elements of the intestinal wall mucosa in the area of the wound defect sutured with Vicryl suture in the dynamics of the experiment: A – arterioles; B – capillaries; C – venules.

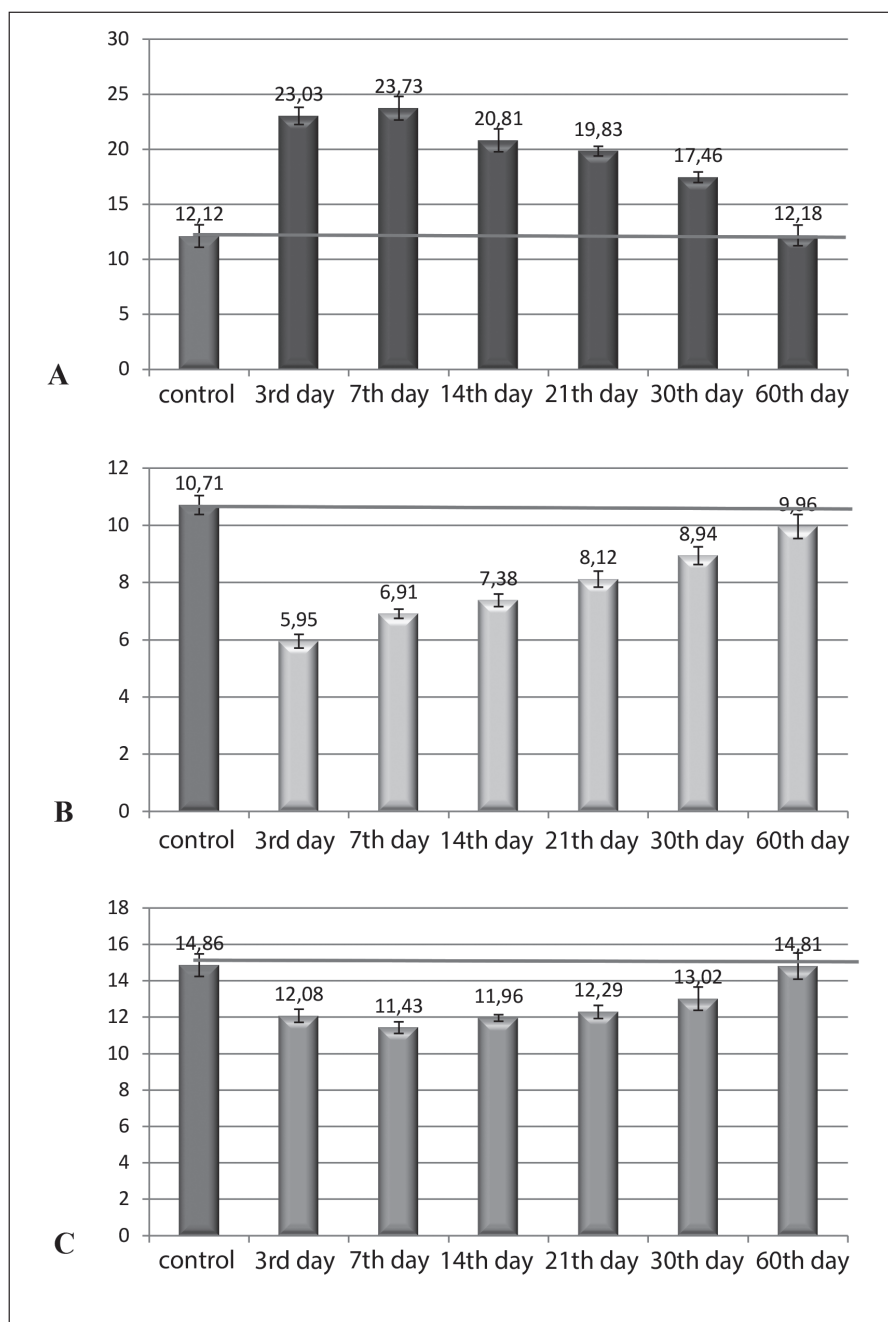
## MATERIALS AND METHODS

The research involved experimental rabbits ( $n = 30$ : 5 animals made up the control group and 25 animals made up the experimental group). Management of animals and all manipulations on them were carried out in accordance with the “Rules for the Use of Laboratory Experimental Animals” (2006, Appendix 4) and the Declaration of Helsinki on the humane treatment of animals, the Law of Ukraine “On the Protection of Animals from Cruelty” (No. 3447-IV, dated February 21, 2006), in compliance with the requirements of the Commission on Bioethics of the Ukrainian Medical Stomatological Academy (minute No. 170, dated January 24, 2019), consistent with the provisions of the “European Convention for the Protection of Vertebrate Animals Used for Experimental and Other Scientific Purposes” (Strasbourg, 1986).

We performed the surgery based on our patented method of surgical intervention on the large intestine under the conditions of the operating room at the Department of Clinical Anatomy and Operative Surgery [7]. The tissues of the cecum were dissected between the omental and free taeniae of the large intestine parallel to them and

perpendicular to the haustra, 3-4 cm long. Subsequently, after the incision, the tissues of the large intestine were sutured with a double-row suture applying Vicryl suture surgical material.

For the first row of sutures we used a continuous screw-in Schmidten suture. The second one, or the so-called clean suture, was carried out applying Lambert’s sero-serous interrupted suture. This technique provided the wound tightness and made it possible to obtain a high-quality histological material containing implanted research surgical suture when the repeated sampling of cecum tissues was required for examination within a certain time frame. Specification of the main morphometric parameters included taking of biopsy specimens of the cecum and paraffin and epoxy resin embedding according to the generally accepted techniques [8]. Thin 4-5  $\mu\text{m}$  sections were made from paraffin blocks followed by hematoxylin and eosin van Gieson staining, as well as Hart staining. Semi-thin 1-2  $\mu\text{m}$  sections were made from epoxy blocks and stained with methylene blue and toluidine blue followed by examination of histological sections with a light microscope Olympus C 3040-ADU containing digital microphotographic attachment and



**Fig. 2.** Morphometric characteristics of the average total diameters in the hemomicrocirculatory bed elements of the intestinal wall submucosa in the area of the wound defect sutured with Vicryl surgical suture in the dynamics of the experiment: A – arterioles; B – capillaries; C – venules.

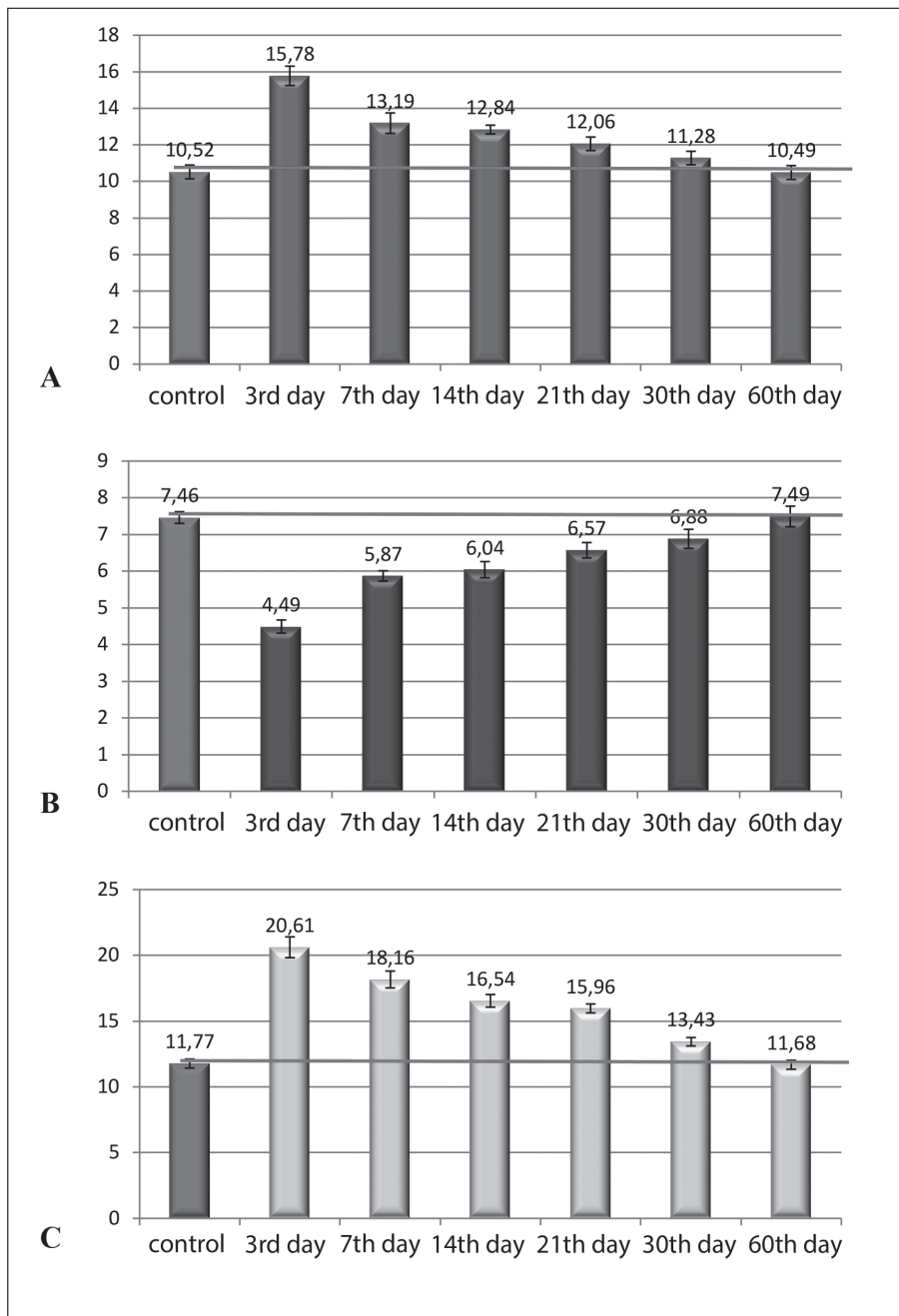
software adapted for studies presented (Olympus DP – Soft, license No. VJ285302, VT310403, 1AV4U13B26802) and Biorex 3 (serial number 5604).

While performing morphometric investigations, we used a system of visual analysis of histologic specimens. Images of histologic specimens were displayed on computer monitor from microscope and applying Visiion CCD Camera. Morphometric studies were provided by VideoTest-5.0, KAAPA Image Baseta Microsoft Excel programs on a personal computer. We examined the total diameter, lumen diameter and wall thickness of microvessels (arterioles, capillaries, venules) and statistically processed the data with Statistica 10 BiostatPro 6 software, as well as with Microsoft Excel 2016. The validation of

the calculations and indicators in the samples was carried out applying Shapiro-Wilk test. The quantitative data assessment included determination of the arithmetic mean of the variation series (M) and its standard error (m). To compare quantitative values in paired rows, we used Student’s t-test. The difference was considered significant at  $p < 0.05$  values.

## RESULTS

The study determined the vascular response patterns of the hemomicrocirculatory bed elements (HMCEB) to experimental cecum wall damage, which resulted in inflammatory process of the perivulnar region at the

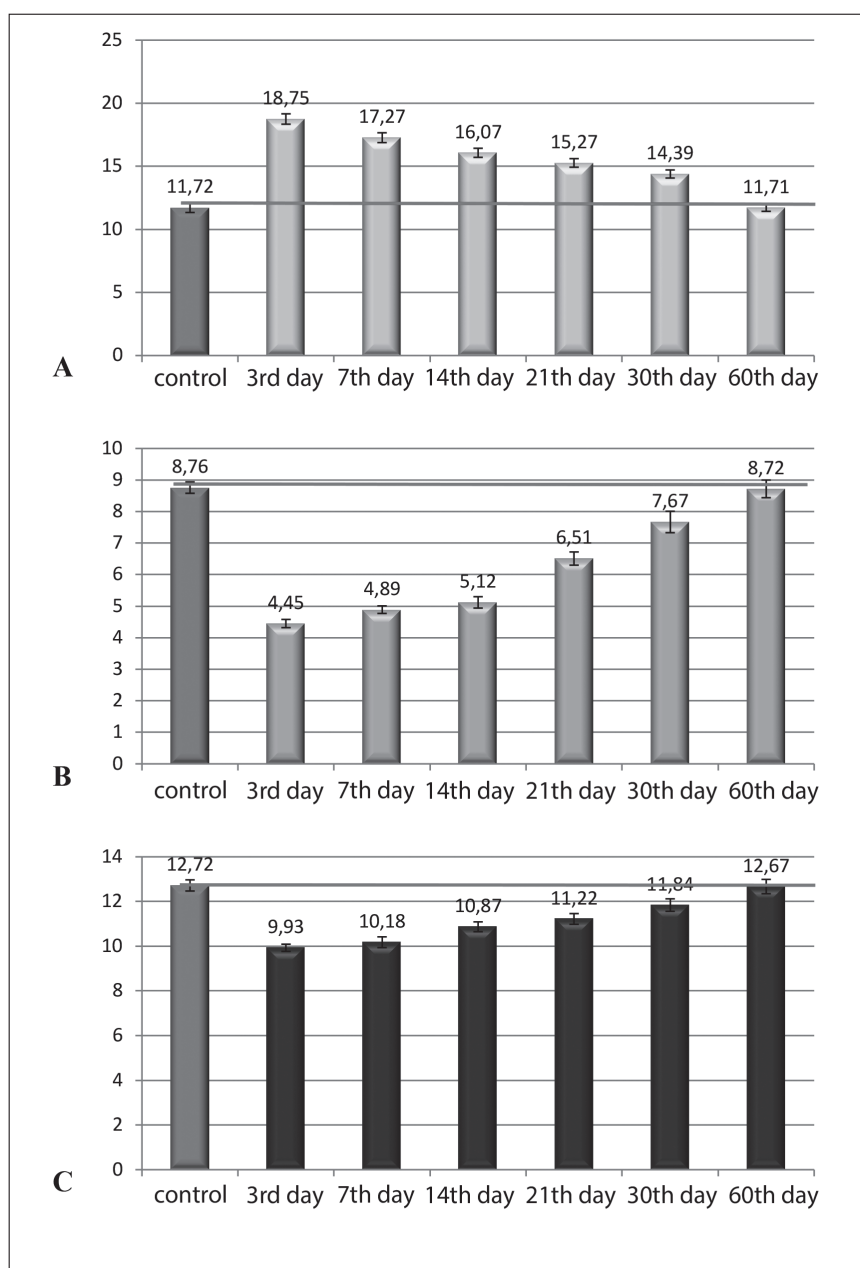


**Fig. 3.** Morphometric characteristics of the average lumen diameters in the hemomicrocirculatory bed elements of the intestinal wall mucosa in the area of the wound defect sutured with Vicryl suture in the dynamics of the experiment: A – arterioles; B – capillaries; C – venules.

early stages and formation of connective tissue scar at the later stages of observation. Thus, the average outer diameter of arterioles, as a resistive link of HMxCB of the cecal mucosa, increased 1.8-fold on the 3rd day of the experiment, and 1.66-fold on the 7th day, which caused the increase in the blood filling of the perivascular region and the formation of active inflammatory focus. The same pattern was observed with arterioles of the submucosa, only the increase coefficients amounted to 1.9-fold on the 3d day and almost 2-fold – on the 7th day, which in turn resulted in the formation of leukocyte infiltrate in the perivascular region. Starting from the 14th day of observation, the arterioles of both mucosa and submucosa, gradually decreased their total

diameter and up to the 60th day of the experiment met the control value.

The capillaries of the cecum mucosa and submucosa, as an exchange link of the HMxCB, began to spasm sharply by 1.6 times starting from the 3rd day of observation, performing the function of blood flow restraining when it actively filled the perivascular region and the formation of active inflammatory focus. From the 7th day of the experiment, they tended to expand. Thus, on the 7th day, the exchange vessels were 1.25 times narrower, compared with the control indicators, and starting from the 14th day – by 1.17 times, and already from the 30th day of the experiment, the capillaries corresponded to the control value, considering the average statistical error at  $p < 0.05$  (Fig. 1, 2).



**Fig. 4.** Morphometric characteristics of the average lumens diameters in the hemomicrocirculatory bed elements of the intestinal wall submucosa in the area of the wound defect sutured with Vicryl surgical suture in the dynamics of the experiment: A – arterioles; B – capillaries; C – venules.

Venules, as a capacitive link of HMCB, expanded by 1.8 times in the intestinal wall mucosa on the 3rd day of the experiment and in the period from 3 to 7 days stayed in such functional state. From the 14th day of the experiment, they tended to narrow at  $p < 0.05$  compared with the previous observation period and reached the indicators of the control group on the 30th day of observation. Venules of the submucosa, on the contrary, spasmed by 1.3 times from the 3rd to the 7th day of the experiment, which was associated with the active blood supply through arterioles during this experimental period and the capillaries spasm. Starting from the 30th day, venules reached their functional state and corresponded to the control value, considering the average statistical error at  $p < 0.05$  (Fig. 1, 2).

According to the literature data, the response of the hemomicrocirculatory bed elements to the impact of

exogenous or endogenous factors, as well as to various damages, is quite specific and corresponds to the certain patterns, especially when these structures are surrounded by a large amount of connective and epithelial tissue. Therefore, when carrying out a morphometric study of the hemomicrocirculatory bed elements, we considered it expedient to analyze the changes not only in the average indicators of the total diameter of arterioles, capillaries and venules, but also changes in the indicators of the average diameter of lumens as well as the average wall thickness of these vessels.

Based on the data of the morphometric assessment of the average diameters of lumens in arterioles, capillaries and venules of the cecum mucosa in the perivulnar region, we determined that the arterioles increased their average diameter of lumens by 1.5 times starting from the 3rd day of observation. The average diameter of the

arteriole lumens was statistically significant at  $p < 0.05$  and did not differ from the analogous indicator in animals of the control group from the 7th experimental day (Fig. 3).

The average diameter of the capillaries lumen, on the contrary, narrowed by 1.7 times starting from the 3rd day of observation, which, in our opinion, caused difficulty in blood flow in the perivascular region due to edema of the connective tissue and the intestinal wall as a whole. Starting from the 7th day of the experiment, the capillaries began to restore the indicator of the average diameter of lumen, but compared with the control group, these indicators were 1.27 times higher. From the 21st day of the experiment, the average diameter of the lumen reliably approximated the control indicators, and the measurement range was within the statistical error (Fig. 3).

Venules, in contrast to capillaries and by analogy with arterioles, increased their lumen diameter starting from the 3rd day of the experiment, but the morphometrically determined coefficient of increase in the index was higher than in arterioles. On the 3rd day of observation, the average diameter of the venule lumen was significantly higher by 1.75 times at  $p < 0.05$  compared with the control indicators, on the 7th day – by 1.54 times, and on the 10th experimental day – by 1.25 times. Starting from the 30th day of observation, this indicator reached the control indicators, and the measurement range was within the statistical error (Fig. 3).

In the dynamics of the experimental study, the changes in the average diameters of the lumen of arterioles, capillaries and venules were different in the area of the wound defect of the cecum submucosa. The average diameter of the arterioles lumen was increased by 1.6 and 1.3 times from the 3rd to 7th days of observation, respectively. The average diameter of the arterioles lumen did not statistically differ from those of the control group of animals from the 30th to 60th days of the experiment and was within the statistical error (Fig. 4).

The average diameter of the capillaries lumen in the caecum submucosa changed dynamically depending on the time of observation. Thus, starting from the 3rd day of the experiment, the average diameter of the capillaries lumen decreased almost 2 times in comparison with the control group. On the 7th day of the experiment, this indicator did not differ significantly at  $p < 0.05$  from that in the previous observation period and compared to the control it was 1.8 times lower. Starting from the 14th day of the experiment, the indicator of the average diameter of the capillaries lumen tended to restore, but was still 1.2 times lower than the control indicator (Fig. 4).

The average diameter of the capillaries lumen did not statistically differ from those of the control group of animals from the 21st day of the experiment and was within the statistical error. The average diameter of the venules lumen in the submucosa 1.3-fold decreased starting from the 3rd experimental day. From the 7th day of observation, this indicator tended to restore in comparison with the control ones, and already on the 14th experimental day, the average diameter of the venule lumen did not

statistically differ from the analogous indicators of the control group of animals and was within the statistical error (Fig. 4).

While comparing the changes in the average diameters of the lumens of arterioles, capillaries and veins of the mucosa and submucosa, it should be noted that the indicators correlate with each other at different periods of the experimental study, presenting unidirectional morphological changes in the mentioned structures (Fig. 4).

## DISCUSSION

The data of research presented make it possible to conclude that the implantation of Vicryl surgical suture material in the tissue of the cecum is a trigger for the formation of the active inflammatory focus as well as leukocyte infiltrate in the perivascular zone, which is proved by the changes in the structural components of the hemomicrocirculatory bed, namely, arterioles, capillaries and venules.

The average indicators of the total diameter, lumen diameter and wall thickness of the microvessels changed in the dynamics of the experiment (from the 3rd to 60th days) and corresponded to the phases of the inflammatory response in the perivascular region and the timing of reparative and regenerative processes [9].

Damage to the intestinal wall is caused by an incision that necessarily causes destructive changes in the tissues that are surrounding the wound defect. Suturing of the wound defect with surgical suture material partially restores the integrity of the intestinal wall and initiates several structural changes on the part of the tissues surrounding the wound defect. These changes, in turn, are aimed at isolation, with further resorption of the surgical thread as a foreign body, the implementation of the inflammatory process caused by the incision of the intestinal wall, and the formation of connective tissue, capable scar at the site of the incision. The main reparative changes of the perivascular zone of the intestinal wall were determined in the mucous membrane due to its thickening as a result of connective tissue edema, destructive and reparative changes of its own plate, and cellular elements, and accumulation in the submucosa of a significant amount of leukocyte infiltrate [10].

Such reactions and processes are consistent and are parts of the whole chain of reparative and adaptive processes. When suturing the wound defect with Vikril surgical thread from the beginning of the experiment on histological specimens, it was found that the surgical thread was surrounded by edematous fluid, and hemorrhages were detected in neighboring tissues. The fibrous component of the connective tissue was divided and leukocyte and lymphocyte infiltration was detected [11].

## CONCLUSIONS

1. Arterioles, as a resistive link, capillaries, as exchange link and venules, as a capacitive HMCB link are actively



- involved in the response to the inflammatory process and formation of connective tissue scar.
- Arterioles of the cecum mucosa and submucosa in the area of the wound defect responded by expanding the average diameters at the early stages of the experiment (3-7 days) and up to 30-60 days met the control parameters.
  - Capillaries spasmed at the early stages of observation and reached the control values up to 30 days.
  - Venules of the mucosa expanded at the early stages of the experiment, while the venules of submucosa, on the contrary, narrowed and reached the control values on the 30th experimental day.
  - The processes of the structural organization of microvessels began in the formed granulation tissue in the perivulnar region of the caecum from the 14th experimental day.

## REFERENCES

- Timerbulatova V.M., Fajazova R.R., Khasanova A.G. Timerbulatova aequabitor ipsi Urazbahtinas IM. Trauma Surgery e converso. M.: MED, press-certioem facere; Laboratorium animalia per Stuctural organization in 2005. M. CCLVI Ipp.Sydorenko normalis sententia comparativa, et in aspectu. Renuntiationes Insecta de/ Insecta. 2019;25 (2):10. DOI: 10,1393
- Bilash S.M. Morphometric characteristics of pyloric gastric glands at experimental acute gastritis and after administration of 'platex-placental' medication on the background of experimental acute gastritis. Problems of Cryobiology and Cryomedicine. 2013; 23(1): 84–90. (in Ukrainian).
- Bilash S.M., Koptev M.M., Vynnyk N.I. et al. Inflammation-related morphological alterations in the microvasculature. Aktual'ni problemy suchasnoyi medytsyny: Visnyk Ukrayins'koyi medychnoyi stomatolohichnoyi akademiyi. 2021;21(1):155-159. DOI 10.31718/2077-1096.21.1.155. (in Ukrainian).
- Hryn V.H., Kostylenko Yu.P., Yushchenko Yu.P. et al. Comparative histological structure of the gastrointestinal mucosa in human and white rat: A bibliographic analysis. Wiad. Lek., 2018;7 (71): 1398-1403. (in Ukrainian).
- Mishalov V.H., Burka A.O., Teslyuk I.I. Khirurgichne likuvannya khvorykh z pislyaoperatsiynymy hryzhamy poperekovo-bokovykh dilyanok zhyvota. [Surgical treatment of patients with postoperative hernias of the lumbar-lateral areas of the abdomen]. Khirurgiya Ukrainy. 2015 Ber;1(25):99-105. (in Ukrainian).
- Pronina O.M., Koptev M.M., Bilash S.M. et al. Response of hemomicrocirculatory bed of internal organs on various external factors exposure based on the morphological research data. Svit biolohiyi ta medytsyny, 2018;1 (63), 153-157. DOI 10.26.724 / 2079-8334-2018-1-63-153-157. (in Ukrainian).
- Pronina O.M., Bilash S.M., Kobenyak M.M. Pat. 140000 Ukrayina, MPK(2020.01) A61L 17/00 Sposib operatyvnoho vtruchannya na tovstomu kyshechnyku dlya doslidzhennya mekhanizmiv rozsmoktuvannya shovnykh nytok. vlasnyk Ukrayins'ka medychna stomatolohichna akademiya – № u 201905403; zayavl. 20. 05. 19; opubl. 10.02.20, Byul № 3. (in Ukrainian).
- Bilash S.M., Pronina O.M., Koptev M.M. Comprehensive morphological studies as an intergal part of modern medical science. Literature review. Visnyk problem biolohiyi i medytsyny. 2019;2(151):20-3. DOI: 10.29254/2077-4214-2019-2-2-151-20-23. (in Ukrainian).
- Kobeniak M.M., Pronina E.N. Reparativna regeneracija tkanin tovstogo kishechnika v ranni termini pri zshivanni ih vikrilom ta desmosinom pislja kolotomii. [Reparative regeneration of intestinal tissue in the early term in case of suturing with vicryl and desmosin for colotomy]. Aktualni problemi suchasnoi medicini: Visnik Ukrainскоi medichnoi stomatologichnoi akademii. 2017;4(60):55-7. (in Ukrainian)
- Bilash S.M., Pronina O.M., Kobeniak M.M. Morfolohichna charakteristika tkanin tovstogo kishechnika pislja eksperimentalnoi rezekcii z vikoristannjam desmosinu u viddaleni stroki. [Morphological characteristics of colon tissues after experimental resection using desmosin in the long term] III Vseukrainska naukovo-praktichna konferencija «Morfolohija ljudini ta tvarin», prysvjachenoj 70-ij richnici z dnja narodzhennja profesora O.I. Cebrzhinskogo. 2017:12. (in Ukrainian).
- Bilash S.M., Pronina O.M., Kobeniak M.M., Sidorenko M.I. Osoblyvosti krovopostachannya serednoho viddilu travnoyi systemy u porivnyalno – vydivomu aspekti. [Features of blood supply of the middle part of the digestive system in the comparative - species aspect] Vistnyk problem biolohiyi i medytsyny 2019; 2 (154): 294-297. DOI:110.29254/2077-4214-2019-4-2-154-294-297. 7. (in Ukrainian).

*The study is a fragment of research work: “Experimental and morphological substantiation of the effect of new surgical suture materials, implants and covering surfaces on various organs when used in experiment and clinical practice” No. 0118U004459.*

## ORCID and contributionship:

Olena M. Pronina 0000-0002-8242-6798 <sup>A, D, F</sup>  
 Serhii M. Bilash 0000-0002-8351-6090 <sup>A, C, E</sup>  
 Mykola M. Kobeniak 0000-0002-7989-5534 <sup>B, C, D</sup>  
 Mykhailo M. Koptev 0000-0002-3726-8911 <sup>B, C, D</sup>  
 Angelina V. Pirog-Zakaznikova 0000-0001-9070-1588 <sup>B, C, D</sup>  
 Valentyna V. Onipko 0000-0002-2260-971X <sup>B, C, D</sup>  
 Volodymyr I. Ischenko 0000-0003-3513-2110 <sup>B, C, D</sup>

## Conflict of interest:

*The Authors declare no conflict of interest.*

## CORRESPONDING AUTHOR

### Mykola M. Kobeniak

Poltava State Medical University  
 23 Shevchenko st., 36024 Poltava, Ukraine  
 tel: +380957260208  
 e-mail: kobeniak1987@gmail.com

**Received:** 22.10.2020

**Accepted:** 15.04.2021

**A** - Work concept and design, **B** - Data collection and analysis, **C** - Responsibility for statistical analysis, **D** - Writing the article, **E** - Critical review, **F** - Final approval of the article