

**Ministry of Public Health of Ukraine  
Higher State Educational Establishment of Ukraine  
«Ukrainian Medical Stomatological Academy»**

**RYBALOV O.V., AVETIKOV D.S.,  
IVANYTS'KA O.S., IVANYTS'KYI I.O.  
HAVRYL'IEV V.M.**

**CLINICAL PRACTICE ON  
SURGICAL STOMATOLOGY**

**Manual for foreign students of stomatological faculties of higher  
medical educational establishments**

**Poltava  
2015**

**UDC 616.314 – 089:378.14**

**LBK 56.6**

**R93**

Recommended by Ministry of Public Health of Ukraine as a manual for English-speaking students of dental faculties at higher educational establishments of Ministry of Public Health of Ukraine (protocol No.2 as of 16.06.2015 of the meeting of the Committee on the organizing the preparation of educational and teaching literature for persons enrolled at higher medical (pharmaceutical) educational establishments and institutions of postgraduate education of Ministry of Public Health of Ukraine)

**Authors:**

**Rybalov O.V.** – doctor of medical science, professor of the Department of Surgical Stomatology and Maxillofacial Surgery with Plastic and Reconstructive Surgery of Head and Neck, Higher state educational establishment of Ukraine «Ukrainian medical stomatological academy»

**Avetikov D.S.** – doctor of medical science, professor, head of the Department of Surgical Stomatology and Maxillofacial Surgery with Plastic and Reconstructive Surgery of Head and Neck, Higher state educational establishment of Ukraine «Ukrainian medical stomatological academy»

**Ivanyts'ka O.S.** – candidate of medical science, assistant of the Department of Surgical Stomatology and Maxillofacial Surgery with Plastic and Reconstructive Surgery of Head and Neck, Higher state educational establishment of Ukraine «Ukrainian medical stomatological academy»

**Ivanyts'kyi I.O.** – candidate of medical science, assistant of the Department of Therapeutic Stomatology, Higher state educational establishment of Ukraine «Ukrainian medical stomatological academy»

**Havryl'iev V.M.** – candidate of medical science, assistant of the Department of Surgical Stomatology and Maxillofacial Surgery with Plastic and Reconstructive Surgery of Head and Neck, Higher state educational establishment of Ukraine «Ukrainian medical stomatological academy»

**Reviewers:**

**Hryhorov S.M.** – doctor of medical science, head of the Department of Surgical Stomatology and Maxillofacial Surgery of Kharkiv National Medical University

**Nahirnyi Ya. P.** – doctor of medical science, head of the Department of Surgical Stomatology of State higher educational establishment «Ternopil State Medical University named after I. Gorbachevsky of Ministry of Public Health of Ukraine»

**Clinical practice on surgical stomatology = Виробнича лікарська практика з хірургічної стоматології:** manual for foreign students of stomatological faculties of higher medical educational establishments of the IVth accreditation level / O.V. Rybalov, D.S. Avetikov, O.S. Ivanyts'ka, I.O. Ivanyts'kyi, Havryl'iev V.M.– Poltava, 2015. – 110 p.

### **ISBN**

The proposed manual is aimed to improve the process of medical practice for students taught in English. Materials represented in the manual help to consolidate the theoretical knowledge and skills of practical activity of dental surgeon. In the manual students can find the descriptions of the most common stomatological diseases according to requirements of keeping the diary of practical training. The manual's appendices, in particular, the examples of prescriptions for drugs commonly used in surgical dentistry, are also practically significant for students.

**Міністерство охорони здоров'я України  
Центральний методичний кабінет з вищої медичної освіти  
Вищий державний навчальний заклад України «Українська  
медична стоматологічна академія»**

**РИБАЛОВ О.В., АВЕТИКОВ Д.С.,  
ІВАНИЦЬКА О.С., ІВАНИЦЬКИЙ І.О.  
ГАВРИЛЬЄВ В.М.**

**ВИРОБНИЧА ЛІКАРСЬКА ПРАКТИКА  
З ХІРУРГІЧНОЇ СТОМАТОЛОГІЇ**

**Навчальний посібник для студентів стоматологічних  
факультетів вищих медичних закладів освіти**

**Полтава  
2015**

**УДК 616.314 – 089:378.14**

**ББК 56.6**

**Р93**

Рекомендовано Міністерством охорони здоров'я як навчальний посібник для англомовних студентів стоматологічних факультетів вищих навчальних закладів МОЗ України (протокол засідання Комісії для організації підготовки навчальної та навчально-методичної літератури для осіб, які навчаються у вищих медичних (фармацевтичному) навчальних закладах та закладах післядипломної освіти МОЗ України, від 16.06.2015 №2)

**Автори:**

**Рибалов О.В.** – доктор медичних наук, професор кафедри хірургічної стоматології та щелепно-лицевої хірургії з пластичною та реконструктивною хірургією голови та шиї ВДНЗ України «Українська медична стоматологічна академія»

**Аветіков Д.С.** – доктор медичних наук, завідувач кафедри хірургічної стоматології та щелепно-лицевої хірургії з пластичною та реконструктивною хірургією голови та шиї ВДНЗ України «Українська медична стоматологічна академія»

**Іваницька О.С.** – кандидат медичних наук, асистент кафедри хірургічної стоматології та щелепно-лицевої хірургії з пластичною та реконструктивною хірургією голови та шиї ВДНЗ України «Українська медична стоматологічна академія»

**Іваницький І.О.** – кандидат медичних наук, асистент кафедри терапевтичної стоматології ВДНЗ України «Українська медична стоматологічна академія»

**Гаврильєв В.М.** – кандидат медичних наук, асистент кафедри хірургічної стоматології та щелепно-лицевої хірургії з пластичною та реконструктивною хірургією голови та шиї ВДНЗ України «Українська медична стоматологічна академія»

**Рецензенти:**

**Григоров С.М.** – доктор медичних наук, професор, завідувач кафедри хірургічної стоматології та щелепно-лицевої хірургії Харківського Національного медичного університету

**Нагірний Я.П.** – доктор медичних наук, професор, завідувач кафедри хірургічної стоматології ДВНЗ «Тернопільський державний медичний університет імені І.Я. Горбачевського МОЗ України»

**Виробнича лікарська практика з хірургічної стоматології = Clinical practice on surgical stomatology:** навчальний посібник для іноземних студентів стоматологічних факультетів вищих медичних навчальних закладів IV рівня акредитації / О.В. Рибалов, Д.С. Аветіков, О.С. Іваницька, І.О. Іваницький, В.М. Гаврильєв – Полтава. – 2015. – 110 с.

### **ISBN**

Даний навчальний посібник дозволяє оптимізувати процес організації виробничої лікарської практики з хірургічної стоматології студентів, викладання яким здійснюється англійською мовою. Матеріали, що містяться у ньому, спрямовані на закріплення отриманих теоретичних знань та навичок практичної діяльності хірурга-стоматолога. У посібнику студенти також знайдуть зразки опису найбільш розповсюджених стоматологічних захворювань відповідно до вимог ведення медичної документації та рекомендації щодо оформлення щоденника виробничої практики. Практичне значення для студентів-практикантів будуть мати і додаткові матеріали посібника, зокрема, приклади оформлення рецептів лікарських препаратів, що найчастіше використовуються у хірургічній стоматології.

## PREFACE

Dear students!

We would like to bring to your attention the manual «Clinical Practice on Surgical Stomatology». Its authors believe that it will really help you in consolidating the theoretical knowledge, as well as in formation of practical skills. It will render your work during clinical practice in surgical dentistry more organized and productive. We hope that the use of this manual will help you to achieve success in your future medical practice.

The collective of authors is particularly grateful to O.M. Vazhnycha, Doctor of Medical Science, Professor of the Department of Experimental and Clinical Pharmacology of Higher state educational establishment of Ukraine «Ukrainian Medical Stomatological Academy» for assistance in preparing background material relating to medications, most frequently used in dentist's practice and L.E. Vesnina, Doctor of Medical Science, Professor of the Department of Normal Physiology of Higher state educational establishment of Ukraine «Ukrainian Medical Stomatological Academy» for the material, containing indices of body's life activity in health.

The authors are also sincerely grateful to reviewers: Doctor of Medical Science, Head of the Department of Surgical Stomatology and Maxillofacial Surgery of Kharkiv National Medical University S.M. Hryhorov and Doctor of Medical Science, Head of the Department of Surgical Stomatology of State Higher Educational Establishment «Ternopil State Medical University named after I. Gorbachevsky of Ministry of Public Health of Ukraine» Ya. P. Nahirnyi for skilled and professional analysis, comments and suggestions which significantly improved the content of the manual.

## CONTENTS

INTRODUCTION	10
KNOWLEDGE AND PRACTICAL SKILLS, WHICH STUDENTS MUST MASTER DURING THE PRACTICAL TRAINING IN SURGICAL DENTISTRY	11
REQUIREMENTS TO THE DIARY OF PRACTICAL TRAINING	14
ORGANISATION OF PRACTICAL TRAINING DEFENCE	16
ESTIMATION CRITERIA OF DOCTOR'S PRACTICE	17
ALGORITHM FOR EXAMINATION OF PATIENT WITH PATHOLOGY OF MAXILLOFACIAL AREA	18
DIAGNOSTIC ALGORITHM FOR THE MOST COMMON DISEASES IN THE OUTPATIENT PRACTICE OF THE DENTAL SURGEON	24
PRINCIPLES OF SURGERY	31
ALGORITHM FOR LOCAL ANESTHESIA DURING SURGERY IN MAXILLOFACIAL AREA	36
ALGORITHM FOR SOME MINOR ORAL SURGICAL PROCEDURES	49
Appendix 1. List of knowledge and practical skills that students should master during practical training in surgical dentistry	76
Appendix 2.FDI two-digit tooth identification chart	77
Appendix 3. Some features of local anesthetic drugs	78
Appendix 4. Main instruments necessary for simple teeth extraction	79
Appendix 5. Table of local anesthetic techniques and instruments for maxillary teeth simple extraction	87
Appendix 6. Table of local anesthetic techniques and instruments for mandibular teeth simple extraction	91



Appendix 7. Types of sutures	94
Appendix 8. Suturing of wound	95
Appendix 9. Blood constants	97
Appendix 10. Prescription of the drugs more often used in the maxillofacial surgery	98
Appendix 11. Pharmacotherapy of urgent states	107
REFERENCES	110

## **INTRODUCTION**

### **The purposes of practical training in surgical stomatology are:**

- 1) to consolidate the knowledge and skills obtained by the students within the course «Surgical dentistry»;
- 2) mastering by students the main methods of diagnostics and treatment used in modern practical health service;
- 3) knowing the rules of sterilization of instruments and materials;
- 4) familiarization with internal schedule of dental services, procedures for admission of patients at polyclinic and at home;
- 5) formation of skills for working with medical documents;
- 6) formation of professional skills to make independent medical decisions;
- 7) training needs in regular improving of knowledge and its application in practical activities;
- 8) implementation of the basic principles of ethics and such requirements of professional deontology as:
  - sensitive and attentive attitude to the patient and his/her relatives;
  - the principle of patient's informed consent to the intervention;
  - maintaining correct relationships with medical staff;
  - confidentiality preservation.

**KNOWLEDGE AND PRACTICAL SKILLS  
WHICH STUDENTS MUST MASTER DURING THE  
PRACTICAL TRAINING IN SURGICAL STOMATOLOGY**

1. To conduct examination of patient and to make a record in the medical card of dental patient on its basis.
2. To pick up a set of tools for examination of surgical dental patient.
3. To implement hygienic and surgical preparation of hands, to know the measures of infection prevention at dental surgeon's work.
5. To conduct examination of salivary glands, lymph nodes of maxillofacial area and neck.
6. To make a preliminary and clinical diagnosis based on examination of patient.
7. To know the scheme of dental patient's card and to be able to report about the patient.
8. To justify a diagnosis and treatment plan of the patient.
9. To justify and perform all kinds of local anesthesia in maxillofacial area.
10. To provide emergency and early management of general and local complications of local anesthesia.
11. To pick up a set of instruments necessary for simple extraction of incisors in the upper jaw.
12. To pick up a set of instruments necessary for simple extraction of canines in the upper jaw.
13. To pick up a set of instruments necessary for simple extraction of premolars in the upper jaw.
14. To pick up a set of instruments necessary for simple extraction of molars in the upper jaw.
15. To pick up a set of instruments necessary for simple extraction of incisors in the lower jaw.
16. To pick up a set of instruments necessary for simple extraction of canine in the lower jaw.
17. To pick up a set of instruments necessary for simple extraction of premolars in the lower jaw.
18. To pick up a set of instruments necessary for simple extraction of molars in the lower jaw.
19. To pick up a set of instruments necessary for surgical extraction of impacted teeth in upper and lower jaws.
20. To pick up a set of instruments for operculotomy at pericoronitis.
21. To pick up a set of instruments for operculectomy at pericoronitis.
22. To pick up a set of instruments for root apex resection.
23. To carry out the operation of tooth or root extraction.
24. To diagnose and treat alveolitis (infected socket).

25. To pick up a set of instruments and local hemostatic drugs to stop of the alveolar bleeding.
26. To diagnose and treat soft tissue hematoma and contracture of the jaws.
27. To diagnose and treat acute perforation of the maxillary sinus.
28. To pick up a set of instruments necessary for the operation of sequestrectomy.
29. To pick up a set of instruments necessary for sinusotomy.
30. To pick up a set of tools necessary for incision and drainage of abscesses.
31. To pick up a set of tools necessary for incision and drainage of furuncles and carbuncles of maxillofacial area.
32. To determine the local and general complications of inflammatory diseases of maxillofacial area.
33. To know basic principles of management of soft tissue injuries.
34. To prepare a set of instruments for the operation of primary and secondary surgical management of wounds of maxillofacial area.
35. To manufacture and apply standard and individual bandaging for injures of maxillofacial area.
36. To know general approach and goals of therapy of facial skeleton fractures.
37. To perform dental wiring for immobilization of fractures of jaws.
38. To make and fixate individual arch bars at fractures of jaws.
39. To know the stages of osteosynthesis operation (rigid fixation of bones).
40. To know stages of reduction of zygomatic bone fragments.
41. To know stages of reduction of nasal bones.
42. To implement temporary bleeding control from wounds of maxillofacial area.
43. To implement permanent bleeding control from wounds of maxillofacial area.
48. To provide emergency and medical assistance during asphyxia.
49. To provide medical aid for fainting, collapse and shock.
50. To provide medical care at angioedema, anaphylactic shock.
51. To provide artificial mouth to mouth respiration and external cardiac massage.
52. To detect complex trauma of maxillofacial area and to plan examination and treatment of patient.
53. To provide medical care at thermal, chemical, physical and combined injuries of maxillofacial area.
54. To prescribe dietary pattern to maxillofacial patients and wounded patients.

55. To carry out medical care for maxillofacial patients and wounded patients.

56. To probe main excretory ducts of major salivary glands and administer drugs.

57. Read X-ray images at:

a) periodontitis;

b) osteomyelitis of facial bones;

c) sinusitis;

d) traumatic dental injury;

d) dislocation of temporomandibular joint;

e) damage of facial bones (jaw, zygomatic bone, nasal bone);

g) diseases of salivary glands.

## REQUIREMENTS TO THE DIARY OF PRACTICAL TRAINING

The diary of practical training is the basic accounting, reporting, training and legal document of the student at the time of undergoing the practical training. The main requirements to the diary of practical training are competent and accurate record keeping, strict adherence to the examination and treatment of the patient. Reductions in the description of the local status and diagnosis of the patient are not allowed. Head of Practice signs the diary of practical training on a daily basis.

### The form of diary's accounting entries

№, Date	Surname, name. Age	Number of visits	Complaints and short anamnesis	Objective examination data. Dental formula	Diagnosis	Performed treatment	Signature of headman
1	2	3	4	5	6	7	8

**Column 1 (Column «№, Date»)** indicates the number of diary's entries (numbered sequentially), as well as the date of admission of the patient.

**In Column 2 (Column «Surname, name. Age»)** a student records passport data of patients.

**In Column 3 (Column «Number of visits»)** a student indicates the serial number of visits: I – initial treatment of the patient in the current year; II – patient's revisiting.

**In Column 4 (Column «Complaints and short anamnesis»)** a student describes the main complaints of the patient at the time of addressing medical care, such as pain (intensity, character and localization, dynamics, irradiation, etc.), dysfunction of maxillofacial area organs, somatic disorders and other; short data history of the disease and life.

**Column 5 (Column «Objective examination data. Dental formula»)** contains the dental status on the standard scheme:

- Inspection of integument of the face and neck, determination of symmetry of the face and neck, skin color and red border, possible pathological changes in tissues of the maxillofacial area;
- Palpation of the bones and soft tissues of the face and neck, place of the trigeminal nerve branch on the surface of the face, detection of edema, infiltration, integrity, pathological mobility, crepitation and pain in bones of the face;
- Determination of the degree of mouth opening, the function of the temporomandibular joint;
- Inspection of the oral vestibule and oral cavity, dentition, tongue, sublingual area, palate, palatine arches, tonsils, large excretory ducts of the salivary glands;

- Inspection, sensing and percussion of teeth, determination of their mobility, the depth of periodontal pockets, determination of the material and the quality of existing fillings and dentures;
- Palpation of the mucous membrane in the projection of root tip;
- Determination of the function of salivary glands;
- The nature of occlusion.

**Making of dental formula is optional.**

Designation of teeth is possible under two basic systems:

**A. The angular system** (for each in the form of a cross, shortened to create angles quadrants with the corresponding numbers of teeth in permanent or milk occlusion):

8 7 6 5 4 3 2 1	1 2 3 4 5 6 7 8
8 7 6 5 4 3 2 1	1 2 3 4 5 6 7 8
V IV III II I	I II III IV V
V IV III II I	I II III IV V

**B. The system FDI-ISO** (developed by Concordance Dental Federation, 1970), which uses two digits: the first – represents the quadrant in the permanent (1, 2, 3, 4) or milk occlusion (5, 6, 7, 8), and the second – the location of the tooth:

18 17 16 15 14 13 12 11	21 22 23 24 25 26 27 28
48 47 46 45 44 43 42 41	31 32 33 34 35 36 37 38
55 54 53 52 51	61 62 63 64 65
85 84 83 82 81	71 72 73 74 75

**Column 6 (Column «Diagnosis»)** contains the patient’s diagnosis in English and Latin. The diagnosis should flow logically from the complaints, anamnesis and physical examination. When observing the patient in dynamics, it displays the current status of the patient.

**In Column 7 (column «Performed treatment»)** a student indicates the type of anesthesia, propyl, and the amount of drug for pain relief, stages of intervention, complications arising during treatment and corrective measures, patient’s appointment.

All data are represented in concrete terms, consistently and in accordance with «Protocols of providing stomatological help»: Order of MPH of Ukraine №566 as of November, 23, 2004 «On the approval of Protocols of medical care providing on specialties «prosthetic stomatology», «therapeutic stomatology», «surgical stomatology», «orthodontics», «pediatric therapeutic stomatology», «pediatric surgical stomatology».

## **ORGANISATION OF PRACTICAL TRAINING DEFENCE**

On the last day of clinical practice, student fills in the consolidated balance sheet of the performed practical work and provides the diary of practical training.

Head of Practice provides the performance record of a student, which reflects the level of theoretical training, initial and acquired practical skills of the student's level, the student's attitude to work, the nature of his/her relationship with patients and hospital staff. During the review of the diary of practical training, the Head of Practice evaluates the correctness of records, timeliness and accuracy of diary's registration with signatures, the student's attitude to mastering practical skills.

During the defence, a student submits the diary of practical training and answers a number of professional questions.



## **ESTIMATION CRITERIA OF DOCTOR'S PRACTICE**

«Excellent». A student has completed the program of doctor's practice to the full extent; he/she gives theoretical ground to the conducted practical manipulations; actively participated in sanitary-educational work; a student is disciplined; the diary of practical training was kept regularly; a student took part in the production and public measures of medical establishment.

«Good». A student accepted the required number of patients; makes admissible errors on the theoretical ground of the conducted practical manipulations; a student is disciplined; the diary of practical training was kept regularly; a student did not participate actively enough in sanitary and educational work, public measures of medical establishment.

«Satisfactory». A student did not complete the program of doctor's practice with the number of the accepted patients, did not apply the methods of treatment recommended by the program; makes errors on the ground of the conducted practical manipulations; demonstrated misconduct in terms of discipline and norms of deontology; the diary of practical training was kept irregularly; a student avoided sanitary and educational work, public and production measures of medical establishment.

«Unsatisfactory». A student failed to complete the program of medical practice on diseases and methods of treatment; cannot give the theoretical ground for practical actions; demonstrated gross misconduct in terms of discipline and norms of deontology; the diary of practical training was kept irregularly; a student was not engaged in sanitary and educational work.

## **ALGORITHM FOR EXAMINATION OF PATIENT WITH PATHOLOGY OF MAXILLOFACIAL AREA**

It is difficult to overstate the importance of a good history and thorough clinical examination for every patient. On this the diagnosis is made and the treatment plan based. A full, clearly written record of the original consultation is essential to assess progress following treatment. Particularly is this true if a colleague should be called to see the patient in the practitioner's absence. The medico legal importance of accurate records cannot be overemphasised.

In hospital and specialist practice this procedure can seldom be relaxed, but the student and the busy practitioner may find it irksome to maintain a high standard when faced with a series of apparently straightforward dental conditions. Nevertheless, sufficient time must be allowed for an unhurried consultation at the first visit. This will help to avoid errors of omission, and may contribute much to the success of treatment and to the interest of the practitioner. With experience, only important facts need be noted, the dental surgeon considering and setting aside the irrelevant points. This technique can be used with safety only after a long apprenticeship during which many histories and examinations have been methodically completed and all the information recorded. In this chapter a system for interviewing and examining patients, and recording findings, is briefly suggested.

At the first meeting it is important for the clinician to establish a relationship with the patient and to assess his attitude to the clinical situation. He is seated comfortably and addressed by his name and correct title. The general details of age, sex, marital status, occupation and address together with the names of his general medical and dental practitioner are entered in the notes. At this stage it should be possible to determine whether the patient is anxious or relaxed. The history is then recorded under the headings shown in italics.

The patient will seldom tell his story well. Some will be verbose, others reticent, while the sequence is usually in inverse chronological order with the most recent events first. The art of the good history lies in avoiding leading questions, in eliciting all the essentials, in censoring verbosity and in arranging the facts in their true order, so that the written record is short and logical. Allowing the patient initially to give the history and subsequently writing notes in chronological order whilst rechecking the facts verbally, helps the clinician obtain a concise and accurate account of the patient's symptoms.

### **Biographic Data**

These include the patient's full name, address, age, gender, occupation, and marital status. The clinician uses this information, along with an impression of the patient's intelligence and personality, to assess the patient's reliability.

### **Chief Complaints**

The patient's chief complaint told in his own words. Opinions, professional and otherwise, repeated in an effort to help must be gently set aside

and the patient encouraged to describe the symptoms he wants cured, and not his views on the diagnosis.

### **History of present complaint**

This is an account in chronological order of the disease. When and how it first started, the suspected cause, any exciting factors, and the character of the local lesion such as pain, swelling and discharge. This includes remissions and the effects of any treatment received. General symptoms such as fever, malaise and nausea are also noted.

### **Previous dental history**

This records how regularly the patient attends for dental care and the importance he attaches to his teeth. Any past experience of oral surgery is included especially where difficulty occurred in the administration of anesthetics, the extraction of teeth and the control of bleeding.

### **Medical history**

A summary in chronological order of the patient's past illnesses. Details of prolonged illness, or those requiring hospital admission or current medication are recorded. The surgeon should exert his critical faculty and write down only those conditions that may affect the diagnosis or treatment.

Most important questions pertaining to general condition of patient s health are:

1. Have you had any health problems during the last 5 years, so that you had to visit a physician or a hospital?
2. Have you taken any medication for whatever reason during the last 2 years?
3. Are you allergic to any substance or medication (e.g., antibiotics, local anesthetics, aspirin, etc.)?
4. Have you taken any antibiotics during the last month?
5. Did you ever have any prolonged bleeding that needed special treatment?
6. Have you ever received radiotherapy in the neck or facial region for therapeutic purposes?
7. Did you ever have, or do you have, a problem related to the following diseases or conditions?
  - Congestive heart failure
  - Prosthetic heart valve
  - Angina pectoris
  - Surgically corrected cardiac disease
  - Myocardial infarction
  - Heart pacemaker
  - Rheumatic fever
  - Hypertension
  - Heart murmur
  - Orthostatic hypotension

- Congenital heart disease
- Cerebrovascular accident
- Cardiac arrhythmia

8. Have you ever been troubled by any other health problems other than the above?

### **The family history**

Occasionally this is of importance in oral surgery. Hereditary diseases such as hemophilia and partial anodontia may be relevant in management of the patient.

### **The social history**

This includes a brief comment on the patient's occupation and social habits such as exercise, smoking and drinking. The home circumstances are important when surgery is to be performed - that is, whether the patient has far to travel, lives alone or has someone to look after him. These factors may influence the decision to treat him as an in- or out-patient.

### **Principles of examination**

Superficially the dental surgeon's examination may seem very different from that of his medical colleagues, yet the basic principles are the same. It should be made according to a definite system which in time becomes a ritual. In this way errors of omission are avoided.

From the moment the patient enters the surgery he should be carefully observed for signs of physical or of psychological disease which may show in the gait, the carriage, the general manner, or the relationship between parent and child. Too little time is often spent on visual inspection, both intra- and extra orally. Eyes first, then hands, should be the rule, not both together.

In palpation all movements are purposeful and logical, and the touch firm but gentle. The tips of the fingers are used first to locate anatomical landmarks and then to determine the characteristics of the pathological condition. The patient's co-operation is sought so that areas of tenderness may be recognized and the minimum discomfort caused.

Wherever possible the normal side is examined simultaneously. Only by such comparison can minor degrees of asymmetry be detected. Swellings situated in the floor of the mouth or in the cheek are felt bimanually with one hand placed in, and one outside, the mouth. Both positive and negative findings are written down as later one may wish to check that at the first visit no abnormality was found in certain structures.

### **Extraoral examination**

This commences with a general inspection, and palpation of the face including the mandible, maxillary and zygomatic bones, noting the presence of any abnormality such as asymmetry or paralysis of the facial muscles. The eyes, their movements and pupil reactions, are observed together with any difficulty in breathing.

### **The temporomandibular joints**

With the surgeon standing behind the patient, the site of the condyles are identified by palpation whilst the patient opens and closes their mouth. The joints are examined for tenderness and clicking or crepitus on opening and closing. The range of opening and left and right lateral excursion are checked and abnormalities noted. The muscles of mastication are palpated for tenderness.

### **The maxillary sinuses**

In disease these may give rise to swellings, to redness and tenderness over the cheek and canine fossa, to nasal discharge, and to fistulae into the mouth, often through a tooth socket.

### **The lymph nodes**

The operator stands behind the patient, who flexes his head forward to relax his neck muscles. Enlarged submental and submandibular nodes can be felt with the finger tips by placing these below the lower border of the mandible and rolling the nodes outwards. The upper deep cervical group can be found by identifying the anterior border of the sternomastoid muscles and rolling the skin and subcutaneous tissues between fingers and thumb. With practice tenderness, consistency and degrees of mobility will be recognized.

### **The lips**

These are inspected for lesions such as assuring at the angles of the mouth, or ulceration.

### **Intraoral examination**

#### **The mucous membranes**

The cheeks, lips, palate and floor of the mouth are examined for color, texture and presence of swelling or ulceration. Comparison of both sides by palpation is essential to discover any abnormality.

#### **The tongue**

Movements, both intrinsic and extrinsic, are tested, as limitation is an important clinical sign in inflammation and early neoplasia. The dorsum is best seen by protruding the tongue over a dental napkin with which it can be grasped, drawn forward and, with the aid of a mouth mirror, examined over its length for fissures, ulcers, etc.

#### **The tonsils**

These are seen by depressing the tongue with a spatula and asking the patient to say 'Ah'. A second spatula compresses the anterior pillar of the fauces to evert the tonsil from its bed. Further pressure will expose and open the crypts.

#### **The pharynx**

Again the tongue is depressed, the patient asked to say 'Ah'. In a good light a small warm mirror is passed over the dorsum of the tongue, past the uvula, and rotated to show the naso- and oro-pharynx.

#### **The salivary glands**

The clinician should record the presence of pain, swelling, altered salivary flow and a bad taste. The periodicity and duration of the swelling is often of great

assistance in making a diagnosis. A subjective view of either an increase or decrease in salivary flow is made. However, this is difficult to confirm except by physiological methods of measurement which are not always easy to perform.

Probing the ducts can be carried out with care to dilate strictures. A stepwise increase in the size of the probes is used. Salivary flow rates can be recorded for the submandibular and parotid glands following initial milking of the ducts and glands.

### **The parodontal tissues**

The color and texture of the gingivae are noted, and the standard of oral hygiene classified including charting the presence of plaque and calculus. Recession, pocketing, and hyperplasia of the gums is measured, and the mobility of the teeth assessed.

### **The teeth**

These are charted for caries and fillings with a mirror and probe. Loose teeth, crowns, or fillings are noted as these may have to be removed before anesthesia is administered.

### **Edentulous ridges**

These are examined for the form of the ridge, retained roots and soft tissue or bony abnormalities. Dentures worn should be inspected in situ.

### **The occlusion**

This is best analyzed by taking study models and mounting them on an anatomical articulator. However, the occlusal function of natural teeth, bridges and dentures should be assessed at the same time as the teeth are charted.

### **Special lesion**

This is the examination of the lesion for which the patient has sought treatment. It may have been included in the general examination mentioned above, but frequently there is a swelling, ulcer, fistula or other disease which requires special attention, the details of which are best recorded under one heading easily referred to throughout treatment.

It is important in examining such pathological entities to determine their site, size, shape, color, the character of their margins and whether they are single or multiple. Tenderness, discharge and lymphatic involvement are also important. Swellings should be palpated to determine whether they are mobile or fixed to the skin or to the underlying tissues. They may be either fluctuant or solid. Solid swellings may be very hard (like bone) or firm (like contracted muscle), soft (like relaxed muscle) or very soft (like fat). Where a collection of fluid is suspected fluctuation is elicited by placing two fingers of one hand on each side of the swelling and pressing centrally with a finger of the other hand. Where the lesion is fluid a thrill will be felt. This must be elicited in two directions at right angles as muscle fluctuates in the longitudinal but not the transverse plane. All pulsatile swellings must be checked to establish whether the pulsation is true or transmitted from an underlying artery.

### **Special investigation**

The history taken, and the examination of the patient having been completed, the surgeon then considers his findings and makes a differential or provisional diagnosis. In this he wishes to establish the disease process and relate it to the tissue involved. It is a useful exercise for the inexperienced to consider in turn the chief pathological categories rejecting those that do not fit the facts ascertained. The tissues in the area may then be reviewed and an attempt made to identify those from which the lesion could arise. In this way a sensible argument may be sustained to support one or more possible or differential diagnoses. To differentiate between these or to confirm a clinical finding special investigations may be necessary. These are not indicated for every patient; indeed, their cost and the delay involved in completing them make it necessary to limit their use. Such investigations are an aid to diagnosis and may also be required for treatment planning.

### **Diagnosis**

When the special investigations have been completed the surgeon should be able to make a final diagnosis and it is important that this be clearly stated in the notes. Diagnosis is not a matter of intuition but is a ‘computer’ exercise in which all the information is sorted and analyzed in the surgeon’s mind. Sometimes it is impossible to reach a decision because of lack of information or knowledge, in which case the surgeon will need to consult textbooks or papers and will be wise to seek the opinion of a colleague.

### **Treatment planning**

Only when the diagnosis is established can a satisfactory treatment plan be made. This should be divided into pre-operative, operative and post-operative care, each of which should be planned in a logical sequence, constantly bearing in mind that the ultimate aim is to cure the patient with the least risk and minimal inconvenience to him.

Patients with underlying diseases should be given particular attention and all necessary preventive measures should be taken, in cooperation with the physician treating the patients, in order to avoid potential complications during and after the surgical procedure. This chapter refers to diseases and conditions that are included in the aforementioned medical history and which may cause problems at the dental office. The preventive measures that must be taken before and after the surgical procedure are also emphasized.

## **DIAGNOSTIC ALGORITHM FOR THE MOST COMMON DISEASES IN THE OUTPATIENT PRACTICE OF THE DENTAL SURGEON**

### **1. ACUTE PERIODONTITIS (SEROUS, PURULENT)**

The patient **complains** of permanent pain of varying intensity in the causal tooth (in upper or lower jaw, to the right or to the left) which increases while eating or biting, feeling of the «growing» tooth. Pain is going along the branches of trigeminal nerve (nose, ears etc.). Patient notices a gum swelling in the area of disturbing tooth, headache, sometimes – rise of temperature.

**Anamnesis morbi (case history):** Pain that appears at first, disturbs one day (for serous process) or several days (for purulent process). Some patients notice that the tooth has been repeatedly filled. The exacerbation of the process after endodontic treatment is possible.

**Physical examination:** the face of the patient is usually symmetric. Ordinary skin color, normal opening of mouth, regional lymphatic nodes are not enlarged at serous process or may be enlarged slightly, moderately painful, not soldered to the surrounding tissues at purulent process. «Casual» tooth's crown is intact or destroyed or tooth is filled, its color could be changed. Tooth probing is painless. Vertical and horizontal percussion is painful. Mucous membrane in the area of the «causal» tooth is swollen, hyperemic, and painful at palpation.

**The X-ray image** of the jaw's alveolar process shows even extension of the periodontal fissure in the periapical area without clear borders.

### **2. CHRONIC PERIODONTITIS (FIBROUS)**

The patient **complains** of destroyed tooth (in upper or lower jaw, to the right or to the left), unpleasant smell from mouth, inconvenience while eating.

**Anamnesis morbi (case history):** the tooth has been repeatedly treated for recent years, gradually destroyed. According to the medical evidence, dental therapist prescribed tooth extraction.

**Physical examination:** symmetric face, normal skin color, turgor is preserved, free opening of mouth, regional lymphatic nodes are not enlarged. «Casual» tooth's crown is destroyed (by 1/2, 2/3, totally) or tooth is filled, its color is changed. Probing of caries and tooth cavity, as well as tooth percussion, is painless or feebly painful (dull percussion sound is possible). Mucous membrane in the area of casual tooth is light pink, humid.

**The X-ray image** of the jaw's alveolar process shows even extension of the periodontal fissure in the periapical area.

### **3. CHRONIC PERIODONTITIS (GRANULATING)**

The patient **complains** of periodic pain in the destroyed or filled tooth (in upper or lower jaw, to the right or to the left) while eating, unpleasant smell



from mouth, suppurative fistula in the mucous membrane in the tooth root's projection.

**Anamnesis morbi (case history):** the tooth has been repeatedly treated for recent years, gradually destroyed. Patient notices periodic exacerbation with formation of the swelling on the gum and its burst brings relief. Due to ineffective treatment the patient was sent to the tooth extraction or mouth sanative procedures before the prosthetic appliance or surgical intervention.

**Physical examination:** symmetric face, normal skin color, turgor is preserved, free opening of mouth, regional lymphatic nodes are not enlarged. «Casual» tooth's crown is destroyed (by 1/2, 2/3, totally) or tooth is filled, its color is changed. Probing of caries and tooth cavity, as well as tooth percussion, is painless or feebly painful, the dull percussion sound is possible. Mucous membrane in the area of «casual» tooth's area is stagnantly hyperemic, there is suppurative or ichoring fistula (or cicatrized gum) from the vestibular side of the alveolar process in the area of apex of the «casual» tooth root.

**The X-ray image** of the jaw's alveolar process shows that there is a focus of osseous tissue destruction without clear contours resembling the «tongues of flame» located in the «casual» tooth's periapical tissues.

#### 4. CHRONIC PERIODONTITIS (GRANULOMATOSIS)

The patient **complains** of destroyed tooth (in upper or lower jaw, to the right or to the left), uncertain pain in this tooth while eating (sometimes pain is absent), protruding swelling on the mucous membrane in the area of the disturbing tooth.

**Anamnesis morbi (case history):** the tooth was repeatedly treated, gradually destroyed. Due to ineffective treatment, the patient was sent by the dental therapist for surgical treatment of tooth since pathologies were found near the root apex during X-ray examination (granuloma, cystogranuloma, radicular cyst).

**Physical examination:** symmetric face, normal skin color, turgor is preserved, free opening of mouth, regional lymphatic nodes are not enlarged. The «casual» tooth's crown is destroyed (by 1/2, 2/3, totally) or tooth could be filled, its color is changed. Probing of caries cavity and tooth percussion are painless or feebly painful (dull percussion sound). There is a positive symptom of the «tremble» by the root apex. Mucous membrane in the area of «casual» tooth's area is light pink, humid. From the vestibular side of the alveolar process in the area of the «casual» tooth root's projection, there is protruding swelling of the mucous membrane of round form, different proportions, soft-elastic consistency, feebly painful at palpation. The positive symptom of vacillation.

**The X-ray image** of the jaw's alveolar process shows that there is an osseous tissue of rarefying hearth with clear contours in the periapical or interdental partition area. The size of odontogenic granuloma is 0.5 cm in

diameter, cystogranuloma – from 0.5 up to 0.8 cm, cyst – over 1.0 cm in diameter.

## 5. CHRONIC PERIODONTITIS AT EXACERBATION STAGE

The patient **complains** of pulsating pain in the tooth (in upper or lower jaw, to the right or to the left) which increases while eating (especially hot food) or biting, feeling of the «growing» tooth. Pain is going along the branches of trigeminal nerve (nose, ears etc.). Patient notices a gum swelling in the area of disturbing tooth, headache, sometimes – rise of temperature.

**Anamnesis morbi (case history):** Pain that suddenly appears after supercooling (or other provoking causes) troubles the patient for several days. There is local swelling of gum. Some patients noticed periodic exacerbation of the process. The tooth is repeatedly treated. The exacerbation of the process after endodontic treatment is possible.

**Physical examination:** The face of the patient is usually symmetric. Ordinary skin color, normal opening of mouth, regional lymphatic nodes are not enlarged. «Casual» tooth's crown is destroyed (by 1/2, 2/3, totally) or tooth is filled, its color could be changed. Tooth probing is painless. Vertical and horizontal percussion is painful. Mucous membrane in the area of the «causal» tooth is swollen, hyperaemic, and painful at palpation. The local area of infiltration in the «causal» tooth root's projection can be distinguished.

**The X-ray image** of the jaw alveolar process in the area of the «causal» tooth's periapical tissues shows the signs of one of chronic periodontitis forms (mostly granulating).

## 6. ACUTE SUPPURATIVE ALVEOLITIS

The patient **complains of** a constant pulsating pain in the extracted tooth's socket (at the upper or lower jaw, at the left or right side), difficulties and pain while eating. The pain is going to the orbit, temple and ear, increasing while eating hot meal. Also there are general discomfort and rise of temperature up to 37.5°C.

**Anamnesis morbi (case history):** the tooth was extracted several days ago. The tooth extraction was atypical or traumatic. Patient can point out long time bleeding from the extracted tooth socket.

**Physical examination:** The face of the patient is symmetric. The skin is pale. The temperature is 37.0-37.5°C. Regional lymphatic nodes are enlarged and a little painful while being palpated. Opening of mouth is limited. There is edema and hyperemia of the mucous membrane in the extracted tooth's alveolar area. Extracted tooth's alveolus is «dry», filled up with gray stinking thin coating or pus content, disintegrated clot of blood, small bone fragments, tooth's crown or root fragments are found. The palpation of gum at the level of

extracted tooth and examination of alveolus are painful. The percussion of the adjacent teeth is sensitive.

**The X-ray image** of the alveolar process in the extracted tooth area shows that there is an alveolus shadow with unclear contours. The presence of residual root parts, interradicular partition, and tiny bone fragments is possible.

## **7. ACUTE SUPPURATIVE PERIOSTITIS OF JAW'S ALVEOLAR PROCESS IN THE AREA OF «CASUAL» TOOTH AND TWO ADJACENT TEETH**

### **The 1st attendance of the patient.**

The patient **complains** of sharp pulsating pain, intumescence in the area of jaw's alveolar process (upper or lower jaw, to the right or to the left). The pain is going along the branches of trigeminal nerve (nose, ears etc.). There are intumescence of cheek or lip soft tissues, general health state deterioration, rise of temperature (up to 37-38°C).

**Anamnesis morbi (case history):** Pain and intumescence appeared 1-3 days ago. Earlier there was pain in the corresponding area of the jaw. The tooth was repeatedly treated and gradually destroyed. The patient can point out self-treatment (cavity rinsing, analgesic drug, compress).

**Physical examination:** the temperature is about 37-38°C. The face of the patient is asymmetric due to swelling in the area of the medial or lower face zone. Skin is of normal color and can be folded. The soft tissues edema can be determined by palpation, deep palpation causes pain. Opening of mouth is free or limited, but in case if there is damage of third molar of the mandible, opening of mouth is limited and painful due to the edema's spreading to the medial pterygoid muscle. «Casual» tooth's crown is partly (by 1/2, 2/3) or totally destroyed. The percussion of «casual» tooth is feebly painful. There is an intumescence on the jaw's alveolar process (upper or lower jaw, to the right or to the left) in the area of «casual» tooth and two adjacent teeth projection. The mucous membrane over the intumescence is hyperemic and edematic. By palpation, dense (during the serous process) infiltrate (up to 3-5 cm in diameter) with fluctuating parts (during the suppurative process) is observed. Regional lymphatic nodes are enlarged and painful while palpation.

**The X-ray image** of the jaw alveolar process in the area of the «causal» tooth's periapical tissues displays the distinguished signs of the forms of chronic periodontitis (mostly granulating).

### **The 2nd attendance of the patient (the 1st day after periostotomy).**

There are **complaints** of pain in operative wound. The patient points out the reduction of swelling, improvement of general health state, lowering of temperature.

**Physical examination:** the temperature is about 37-38°C. The face asymmetry is reduced. Opening of mouth is full. Regional lymphatic nodes are enlarged and feebly painful while palpation. There is reduction of swelling and

hyperemia, mucous membrane infiltration in operative wound area. The wound is drained, it is full of ichor and pus. There is a clot of blood in the extended tooth alveolus. The percussion of the adjacent teeth is painless.

**The 3rd attendance of the patient (the 3rd day after periostotomy).** There are no **complaints**.

**Physical examination:** The general health state is satisfactory. The temperature is about 36.6°C. The face is symmetric. The skin is of normal color. Opening of mouth is free. Regional lymphatic nodes have been reduced; they are feebly painful while being palpated. Edema and hyperemia of the mucous membrane, as well as periosteum infiltration in the operative wound area, are absent. The wound is granulating and epithelializing along the edges. There is a clot of fibrin in the extracted tooth alveolus.

## **8. CHRONIC PARODONTITIS, GENERALIZED FORM, AVERAGE DEGREE OF SEVERITY, TOOTH MOBILITY OF THE II DEGREE**

There are **complaints of** constant ache in the area of mobile tooth; difficulties while eating, unpleasant smell from mouth.

**Anamnesis morbi (case history):** tooth mobility troubles the patient about a year, gradually increases. The patient can point out previous medical treatment performed by dental therapist.

**Anamnesis vitae (life history):** the chronic diseases of cardiovascular, digestive and respiratory systems are possible. It is obligatory to ascertain the industrial factors, allergic reaction, stress situation.

**Physical examination:** The face of the patient is symmetric. The skin is of normal color. The nasolabial fold and chin fissure are pronounced. Regional lymphatic nodes are not enlarged. Opening of mouth is full. The crown of the disturbing tooth is intact. Tooth root is bared by  $\frac{1}{2}$  ( $\frac{2}{3}$ ,  $\frac{1}{3}$ ). There is tooth mobility of the 2nd degree. There are many soft and solid tooth deposits, pathological pockets filled up with pus. The gum is stagnantly hyperemic, easily bleeding while being touched with instruments.

**The X-ray image** of the alveolar process shows horizontal and (or) vertical resorption of the interdental partitions, the periodontal tooth fissure extensions, osteoporosis.

## **9. THE ACUTE TRAUMATIC FRONTAL BILATERAL MANDIBULAR DISLOCATION**

There are **complaints of** pain in the parotid area, impossibility to close up the teeth, difficulties with speaking and eating, salivation disorders.

**Anamnesis morbi:** the beginning of the disease is connected with the lower face zone trauma or with the attempt to open mouth wide.

**Physical examination:** The face of the patient is asymmetric due to the lengthening of lower part of the face. The skin color is not changed. The

abrasions and subcutaneous hemorrhages are possible. Submandibular lymphatic nodes are not enlarged. The patient cannot close his/her lips up. The bite is open, at the presence of teeth the bite is fixed on the last molars. The palpation shows pathological position of the heads: under the zygomatic arch, before the arthral tubercle of the temporal bone. The palpation of the tissues in the parotid zone is painful. The retraction of soft tissues ahead of tragus is marked. While palpating external acoustic duct, there is no arthral heads motion. The tension of the masseter muscles is marked. At an attempt of removing mandible in the area of temporo-mandibular joint, the pain appears (the positive symptom of loading). There is no mandible disintegrity in the area of ramus, angle, lower edge of the mandibular body. Red border of lips and tongue is dry.

**The extra-oral X-ray image** of the facial bones in lateral projection displays an extension of the contours of temporo-mandibular joint, faulty position of mandibular arthral heads in front of arthral tubercle of temporal bone under the zygomatic arc.

## **10. TRAUMATIC ANGULAR LEFT-SIDED FRACTURE OF THE MANDIBLE WITH DISPLACEMENT OF THE FRAGMENTS**

There are **complaints** of pain in the area of mandible angle to the left, painful swelling of the soft tissues in the parotid-chewing zone, difficulties while closing teeth up and difficulties with speaking and eating, related to this disorder.

**Anamnesis morbi (case history).** The patient connects the beginning of disease with trauma (domestic, industrial or sport). It is obligatory to ascertain the trauma circumstances (exact time, place and how it happened). The patient does not point out the loss of consciousness, sickness, vomiting and memory disorders. After the trauma, there was a short-time bleeding from the mouth cavity.

**Physical examination:** There is a face asymmetry due to the tissue swelling in the lower parts of the left parotid-masticatory area. There are several abrasions on the damaged skin area and visually detectable subcutaneous hemorrhages. There is limited opening of mouth due to pain in the area of the left mandible angle. The pain in that area increases while biting. There is a full volume of the joint heads excursion. The outlets of trigeminal nerve are painless. There is sensory decrement of skin and mucous membrane of the lower lip to the left. While swelling is being palpated, the edematic, sharp painful soft tissues are distinguished within such borders: from above – lower edge of zygomatic arch, from below – submandibular area, at the front – anterior edge of the masticatory muscle, from behind – posterior edge of mandibular ramus.

The continuity of the mandibular lower edge is preserved. There is considerable pain in the area of mandibular left angle. The symptom of loading in the area of mandibular left angle is positive. The palpation of the orbital contours, zygomatic arcs and bones, maxillary-zygomatic sutures, nasal bones, frontal surface of the maxilla is painless.

The red border of the lips is humid. The vestibular mucous membrane of the mouth, cheeks, right pterygoid-mandibular fold, hard and soft palate, alveolar process, sublingual areas is light pink and humid. There is submucous hemorrhage in the lower parts of the left pterygoid-mandibular fold. The mucous membrane is penetrated with medial tubercles from vestibular side of the alveolar process in the area of 38. The occlusion is open and oblique due to the lack of molars contacts to the left. Frenulum of low lip is displaced to the right.

The percussion in the area of 38 is painful and in the area of 37 is sensitive. During the bimanual palpation of mandible, there is a pathological mobility in the area of 38, crepitus of the bone fragments. From the mouth cavity side one can palpate fragment of left ramus, displaced upward.

During the salivary glands massage, the transparent, thick secretion from the excretory ducts is produced in sufficient amount. The massage and palpation of the major salivary glands are painless. The tongue is covered with brown thin coating. Lingual papillae are moderately expressed.

**The X-ray image of mandible** displays the mandibular disintegrity in the angle area. Fracture line runs through periodontal fissure of partly eruption of 38. There is a displacement of small fragment of the mandible upward.

## **PRINCIPLES OF SURGERY**

The main concern of the dentist performing surgical procedures involves fundamental principles of surgery, asepsis and antisepsis, to prevent pathogenic microbes from entering the body as well as spread of certain infectious diseases from one patient to another. Sterilization of instruments, as well as preparation of the patient and dentist are therefore considered necessary.

### **Sterilization of Instruments**

The basic methods used for sterilization of instruments are: dry heat, moist heat (autoclave), chemical means, and sterilization with ethylene oxide. Sterilization of instruments is achieved in steel trays or the instruments are wrapped in drapes, which are placed either directly in the autoclave or in special metal containers, which have holes so that the steam may pass through during sterilization. After sterilization, the holes of the container are sealed, so that whatever it contains remains sterilized until it is used. Wrapped instruments may also be sterilized with ethylene oxide. This method is often used for plastic or metal instruments that are not heat resistant.

Packages containing a full set of instruments necessary for each surgical procedure are considered very practical. The sterilized instruments these packages contain may be sealed and stored for a long period of time. Packages which are opened and from which one or more instruments are removed repeatedly must be resterilized at least once a week. All instruments and materials that are to be used for the surgical procedure are neatly arranged on the tray of the dental engine or surgery tray, after sterile drapes are placed to cover these surfaces.

### **Preparation of Patient**

The skin around the mouth is first disinfected with gauze impregnated with antiseptic solution, and then the mucosa of the oral cavity is disinfected. The patient is then covered with sterile drapes.

### **Preparation of Surgeon**

The preparation of the surgeon is necessary in all surgical procedures and includes the disinfection of hands and appropriate clothing. Before this procedure though, the dentist must have put on shoe covers, a cap covering the hair, and a surgical mask.

The disinfection procedure starts with cleaning the hands with soap. Scrubbing should be restricted to critically contaminated areas. For disinfection alcoholic solutions or alternatively disinfectant soaps are recommended. Depending on the detergent a total time of 3-5 min is recommended. First hands, arms and elbows, then hands and wrists and finally the hands only are disinfected. Care should be taken so that no non-sterile areas above the elbows are touched during this procedure.

After this procedure, the dentist wears the sterile gown, which is tied by the assistant, and then dons the gloves. The first glove is held by the right hand by the cuff and is placed on the left hand, while the second glove is held by its exterior surface by the gloved hand and is placed on the right.

## **Surgical Incisions**

The following fundamental rules apply to every surgical procedure, concerning the incision. The incision must be carried out with a firm, continuous stroke, not interrupted strokes. During the incision, the scalpel should be in constant contact with bone. Repeated strokes at the same place, many times, impair wound healing. Incision should be carried out in such a way that injury of anatomic structures is avoided, such as: the mental neurovascular bundle, palatal vessels emerging from the greater palatine foramen and incisive foramen, infraorbital nerve, lingual nerve, submandibular duct, parotid duct, hypoglossal venous plexus, buccal artery (of concern when incision of an abscess of the pterygo-mandibular space is to be performed), facial nerve and facial artery and vein, which are of concern basically for the drainage of abscesses performed with extraoral incisions.

Vertical releasing incisions should begin approximately at the buccal vestibule and end at the interdental papillae of the gingiva. Envelope incisions and semilunar incisions, which are used in apicoectomies and removal of root tips, must be at least 0.5 cm from the gingival sulcus. The elliptic incision, which is used for the excision of various soft tissue lesions, comprises two convex incisions joined at an acute angle at each end, while the depth of the incision is such that there is no tension when the wound margins are coapted and sutured. The mucosa and periosteum must be reflected together. This is achieved (after a deep incision) when the elevator is continuously kept and pressed firmly against the bone. When the incision is not made along the gingival sulcus, for esthetic reasons, and especially in people with broad smiles, the scar that will result must be taken into consideration, particularly on the labial surface of the front teeth. During the surgical procedure, excessive pulling and crushing or folding of the flap must be avoided, because the blood supply is compromised and healing is delayed.

## **Suturing**

Suturing of the surgical wound is necessary, aiming at holding a flap over the wound, reapproximating the wound edges, protecting underlying tissues from infection or other irritating factors, and preventing postoperative hemorrhage. Suturing may also aid in the following:

- When hemorrhage is present deep in the tissues and ligation is required or for ligation of a large vessel
- In cases of severe hemorrhage where the suture holds the hemostatic plug in place
- For infections, after the incision, for stabilization of the rubber drain at the site of incision
- For immobilization of pedicle flaps in their new position, etc.

Stabilization of sutures is achieved with knots, which may be simple or a surgeon's knot, and are either tied with the fingers of both hands or with the help of the needle holder.

The technique applied for tying knots is as follows: after the needle passes through both wound edges, the suture is pulled, so that the needle-bearing end is



longer. Afterwards, the long end of the suture is wrapped around the handle of the needle holder twice. The short end of the suture (which is usually held by the assistant with anatomic forceps) is grasped by the needle holder and pulled through the loops. The suture is then tightened by way of its two ends, thus creating the first double-wrapped knot, which is called a surgeon's knot. The flap is therefore replaced in the desired position. A single-wrap knot is then created, in the counterclockwise direction, which is named a safety knot. The knot must always be to the side and never on the incision itself. This makes tightening easier, irritates the wound less, and facilitates cutting and removing the suture.

### **Suturing Techniques**

The main sutures used in oral surgery are the interrupted, continuous, and mattress sutures.

**Interrupted Suture.** This is the simplest and most frequently used type, and may be used in all surgical procedures of the mouth. The needle enters 2–3 mm away from the margin of the flap (mobile tissue) and exits at the same distance on the opposite side. The two ends of the suture are then tied in a knot and are cut 0.8 cm above the knot. To avoid tearing the flap, the needle must pass through the wound margins one at a time, and be at least 0.5 cm away from the edges. Over-tightening of the suture must also be avoided (risk of tissue necrosis), as well as overlapping of wound edges when positioning the knot. The advantage of the interrupted suture is that when sutures are placed in a row, inadvertent loosening of one or even losing one will not influence the rest.

**Continuous Suture.** This is usually used for the suturing of wounds that are superficial but long, e.g., for recontouring of the alveolar ridge in the maxilla and mandible.

The technique applied is as follows: after passing the needle through both flap margins, an initial knot is made just as in the interrupted suture but only the free end of the suture is cut off. The needle-bearing suture is then used to create successive continuous sutures at the wound margins. The last suture is not tightened, but the loop created actually serves as the free end of the suture. Afterwards, the needle-bearing suture is wrapped around the needle holder twice, which grasps the curved suture (first loop), pulling it through the second loop. The two ends are tightened, thus creating the surgeon's knot.

The continuous locking suture is a variation of the continuous simple suture. This type of suture is created exactly as described above, except that the needle passes through every loop before passing through the tissues, which secures the suture after tightening. Suturing continues with the creation of such loops, which make up parts of a chain along the incision. These loops are positioned on the buccal side of the wound, after being tightened.

The advantage of the continuous suture is that it is quicker and requires fewer knots, so that the wound margins are not tightened too much, thus avoiding the risk of ischemia of the area. Its only disadvantage is that if the suture is inadvertently cut or loosened, the entire suture becomes loose.

**Mattress Suture.** This is a special type of suture and is described as horizontal (interrupted and continuous) and vertical. It is indicated in cases where strong and secure reapproximation of wound margins is required. The vertical suture may be used for deep incisions, while the horizontal suture is used in cases which require limiting or closure of soft tissues over osseous cavities, e.g., postextraction tooth sockets. Reinforcement of the mattress suture is achieved with insertion of pieces of a rubber drain.

The technique used for the mattress suture is as follows: in the interrupted suture (horizontal and vertical), the needle passes through the wound margins at a right angle, and the needle always enters and exits the tissues on the same side. In the horizontal continuous suture, after creating the initial knot, the needle enters and exits the tissues in a winding maze pattern. The final knot is tied in the same fashion as in the continuous simple suture.

### **Sutures**

Great progress in sutures has been made since 1865, when disinfection and sterilization first started being used in surgery. There is a big variety in the size of surgical sutures available today, and two basic categories: resorbable and nonresorbable sutures.

**Resorbable Sutures.** These sutures are resorbed after a certain time, which usually coincides with healing of the wound. These sutures are made of gut or vital tissue (catgut, collagen, fascia, etc.) and are plain or chromic, or of synthetic material, e.g., polyglycolic acid (Dexon). Plain catgut sutures are resorbed postsurgically over 8 days, chromic sutures in 12– 15 days, and synthetic (Dexon) sutures in approximately 30 days. These types of sutures are used for flaps with little tension, children, mentally handicapped patients, and generally for patients who cannot return to the clinic to have the sutures removed.

**Nonresorbable Sutures.** These sutures remain in the tissues and are not resorbed, but have to be cut and removed about 7 days after their placement. They are fabricated of various natural materials, mainly surgical silk (monofilamentous or multifilamentous, in many diameters and lengths) and surgical cotton suture. Silk sutures are the easiest to use and the most economical, and have a satisfactory ability to hold a knot.

The most commonly used suture sizes are 4–0 and 3–0 for resorbable sutures, and 3–0 and 2–0 for nonresorbable sutures. These kinds of sutures are sold in sterilized packages with pre-attached atraumatic needles or in bundles without needles.

### **Needles**

A variety of needles are available in oral surgery, and they may differ in shape, diameter, cross-sectional view, and size. They are usually made of stainless steel, which is a strong and flexible material. The needles preferred by surgeons today are atraumatic disposable needles with pre-attached sutures on their posterior ends. Needles that may be used and sterilized many times are also available, with an eye or groove in the needle, through which the suture is passed.

**Needles with Round or Oval Cross-Sectional View.** These are considered atraumatic and are mainly used for suturing thin mucosa. Their disadvantage is that great pressure is required when passing through the tissues, which may make suturing the wound harder.

**Triangular Needles.** These needles have sharp cutting edges and are preferred for suturing thicker tissues. When they are used for thin mucosa, care is required because they may tear the tissues. The most suitable needles are semicircular or three-eighths of a circle and 19–20 mm long, in both cases.

## **ALGORITHM FOR LOCAL ANESTHESIA DURING SURGERY IN MAXILLOFACIAL AREA**

Local anesthesia implies an isolated and temporary state of insensibility in a restricted area without loss of consciousness. Local anesthetic can be produced by the action of the local anesthetic agent on either the free nerve endings, the terminal nerve endings in the area of the surgery or the main nerve trunk supplying this region. All techniques of local anesthesia are usually divided into two groups: injection and non-injection (topical) techniques. The injection technique comprises infiltration, conduction anesthesia (nerve block) and squirt-and-cut technique (by A.V. Vishnevsky method). The non-injection group of local anesthesia in stomatology includes chemical and physical techniques.

Achieving good local anesthesia is a prerequisite for virtually all dental surgeries, and in oral surgery the confidence it gives is mandatory from both the patient's and the surgeon's point of view. The ability to administer a comfortable local anesthetic to any patient is a fundamental skill that dental surgeons should strive to achieve. Anesthesia will make it possible to significantly reduce the stress levels in both giver and receiver; therefore, the technique must be constantly reviewed and revised.

Not only is the actual injection of local anesthetic important, the operator must give the drug adequate time to block nerve transmission and must have confidence in his or her ability to recognize the subjective changes it will bring about before testing its adequacy. One of the most common faults is testing the effect of local anesthetic before reasonable time has elapsed, when lack of necessary depth of anesthesia causes discomfort. This immediately results in loss of confidence in the patient, who becomes more apprehensive and may therefore be far more difficult to convince that adequate anesthesia, even after further administration, is finally attained.

Patients must be told before the testing of an anesthetic that all sensation is not, and will not, be lost, and that it is specifically pain that will be eliminated. This is particularly true in oral surgery practice, where the procedure may often involve causing a very real feeling of pressure that can be alarming to patients who have not been fully briefed on what the local anesthetic can and cannot do. If patients are asked to report «feeling anything» during the testing procedure they might truthfully say that they feel something, and this could lead to further, and possibly unnecessary, administration of local anesthetic.

### **INJECTION ANESTHESIA TECHNIQUES**

Injection anesthesia is a technique of anesthesia in which the anesthetic solution is injected into the tissues with the help of a surgical needle.

## **1. LOCAL INFILTRATION TECHNIQUES**

Infiltration anesthesia is achieved when the terminal nerve endings supplying the operative region are flooded by the diffusion of the injected anesthetic solution rendering it incapable of becoming stimulated.

### **1.1. Soft Tissue Infiltration**

In these techniques, the tissues are anesthetized when flooded by local anesthetic solution and nerve endings of surgery site get paralyzed. Infiltration anesthesia is mostly used for blocking odontic nervous plexus in maxillary teeth extraction. This is due to a higher efficacy of infiltration anesthesia in maxillary alveolar ridge as opposed to the mandibular one. The cortical plate of maxillary alveolar ridge in its vestibular and palatal side is rather thin and full of small openings penetrated by blood vessels and nerve trunks. These openings can be seen all along the maxillary ridge. In the lower jaw the cortical plate is thicker and denser with less openings which can mostly be seen at the incisors, canines, and premolars (the latter is quite rare). The anesthetic solution infiltrates into the marrowy strata via periosteum and numerous openings in the external thin compact plate of the upper jaw and blocks the corresponding site of odontic plexus. This is achieved by submucosal or paraperiosteal injections.

This anesthesia for teeth extraction is performed with two injections: from the vestibular and palatal (lingual) sides. Administration should be considered as two-part technique: 1. Needle insertion; 2. Administering local anesthetic. To achieve minimal discomfort, topical local anesthetic should be applied 2-3 min before the injection. The index finger or thumb of the «free» hand should pull the lip or cheek so that the sulcus tissues are taut, as this will minimize discomfort on administering the needle. A needle is jabbed into the mucous membrane at the angle of 45° at the beginning of transitory fold at the level of root apex of the tooth preceding the one to be extracted. The tip of the needle needs to be administered only 3-4 mm into the tissue adjacent to the tooth to be anaesthetized.

After releasing a small quantity of anesthetic solution, the needle should be moved backwards aligning with the bone, horizontally up to the root apex of the tooth located behind the one to be extracted. While moving the needle, basic quantity of anesthetic solution is released, the maximum of which should be injected at the level of apex of the tooth to be extracted. The solution should be administered slowly because the lumen of a dental needle is very fine and undue force of the solution being injected can lead to unwanted pain and tissue damage. This therefore takes time and patience but is essential in reducing discomfort. In order to ensure pain control from the palatal side, the needle is jabbed into the palate mucous membrane up to the bone at the distance of 1 cm to gum margin in parallel to the axis of tooth to be extracted and small quantity of anesthetic solution is injected. In performing subperiosteal injections, the needle meets resistance and no attempt should be made to force the needle further towards the bone.

Along with tooth extraction, surgery the infiltration technique of anesthesia is applicable in the mouth mucous membrane incision. In this case, anesthesia starts with forming a subepithelial struma. A thin needle is jabbed at an acute angle under the mouth mucous membrane epithelium and some anesthetic solution is administered under some pressure. Then the needle is moved under the mucous layer and if necessary, into deeper tissues preceding needle's movements with a stream of anesthetic solution avoiding the abscessed cavity.

### **1.2. Bony Tissue Infiltration**

The effect of intraosseous (spongy) anesthesia is mainly caused due to extravascular distribution of anesthetic agent in periapical tissues and in interalveolar septum tissues. The advantage of this technique is a rapid onset of deep anesthesia and its somewhat prolonged effect.

**Indications:** complications resulting from tooth extraction (dental fractures), surgical (atypical) extraction with prolonged surgery duration or high level of injury threat, pulpitis management.

The injection is given into the foot of gingival papilla distal off the affected tooth at the angle of 40-50° to the gum. At the depth of 2 to 3 mm, a small quantity of anesthetic solution is infiltrated to see the mucosa getting pale and then the needle is moved deep into the tissues to touch the interdental septum. Here the point of needle is inserted at 1.5-2 mm into the spongy bone of septum to infiltrate slowly the remaining anesthetic solution into the bone under some pressure.

### **1.3. Periodontal Ligament Injection**

This technique introduces local anesthetic directly into the periodontal space and, as the force required is quite substantial, specialized syringes are available to achieve this. In oral surgery, the intraligamentous injection is most frequently used if pain is being felt despite the normal techniques of infiltration or block anesthesia. This can occur when a tooth has acute pulpitis or apical infection. It may also be of value if limitation of jaw mobility makes block injection difficult or impossible. One of its advantages is the small volume of local solution needed, but it is often uncomfortable to administer and will cause a bacteremia which should be prophylactically covered with appropriate antibiotic in an endocarditis at-risk patient.

### **1.4. Intrapulpal Injection**

This injection is normally used where, despite apparently good anesthesia by other conventional means, the tooth remains painful on manipulation. This again is a feature of some pulpal or apical infections. In oral surgery, the tooth is normally being extracted and either the pulp canal(s) are already accessible or can be accessed using a small round bur. The technique is imprecise and escape of the solution is almost invariable. It can, however, be remarkably successful if

sufficient local can be introduced. Discomfort during its administration is often a reliable indication that it will prove of benefit.

## **2. BLOCK ANESTHESIA**

The block techniques of anesthesia provide a more effective and durable pain control encircling a larger site with less anesthetic solution as compared to infiltration techniques. This effect is caused by administering the anesthetic solution with close proximity to the nerve trunk paralyzing the pain sensation in the site innervated by this nerve. Block anesthesia requires good knowledge of maxillofacial topographic anatomy.

The former outputs involvement mean central conduction anesthesia, the latter outputs involvements indicate peripheral block anesthesia. When a branch of trigeminal nerve is blocked inside the mouth cavity, the anesthesia is referred to as intraoral, when anesthesia is performed from the side of soft facial tissues, it is called extra oral anesthesia.

### **2.1. PERIPHERAL BLOCK TECHNIQUES OF ANESTHESIA AT MAXILLA**

#### **2.1.1. Posterior Superior Alveolar Nerve Block (Tuberosital Anesthesia)**

##### **Intraoral technique**

**Indications:** maxillary molars extraction, excision of benign tumors, excision of periodontal ridge cyst.

**Target area** – maxillary tuber, located at the posterior surface of upper jaw (1.5-2 cm higher off the ridge rim, at the last molar level).

**Injection site** – in a slightly open mouth the needle is pricked into the transitory fold over the second molar at the angle of 45°.

**Direction of needle movements** – upward, to the rear and inward.

**Depth of needle penetration** – 1,5 to 2.0 cm continually not to lose contact with the bone and preceding the penetration with a stream of anesthetic solution. After aspiration is performed, the solution is administered.

**The area of pain control** comprises the upper molars and corresponding part of gum mucosa from the side of mouth atrium, fundus of maxillary sinus mucosa.

#### **2.1.2. Anterior and Middle Superior Alveolar Nerves Block (Infraorbital Injection)**

**Indications:** infraorbital anesthetics applicable in incisors, canine and premolars extraction and apicectomy as well as small benign tumors excision in maxillary ridge between the central and second premolars of the corresponding side; also in the upper lip, nasal arch and wing of nose.

Anesthesia near the infraorbital foramen is performed by two methods – intra- and extra oral.

### **Intraoral technique**

**Target area** – infraorbital foramen.

At first it is needed to define the location of the infraorbital foramen, according the special identification points. For achieving a good effect, solution of anesthetic can be entered directly into an infraorbital channel.

Infraorbital foramen's projection in the skin can be located in the following way:

- by palpating the lower rim of orbit, a bony shelf is located which corresponds to the conjunction site of zygomatic process of maxilla with zygoma; as a rule it is found at 0.5 cm inwards off the middle lower rim of orbit; 0.5 to 1.3 cm lower off this point the infraorbital foramen is located;
- it is possible to be oriented using the location of the teeth: the infraorbital foramen is 0.5 to 1.3 cm lower off the junction point of infraorbital rim with the vertical line between premolars;
- infraorbital foramen is located 0.5 to 1.3 cm lower off the junction point of orbit lower rim with the vertical line drawn through the middle of forward-looking eye pupil.

**Injection site** – after determination of infraorbital foramen location, firmly fix the index finger of left arm to this place. Displace an upper lip with thumb of that hand outside and up. Needle 4-5 cm long is inserted through the mucosa between central and lateral incisors in direction to infraorbital foramen, which is at the level of the tip of index finger. If an inflammatory process takes place in the area of frontal teeth, a needle can be inserted at the level of canine or first premolar and moved toward infraorbital foramen (anesthesia is less intensive).

**Direction of needle movements** – the needle should be moved along the bone to the rear, upward and outward in the direction to infraorbital foramen spraying small quantities of anesthetic solution all along. Aspiration is performed and the solution is then administered.

**Pain control area** – incisors, canines and premolars, alveolar ridge bone tissue, vestibular side of the gum with the abovementioned teeth, a part of maxillary antrum mucosa, upper lip and cheek, infraorbital area skin, lateral surface of nasal back, wing of nose and upper lip.

### **Extra oral techniques**

**Target area** – infraorbital foramen (its location techniques have been mentioned above). At this level, soft tissues are fixed with index finger of left arm.

**Injection site** – from the side of skin, retreating by 0.5 cm from the foramen projection and inside.

**Needle movements direction** – to the rear, upward and outward. Injection is given to the bone, and then 0.5 ml solution of anesthetic is administered with the purpose of painless search for the infraorbital foramen. When the needle has



reached the channel, the patient feels brief pain. Aspiration is performed and the solution is then administered.

**Pain control area** – the same as in the intraoral technique.

### **2.1.3. Anterior Palatine Nerve Block (Greater Palatine Foramen Injection, Palatine Anesthesia)**

This technique is applicable for blocking the anterior branches of palatine nerve which innervates the hard palate mucosa at the front of canine to the palatal junction.

**Indications:** for anesthetizing the mucosa in maxillary premolars and molars extraction, in the ridge surgery and surgery in the palate between the abovementioned teeth.

**Target area** is a small foramen in the fissure formed by the palatine and alveolar processes around the third molar and if it is absent – around the second one. This fissure is filled with spongy tissue.

**Injection site** – for pain relief it is sufficient to give an injection in close proximity to palatine foramen in the spongy tissue wherefrom the fluid penetrates palatine foramen. The site of injection is located forwards and outwards off the palatine foramen projection at the part of palate mucosa where a small palatine foramen is located which is approximately 0.5 cm off the alveolar ridge. If molars are missing, the injection is given 0.5 cm to the anterior off the line separating the soft and hard palate which can be distinguished by color.

**The direction of needle** – the needle is sent upwards, to the rear and somewhat to the front as far as it faces the bone which is 2-3 cm deep.

**Pain relief area** – minimum volumes of solution (0.3-0.5 ml) provide hard and soft palate tissues anesthesia between the third molar and middle of the canine.

### **2.1.4. Nasopalatine Nerve Block (Incisive Foramen Injection)**

The nasopalatine nerve goes out in the front area of the hard palate through the incisive canal. The incisive foramen is located on the middle line of the palate between central incisors, in 7-8 mm from a gingival edge. There are two routes of nasopalatine anesthesia – intraoral and extra oral (intranasal).

**Indications:** pain control in the anterior part of hard palate between the canines.

#### **Intraoral route**

**Target area** – incisive foramen located under the base of incisive papilla in the junction point of palate middle line with the line between the two canines.

**Injection site** – with the mouth wide open, a needle is inserted in the area of incisive papilla. Moving the needle toward a bone, release 0.3-0.5 ml solution of anesthetic which blocks a nerve in a channel.

**Direction of needle** – from the bottom upwards, from the rear to the front and inside. A good anesthetizing effect can be achieved by inserting the needle into the channel at the depth 0.5 cm to the side of incisive papilla.

**Pain relief area** – the mucous membrane of hard palate front side limited by the line joining canines' middle.

#### **Extra oral route**

In some cases, in the presence of pathological process in the frontal area of alveolar process (periostitis, osteomyelitis, tumor, etc.), there is a necessity for an extra oral route. It is achieved by the bilateral injection of anesthetic near the basis of the nose.

## **2.2. PERIPHERAL BLOCK TECHNIQUES OF ANESTHESIA AT MANDIBLE**

### **2.2.1. Mandibular Anesthesia**

**The target area** – the mandibular foramen is present on the internal surface of the mandibular ramus in its medial part. From the anterior and interior, it is covered with a bony prominence – mandibular «lingua». The foramen is located 1.5 cm posterior to the anterior border of the mandibular ramus, 1.3 cm away from its posterior border, and 2.5 cm away from the inferior border.

Anesthesia can be performed via intraoral and extra oral routes. The intraoral technique is more commonly used. There are dactylar and apodactylar Mandibular Standard Techniques.

**Position of the patient** – the patient is seated comfortably in the dental chair with his/here head, neck and trunk on the same plane and back resting on the chair respectively. When the patient's mouth is wide open, the occlusal plane of the mandibular teeth should be parallel with the floor.

#### **Dactylar Mandibular Anesthesia Standard Technique**

**The injection site** is located as follows. The positioning of retromolar fossa and temporal ridge are found by palpating and the projection of the latter is virtually transferred onto the mucous membrane. Then the index finger is fixed in retromolar fossa. Locating the syringe at the level of premolars of the opposite side the needle is inserted inwards from the temporal ridge and 0.75-1 cm higher off the masticator surface of third molar or along the superior-internal rim of index finger nail bone.

**The direction and depth of needle penetration** – the needle is moved to the outwards and to the rear at the depth of 0.5 to 0.75 cm where it reaches the bone. Then the syringe is moved to incisors, needle is deepened 2 to 2.5 cm along the bone and after that the syringe is again transferred as far as possible to the molars area and after aspiration anesthetic solution is injected.

#### **Apodactylar Mandibular Anesthesia Standard Technique**

**The injection site, direction and depth of needle penetration** – when the patient's mouth is wide open, the syringe is located at the level of premolars or

first molar of the opposite side. The needle is inserted into external clivus of pterygomandibular fold in the middle of distance between masticator surfaces of upper and lower molars (if they are missing – in the middle of distance between the ridges of alveolar processes). The needle is moved to the outside and to the rear until it touches the bone which is 1.5 to 2 cm deep and after aspiration the anesthetic solution is injected. Sometimes after moving the needle as deep as 2 cm inside no bone can be reached. In this case one should direct the syringe to the opposite side locating it at the second molar level. If the pterygomandibular fold is wide, the needle is pricked into its middle; when the fold is narrow – into its medial rim.

**Nerves anaesthetized** – inferior alveolar and lingual nerves.

**Pain relief area** – teeth to the midline body of the mandible, inferior portion of the ramus, mucosa, half of the inferior lip, tip of the tongue.

### **2.2.2. Mandibular Torus Anesthesia (by Weisbrem's method)**

**The target area** is mandibular torus formed by the fusing bone ridges going from the coronoid and condyloid processes.

**Injection site** is on the point formed by crossing of the horizontal line 0.5 cm lower off the masticator surface of third upper molar and the sulcus formed by lateral clivus of pterygomandibular fold and the cheek. Injection is given in the mouth open as wide as possible.

**The direction and depth of needle penetration** – the syringe is inserted at the level of lower molars on the side opposite to the site to be anaesthetized. The needle is moved as far as possible to reach the bone and after aspiration the anesthetic solution is injected.

**Nerves anaesthetized** – in this technique the simultaneous blocking of three nerves (inferior alveolar nerve, lingual and buccal nerves) can be observed in the area of bone shelf (torus) where they are densely located.

**Pain relief area** involves the tissues anaesthetized at mandibular anesthesia as well as mucosa on the vestibular side of mandible and from the middle of second premolar to the middle of second molar.

### **2.2.3. Mental and Incisive Nerves Block (Mental Foramen Injection)**

The term «Mental anesthesia» does not only mean mental nerve block but rather an injection in the area of the mental foramen, which results in anesthesia of both the mental and the incisive branches of the inferior alveolar nerve.

#### **Intraoral technique**

**The target area** is mental foramen located at the level of second lower premolar or between the second and first premolars and 12-13 mm higher off the lower rim of mandible. Its another location is the middle of distance between the anterior edge of masticator muscle and middle line of the low jaw.

**Injection site** – the needle is inserted some millimeters away from the transitory fold at the level of first molar crown.

**Needle direction and penetration.** Taking into consideration that mental foramen opens to the rear, upwards and outwards the direction of needle will correspondingly be from the rear forward, from the bottom upwards and from the outside inside. The needle should be moved 0.75-1 mm deep where it will reach mental foramen, after injecting small quantity of anesthetic the needle is carefully transferred to find the canal opening and then moved inside the canal 3-5 mm deep. After that the basic quantity of anesthetic solution should be deposited.

**Pain relief area** is the soft tissues of chin, lower lip, bone tissue of ridge, vestibular side of gum. In intra-canal distribution of anesthetic, a profound anesthesia is observable within premolars and canine while in the incisors area it is inadequate due to anastomosis on the opposite side.

#### **Extra oral technique**

Left hand fingers are placed on the position of mental foramen and fixed from the side of mouth cavity. From the side of facial skin, an injection is given upwards and to the rear off the mental foramen with the needle directed downwards and forward to reach the bone hitting the mental foramen in many cases. Otherwise some anesthetic solution is deposed onto the bone part and then carefully sliding with the tip of needle along the anesthetized area to reach the mental foramen to release 0.25-0.5 ml of anesthetic solution there.

**The pain relief area** is the same as in intraoral technique.

#### **2.2.4. Bersche-Dubov Anesthesia Technique**

In order to relieve inflammatory contracture in the lower jaw, **Bershe anesthesia technique** may be applicable which blocks motor fibers and **Dubov anesthesia technique** that arrests motor and sensory fibers of IIIrd branch of trigeminal nerve.

**Target area** is the medial surface of ramus bone in the area of its incisure where the lateral-motor and medial-sensory twigs of IIIrd trigeminal branch are closely set.

**Injection site** – the needle is pricked at 90° to the skin under zygomatic arch 2 cm forwards off the ear tragus.

**Needle direction and penetration.** The needle is moved perpendicularly to the medial line 2 to 2.5 cm deep through the semilunar incisure according to Bersche, 3 to 3.5 cm deep via Dubov technique.

**Pain control area** depends on the depth of needle penetration into the tissues. When moving the needle to 2-2.5 cm deep only the motor twigs of IIIrd trigeminal nerve branch are blocked. When penetrating 3-3.5 cm deep and deposing the anesthetic solution here the drug floods the inner surface of lateral pterygoid muscle where the sensory twigs of mandibular nerve are blocked along with the motor ones.

### **2.3. CENTRAL ANESTHESIA OF THE SECOND AND THE THIRD BRANCHES OF TRIGEMINAL NERVE NEAR THE BASE OF THE SKULL**

If a traditional peripheral block anesthesia is impossible (there is contracture, inflammatory process or new formations) it is necessary to block the barrels of the second and third branches of the trigeminal nerve at the place of their exit from openings of the skull base.

#### **2.3.1. Central Anesthesia of Trigeminal Nerve IInd Branch (Maxillary Nerve)**

Necessity of this type of anesthesia appears in those cases when operative interference is allowed in the whole maxilla, when there is a plural exodontia or when the ordinary block anesthesia is impossible because of any anatomic changes or presence of pathological process. This anesthesia is applicable in blocking neuralgia of the IInd branch of trigeminal nerve as well.

**Target area** is pterygolapatine fossa penetrated by the nerve coming from cranial cavity through a foramen rotundum. Penetration of the injection needle to the round opening, where a maxillary nerve gets out of the skull, is more dangerous than to a pterygopalatine fossula. A pterygopalatine fossa is closer to the centre than an infratemporal fossa and is between the maxilla and the pterygoid process of the sphenoid bone.

**The subzygomatic-pterygoid route** was developed in detail by S.N. Weisblatt in 1941. It has been proved by the author that a projection of the external plate of the pterygoid process of a sphenoid bone is in the middle of the trago-orbital line, which is led from the tragus of the auricle to the external edge of the eye socket.

**Needle direction and penetration.** As the oval opening is located behind the pterygoid process, S.N. Weisblatt recommends injecting a needle, 7 cm long, under the zygomatic arch, orienting on the middle of the trago-orbital line. The needle is moved along strictly perpendicularly to skin to the rest of the external plate of the pterygoid process of a sphenoid bone. The depth of penetration of the needle is marked by a finger. At first it is necessary to reach by a needle the external plate of pterigoid process, which corresponds to the depth of injection 4.5-5.5 cm. Draw out a needle little more than a half. Return the tag of the needle ahead under the angle of 15-20° and again dip the needle into the soft tissues at the first (marked) depth. Having reached a pterygopalatine fossula, inject anesthetic solution.

**Pain control area.** Anesthetizing of all tissues, which are innervated by the second branch of trigeminal nerve, appears in 15-20 minutes.

### **The palatal route**

**Needle direction and penetration.** A patient opens the mouth wide open. At first a small amount of anesthetic solution is being injected near the large palatal foramen. Then the needle, not less than 5 cm long, is injected through the opening and moved along a pterygopalatine channel at the depth of 3.5-4 cm (that corresponds to the distance to the round foramen). While moving through a channel, weak resistance of the bone walls is felt. Inject about 2 ml of anaesthetic.

**Pain control area.** Anaesthetizing of all tissues, which are innervated by the second branch of trigeminal nerve, appears in 10-15 minutes.

### **The tuberal route**

**Needle direction and penetration.** At first this way of anaesthetizing is worth conducting as extraoral tuberal anaesthesia. A needle is injected through the cheek under a zygomatic arch, then a needle is brought to the maxillary exuberance. Then, while slipping the needle along a bone, a syringe is taken outside and the needle is continued to move inside and upwards at the depth of 4.0-5.0 cm in a pterygopalatine fossa.

**Pain control area.** Anaesthetizing of all tissues, which are innervated by the second branch of trigeminal nerve, appears in 15-20 minutes.

### **2.3.2. Central Anesthesia of Trigeminal Nerve IIIrd Branch (Mandibular Nerve)**

This anesthesia technique is applicable for widespread surgeries in the mandible, in cases of impossibility of conducting intraoral method (there is an inflammatory process in the area of the corner of the lower jaw, reflex contraction of jaws, etc.), and in blocking neuralgia of the IIIrd trigeminal nerve branch.

**Target area.** Anesthetizing of the IIIrd branch of the trigeminal nerve is done near the oval foramen.

For anesthesia near the oval foramen of sphenoid bone, the following four routes are used: subzygomatic, suprazygomatic, mandibular, infraorbital.

**The subzygomatic route** was developed by S.N. Weisblatt in 1934.

**Needle direction and penetration.** The injection is made in the middle of the trago-orbital line; the needle is inserted up to the stop into the outer plate of the pterygoid process of the sphenoid bone. The depth of penetration is marked with finger. The needle is pulled out to the hypoderm, without moving a finger that captures the depth of pterygoid process. The needle tip is turned backwards at an angle of not less than 20°, and the needle is dipped again into the soft tissue at the depth which was previously marked. Thus, the target point of anesthesia (the oval foramen of sphenoid bone) is reached.

**Pain control area** comprises all the tissues of the corresponding part of mandible and part of the tongue.

**The suprazygomatic route** of anesthesia was suggested by S.N. Weisblatt in 1955.

**Needle direction and penetration.** The injection is carried out in the middle of the trago-orbital line over the zygomatic arch with a slight downward angle, which makes it possible to get to the outer plate of the sphenoid bone. Subsequently, performance of this route of pain relief is no different from the subzygomatic one (previously described).

**Pain control area** comprises all the tissues of the corresponding part of mandible and part of the tongue.

**The mandibular route** was applied by S.N. Weisblatt in 1937.

**Needle direction and penetration.** It is needed to take the syringe with needle not less than 8 cm in length. The distance from the injection site to the lower edge of the zygomatic arch is marked on a needle with the finger or a sterile rubber.

The site of injection is typical of extra oral mandibular anesthesia. It is necessary to permeate the inner surface of the ramus of mandible; having passed 0.5-0.75 cm, the needle tip is bent from the bone wall inside. For this purpose, it is needed to avert the syringe outwards at the same angle as we turned it inside during the preliminary measurement of the distance from the injection site to the lower edge of the zygomatic arch.

**Pain control area** comprises all the tissues of the corresponding part of mandible and part of the tongue.

**The orbital route** was proposed by S.N. Weisblatt in 1956.

**Needle direction and penetration.** The injection site is at the lower edge of the orbit near its lower external corner. The needle at the distance of 2-2.5 cm penetrates the wide lateral part of the infraorbital gap in the infratemporal fossa and then, moving in contact with the bottom wall of the orbit, it is brought to the oval foramen of sphenoid bone.

**Pain control area** comprises all the tissues of the corresponding part of mandible and part of the tongue.

### **3. Squirt-and-cut technique (by A.V. Vishnevsky method)**

This anesthesia implies infiltrating tightly all the corresponding tissues of assumed incision with 0,25% solution of Novocaine. After incision of skin the subjacent tissues are again infiltrated with anesthetic which ensures their insensibility.

## **NON-INJECTION (TOPICAL) ANESTHESIA TECHNIQUES**

The non-injection group of local anesthesia in stomatology includes chemical and physical techniques. Topical anesthesia is useful as it permits the painless insertion of sharp needles and also enables simple superficial procedures.

The application of ointments or solution containing local anesthetic compounds to accessible structures, e.g. skin and mucous membrane is called chemical technique of topical anesthesia. In such condition the anesthetic agent penetrates through the epithelium and renders the region insensible by its effect on the free nerve endings. The application of cold to the surface of mucous membrane or skin is called physical technique of topical anesthesia. Within this group of anesthesia, ice bags or crushed ice, as well as topical ethyl chloride spray are used. Ethyl chloride, after being sprayed to the region, as far as it evaporates, causes drop in the temperature of the sprayed region with the resultant effect of superficial surface anesthesia.

## **COMPLICATIONS IN LOCAL ANESTHESIA**

### **A. General complications**

1. Syncope
2. Toxic response to local anesthetic agents with vasoconstrictors
3. Allergy
4. Incursion of concurrent chronic diseases caused by local anesthesia
  - epilepsy
  - ischemic heart disease, myocardial infarction
  - hypertensive crisis
  - steroid crisis
  - diabetic coma
5. Viral hepatitis
6. AIDS

### **B. Local complications**

1. Post-injection pains
2. Soft tissues edema
3. Needle-caused injuries of soft tissues
4. Soft tissue necrosis
5. Jaws contracture.
6. Bleeding, hematoma
7. Tissue ischemia
8. Paresthesia or anesthesia with prolonged duration
9. Facial nerve paresis
10. Diplopia
11. Soft tissues emphysema
12. Injury (biting) of a lip, tongue due to their decreased sensitivity.



## **ALGORITHM FOR SOME MINOR ORAL SURGICAL PROCEDURES**

### **1. OPERATION OF TOOTH EXTRACTION**

#### **1.1. Simple (Closed) Tooth Extraction**

The simple (closed) technique is that which is used most often in everyday practice. The simple extraction is accomplished with the help of extraction forceps and elevators.

#### **Instruments**

##### **Forceps**

The basic components of the extraction forceps are the handle, which is above the hinge, and the beaks, which are below the hinge. The instrument is held in the hand by the handle, upon which pressure is exerted during the extraction. The beaks are the functional component of the forceps and grasp the tooth at the cervical region and remove it from the alveolar socket.

Because tooth anatomy varies, extraction forceps with specially designed beaks have been manufactured, so that they may be used for specific teeth. So, according to the size and shape of the handles and beaks, the following types exist.

##### **Maxillary Forceps**

**The Straight Forceps.** Forceps for extracting upper anterior teeth are of a simple design. The handles are straight and 12-14 cm long, joined at a hinge to the beaks, which are 2-3 cm long. The handles are contoured on their outer surface to allow a good grip. The beaks are both concave on their inner aspect, shaped to fit around the root of the tooth as closely as possible when the forceps are applied in the long axis of the tooth. The beaks are applied labially and palatally. All extraction forceps can be seen as modifications of this basic design. These forceps can be applied to the long axis of anterior teeth, gaining access by the patient opening their mouth fairly widely. However, if one were to attempt to use these forceps on an upper first premolar, there is a risk of traumatizing the lower lip.

**The S-shaped Forceps.** Forceps for use in the upper jaw further back than the canine have a curve in the beak, which keeps them above the lip when they are in the long axis of the tooth. The beaks of these forceps are also concave on their inner aspect to fit the root of upper premolars. These forceps could be used to extract posterior teeth, but for teeth with multiple roots, forceps are available with beaks specifically designed to fit complex root forms.

**The S-shaped Right and Left Forceps.** These forceps have a slightly curved shape that looks like an «S». The buccal beak of each forceps has a pointed design, which fits into the buccal bifurcation of the two buccal roots, while the palatal beak is concave and fits into the convex surface of the palatal root. S-shaped Right Forceps are used for removal of the first and second molars of the right maxilla, S-shaped Left Forceps are used for removal of the first and second molars of the left maxilla.

**The Bayonet-shaped Forceps.** Erupted third molars have a single conically shaped root, but access for extraction of teeth far back in the mouth can be difficult. A further variation involves a step in the beaks of the forceps, which enables us to put the beaks on the upper third molar whilst avoiding the lower lip. Another design variation is shown in the offset molar forceps with very narrow beaks. These are used primarily to remove broken maxillary molar roots but can be used for removal of narrow premolars. These forceps, are also known as **Bayonet-shaped Root Tip Forceps**.

### **Mandibular Forceps**

Extraction of mandibular teeth requires forceps that can be used for single-rooted teeth for incisors, canines, and premolars, as well as for two-rooted teeth for the molars. The forceps most commonly used for the single-rooted teeth are the **Beak-shaped Forceps (English-style Forceps)** or the **Lower Universal Forceps**.

**The Beak-shaped Forceps (English-style Forceps).** Such forceps can be used effectively on lower teeth, from second premolar to second premolar. These forceps has hinges in vertical direction. Great force can be generated during extraction with this type of forceps, so that if the bone is not elastic, there is increased risk of fracture of the alveolar bone. Just as with the forceps for upper teeth, beak design has been modified for multiple-rooted teeth.

**The Mandibular Molar Forceps.** These forceps are used for both sides of the jaw and have straight handles while the beaks are curved at approximately a right angle compared to the handles. Both beaks of the forceps have pointed ends, which fit into the bifurcation of the roots buccally and lingually. These forceps are used for the removal of both the first and second molar of the right and left side of the lower jaw.

**The Forceps curved on a plane.** There are special for removal third molars. These forceps also have points on both beaks, but they bent on a plane, as against other lower forceps bent on an edge. In case of need we can use these tools for extraction of all lower molars when patient has a trismus or insufficient opening of a mouth.

### **Elevators**

The elevator is the second most important instrument (after the extraction forceps) with which tooth extraction is achieved or aided. Sometimes teeth and roots may be removed with elevators alone. It is composed of three parts: the handle, the shank, and the blade. The shape of blade differs for each elevator type, and each is used as the need dictates.

**The Straight Elevator.** This is the most commonly used type of elevator for the removal of teeth and roots, in both the upper and lower jaws. As already mentioned, the elevator's components are the handle, shank, and blade. The handle is pear-shaped, and big enough to be held comfortably in the hand for the surgeon to apply pressure to the tooth to be luxated. The shank is narrow and long and connects the handle to the blade. The blade has two surfaces: a convex and a concave one. The concave surface is placed buccally, either perpendicular to the tooth or at an angle, and always in contact with the tooth to be luxated. The elevator is held in the dominant hand, and the index

finger is placed along the blade almost reaching its end. The end of the blade is left exposed and is seated between the socket and the tooth to be luxated.

**Pair Angled Elevators.** Their handle is similar to that of the straight elevator. The shank has a double angle, so that the instrument may enter the socket, and the two elevators face in opposite directions. The blade has a convex and concave surface, ending in a sharp point. There are also double-angled elevators with narrow blades and very sharp ends, which may easily remove small broken root tips.

### **Requirements for a Successful Simple Tooth Extraction**

The positions of the patient, chair and operator are critical for successful completion of the extraction. To ensure adequate visualization and comfort during the various manipulations required for the tooth extraction, the dental chair must always be positioned correctly. For the extraction of a maxillary tooth, the patient's mouth must be at the same height as the dentist's shoulder and the angle between the dental chair and the horizontal (floor) must be approximately 120°. Also, the occlusal surface of the maxillary teeth must be at a 45° angle compared to horizontal when the mouth is open. For the extraction of mandibular teeth, the chair is positioned lower than for extraction of maxillary teeth, so that the angle between the chair and the horizontal is about 110°. Furthermore, the occlusal plane of the mandibular teeth must be parallel to the floor when the patient's mouth is open.

The position of right-handed dentists during extraction of maxillary teeth using forceps is in front of and to the right of the patient. For the extraction of mandibular teeth right-handed dentists should be positioned in front of the patient, or behind them and to their right.

### **General Principles of Tooth Extraction Procedure**

The extraction itself is accomplished in two stages. During the first stage, the tooth is separated from the soft tissues surrounding it using a desmotome or smoother; during the second stage, the tooth is elevated from the socket using forceps or an elevator.

When using the forceps and elevators to luxate and remove teeth, it is important that the surgeon's opposite hand play an active role in the procedure. For the right-handed operator, the left hand has a variety of functions. It reflects the soft tissues of the cheeks, lips, and tongue to provide adequate visualization of the surgical field. It helps to protect other teeth from the forceps, should it release suddenly from the tooth socket. It helps to stabilize the patient's head during the extraction process. In some situations, large amounts of force are required to expand heavy alveolar bone; therefore the patient's head requires active assistance to be held steady.

The opposite hand plays an important role in supporting and stabilizing the lower jaw when mandibular teeth are being extracted. It is often necessary to apply considerable pressure to expand heavy mandibular bone, and such forces can cause discomfort and even injury to the TMJ unless a steady hand counteracts

them. Finally, the opposite hand supports the alveolar process and provides tactile information to the operator concerning the expansion of the alveolar process during the luxation period. In some situations it is impossible for the opposite hand to perform all of these functions at the same time, so the surgeon requires an assistant to help with some of them.

After reflecting of the gingiva, the beaks of the forceps are positioned at the cervical line of the tooth, parallel to its long axis, without grasping bone or gingivae at the same time. The initial extraction movements applied are very gentle. For the surgeon to extract teeth successfully it is important to understand the morphology of the roots of the tooth which is to be extracted. Only then can force be applied appropriately to remove the tooth.

More specifically, the dentist applies slow steady pressure to move the tooth buccally at first, and then palatally or lingually. Movements must become greater gradually and the buccal pressure is greater than the corresponding palatal or lingual pressure, because the labial or buccal bone is thinner and more elastic compared to that of the palate. If anatomy of the root permits (single, conical roots), rotational force may be applied in addition to buccopalatal or buccolingual pressure. These movements expand the alveolar bone and also sever all the periodontal fibers. Slight traction is also employed at the same time, facilitating the tooth extraction. During the final extraction phase, traction is not permitted, because there is risk of damage due to sudden removal of the tooth and the risk of the forceps knocking the teeth of the opposite arch. To avoid such a possibility, the final extraction movement must be labial or buccal, and in a curved direction that is outwards and upwards for the maxilla, and outwards and downwards for the mandible. Before the tooth is delivered from the socket, the soft tissue between the tooth and the gingiva must be examined for a possible attachment. If this is the case, the gingiva must be completely severed from the tooth, because there is a risk of greatly tearing the tissues.

After extraction of the tooth, the bottom of the socket is inspected and if the tooth is nonvital should be curetted with a periapical curette to remove any periapical lesion from the area. Curetting must be done carefully, because if any remnants of granulation tissue remain in the socket, there is a chance they will develop into a cyst. Sometimes the lesion is firmly attached to the root tip of the tooth and is extracted together with the tooth. When the lesion is large and the entire lesion cannot be removed through the socket alone, then surgery is required.

Afterwards, and only if considered necessary (e.g., there are sharp bone edges), the alveolar margin is smoothed using rongeur forceps or a bone file, and then the lingual and buccal plates are compressed using finger pressure. This is done to restore the expansion of the socket caused by the extraction, and also for initial control of hemorrhage.

### **Post-Extraction Instructions**

The incidence of post-extraction complications may be reduced by clear

post-extraction instructions. The patient must be warned not to use a rinsing for the first 24 hours. After this, the mouth may be rinsed with warm chamomile or salt water, three times a day for 3-4 days. The teeth should be brushed with a toothbrush and flossed, but the patient should avoid the area of surgery.

Very hot or cold foods, alcohol or exercise are best avoided over the same period. The patient's diet on the day of the surgical procedure must consist of cold, liquid foods (pudding, yogurt, milk, cold soup, etc.).

After surgery, better if the patient can stay at home and not go to work for 1 or 2 days, depending on the extent of the surgical wound and the patient's physical condition. After the surgical procedure, the extraoral placement of cold compresses (ice pack wrapped in a towel) over the surgical area is recommended (this should last for 10-15 min at a time, and be repeated every half hour, for at least 4-6 h). If sutures were placed on the wound, the patient must have them removed a week later. Where extractions were performed under a local anesthetic the danger of biting or burning the anesthetized lips or mouth should be stressed.

### **1.1.1. Extraction of Maxillary Central Incisors**

**Instruments.** Straight Crown Forceps, Desmotome or Smoother, Bone Curette, Tweezers, Mouth Mirror.

**Patient's Position.** For the extraction of maxillary central incisors, the patient's mouth must be at the same height as the dentist's shoulder.

**Doctor's Position.** In order to extract maxillary central incisors, right-handed dentists must be positioned in front of and to the right of the patient. The index finger of the left hand is then placed labially, and the thumb palatally, firmly holding the alveolar process next to the tooth to be extracted.

**Algorithm of Extraction.** At first stage the tooth is separated from the soft tissues surrounding it using a desmotome or smoother. Beaks of the forceps are adapted to the tooth, and the beaks must be parallel to the long axis of the tooth. Beaks of the forceps are pushed to edges of socket walls and are fixed. The initial extraction movements are gentle, first in a labial direction, and then palatal. After the initial force is applied to the tooth, motions gradually become greater and the final extraction force is applied labially. Because the root of the central incisor is conical in shape, its removal may also be achieved using rotational forces. More specifically, the tooth is rotated first in one direction and immediately afterwards in the other direction, until the periodontal fibers are completely severed. The tooth is then delivered from the socket using slight traction.

### **1.1.2. Extraction of Maxillary Lateral Incisors**

**Instruments.** Straight Crown Forceps, Desmotome or Smoother, Bone Curette, Tweezers, Mouth Mirror.

**Patient's Position.** For the extraction of maxillary lateral incisors, the patient's mouth must be at the same height as the dentist's shoulder.

**Doctor's Position.** In order to extract maxillary lateral incisors, right-handed dentists must be positioned in front of and to the right of the patient. The fingers of the left hand are placed in exactly the same way as for the central incisors.

**Algorithm of Extraction.** At first stage the tooth is separated from the soft tissues surrounding it using a desmotome or smoother. Beaks of the forceps are adapted to the tooth, and the beaks must be parallel to the long axis of the tooth. The extraction movements for removal of the lateral incisor are labial and palatal. Because the lateral incisor has a thin root and there is usually curvature of the root tip distally, rotational force is not allowed. Slight rotational motions may be employed only in the final stage, with simultaneous traction of the tooth from the socket.

### **1.1.3. Extraction of Maxillary Canines**

**Instruments.** Straight Crown Forceps, Desmotome or Smoother, Bone Curette, Tweezers, Mouth Mirror.

**Patient's Position.** For the extraction of maxillary canines, the patient's mouth must be at the same height as the dentist's shoulder.

**Doctor's Position.** In order to extract maxillary canines, right-handed dentists must be positioned in front of and to the right of the patient, whose head should be turned towards the dentist. The fingers of the left hand are placed as follows: for the right side, the thumb is placed labially and the index finger palatally, while for the left side, the index finger is placed labially and the thumb palatally.

**Algorithm of Extraction.** At first stage the tooth is separated from the soft tissues surrounding it using a desmotome or smoother. Beaks of the forceps are adapted to the tooth, and the beaks must be parallel to the long axis of the tooth. The extraction movements are labial and palatal, with gradually increasing intensity. Because the canine has a flattened root and the root tip is usually curved distally, rotational motions are not permitted, or if they are used, they must be done so very gently and with alternating buccopalatal pressure. The final extraction movement is labial.

### **1.1.4. Extraction of Maxillary Premolars**

**Instruments.** S-shaped Crown Forceps, Desmotome or Smoother, Bone Curette, Tweezers, Mouth Mirror.

**Patient's Position.** For the extraction of maxillary premolars, the patient's mouth must be at the same height as the dentist's shoulder.

**Doctor's Position.** In order to extract maxillary premolars, the dentist should be positioned in front of and to the right of the patient. For right-handed dentists, the fingers of the left hand are placed as follows: for the right side, the index finger is placed palatally and the thumb buccally, while for the left side, the index finger is placed buccally and the thumb palatally.

**Algorithm of Extraction.** At first stage the tooth is separated from the soft tissues surrounding it using a desmotome or smoother. Beaks of the forceps are adapted to the tooth, and the beaks must be parallel to the long axis of the tooth. As for the first premolar, because it usually has two roots, buccal and palatal pressure should be gentle

and slight. If movements are vigorous and abrupt, there is a risk of fracturing the root tips. Rotational motions are not allowed due to the tooth's anatomy. Extraction of the second premolar is easier, because the tooth has one root. Movements are the same as those for the first premolar. The final movement for both teeth is buccal.

### **1.1.5. Extraction of Maxillary First and Second Molars**

**Instruments.** S-shaped Right Forceps, S-shaped Left Forceps, Desmotome and Smoother, Bone Curette, Tweezers, Mouth Mirror.

**Patient's Position.** For the extraction of maxillary first and second molars, the patient's mouth must be at the same height as the dentist's shoulder.

**Doctor's Position.** In order to extract maxillary molars, the dentist must be positioned in front of and to the right of the patient. The fingers of the left hand are placed in exactly the same way as for maxillary premolars. The appropriate forceps are chosen, depending on the tooth to be extracted.

**Algorithm of Extraction.** At first stage the tooth is separated from the soft tissues surrounding it using a desmotome or smoother. Beaks of the forceps are adapted to the tooth, and the beaks must be parallel to the long axis of the tooth. The maxillary first molar has three diverging roots: the palatal, which is the largest and most widely divergent toward the palate, and the two buccal roots, which are often curved distally. The tooth is firmly anchored in the alveolar bone and its buccal surface is reinforced by the extension of the zygomatico-alveolar process. This tooth therefore requires the application of strong force during its extraction, which may cause fracture of the crown or root tips. To avoid this from happening, initial movements must be gentle, with buccopalatal pressure and an increasing range of motion, especially buccally, where resistance is less. The final extraction movement is a buccal upwards curved motion, following the direction of the palatal root. Because the root tips are close to the maxillary sinus, their removal requires careful consideration, due to the risk of oroantral communication.

Extraction of the maxillary second molar may be accomplished in the same way as for the maxillary first molar, because the teeth have similar anatomy. Extracting the second molar, however, is considered to be easier than extracting the first molar, because there is less resistance from the buccal alveolar process and relatively little divergence of the roots. Quite often the roots of this tooth are fused together in a conical shape. In this case, extraction of the tooth is even easier.

### **1.1.6. Extraction of Maxillary Third Molar**

**Instruments.** Bayonet-shaped Crown Forceps, Straight Elevator, Desmotome or Smoother, Bone Curette, Tweezers, Mouth Mirror.

**Patient's Position.** For the extraction of maxillary third molar, the patient's mouth must be at the same height as the dentist's shoulder.

**Doctor's Position.** In order to extract maxillary third molars, the dentist must be positioned in front of and to the right of the patient. The fingers of the left hand are placed in exactly the same way as for maxillary premolar extraction.

**Algorithm of Extraction.** At first stage the tooth is separated from the soft tissues surrounding it using a desmotome or smoother. Beaks of the forceps are adapted to the tooth, and the beaks must be parallel to the long axis of the tooth. The maxillary third molar is the smallest of all molars and varies greatly in size, number of roots, and root morphology. It most commonly has three roots just like the other maxillary molars, but smaller and converging. They are usually fused together in a conical shape, curved distally. Extraction of the tooth depends on its location, as well as on the number and shape of the roots.

If the third molar has erupted completely and its roots are fused (conical shape), its extraction does not usually present any difficulty and it may be removed with only buccal pressure. The risk of fracturing the palatal alveolar process is avoided this way, which would otherwise occur if force were applied palatally (the palatal bone is thinner and lower than the buccal bone). When the tooth has three or more roots, though, its extraction is accomplished by applying buccal pressure and very gentle palatal pressure.

The final extraction movement must always be buccal. Root anatomy of the third molar permitting, extraction is easily accomplished using the straight elevator. The elevator is positioned between the second and third molars and the tooth is luxated according to the direction of its roots.

#### **1.1.7. Extraction of Mandibular Incisors**

**Instruments.** Beak-shaped Crown Forceps, Desmotome or Smoother, Bone Curette, Cotton and dressing Tweezers, Mouth Mirror.

**Patient's Position.** For the extraction of mandibular incisors, the patient's mouth must be at the same height as the dentist's elbow.

**Doctor's Position.** In order to extract mandibular incisors, right-handed dentists may be positioned in front of and to the right of the patient. The mandible is stabilized with the four fingers, which are placed on the submandibular area, and the thumb is placed on the occlusal surfaces of the teeth.

**Algorithm of Extraction.** At first stage the tooth is separated from the soft tissues surrounding it using a desmotome or smoother. Beaks of the forceps are adapted to the tooth, and the beaks must be parallel to the long axis of the tooth. Mandibular incisors have narrow flattened roots, which are not very firmly anchored in the alveolar bone. These teeth have one root and are curved at the root tip, especially the lateral incisor. Their extraction is easy, due to their morphology and the thin labial alveolar bone surrounding the root. Extraction pressure is applied labially and lingually, gradually increasing in intensity. Due to the flattened roots of the teeth, only slight rotational force is permitted.

#### **1.1.8. Extraction of Mandibular Canines**

**Instruments.** Beak-shaped Crown Forceps, Desmotome or Smoother, Bone Curette, Tweezers, Mouth Mirror.



**Patient's Position.** For the extraction of mandibular canines, the patient's mouth must be at the same height as the dentist's elbow.

**Doctor's Position.** In order to extract mandibular canines right-handed dentists must be positioned in front of and to the right of the patient.

**Algorithm of Extraction.** At first stage the tooth is separated from the soft tissues surrounding it using a desmotome or smoother. Beaks of the forceps are adapted to the tooth, and the beaks must be parallel to the long axis of the tooth. Mandibular canines usually have only one root. Seventy per cent of these teeth have a straight root, while 20% present distal curvature. Compared to incisors, canines are more difficult to extract, due to the long root and frequent curvature of the root tip. Extraction movements are the same as those employed for central and lateral incisors. The final extraction movement for all anterior teeth is labial, curved outwards and downwards. Damage of maxillary teeth by the forceps is thus avoided.

### **1.1.9. Extraction of Mandibular Premolars**

**Instruments.** Beak-shaped Crown Forceps, Desmotome or Smoother, Bone Curette, Tweezers, Mouth Mirror.

**Patient's Position.** For the extraction of mandibular premolars, the patient's mouth must be at the same height as the dentist's elbow.

**Doctor's Position.** In order to extract mandibular right premolars, the dentist must be positioned behind and to the right of the patient; for extraction of left premolars the dentist must be positioned in front of and to the right of the patient.

**Algorithm of Extraction.** At first stage the tooth is separated from the soft tissues surrounding it using a desmotome or smoother. Beaks of the forceps are adapted to the tooth, and the beaks must be parallel to the long axis of the tooth. Even though mandibular premolars are generally surrounded by dense, hard bone, their extraction is considered quite easy because their roots are straight and conical, although sometimes they may be thin or the root tip may be large. Buccolingual force is applied for extraction of these teeth. Gentle rotational force may also be applied when extracting the second premolar. The final extraction movement is outwards and downwards.

### **1.1.10. Extraction of Mandibular First and Second Molars**

**Instruments.** Beak-shaped Molar Forceps with spines, Desmotome or Smoother, Bone Curette, Tweezers, Mouth Mirror.

**Patient's Position.** For the extraction of mandibular first and second molars, the patient's mouth must be at the same height as the dentist's elbow.

**Doctor's Position.** In order to extract right mandibular first and second molars, the dentist must be positioned behind and to the right of the patient; for extraction of left molars, the dentist must be positioned in front of and to the right of the patient.

**Algorithm of Extraction.** At first stage the tooth is separated from the soft tissues surrounding it using a desmotome or smoother. Beaks of the forceps are adapted to the tooth, and the beaks must be parallel to the long axis of the tooth. The mandibular first

molar usually has two roots, a mesial and a distal one. The mesial root is larger, more flattened than the distal root and usually is curved distally. The distal root is straighter and narrower than the mesial root, and more rounded. The mandibular second molar has a morphology similar to that of the first molar. Even though this tooth is surrounded by dense bone, it is removed more easily than the first molar, because its roots are smaller and less divergent, and they are often fused together.

The extraction technique is the same for both molars. Initially the movements are gentle with buccal and lingual pressure. After the tooth is slightly mobilized, force is gradually increased and the final extraction movement is buccal, taking care not to damage the maxillary teeth with the forceps.

#### **1.1.11. Extraction of Mandibular Third Molar**

**Instruments.** Mandibular Third Molar Forceps (Forceps Curved on the Plane), Straight Elevator, Lecluse's elevator, Desmotome or Smoother, Bone Curette, Tweezers, Mouth Mirror.

**Patient's Position.** For the extraction of mandibular third molar, the patient's mouth must be at the same height as the dentist's elbow.

**Doctor's Position.** In order to extract mandibular third molars by Mandibular Third Molar Forceps, the dentist must be positioned in front of and to the right of the patient.

**Algorithm of Extraction.** At first stage the tooth is separated from the soft tissues surrounding it using a desmotome or smoother. Beaks of the forceps are adapted to the tooth, and the beaks must be parallel to the long axis of the tooth. The mandibular third molar usually has two roots, whose morphology is similar to that of the other molars. They are smaller, though, and usually are fused in a conical shape, widely diverging distally. Buccolingual pressure is applied and the range of motion depends on the morphology of the buccal and lingual alveolar bone. The lingual alveolar bone is very thin compared to the buccal alveolar bone, which is unyielding in the third molar area; therefore, the force that mobilizes the tooth must be applied in the lingual direction. Afterwards, pressure must be applied very carefully, so as to avoid fracture of both the tooth, due to excessive buccal force, and the lingual plate of bone.

If the third molar has one root or if the roots converge and are curved in the same direction, the extraction may be accomplished using the straight elevator alone. In this case the elevator is positioned at the mesial surface of the tooth, which is delivered according to the direction of curvature of the roots.

#### **1.1.12. Extraction of Roots**

##### **Extraction Technique Using Root Tip Forceps**

The root tip forceps are used in exactly the same way as the tooth forceps. In order to use this instrument, the root must protrude out of the gingivae, so that it can be firmly grasped. As for the dentist's position, placement of fingers of the nondominant hand and extraction movements, they are no different than those described for intact teeth.

## **Extraction Technique Using Elevator**

A variety of elevators may be used to extract roots and root tips. The most commonly used elevator is the straight elevator. There is no doubt that the straight elevator is the ideal instrument in everyday dentistry, as long as it is used correctly. Otherwise, it may cause a number of undesirable complications. In order to avoid such situations, certain basic rules must be followed:

A. The straight elevator must be held in the dominant hand and the index finger placed along the blade, leaving its anterior end exposed, which is used to luxate the tooth or root.

B. This instrument must always be used buccally, and never on the lingual or palatal side.

C. The concave surface of the blade must be in contact with the mesial or distal surface of the tooth to be extracted, and be seated between the tooth and alveolar bone.

D. During luxation, a cotton roll or gauze should be placed between the finger and palatal or lingual side, to avoid injury of the finger or tongue in case the elevator slips.

E. During luxation, the adjacent tooth should not be used as a fulcrum, but only the alveolar bone. Otherwise, there is a risk of damaging the periodontal ligament fibers.

During the luxation attempt using the straight elevator, the fingers of the left hand must be in a certain position.

**Maxilla:** From the right premolar up to the right third molar (teeth 14-18), the index finger is placed palatally and the thumb is placed buccally. From the right canine up to the left third molar (teeth 13-28), the index finger is placed labially or buccally and the thumb is placed palatally.

**Mandible:** From the right first premolar up to the right third molar (teeth 44-48), the nondominant hand embraces the patient's head and the index finger is placed buccally, while the thumb is placed lingually. From the right canine up to the left third molar (teeth 43-38), the index finger is placed lingually and the thumb is placed labially or buccally

### **Extraction of Single-Rooted Teeth with Destroyed Crown**

The removal of single-rooted teeth whose crown has been destroyed is accomplished with the help of the straight elevator. More specifically, the blade of the elevator is seated between the root and alveolar bone (perpendicular or at an angle), with the concave surface of the blade in contact with the mesial or distal surface of the root. Using the alveolar bone as a fulcrum, rotational forces are applied around the axis of the elevator, in the mesial and distal area, resulting in displacement of the root and elevation from the socket.

### **Extraction of Multi-Rooted Teeth with Destroyed Crown**

The extraction of roots of multi-rooted teeth whose crown is destroyed is impossible using extraction forceps or root tip forceps. In such cases, removal is accomplished after separating the roots using the procedure described below.

If the roots are above the alveolar bone, the roots are sectioned and separated after creating a deep perpendicular buccolingual groove using a fissure bur, which reaches the intraradicular bone. The roots are then removed separately one at a time, using either root tip forceps or an elevator.

Sectioning may also be accomplished using the straight elevator, after placing its blade in the root bifurcation, with the concave surface of the instrument in contact with the distal root. At the same time, the fingers are placed as described for the extraction using an elevator, protecting the tissues from the sharp end of the blade in case the instrument slips. The roots are separated employing rotational movements, while at the same time the distal root is elevated relatively easily from its socket. The mesial root may then be removed using the angled elevator. The elevator is placed so that the blade is positioned in the empty socket with its end facing the root. The intraradicular bone is removed first (if it is higher than the root) and then the tip of the elevator comes into contact with the root, which is removed after carefully applying rotational pressure upwards.

### **Extraction of Root Tips**

In order to extract root tips from the maxilla and mandible, double-angled elevators are considered the most appropriate instruments, due to their sharp tip, which fits easily between the root tip and the alveolar bone, first mobilizing and then luxating the root tip from the socket. In these cases, especially useful instruments are those that have very narrow blades of various shapes (straight, hooked, etc.). Their use is indicated for the removal of small root tips remaining at the bottom of the socket, since they may be placed in that area more easily than standard elevators.

The procedure for extracting a root tip is now described. When the root tip is very small and deep in the socket, a narrow angled elevator is placed between the alveolar bone and the root tip, and the instrument is pushed forward gently as apically as possible. Luxation is then attempted until the root tip is mobilized. If the root tip is not mobilized at all, attempts are continued on the mesial and distal aspects of the socket until the root tip is fully mobilized, upon which its removal is very easy.

When the extraction involves a root tip of a maxillary or mandibular molar and the extraction proves difficult, part of the intraradicular bone is removed from inside the socket with a round bur or sharp instrument, creating room that will facilitate its luxation. If the root tip belongs to the palatal root, even though the extraction may be accomplished using the same procedure, the dentist must be especially careful, because there is an increased risk of displacing the root tip into the maxillary sinus.

The root tip may also be removed with the aid of an endodontic file, which is first positioned inside the socket and then screwed into the root canal, upon which the root tip is delivered either by hand or with a needle holder. When a needle holder is used, a protective gauze may be placed between it and the occlusal surface of the teeth on which it rests.

## **1.2. SURGICAL TOOTH EXTRACTION**

Surgical extraction is the method by which a tooth is removed from its socket, after creating a flap and removing part of the bone that surrounds the tooth. This technique is relatively simple and within a general practitioner's scope if the basic principles of the surgical technique are followed.

### **Steps of Surgical Extraction**

The surgical extraction techniques for single-rooted and multi-rooted teeth are similar, and include the following steps:

1. Creation of a flap.
2. Removal of bone and exposure of an adequate part of the root.
3. Extraction of the tooth or root with elevators or forceps.
4. Postoperative care of wound and suturing.

The surgical extraction involves teeth with intact crowns, roots and root tips, and presents certain characteristics in each of these cases.

### **1.2.1. Removal of Single-rooted or Multi-rooted Tooth with an Intact Crown**

The removal of a single-rooted or multi-rooted tooth with an intact crown is achieved with the simple extraction technique and is usually very easy. There are certain situations, though, when the extraction requires a surgical approach, in order to avoid undesirable complications. The procedure for these cases is as follows. When the extraction involves a multi-rooted maxillary tooth, an envelope flap is created and the buccal plate is removed using a round bur, as far as the root bifurcation. The two buccal roots are sectioned after a groove is created using a fissure bur, and the crown together with the palatal root is then removed. The two other roots are then removed separately, preferably using a straight elevator or root tip forceps.

If an extraction is indicated for a tooth that has hypercementosis at the root tip, then it must be performed using the surgical technique. Otherwise, as already mentioned, fracture of the root tip is inevitable. The procedure used for such cases generally is described below:

When the tooth to be extracted is single-rooted, an L-shaped flap is initially created, and the bone covering the buccal surface of the root is then removed. The extraction is performed easily towards the buccal side that is no longer covered by bone, using forceps or elevators.

When the tooth to be extracted is multi-rooted with hypercementosis at the root tip, at first an envelope flap is created, and the buccal bone is removed to just below the root bifurcation. The roots are separated, after a vertical groove is created on the crown of the tooth using a fissure bur, which extends as far as the intraradicular bone. After this procedure, the mesial part is removed first (root and crown) using forceps or an elevator. Afterwards, the intraradicular bone is removed using a round bur, and the socket is widened along the length of the root. After this widening, the distal part, which includes the bulbous root tip, is easily removed using forceps, a straight elevator or an elevator with T-shaped handles.

### 1.2.2. Surgical Extraction of Roots

There are various surgical techniques for root removal, as listed below:

- Removal of part of the buccal bone for luxation of the root buccally.
- The opening of a window on the buccal bone for removal of the root through the socket or through the window itself.
  - Creation of a groove on the surface of the root (to be used as a purchase point for positioning the elevator), after removal of a small amount of buccal bone.
  - Creation of a groove between the root and bone, which allows for positioning of the elevator.

When the tooth is single-rooted and the level of the root is below the margin of alveolar bone, an L-shaped incision is made, the flap is reflected, and a large part of the buccal bone is removed using a round bur until the root is exposed. The root is then luxated using a straight elevator, which is placed palatally in the gingival sulcus (when it involves the maxilla). The root is mobilized easily, using rotational movements with the elevator and applying a small amount of pressure outwards. After smoothing the bone margins, the surgical field is irrigated with saline solution and, after repositioning the flap, the wound is sutured.

### Complication of Extraction

Undesirable situations are often encountered in dental practice, caused by a dentist's mistake, culpability of the patient, or other unstable factors.

**Perioperative complications** are the complications that occur during the surgical procedure, while **postoperative complications** occur during the postoperative period.

**Perioperative Complications.** These mainly include:

- Fracture of the crown of the adjacent tooth or luxation of the adjacent tooth
- Soft tissue injuries
- Fracture of the alveolar process
- Fracture of the maxillary tuberosity
- Fracture of the mandible
- Dislocation of the temporomandibular joint
- Subcutaneous or submucosal emphysema
- Hemorrhage
- Displacement of the root or root tip into soft tissues
- Displacement of an impacted tooth, root or root tip into the maxillary sinus
- Oroantral communication
- Nerve injury
- 

**Postoperative Complications.** These include:

- Trismus
- Hematoma

- Ecchymosis
- Edema
- Postextraction granuloma
- Painful postextraction socket
- Fibrinolytic alveolitis (dry socket)
- Infection of wound

### **Fracture of Crown or Luxation of Adjacent Tooth**

The fracture of the crown of an adjacent tooth that presents extensive caries or a large restoration is a common complication during the extraction procedure. Luxation or dislocation of an adjacent tooth occurs when a great amount of force is exerted during the luxation attempt, particularly when the adjacent tooth is used as a fulcrum. The same complication may arise if care is not taken during the extraction of a deciduous molar. In this case, the forceps may grasp the crown of the succedaneous permanent premolar together with the deciduous tooth and luxate it as well.

*Treatment.* When an adjacent tooth is inadvertently luxated or partially avulsed, the tooth is stabilized for approximately 40-60 days. If there is still pain during percussion even after this period, then the tooth must be endodontically treated. If the tooth is dislocated, it must be repositioned and stabilized for 3-4 weeks.

### **Soft Tissue Injuries**

Soft tissue injuries are a common complication and most times are due to the inept or inadvertent manipulation of instruments (e.g., slippage of elevator) during the removal of teeth. The areas most often injured are the cheeks, the floor of the mouth, the palate, and the retromolar area. Injury by the elevator may also occur at the corner of the mouth and lips because of prolonged and excessive retraction force and pressure during the extraction of posterior maxillary and mandibular teeth, especially when patients have a reduced aperture. Furthermore, a burn may occur on the lower lip if an overheated surgical handpiece comes into contact with the lip. Abrasions also happen when the shank of a rotating bur comes into contact with the area.

Another soft tissue injury that can occur sometimes is the tearing of the flap during reflection, as well as tearing of the gingiva during extraction. The latter may occur if the soft tissues surrounding the tooth have not been completely severed or loosened, or if part of the alveolar process is removed together with the tooth, thus tearing the soft tissues attached to the bone to a great extent.

*Treatment.* When injuries are small and localized at the region of the cheek, tongue, or lips, then no particular treatment is considered necessary. In certain cases healing is facilitated if the lesion is covered with any appropriate ointment. This may also lessen the patient's discomfort. When the injury is extensive, though, and there is also hemorrhaging, the surgical procedure must be postponed and the dentist must control the bleeding and proceed with suturing of the wound.

### **Fracture of Alveolar Process**

This complication may occur if extraction movements are abrupt and awkward, or if there is ankylosis of the tooth in the alveolar process, whereupon part of the labial, buccal, palatal or lingual cortical plate may be removed together with the tooth. Fracture of the alveolar process occurs most often during the extraction of canines, especially if the bone of the region has become weak due to injury or because of a previous extraction of the lateral incisor or the first premolar. Fracture of the lingual cortical plate is especially significant, because the lingual nerve may also be traumatized.

*Treatment.* When the broken part of the alveolar process is small and has been reflected from the periosteum, then it is removed with forceps and the sharp edges, if any, of the remaining bone are smoothed. Afterwards, the area is irrigated with saline solution and the wound is sutured. If the broken part of the alveolar process is still attached to the overlying soft tissues, then it may remain after stabilization and suturing of the mucoperiosteum.

### **Fracture of Maxillary Tuberosity**

Fracture of the maxillary tuberosity is a grave complication, which, depending on its extent, may create problems for the retention of a full denture in the future. This complication may occur during the extraction of a posterior maxillary tooth and is usually due to the following reasons:

1. Weakening of the bone of the maxillary tuberosity, due to the maxillary sinus pneumatizing into the alveolar process. In this case, risk of fracture is increased if the extraction of a molar is performed with forceful and careless movements.
2. Ankylosis of a maxillary molar that presents great resistance to movements during the extraction attempt.

### **Dislocation of Temporomandibular Joint**

This complication may occur during a lengthy surgical procedure on patients who present a shallow mandibular fossa of the temporal bone, low anterior articular tubercle, and round head of condylar process. In unilateral dislocation the mandible deviates towards the healthy side, while in bilateral dislocation, the mandible slides forward in a gaping prognathic position. The patient is unable to close their mouth (open bite) and movement is restricted. In order to avoid such a complication, the mandible must be firmly supported during an extraction and patients must avoid opening their mouth excessively, especially those with a history of habitual temporomandibular joint luxation.

*Treatment.* Immediately after the dislocation, the thumbs are placed on the occlusal surfaces of the teeth, while the rest of the fingers surround the body of the mandible right and left. Pressure is then exerted downward with the thumbs and simultaneously upwards and posteriorly with the rest of the fingers, until the condyle is replaced in its original position. After repositioning, the patient must limit any movement of the mandible that may lead to excessive opening of the mouth for a few



days. When luxation is habitual, the mandible is often repositioned in its original position spontaneously.

### **Bleeding**

Hemorrhage is a common complication in oral surgery, and may occur during a simple tooth extraction or during any other surgical procedure. In all cases, hemorrhage may be due to trauma of the vessels in the region as well as to problems related to blood coagulation. Profuse hemorrhage may occur as a result of injury or severance of the inferior alveolar vessels or the palatal artery.

Severe hemorrhagic diatheses (e.g., hemophilia, etc.) should be ascertained by taking a thorough medical history, and management must be planned before the surgical procedure.

Postoperative bleeding in healthy patients may be the result of poor hemostasis of the wound due to insufficient compression, or to inadequate removal of inflammatory and hyperplastic tissue from the surgical field.

*Treatment.* The main means of arresting bleeding are compression, ligation, suturing, electrocoagulation and the use of various hemostatic agents.

*Compression* aims at causing vasoconstriction and decreasing the permeability of the capillaries, and is achieved by placing gauze over the bleeding site with pressure. Placing pressure by biting on a gauze for 10-30 min over the postextraction wound or other superficial bleeding areas is usually sufficient. If the bleeding does not stop after applying pressure for the aforementioned time, then there is a hemorrhagic problem to a certain degree and blood flow must be arrested, depending on the case. Bone hemorrhage is adequately treated by means of compression of the bone surrounding the vessel, in order to obstruct blood flow. This may be achieved by using a mallet and a small blunt instrument. Sterile bone wax may also be used to arrest bone bleeding, which is placed with pressure inside the bleeding bone cavity. Packing iodoform gauze, which also has antiseptic properties, inside the alveolus may arrest bone bleeding as well. This gauze may remain inside the cavity, depending on the case, for between 10 min and 3-4 days, after which it is removed.

*Suturing* the wound mechanically obstructs the severed end of the bleeding vessel. This technique is used for arresting soft tissue hemorrhage as well as postextraction bleeding that is treated with tightly suturing the wound margins. If it is impossible to coapt the wound margins, a gauze pack is placed over the wound, which is stabilized with sutures over the postextraction socket for 2-3 days.

*Ligation* is the most successful way to control soft tissue hemorrhage that involves a large vessel. If, for example, a large vessel is severed during the surgical procedure, a hemostat is used to clamp and ligate the vessel. If a small-sized vessel is bleeding, then a narrow hemostat is used to clamp the bleeding area of the soft tissues, arresting hemorrhage within a few minutes, without ligation of the tissues.

*Electrocoagulation* is based on the coagulation of blood through the application of heat, resulting in the retraction of tissues in a necrotic mass.

*Hemostatic materials*, such as vasoconstrictors (adrenaline), alginic acid, desiccated alum, etc., have proven to be very effective in the control of bleeding. These materials are used to arrest capillary hemorrhage and are used topically over the bleeding area. Other materials are also used, such as fibrin sponge, gelatin sponge, oxidized cellulose, etc., whose hemostatic properties cause blood coagulation by creating a normal blood clot at the severed ends of the bleeding vessels. These materials are suitable only for local application and are used to arrest generalized capillary bleeding, especially to control bleeding of the postextraction alveolus. The procedure for using the hemostatic agents is usually as follows. In the case of a relatively small hemorrhage, which persists despite biting on a gauze pack over the postextraction wound, an absorbable hemostatic sponge is placed inside the alveolus and pressure is applied over the gauze, or the wound margins are sutured with a figure-eight suture.

It is difficult for the dentist alone to control bleeding in patients with a hemorrhagic diathesis. In such cases, after adhering to the specified aforementioned measures, a pressure pack is placed over the wound and the patient is referred to a hospital for more effective treatment (administration of replacement factors, etc.).

### **Displacement of Root into Soft Tissues**

This complication may occur in the following situations:

- When the buccal or lingual cortical plate, as well as the root tip region of maxillary posterior teeth is eroded. In this case, the root or root tip may easily be displaced during luxation towards the buccal soft tissues or the floor of the mouth, or between the bone and mucosa of the maxillary sinus, respectively.
- In the case of perforation of the bone as a result of continuous attempts to remove the root tip, which may be displaced as described above.

*Treatment.* Removal of the root tip, especially from buccal soft tissues, is not particularly difficult if its exact position has been localized. This localization is achieved with careful palpation of the area suspected of containing the displaced root tip.

Displacement of the root tip between bone and the mucosa of the maxillary sinus does not usually require any treatment. The root tip usually remains in this position and the patient is given antibiotics. The exact position of the root tip must be verified, though, to make sure that it is not inside the maxillary sinus. If the root tip has been displaced into the floor of the mouth, its exact position must be verified clinically and radiographically, because the area's anatomy complicates the removal procedure.

### **Displacement of Tooth or Root into Maxillary Sinus**

This complication may occur particularly during an attempt to luxate an impacted maxillary third molar, when the impacted tooth is close to the maxillary sinus and the surgical procedure has not been carefully planned. In order to avoid such a complication, exposure of the impacted tooth must be adequate in terms of the extent of the flap and the amount of bone removed, so that the forces exerted during luxation

are maximally controlled. A root or root tip (usually the palatal root of a molar) may also be displaced into the maxillary sinus during the removal attempt.

*Treatment.* If the tooth or root tip cannot be removed with the surgical technique immediately after the complication arises, any attempt to find the tooth or root tip with various instruments must be avoided and the patient should be informed of the situation. Antibiotic treatment and nasal decongestants are also administered, and surgical removal is scheduled. It must be treated as soon as possible, because there is a risk of infection of the maxillary sinus, which usually worsens due to the existing oroantral communication. The exact position of the tooth or root tip must be confirmed with radiographic examination. Removal of the tooth or root from the maxillary sinus is usually achieved with trephination of the maxillary sinus using a Caldwell–Luc approach.

### **Oroantral Communication**

This is a common complication, which may occur during an attempt to extract the maxillary posterior teeth or roots. It is identified easily by the dentist, because the periapical curette enters to a greater depth than normal during debridement of the alveolus, which is explained by its entering the maxillary sinus. Oroantral communication may also be confirmed by observing the passage of air or bubbling of blood from the postextraction alveolus when the patient tries to exhale gently through their nose while their nostrils are pinched (Valsalva test). If the patient exhales through their nose with great pressure, there is a risk of causing oroantral communication, even though communication may not have occurred initially, such as when only the mucosa of the maxillary sinus is present between the alveolus and the antrum.

Oroantral communication may be the result of:

1. Displacement of an impacted tooth or root tip into the maxillary sinus during a removal attempt.
2. Closeness of the root tips to the floor of the maxillary sinus. In this case the bony portion above the root tips is very thin or may even be absent, whereupon oroantral communication is inevitable during extraction of the tooth, especially if the alveolus is debrided unnecessarily.
3. The presence of a periapical lesion that has eroded the bone wall of the maxillary sinus floor.
4. Extensive fracture of the maxillary tuberosity (during the extraction of a posterior tooth), whereupon part of the maxillary sinus may be removed together with the maxillary tuberosity.
5. Extensive bone removal for extraction of an impacted tooth or root.

*Preventive Measures.* In order to avoid oroantral communication as well as displacement of an impacted tooth or root into the maxillary sinus, the following preventive measures are recommended:

- Radiographic examination of the region surrounding the tooth to be extracted
- Careful manipulations with instruments, especially during the luxation of a root tip of a maxillary posterior tooth

- Careful debridement of periapical lesions that are close to the maxillary sinus
- Avoiding luxation of the root tip if visualization of the area is hindered by hemorrhage

The technique of immediate closure with a flap procedure is indicated when the sinus is free of disease. In this case, the oroantral fistula is covered, without operating on the antrum also. However, when infection of the maxillary sinus is present, the flap procedure technique is performed together with trephination of the antrum.

Oronasal communication may also occur, either labially or palatally. In the first case, the complication may occur especially during the surgical removal of impacted canines with a labial localization, during apicoectomies, etc. In the latter case, the communication occurs during the attempt to remove cysts, palatal exostoses, and deeply impacted canines.

*Treatment.* The management of oroantral communication depends on its size and when treatment is to be scheduled.

For a small-sized oroantral communication, which is perceived immediately after the extraction, treatment consists of suturing the gingiva with a figure-eight suture after filling the alveolus with collagen, unless there are enough soft tissues, in which case placement of tight sutures over the wound is preferred.

When the soft tissues do not suffice, a small portion of the alveolar bone is removed with a bone rongeur so that the buccal and palatal mucosa can be reapproximated more easily, facilitating closure of the oroantral communication. Infection of the maxillary sinus is thus avoided, and the blood clot is held in place, which will aid in the healing process. The same procedure applies to the closure of larger-sized oroantral communications.

The administration of prophylactic antibiotics is not deemed necessary, unless the oroantral communication is the result of an extraction of a tooth with acute periapical inflammation, upon which broad-spectrum antibiotics must be administered. Nasal de-congestants must also be prescribed. The patient is informed of the situation, and given appropriate instructions (e.g., avoiding sneezing, blowing nose), and is rescheduled for examination in 15 days.

A large oroantral communication or one that has remained open for 15 days or longer must be treated using other techniques (such as the closure with flap procedure, either immediately or at a later date), which ensure restoration. These techniques are achieved using pedicle mucoperiosteal flaps (buccal, palatal, and bridge flaps).

### **Nerve injury**

Nerve injury, especially the severance of large nerve branches, is one of the most serious complications that may occur during oral surgical procedures. The most common nerve injuries are of the inferior alveolar, mental, and lingual nerves. Nerve trauma may cause sensory disturbances in the innervated area, such as: anesthesia or hypesthesia, paresthesia, dysesthesia. Anesthesia or hypesthesia: loss or decrease,

respectively, of sensation in an area. Paresthesia: subjective sensation of burning, tingling, needles and pins, numbness, etc. Dysesthesia: abnormal unpleasant sensation to normal stimulus, e.g., burning sensation to simple touch.

Resulting in various undesirable situations, such as a burning sensation, tingling, needles and pins, biting of the tongue and lips, abnormal chewing, burns through consumption of hot foods, etc.

Before describing the complications, basic information involved in the classification of nerve injuries is provided, so that the diagnosis, prognosis, and treatment may be more easily understood.

There are three types of nerve damage: neurapraxia, axonotmesis, and neurotmesis.

1. *Neurapraxia*: This type of damage has the most favorable prognosis and may occur even after simple contact with the nerve. Nerve conduction failure is usually temporary and there is complete recovery, without permanent pathologic and anatomic defects. Recovery is quite rapid and occurs gradually within a few days to weeks.

2. *Axonotmesis*: This is a serious injury of the nerve resulting in degeneration of the nerve axons, without anatomic severance of the endoneurium. Regeneration and recovery of sensation is slower than in neurapraxia and usually begins as paresthesia 6-8 weeks after injury. Regeneration of the nerve maybe exceptionally favorable, but there is a chance of a certain degree of sensory disturbance of the area remaining.

3. *Neurotmesis*: This is the gravest type of nerve injury resulting in discontinuation of conduction due to severance of the nerve or due to the formation of scar tissue at the area of trauma. Neurotmesis maybe produced by: trauma of the nerve branch due to traction, ischemia due to prolonged compression, severance or tearing of the nerve, as well as certain chemical substances. This type of injury may cause permanent damage to nerve function, including paresthesia or even anesthesia. The formation of scar tissue may also prevent axon regeneration.

*Etiology*. Nerve injury may occur in the following cases:

- During administration of a nerve block (rarely) of the inferior alveolar nerve and mental nerve.
- While creating an incision that extends to the region of the mental foramen and the lingual vestibular fold.
- While creating an incision at the alveolar ridge of an edentulous patient, whose mental foramen, due to bone resorption, is localized superficially.
- During excessive flap retraction and compression with retractors during retraction in the region of the mental nerve or at the lingual region of the third molar.
- When bone near a nerve is excessively heated, if the bur of the surgical handpiece is not irrigated with a steady stream of saline solution.

- In the case of removal of impacted teeth, roots and root tips that are deep in the bone and are close to the mental or inferior alveolar nerves.
- During perforation of the lingual cortical plate, when roots of a posterior tooth are sectioned or if a crown of an impacted third molar is sectioned (injury to lingual nerve).

*Treatment.* No particular therapy is indicated for neurapraxia or axonotmesis, unless there is a root tip or other foreign body compressing the nerve, in which case it must be removed. Treatment is usually palliative, including the administration of analgesics in painful situations, and multi-vitamin supplements of the vitamin B complex to restore sensation more rapidly. Damage to the nerve as a result of neurotmesis must be treated as soon as possible; often, a graft must replace the injured nerve segments or the severed segments must be sutured.

### **Trismus**

Trismus usually occurs in cases of extraction of mandibular third molars, and is characterized by a restriction of the mouth opening due to spasm of the masticatory muscles. This spasm may be the result of injury of the medial pterygoid muscle caused by a needle (repeated injections during inferior alveolar nerve block) or by trauma of the surgical field, especially when difficult lengthy surgical procedures are performed. Other causative factors are inflammation of the postextraction wound, hematoma, and postoperative edema.

*Treatment.* The management of trismus depends on the cause. Most cases do not require any particular therapy. When acute inflammation or hematoma is the cause of trismus, hot mouth rinses are recommended initially, and then broad-spectrum antibiotics are administered. Other supplementary therapeutic measures include:

- Heat therapy, i.e., hot compresses are placed extra-orally for approximately 20 min every hour until symptoms subside
- Gentle massage of the temporomandibular joint area
- Administration of analgesics, anti-inflammatory and muscle relaxant medication
- Physiotherapy lasting 3-5 min every 3-4 h, which includes movements of opening and closing the mouth, as well as lateral movements, aimed at increasing the extent of mouth opening

Administration of sedatives, for management of stress, which worsens while trismus persists, leading to an increase of muscle spasm in this area.

### **Hematoma**

This is a quite frequent postoperative complication due to prolonged capillary hemorrhage, when the correct measures for control of bleeding are not taken (ligation of small vessels, etc.). In this case blood accumulates inside the tissues, without any escape from the closed wound or tightly sutured flaps under pressure. Depending on the operation, the hematoma may be submucosal, subperiosteal, intramuscular or fascial.

As for patients with hemorrhagic diatheses, hematomas formed in the palatopharyngeal arches are considered most dangerous of all.

*Treatment.* If a hematoma is formed during the first few hours after the surgical procedure, therapeutic management consists of placing cold packs extra orally during the first 24 h, and then heat therapy to help it to subside more rapidly. Some people recommend the administration of antibiotics to avoid suppuration of the hematoma, and analgesics for pain relief.

### **Painful Postextraction Socket**

This is a common complication, which occurs immediately after the anesthetic wears off. It occurs mainly at the postextraction wound of mandibular posterior teeth, although maxillary posterior teeth may also be involved, due to the anatomy of the bone (dense), where sharp bony spicules are easily created, especially if the extractions are difficult and are performed with awkward manipulations. The uneven bone edges injure the soft tissues of the postextraction socket, resulting in severe pain and inflammation at the extraction site. In this case, the alveolus is filled with a blood clot that becomes organized for postextraction healing, but not for development of epithelium that will cover the wound.

*Treatment.* This complication is treated with smoothing of the bone margins of the wound, especially the intraradicular bone. In addition to giving the patient analgesics, gauze impregnated with eugenol should be placed over the wound margins for 36-48 h.

### **Fibrinolytic Alveolitis (Dry Socket)**

This postoperative complication appears 2-3 days after the extraction. During this period, the blood clot disintegrates and is dislodged, resulting in delayed healing and necrosis of the bone surface of the socket. This disturbance is termed fibrinolytic alveolitis and is characterized by an empty socket, fetid breath odor, a bad taste in the mouth, denuded bone walls, and severe pain that radiates to other areas of the head.

As for the etiology and pathogenesis of dry socket, various factors have been cited, some of which include dense and sclerotic bone surrounding the tooth, infection during or after the extraction, injury of the alveolus, and infiltration anesthesia.

*Treatment.* This type of complication is treated by gently irrigating the socket with warm saline solution, and placing gauze impregnated with eugenol, which is replaced approximately every 24 h, until the pain subsides. Also, gauze soaked in zinc-oxide/eugenol may be used, which remains inside the alveolus for 5 days; alternatively iodoform gauze or enzymes are applied locally. With this palliative treatment, the pain gradually subsides, and the patient is given instructions to avoid mastication on the affected side while good oral hygiene is emphasized.

### **Infection of Wound**

Infection of the wound is a complication that may present and spread not only to the superficial surgical wound, but also to the depth and extent of the

tissues involved in the surgical manipulations. Infection of the wound may be caused by:

- The use of infected instruments and disposable materials during the surgical procedure.
- A septic substrate over which the surgical procedure is performed.
- Systemic diseases which lead to increased susceptibility to infection (e.g., leukemia, agranulocytosis), as well as those diseases whose therapy causes immunosuppression. According to past studies, diabetes mellitus is also included in these systemic diseases. Today, though, specialists do not agree with this point of view and consider that patients with controlled diabetes should not be treated in the same way as those patients who suffer from the aforementioned diseases.

When the dentist deems that there is a risk of developing a postoperative infection, prophylactic antibiotics are administered. If the wound has already become infected though, the appropriate antibiotic therapy should be administered, depending on the case.

### **Disturbances in Postoperative Wound Healing**

Wound healing disturbances after a surgical procedure may be caused by general or local factors. General factors include blood diseases (agranulocytosis, leukemia), diabetes mellitus, Paget's disease, osteoporosis, etc. Local factors include wound infection, inflammatory hyperplastic granuloma, dry socket, irradiated region, benign and malignant neoplasms, wound damage caused by instruments (burs and elevators), and flap dehiscence due to rupture of sutures.

## **2. TAPPING OF SUBPERIOSTEAL ABSCESSSES IN JAWS**

The subperiosteal abscess involves limited accumulation of pus that is semifluctuant. It is located between bone and the periosteum, at the buccal, palatal, or lingual region, relative to the tooth responsible for the infection. This type of abscess is the result of spread of an intraalveolar abscess, when the pus perforates the bone and becomes established underneath the periosteum.

**Instruments:** Scalpel, Pean's Forceps, Anatomical Tweezers, Surgical Tweezers, Bulbous-end Probe, Mouth Mirror, Syringe for Irrigating Surgical Field.

**Surgical Technique.** This abscess is treated after adequate anesthesia with an intraoral incision and drainage. The incision is performed on the mucosa, taking into consideration the course of the vessels and nerves in the region (mental nerve and palatal vessels and nerves) in order to avoid injury. The scalpel blade reaches bone, to ensure greater drainage of pus. At palatal localization of subperiosteal abscesses, soft tissues in the center of abscess are cut to the bone in a wedge-like section, 2-3 mm wide to prevent adhesion of the wound edges and provide outflow of purulent exudate. When tapping subperiosteal abscess in mandible from lingual sides, one should remember about the possibility of traumatizing lingual artery and duct of submandibular salivary gland.



### 3. APICOECTOMY

Apicoectomy is the surgical resection of the root tip of a tooth and its removal together with the pathological periapical tissues. Accessory root canals and additional apical foramina are also removed in this way, which may occur in the periapical area and which may be considered responsible for failure of an endodontic therapy.

**Instruments.** Microhead Handpiece (straight and contra-angle) and Microbur, Appropriate Burs (round, fissure, inverted cone), Special Narrow Periapical Curette Tips for Preparation of the Periapical cavity, Scalpel Handle, Scalpel Blade, Mirror, Periosteal Elevator, Small Hemostat, Suction Tips (small, large), Retractors, Periodontal curette, Periapical curette, Needle Holder, Scissors, Needles no. 3-0 and 4-0 sutures, Syringe for Irrigating Surgical Field.

#### **Surgical Technique**

1. Designing of flap.
2. Localization of apex, exposure of the periapical area and removal of pathological tissue.
3. Resection of apex of tooth.
4. Retrograde filling, if deemed necessary.
5. Wound cleansing and suturing.

#### **Designing of Flap**

Flap design depends on various factors, which mainly include position of the tooth, presence of a periodontal pocket, presence of a prosthetic restoration, and the extent of the periapical lesion.

There are three types of flaps principally used for apicoectomy: the semilunar, triangular, and trapezoidal. The semilunar flap is indicated for surgical procedures of limited extent and is usually created at the anterior region of the maxilla, which is where most apicoectomies are performed. In order to ensure optimal wound healing, the incision must be made at a distance from the presumed borders of the bony defect, so that the flap is repositioned over healthy bone. If there is an extensive bony defect, especially towards the alveolar crest, then the triangular or trapezoidal flap is preferred. It must be noted that the pathological lesion, which has perforated the bone and has become attached to the periosteum, must be separated from the flap with a scalpel. In case of a fistula, the fistulous tract must also be excised near the bone, because, if it is excised at the mucosa, then there is risk of even greater perforation, resulting in disturbances of the healing process.

When the apicoectomy is performed at the anterior region (e.g., maxillary lateral incisor) and there is an extensive bony defect near the alveolar crest, the surgical procedure is performed using a trapezoidal flap. The incision for creating the flap begins at the mesial aspect of the central incisor and, after continuing around the cervical lines of the teeth, ends at the distal aspect of the canine. With a periosteal elevator, the mucoperiosteum is then carefully reflected upwards.

**Localization and Exposure of Apex.** The next step after creating a flap is localization and exposure of the apex. When the periapical lesion has perforated the buccal bone, localization and exposure of the root tip is easy, after removing the

pathological tissues with a curette. If the buccal bone covering the lesion has not been completely destroyed, but is very thin, then its surface is detected with an explorer or dental curette, whereupon, due to decreased bone density, the underlying bone is easily removed and the apex localized. When the buccal bone remains completely intact, then the root tip may be located with a radiograph. More specifically, after taking a radiograph, the length of the root is determined with a sterilized endodontic file or metal endodontic ruler. The length measured is then transferred to the surgical field, determining the exact position of the root tip. Afterwards, with a round bur and a steady stream of saline solution, the bone covering the root tip is removed peripherally, creating an osseous window until the apex of the tooth is exposed. If the overlying bone is thin and the pathological lesion is large, the osseous window is enlarged with a blunt bur or a rongeur. Enough bone is removed until easy access to the entire lesion is permitted. A curette is then used to remove pathological tissue and every foreign body or filling material, while resection of the root tip follows.

**Resection of Apex of Tooth.** The apex is resected (2-3 mm of the total root length) with a narrow fissure bur and beveled at a 45° angle to the long axis of the tooth. For the best possible visualization of the root tip, the beveled surface must be facing the dental surgeon. After this procedure, the cavity is inspected and all pathological tissue is meticulously removed by curettage, especially in the area behind the apex of the tooth. If the entire root canal is not completely filled with filling material or if the seal is inadequate, then retrograde filling is deemed necessary.

**Wound Cleansing and Suturing of Flap.** After copious irrigation with saline solution, the flap is repositioned and interrupted sutures are placed. Healing of the periapical area is checked every 6-12 months radiographically, until ossification of the cavity is ascertained. In order to evaluate the result, a preoperative radiograph is necessary, which will be compared to the postoperative radiographs later.

### **Complications**

The most common complications that may occur during apicoectomy are:

- Damage to the anatomic structures in case of penetration of the nasal cavity, maxillary sinus and mandibular canal with the bur.
- Bleeding from the greater palatine artery during apicoectomy of palatal root.
- Healing disturbances, if the semilunar incision is made over the bony deficit or if the flap, after reapproximation, is not positioned on healthy bone.
- Dislodged filling material due to superficial placement, as a result of insufficient preparation of apical cavity.
- Incomplete root resection, due to insufficient access or visualization and misjudged length of root. As a result, the apical portion of the root remains in position and the retrograde filling is placed improperly, with all the resulting consequences.

#### **4. REMOVAL OF STONE FROM DUCT OF SUBMANDIBULAR GLAND**

Sialolithiasis may occur in the ducts of large salivary glands or in the parenchyma of the glands themselves. Of these glands, the submandibular is the most common site of occurrence compared to the parotid and sublingual glands. Fifty per cent of sialoliths (stones) of the submandibular gland are located at the anterior portion and the middle of the gland, another 35% at its posterior portion, and the remaining 15% inside the gland itself. Sialolithiasis is the most common cause of inflammation of the gland, resulting in sialadenitis. If this condition is not treated, it becomes chronic with frequent recurrences, and may lead to destruction of the gland.

**Instruments:** Scalpel, Spatula, Farabeuf Retractor, Salivary Probes, Tweezers, Hemostatic Clamp, Curette Spoon, Scissors, Needle-holder, Sutural Material.

**Surgical Technique.** The procedure for removal of sialolith which located inside the duct of the submandibular salivary gland is as follows. After local anesthesia, an incision is made on the mucosa of the floor of the mouth along the length of the duct, while the floor of the mouth is extraorally simultaneously pushed upwards. The incision is 1-1.5 cm long and is made exactly over the position of the sialolith. After localization and preparation of the duct, a traction suture is placed underneath the duct and posterior to the sialolith, to facilitate the incision procedure, but also to avoid distant displacement of the sialolith. Afterwards, the suture is retracted upwards and an incision is made at the duct along its long axis, resulting in spontaneous exposure of the sialolith, which is removed with a curette or a hemostat. The wound is then sutured with interrupted sutures at the mucosa only, without including the duct. During the surgical procedure, the dentist must pay particular attention to the proper preparation of the duct, in order to avoid risk of severance, which would result in chronic sialadenitis. Also, care must be taken when the sialolith is located in a posterior area, where the duct is in close proximity to the lingual nerve. Careful manipulations must also be performed in such a case with the aforementioned technique, because injury or severance of the nerve would result in permanent hypesthesia or anesthesia of the respective half of the tongue.

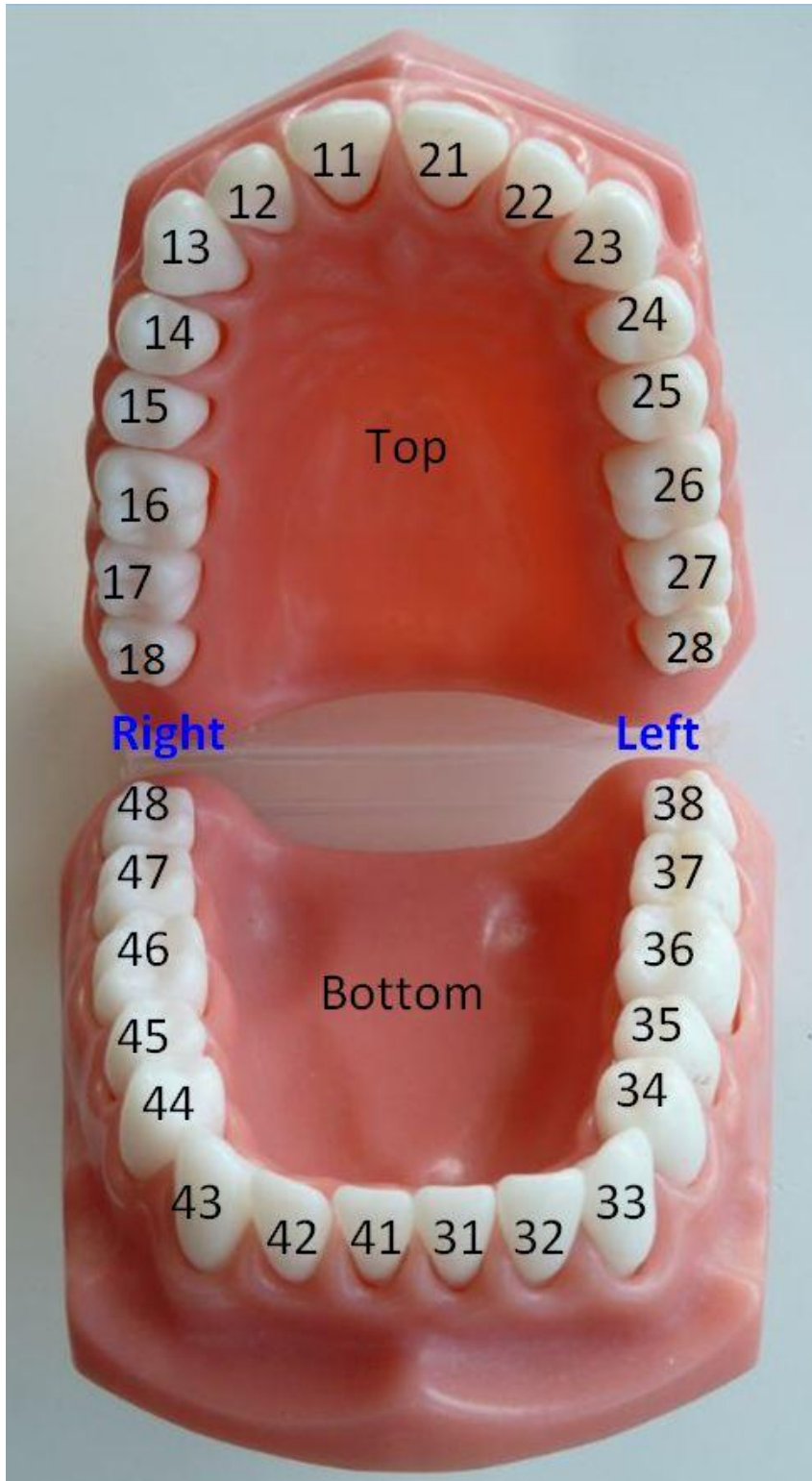## APPENDIX 1.

### LIST of practical skills on clinical practice on surgical stomatology

List of practical skills	Planned
<b>Accepted patients, total amount</b>	60
Total amount of primary patients	40
Total amount of secondary patients	20
<b>Block anesthesia(total amount), including:</b>	72
Tuberal anesthesia	10
Infraorbital anesthesia	5
Anterior palatine nerve block	20
Nasopalatine nerve block	20
Mandibular anesthesia	10
Torusal anesthesia	5
Mental anesthesia	2
<b>Terminal (Infiltration)</b>	35
<b>Simple teeth and root extraction</b>	60
<b>Surgical teeth and root extraction</b>	2-5
<b>Urgent operation</b>	11-15
Tapping of subperiosteal abscesses in jaws	5
Surgical wound treatment	1
Incision of the soft tissues abscesses	1
Operculotomy at the pericoronitis	2-3
Operculectomy at pericoronitis	2-5
<b>Treatment of complications</b>	7
Postextractional bleeding stopping	1
Hematoma treatment	1
Alveolitis treatment	5
<b>Another kinds of manipulation</b> (debridement of injures, irrigation of purulent wounds, reposition of dislocation of mandible and others)	8-16

**APPENDIX 2.**

**FDI TWO-DIGIT TOOTH IDENTIFICATION CHART**



### APPENDIX 3.

#### SOME FEATURES OF LOCAL ANESTHETIC DRUGS

##### THE DURATION OF ACTION OF LOCAL ANESTHETICS

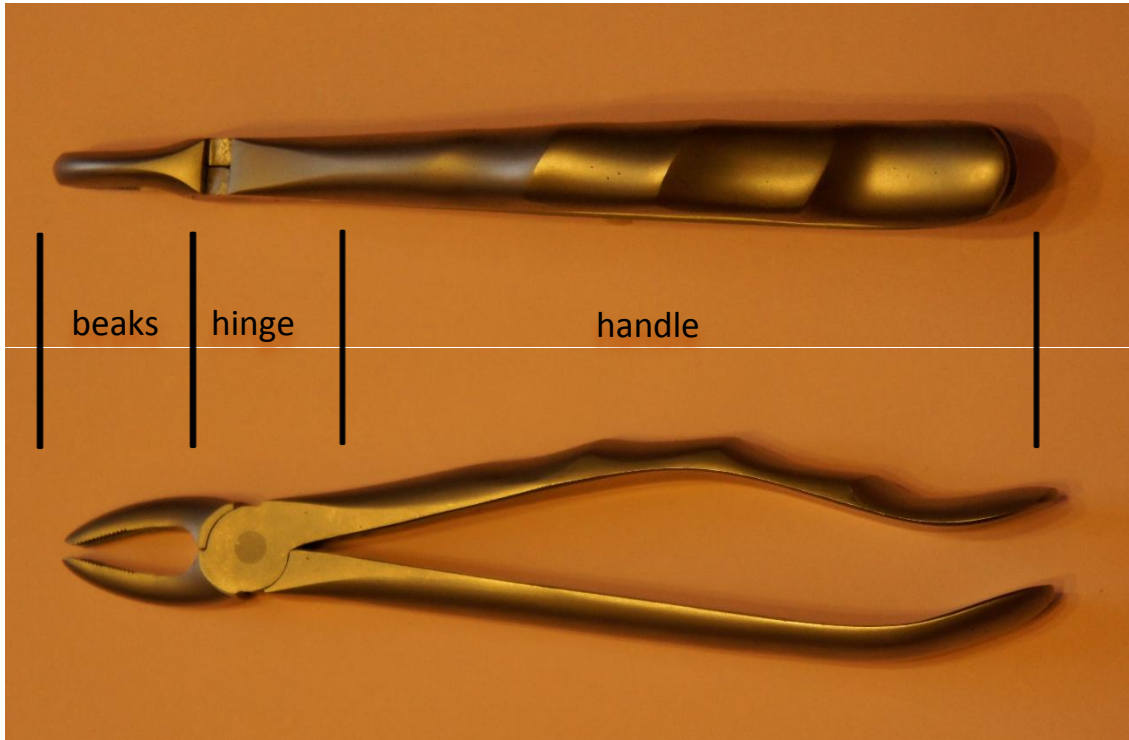
Local anesthetic Drugs	Duration of anesthesia(minutes)	
	Without vasoconstrictor	With vasoconstrictor
Procaine (Novocaine)	15-30	30-40
Lidocaine	30-60	120-130
Mepivacaine	45-90	120-360
Articaine	60	180

##### TOXICITY AND ANESTHETIC ACTIVITY OF LOCAL ANESTHETICS


Local anesthetic Drugs	Toxicity	Anesthetic effect
Procaine (Novocaine)	1	1
Lidocaine	2	4
Mepivacaine	2	4
Articaine	1.5	5

**APPENDIX 4.**

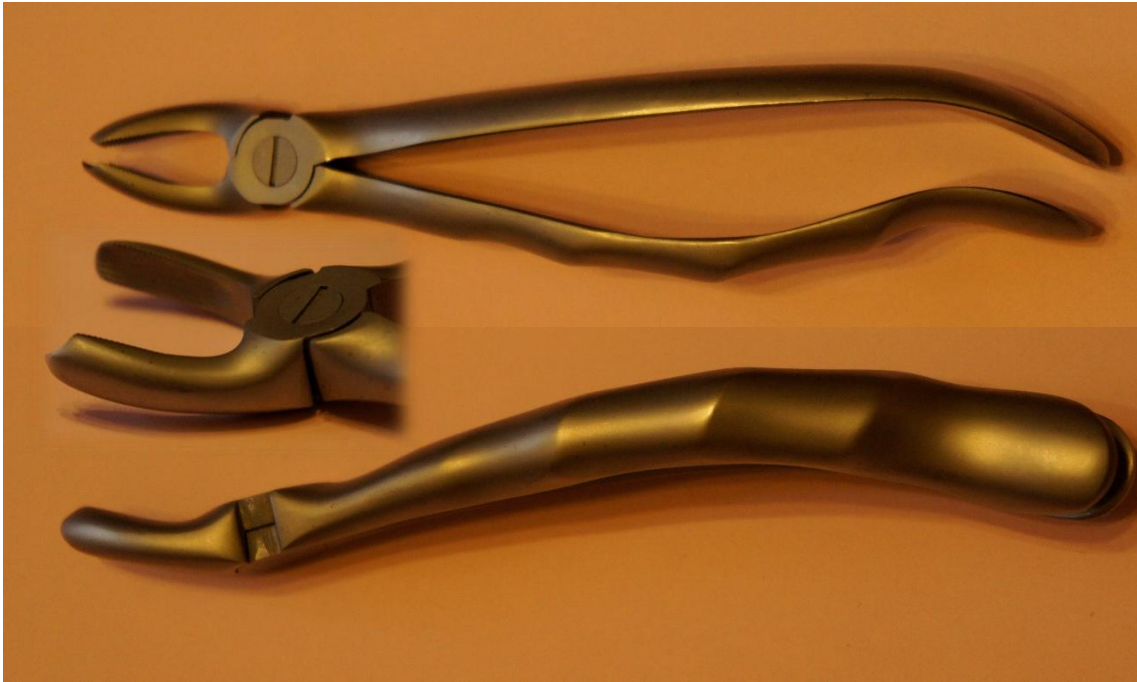
**THE MAIN INSTRUMENTS NECESSARY  
FOR SIMPLE TEETH EXTRACTION**




**Straight Crown Forceps**



**S-shaped Crown Forceps**

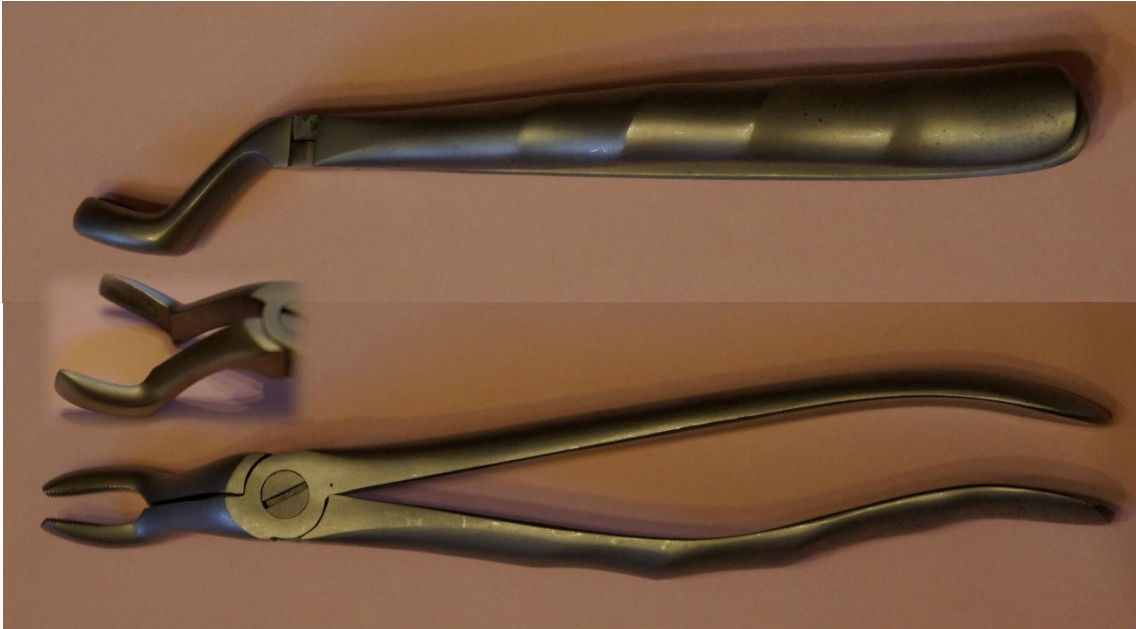


**S-shaped Right Forceps**

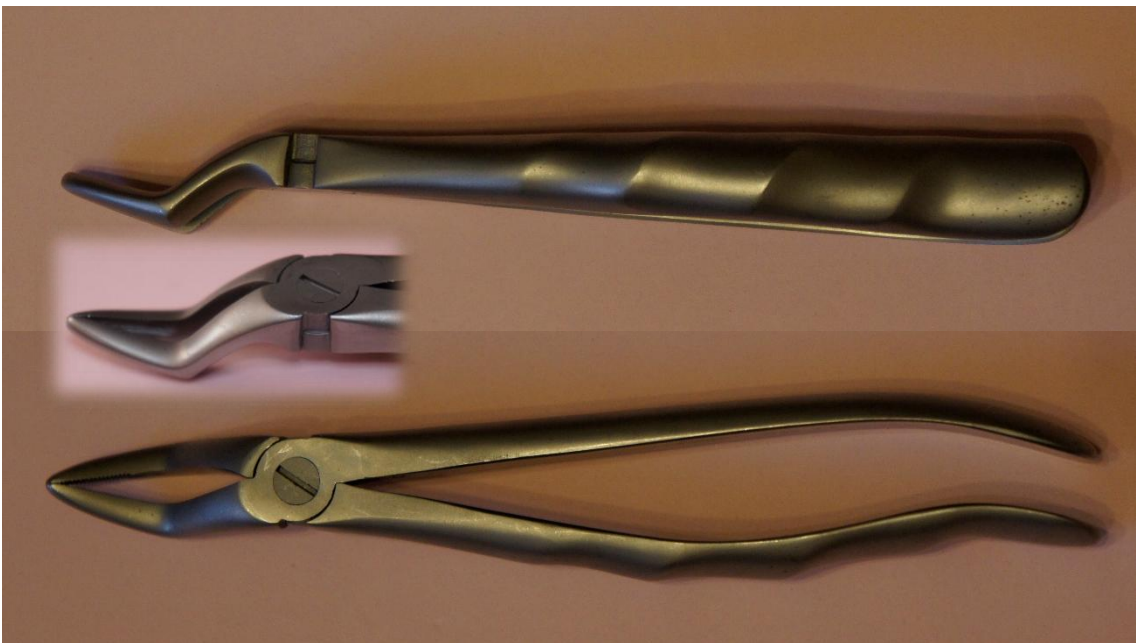


**S-shape Left Forceps**

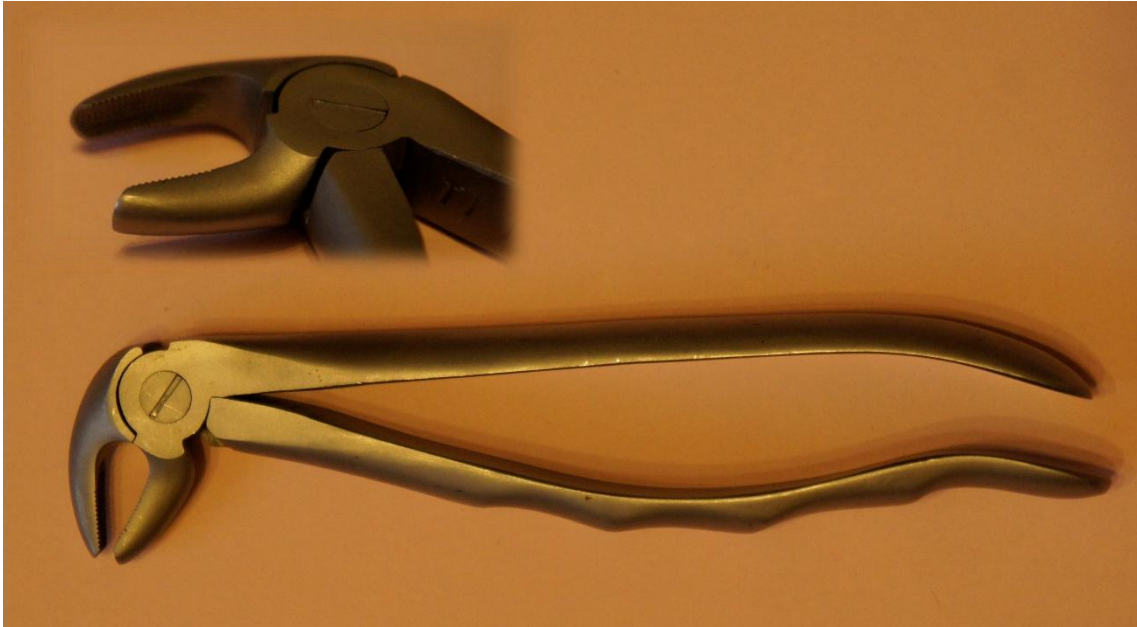




**Bayonet-shaped Crown Forceps**




**Bayonet-shaped Root Forceps**



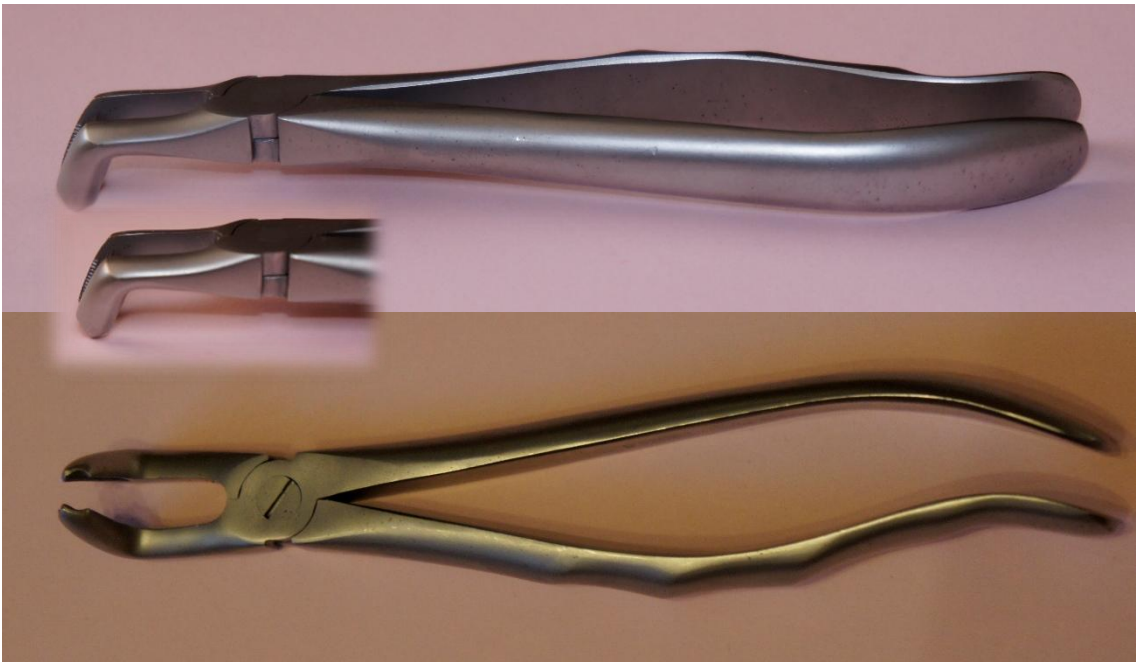
**Beak-shaped Crown Forceps**



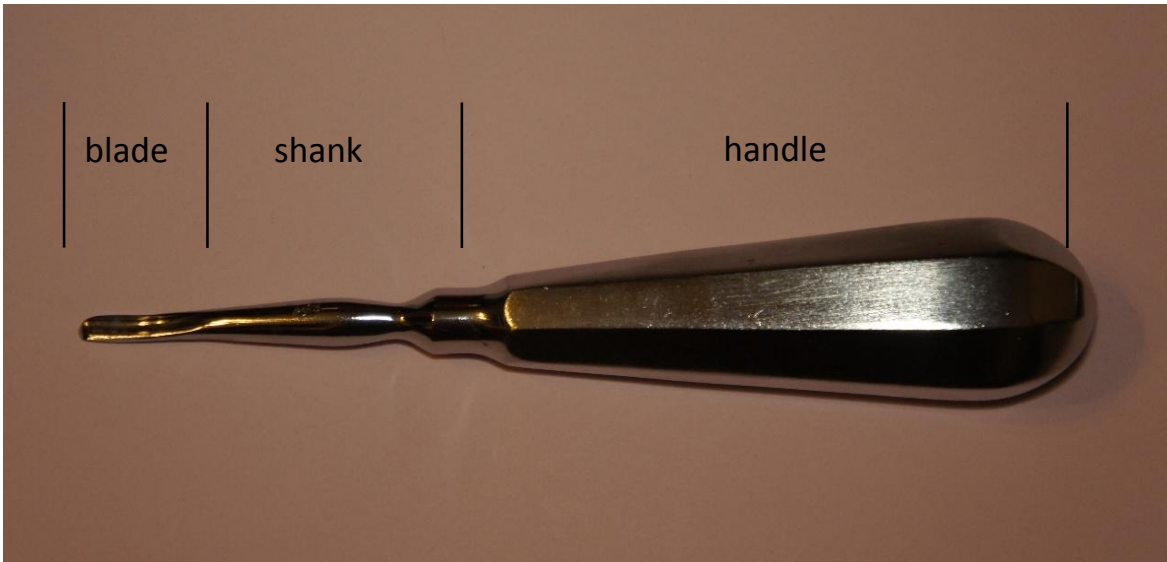
**Beak-shaped Root Forceps**



**Beak-shaped Forceps for Molars**



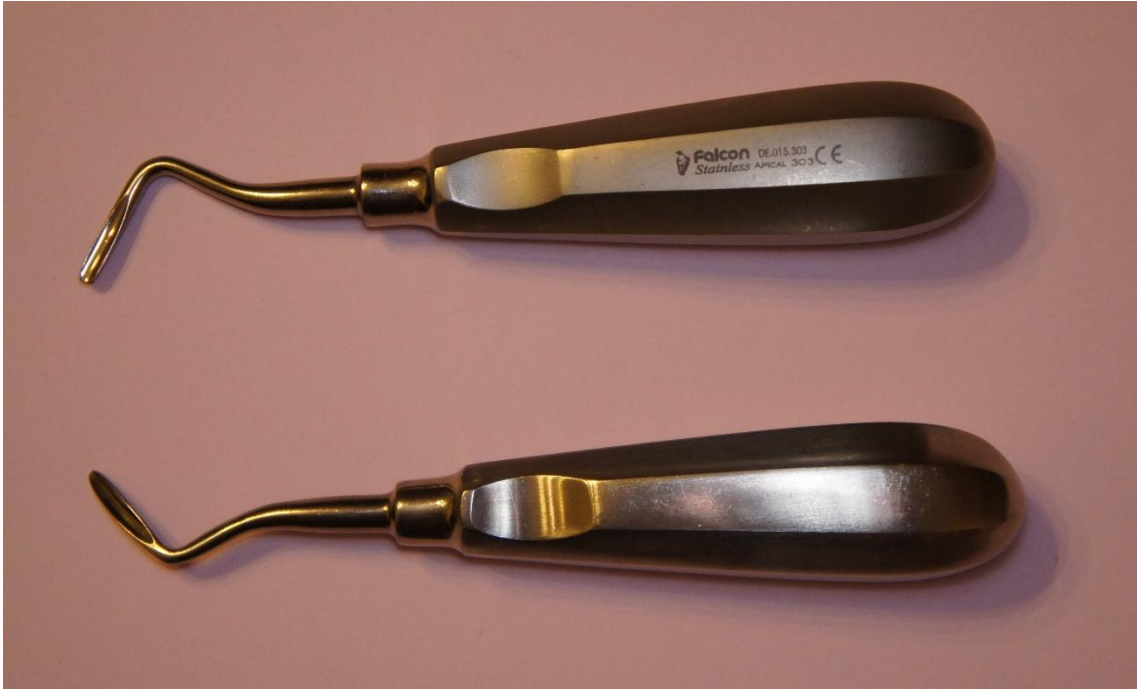**Forceps Curved on the Plane**



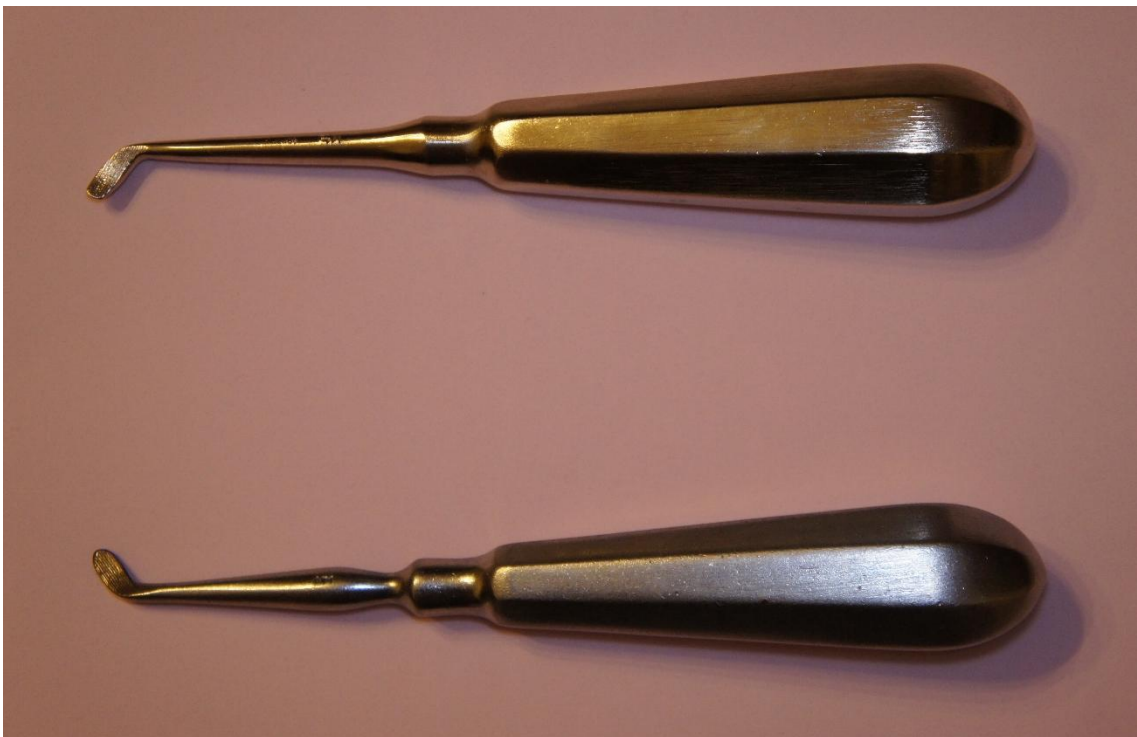**Straight Elevator**



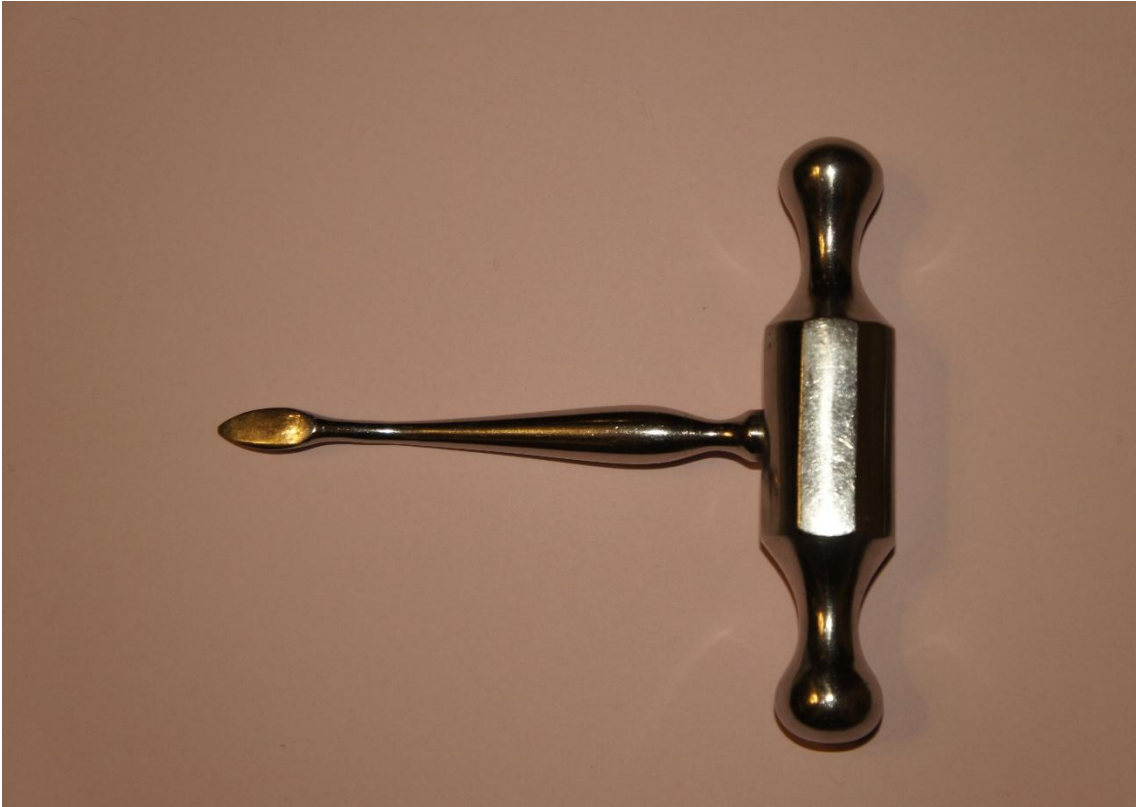**Bayonet-shaped Elevator**



**Pair of Angled Elevators**



**Pair of Angled Elevators**



**Lecluse's Elevator**

**APPENDIX 5.**

**LOCAL ANESTHETIC TECHNIQUES AND INSTRUMENTS  
FOR MAXILLARY TEETH EXTRACTION**

<b>Tooth</b>	<b>Anesthesia</b>	<b>Instruments</b>
<b>MAXILLA</b>		
<b>18, 28</b>	Posterior Superior Alveolar Nerve Block (Tuberosital Anesthesia) and Anterior Palatine Nerve Block (Palatinal Anesthesia)	Bayonet-shaped Crown Forceps or Straight Elevator
<b>Roots of 18, 28</b>	Posterior Superior Alveolar Nerve Block (Tuberosital Anesthesia) and Anterior Palatine Nerve Block (Palatinal Anesthesia)	Bayonet-shaped Root Forceps or Straight Elevator
<b>17, 16</b>	Posterior Superior Alveolar Nerve Block (Tuberosital Anesthesia) and Anterior Palatine Nerve Block (Palatinal Anesthesia)	S-shaped Right Forceps
<b>27, 26</b>	Posterior Superior Alveolar Nerve Block (Tuberosital Anesthesia) and Anterior Palatine Nerve Block (Palatinal Anesthesia)	S-shaped Left Forceps
<b>Roots of 17, 16, 27,26</b>	Posterior Superior Alveolar Nerve Block (Tuberosital Anesthesia) and Anterior Palatine Nerve Block (Palatinal Anesthesia)	Bayonet-shaped Root Forceps or Straight Elevator

<p><b>15, 25</b></p>	<p>1. Anterior and Middle Superior Alveolar Nerves Block (Infraorbital Injection), Posterior Superior Alveolar Nerve Block (Tuberosital Anesthesia) and Anterior Palatine Nerve Block or 2. Plexus Anesthesia and Anterior Palatine Nerve Block (Palatinal Anesthesia)</p>	<p>S-shaped Crown Forceps</p>
<p><b>Roots of 15, 25</b></p>	<p>1. Anterior and Middle Superior Alveolar Nerves Block (Infraorbital Injection), Posterior Superior Alveolar Nerve Block (Tuberosital Anesthesia) and Anterior Palatine Nerve Block (Palatinal Anesthesia) or 2. Plexus Anesthesia and Anterior Palatine Nerve Block (Palatinal Anesthesia)</p>	<p>S-shaped Root Forceps or Bayonet-shaped Root Forceps</p>
<p><b>14, 24</b></p>	<p>1. Anterior and Middle Superior Alveolar Nerves Block (Infraorbital Injection) and Anterior Palatine Nerve Block (Palatinal Anesthesia) or 2. Plexus Anesthesia and Anterior Palatine Nerve Block (Palatinal Anesthesia)</p>	<p>S-shaped Crown Forceps</p>



<p><b>Roots of 14, 24</b></p>	<p>1. Anterior and Middle Superior Alveolar Nerves Block (Infraorbital Injection) and Anterior Palatine Nerve Block (Palatinal Anesthesia) or 2. Plexus Anesthesia and Anterior Palatine Nerve Block (Palatinal Anesthesia)</p>	<p>S-shaped Root Forceps or Bayonet-shaped Root Forceps</p>
<p><b>13, 23</b></p>	<p>Anterior and Middle Superior Alveolar Nerves Block (Infraorbital Injection), Anterior Palatine Nerve Block (Palatinal Anesthesia) and Nasopalatine Nerve Block (Incisive Foramen Injection)</p>	<p>Straight Crown Forceps</p>
<p><b>Roots of 13, 23</b></p>	<p>Anterior and Middle Superior Alveolar Nerves Block (Infraorbital Injection), Anterior Palatine Nerve Block (Palatinal Anesthesia) and Nasopalatine Nerve Block (Incisive Foramen Injection)</p>	<p>Straight Root Forceps or Bayonet-shaped Root Forceps</p>
<p><b>12, 22</b></p>	<p>Anterior and Middle Superior Alveolar Nerves Block (Infraorbital Injection) and Nasopalatine Nerve Block (Incisive Foramen Injection)</p>	<p>Straight Crown Forceps</p>
<p><b>Root of 12, 22</b></p>	<p>Anterior and Middle Superior Alveolar Nerves Block (Infraorbital Injection) and Nasopalatine Nerve Block</p>	<p>Straight Root Forceps or Bayonet-shaped Root Forceps</p>

	(Incisive Foramen Injection)	
<b>11, 21</b>	Anterior and Middle Superior Alveolar Nerves Block (Infraorbital Injection), Nasopalatine Nerve Block (Incisive Foramen Injection) and Infiltration Anesthesia from opposite central incisor	Straight Crown Forceps
<b>Roots of 11, 21</b>	Anterior and Middle Superior Alveolar Nerves Block (Infraorbital Injection), Nasopalatine Nerve Block (Incisive Foramen Injection) and Infiltration Anesthesia from opposite central incisor	Straight Root Forceps or Bayonet-shaped Root Forceps

**APPENDIX 6.**

**LOCAL ANESTHETIC TECHNIQUES AND INSTRUMENTS  
FOR MANDIBULAR TEETH EXTRACTION**

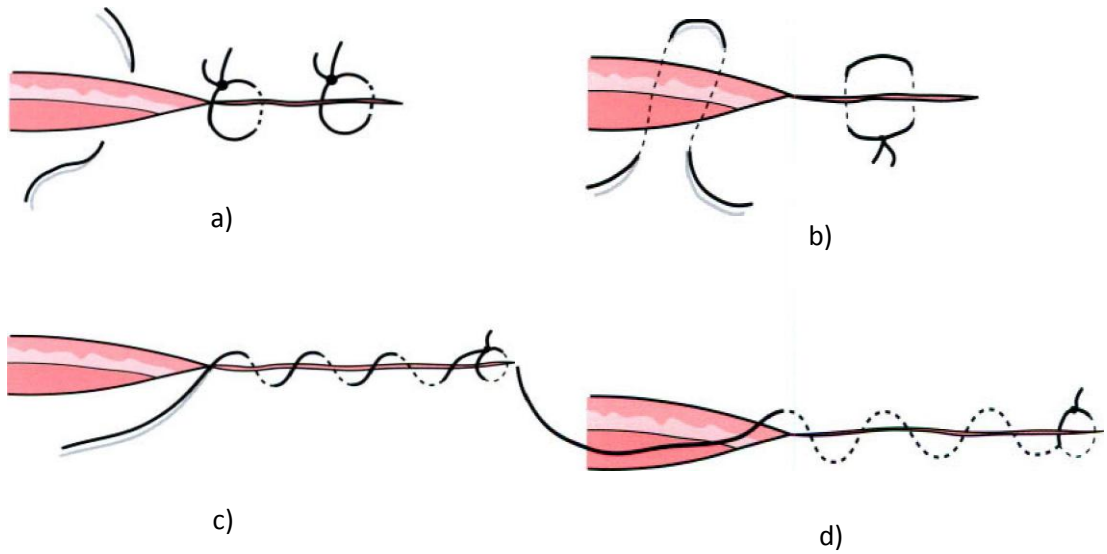
<b>Tooth</b>	<b>Anesthesia</b>	<b>Instruments</b>
<b>MANDIBLE</b>		
<b>38, 48</b>	1. Inferior Alveolar and Lingual Nerves Block (Mandibular Anesthesia) or 2. Inferior Alveolar, Lingual and Buccal Nerves block (Torus Anesthesia)	Beak-shaped Forceps Curved on the Plane, or Straight Elevator, Lecluse's elevator
<b>Roots of 38, 48</b>	1. Mandibular Anesthesia or 2. Torus Anesthesia	Beak-shaped Root Forceps, Straight Elevator, or Angle Elevators
<b>37, 36, 47, 46</b>	1. Torus Anesthesia or 2. Mandibular Anesthesia and Buccal Anesthesia	Beak-shaped Forceps for Molars, Elevators
<b>Roots of 37, 36, 47, 46</b>	1. Torus Anesthesia or 2. Mandibular Anesthesia and Buccal Anesthesia	Beak-shaped Root Forceps, Straight Elevator, or Angle Elevators
<b>35, 45</b>	1. Torus Anesthesia or 2. Mandibular Anesthesia and Buccal Anesthesia	Beak-shaped Crown Forceps (for Single Root Teeth)
<b>Roots of 35, 45</b>	1. Torus Anesthesia or 2. Mandibular Anesthesia and Buccal Anesthesia	Beak-shaped Root Forceps

<p><b>34, 33, 32, 44, 43, 42</b></p>	<p>1. Mandibular Anesthesia or 2. Torus Anesthesia or 3. Mental and Incisive Nerves Block (Mental Foramen Injection) and Lingual Anesthesia</p>	<p>Beak-shaped Crown Forceps (for Single Root Teeth)</p>
<p><b>Roots of 34, 33, 32, 44, 43, 42</b></p>	<p>1. Mandibular Anesthesia or 2. Torus Anesthesia or 3. Mental and Incisive Nerves Block (Mental Foramen Injection) and Lingual Anesthesia</p>	<p>Beak-shaped Root Forceps</p>
<p><b>31,41</b></p>	<p>1. Mandibular Anesthesia and Infiltration Anesthesia from opposite central incisor or 2. Torus Anesthesia and Infiltration Anesthesia from opposite central incisor or 3. Mental and Incisive Nerves Block (Mental Foramen Injection), Lingual Anesthesia and Infiltration Anesthesia from opposite central incisor</p>	<p>Beak-shaped Crown Forceps (for Single Root Teeth)</p>
<p><b>Roots of 31, 41</b></p>	<p>1. Mandibular Anesthesia and Infiltration Anesthesia from opposite central incisor or 2. Torus Anesthesia and Infiltration Anesthesia from opposite central incisor or 3. Mental and Incisive Nerves Block</p>	<p>Beak-shaped Root Forceps</p>

	(Mental Foramen Injection), Lingual Anesthesia and Infiltration Anesthesia from opposite central incisor	
--	---	--

## APPENDIX 7.

### TYPES OF SUTURES



- a) Interrupted;
- b) Mattress;
- c) Continuous;
- d) Subcutaneous continuous.

**APPENDIX 8.**

**SUTURING OF WOUND  
(KNOT IS TIED WITH THE HELP OF THE NEEDLE HOLDER)**

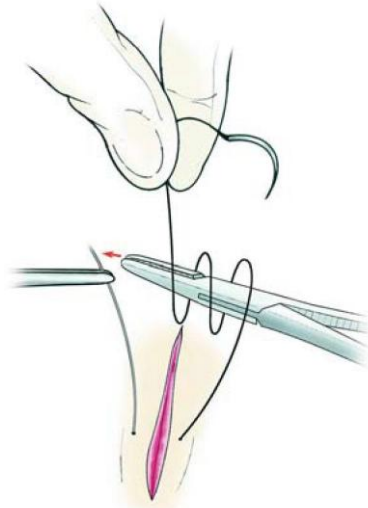


Fig. 1. Suture is initially wrapped twice around the needle holder

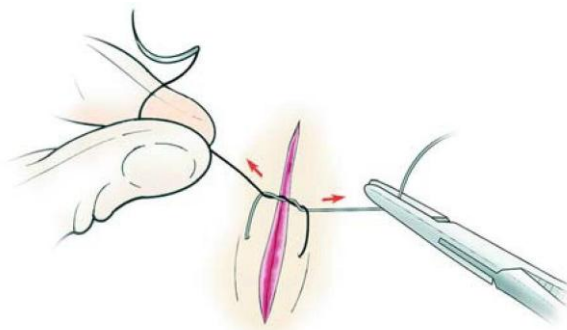


Fig. 2. The two ends of the suture are tightened to create a surgeon's knot over the wound (double knot)

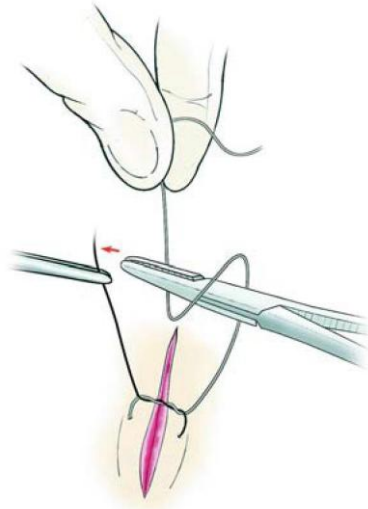


Fig. 3. Safety knot, created by the single wrap of the suture in the counterclockwise direction as opposed to

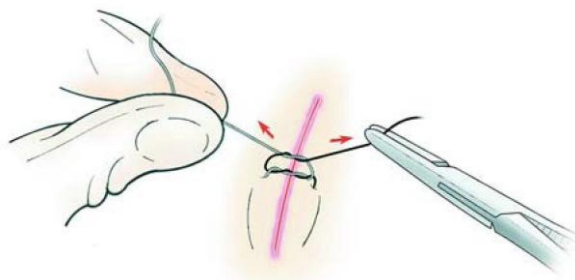


Fig. 4. Tightening of the safety knot over the initial surgeon's knot



## APPENDIX 9.

### BLOOD CONSTANTS

Index	Normal values
Hematocrit (in arterial and venous blood):	36-48%
• in men	40-48%
• in women	36-44%
Erythrocytes sedimentation rate (ESR):	
• in men	2-10 mm/h
• in women	2-15 mm/h
• in the old	up to 15-20 mm/h
• at pregnancy	15-25 mm/h
Erythrocytes number:	
• in men	4,5-5,0x10 <sup>12</sup> /l
• in women	3,7-4,5x10 <sup>12</sup> /l
Hemoglobin level:	
• in men	130-160 g/l
• in women	120-140 g/l
Color index	0,75-1,0
Reticulocytes	0,5-2,0%
Leucocytes	4,0-9,0x10 <sup>9</sup> /l
Leucocytes formule:	
• juniors	0-1,0%
• rod-nucleated neutrophils	1,0-5,0
• segments-nucleated neutrophils	40-65%
• basophils	0-1,0%
• eosinophils	1,0-4,0%
• lymphocytes	20,0-40,0%
• monocytes	2-10%
Platelets amount	180-400x10 <sup>9</sup> /l
Bleeding time (by Duke)	2-4 min

## APPENDIX 10.

### PRESCRIPTION OF THE DRUGS MORE OFTEN USED IN THE MAXILLOFACIAL SURGERY

#### I. LOCAL ANESTHETICS

1. Rp.: Sol. Novocaini 2% – 5 ml  
D. t. d. N. 10 in ampull.  
S. For block anesthesia.
2. Rp: Sol. Lidocaini 2% – 2 ml  
D. t. d. N. 10 in ampull.  
S. For block anesthesia.
3. Rp.: Sol. Mepivacaini 3% – 1,8 ml  
D. t. d. N. 10 in ampull.  
S. For block anesthesia.
4. Rp.: Sol. Scandonesti 3% – 1,8 ml  
D. t. d. N. 10 in ampull.  
S. For block anesthesia.
5. Rp.: Sol. Articaini 4% –1,8 ml  
D. t. d. N. 10 in ampull.  
S. For block anesthesia.
6. Rp.: Ultracaini D-S 1,7 ml  
D. t. d. N. 10 in ampull.  
S. For block anesthesia.
7. Rp.: Septanesti 1:200000 1,8 ml  
D. t. d. N. 10 in ampull.  
S. For block anesthesia.
8. Rp.: Ubistesini Standart 1,8 ml  
D. t. d. N. 10 in ampull.  
S. For block anesthesia.

#### II. ANTISEPTICS

1. Rp.: Sol. Hydrogenii peroxydi 3% – 50 ml  
D. S. For processing of wound.

2. Rp.: Sol. Iodi spirituose 5% – 10 ml  
D. S. For processing of the skin around the wound or minor cuts of skin.
3. Rp.: Ioddicerini 25 ml  
D. S. For processing of mucous membrane.
4. Rp.: Sol. Iodonati 1% – 200 ml  
D. S. For processing of mucous membrane.
5. Rp.: Iodoformii 5,0  
Glycerini 10 ml  
Aetheris medicinalis 90 ml  
M. D. S. For gauze tampon.
6. Rp.: Sol. Iodinoli 1% – 200 ml  
D. S. For stomatological department.
7. Rp.: Sol. Chlorhexidini bigluconatis 20% – 500 ml  
D. S. Dissolve in ethyl alcohol (70%) in ratio 1:40, use for processing of surgical area.
8. Rp.: Spiritus aethylici 70% – 50 ml  
D. S. For processing of surgeon's hands.
9. Rp.: Spiritus aethylici 90% – 50 ml  
D. S. For disinfection of surgical tools.
10. Rp.: Sol. Viridis nitentis spirituosae 1% – 10 ml  
D. S. For processing of the skin around the wound or small cuts of skin.
11. Rp.: Sol. Aethacridini lactatis 0,1% – 500 ml  
D. S. For rinsing.
12. Rp.: Furacilini 0,02 ad usum externum  
D. t. d. N. 10 in tab.  
S. Dissolve 1 tablet in 100 ml of water. For rinsing.
13. Rp.: Sol. Dioxidini 1% – 10 ml  
D. t. d. N. 10 in ampull.  
S. For irrigation of purulent wounds.

14. Rp.: Ectericidi 250 ml  
D. S. For irrigation of purulent wounds.
15. Rp.: Microcidi 200 ml  
D. S. For application on mucous membrane.
16. Rp.: Sol. Chlorophyllipti spirituosae 1% – 200 ml  
D. S. Dissolve in water in ratio 1:3, use for irrigation of purulent wounds.
17. Rp.: Sol. Chloramini 4% – 500 ml  
D. S. For disinfection.

### **III. NON-OPIOID AND OPIOID (NARCOTIC) ANALGESICS**

1. Rp.: Sol. Analgini 50% – 2 ml  
D. t. d. N. 10 in ampull.  
S. Administer 2 ml IM.
2. Rp.: Analgini 0,5  
D. t. d. N. 10 in tab.  
S. Take 1 tablet for pain.
3. Rp.: Paracetamoli 0,2  
D. t. d. N. 10 in tab.  
S. Take 1 tablet 2 times a day.
4. Rp.: Acidi acethylsalicylici 0,5  
D. t. d. N. 10 in tab.  
S. Take 1 tablet for pain.
5. Rp.: Diclofenaci natrii 0,025  
D. t. d. N. 10 in tab.  
S. Take 1 tablet 4 times a day.
6. Rp.: Sol. Diclofenaci-natrii 2,5% – 3 ml  
D. t. d. N. 10 in ampull.  
S. Administer 3 ml IM.
7. Rp.: Ibuprofeni 0,2  
D. t. d. N. 10 in tab.  
S. Take 1 tablet 3 times a day.

8. Rp.: Sol. Promedoli 1% – 1 ml  
D. t. d. N. 10 in ampull.  
S. Administer 1 ml IM for pain.
9. Rp.: Sol. Omnoponi 1% – 1 ml  
D. t. d. N. 6 in ampull.  
S. Administer 0,5-1 ml SC.
10. Rp.: Sol. Phentanyli 0,005% – 2 ml  
D. t. d. N. 10 in ampull.  
S. Administer 1 ml IM (slowly).
11. Rp.: Sol. Tramadoli hydrochloridi 5% – 1 ml  
D. t. d. N.10 in ampull.  
S. Administer 1 ml IM.

#### **IV. ANTIBIOTICS**

1. Rp.: Ampicillini 0,25  
D. t. d. N. 10 in tab.  
S. Take 1 tablet every 6 hrs.
2. Rp.: Ampioxi 0,25  
D. t. d. N. 20 in caps.  
S. Take 2 caps. 4-6 times a day.
3. Rp.: Cefalexini 0,25  
D. t. d. N. 50 in caps.  
S. Take 1 caps. every 6 hrs.
4. Rp.: Ceftriaxononi 0,5  
D. t. d. N. 10.  
S. Dissolve in 5 ml of 0,5% solution of Lidocaine.  
Administer IM every 12 hrs.
5. Rp.: Doxycyclini hydrochloridi 0,1  
D. t. d. N. 10 in tab.  
S. Take 1 tablet every 12 hrs.
6. Rp.: Methacyclini hydrohloridi 0,3  
D. t. d. N. 16 in caps.  
S. Take 1 caps. every 12 hrs.

7. Rp.: Azithromycini 0,5  
D. t. d. N. 20 in tab.  
S. Take 1 tablet once a day.
8. Rp.: Sol. Gentamicini sulfatis 4% – 1 ml  
D. t. d. N. 20 in ampull.  
S. Administer 1 ml IM every 12 hrs.
9. Rp. Lincomycini hydrochloridi 0,25  
D. t. d. N. 20 in caps.  
S. Take 1 caps. every 12 hrs.
10. Rp. Sol. Lincomycini hydrochloridi 30% – 2 ml  
D. t. d. N. 20 in ampull.  
S. Administer 2 ml IM every 8 hrs.

## **V. SULFANILAMIDES AND ANTIFUNGALS**

1. Rp.: Sulfadimezini 0,5  
D. t. D. N. 20 in tab.  
S. Take 4 tablets (2,0) for the 1st administration, then 2 tablets (1,0) 4 times a day, after the normalization of body temperature 1 tablet (0,5) 3 times a day during 3 days.
2. Rp.: Sulfaleni 0,2  
D. t. d. N. 10 in tab.  
S. Take 5 tablets (1,0) for the 1st administration, then 1 tablet (0,2) once a day.
3. Rp.: Sulfadimethoxini 0,5  
D. t. d. N. 30 in tab.  
S. Take 4 tablets (2,0) for the 1st administration, then 2 tablets (1,0) once a day, after the normalization of body temperature 1 tablet (0,5) once a day during 3 days.
4. Rp.: Norsulfasoli 0,5  
D. t. d. N. 20 in tab.  
S. Take 4 tablets (2,0) for the 1st administration, then 2 tablets (1,0) 4 times a day, after the normalization of body temperature 1 tablet (0,5) 3 times a day during 3 days.

5. Rp.: Tab. «Co-Trimoxazole» N. 10  
D.S. Take 2 tablets twice a day.

6. Rp.: Itraconazoli 0,1  
D. t. d. N. 10 in caps.  
S. Take 1 caps. once a day.

## **VI. ANTIHISTAMINES**

1. Rp.: Dimedroli 0,05  
D. t. d. N. 20 in tab.  
S. Take 1-2 tablets 2 times a day.

2. Rp.: Suprastini 0,025  
D. t. d. N. 20 in tab.  
S. Take 1 tablet 2 times a day.

3. Rp.: Dragee Diazolini 0,05  
D. t. d. N. 10.  
S. Take 1 dragee 2 times a day after meals.

4. Rp.: Tavegili 0,001  
D. t. d. N. 50 in tab.  
S. Take 1 tablet 2 times a day.

## **VII. COAGULANTS AND STRYPTICS**

1. Rp.: Spongie haemostaticae N. 3  
D. S. Apply on the wound.

2. Rp.: Sol. Acidi aminocapronici 5% – 100 ml  
D. S. Topically for terminal capillary bleeding.

3. Rp.: Sol. Acidi aminocapronici 5% – 100 ml  
Steril.!  
D. S. For IV infusion.

4. Rp.: Trombini sicci 0,001  
D. t. d. N. 10 in ampull.  
S. Dissolve contents of the ampoule in 15 ml of isotonic solution of Natrium chloridum. Moisten a tampon. Apply the tampon to the wound.

5. Rp.: Vikasoli 0,015  
D. t. d. N. 25 in tab.  
S. Take 1 tablet 2 times a day.

6. Rp.: Sol. Vikasoli 1% – 1 ml  
D. t. d. N. 10 in ampull.  
S. Administer 1 ml IM.

### VIII. VITAMINS AND ENZYMES

1. Rp.: Sol. Retinoli acetatis oleosae 3,4% – 10 ml  
D.S. Take 2-3 drops orally 4 times a day.

2. Rp.: Sol. Tocopheroli acetatis oleosae 30% – 20 ml  
D. S. Take 10 drops 2 times a day.

3. Rp.: Riboflavini 0,005  
D. t. d. N. 50 in tab.  
S. Take 1 tablet 2 times a day.

4. Rp.: Sol. Acidi ascorbinici 5% – 1 ml  
D. t. d. N. 20 in ampull.  
S. Administer 1 ml IM, 2 times a day.

5. Rp.: Pyridoxini 0,01  
D. t. d. N. 50 in tab.  
S. Take 1-2 tablets 3-4 times a day.

6. Rp: Sol. Cyancobalamini 0,01% – 1 ml  
D. t. d. N. 10 in ampull.  
S. Administer 1ml IM.

7. Rp.: Methylmethioninsulfonii chloridi 0,05  
D. t. d. N. 100 in tab.  
S. Take 2 tablets 3 times a day after meals.

8. Rp.: Sol. Thiamini chloridi 2,5% – 1 ml  
D. t. d. N. 10 in ampull.  
S. Administer 2 ml IM.



9. Rp.: Sol. Acidi nicotini 1% – 1 ml  
D. t. d. N. 10 in ampull.  
S. Administer 1 ml SC.
10. Rp.: Acidi folici 0,001  
D. t. d. N. 10 in tab.  
S. Take 1 tablet 3 times a day.
11. Rp.: Trypsini crystallisati 0,01  
D. t. d. N. 10 in ampull.  
S. Dissolve contents of the ampoule in 10 ml of isotonic solution of Natrii chloridum. Apply on the wound.
12. Rp.: Ung. Iruxoli 30,0  
D. S. For enzymatic wound cleansing.
13. Rp.: Terrilitini 200 PU  
D. t. d. N. 10.  
S. Dissolve contents of the flacon in 4-5 ml of 0,25% solution of Procaine. Apply on the wound.
14. Rp.: Lydasi 0,1  
D. t. d. N. 10.  
S. Dissolve contents of the flacon in 1 ml of 0,5% solution of Procaine, for electrophoresis.

## **IX. DRUGS INFLUENCING SALIVATION**

1. Rp.: Sol. Pilocarpini hydrochloridi 1% – 10 ml  
D. S. Take 10 drops 3 times a day during 2-3days.
2. Rp.: Sol. Atropini sulfatis 0,1% – 10 ml  
D. S. Take 5 drops 2 times a day.
3. Rp.: Sol. Atropini sulfatis 0,1% – 1 ml  
D. t. d. N. 10 in ampull.  
S. Administer 0,5-1 ml SC 1-2 times a day.

## **X. EMERGENCY DRUGS**

1. Rp.: Sol. Adrenalini hydrochloride 0,1% – 1 ml  
D. t. d. N. 6 in ampull.  
S. Administer 0,5 ml SC.

2. Rp.: Sol. Mesatoni 1% – 1 ml  
D. t. d. N. 6 in ampull.  
S. Administer 0,5 ml SC.
3. Rp.: Cordiamini 2 ml  
D. t. d. N. 10 in ampull.  
S. Administer 2 ml SC.
4. Rp.: Sol. Coffeini natrii-benzoatis 10% – 1ml  
D. t. d. N. 6 in ampull.  
S. Administer 1 ml SC.
5. Rp.: Sol. Lobelini hydrochloridi 1% – 1 ml  
D. t. d. N. 6 in ampull.  
S. Administer 1 ml SC.
6. Rp.: Sol. Glucosi 40% – 20 ml  
D. t. d. N. 10 in ampull.  
S. For IV administration.
7. Rp.: Sol. Furosemidi 1% – 2 ml  
D. t. d. N. 10 in ampull.  
S. Administer 2 ml IM or IV.
8. Rp.: Hydrocortisoni hemisuccinatis 0,1  
D. t. d. N. 10 in ampull.  
S. Dissolve in 5-10 ml of water for injections,  
administer IV.
9. Rp.: Sol. Calcii chloridi 10% – 10 ml  
D. t. d. N. 10 in ampull.  
S. Administer 10 ml IV.
10. Rp.: Sol. Euphyllini 2,4% – 10 ml  
D. t. d. N. 10 in ampull.  
S. Administer IV slowly with 5-20 ml of 20% solution  
glucose.
11. Rp.: Sol. Ammonii caustici 10% – 30 ml  
D.S. Moisten a piece of cotton, bring to the nose of  
the patient.

## APPENDIX 11.

### PHARMACOTHERAPY OF URGENT STATES

(Vazhnicha O.M. – Doctor of Medical Science, Professor of the Department of Experimental and Clinical Pharmacology of Higher state educational establishment of Ukraine «Ukrainian Medical Stomatological Academy»)

#### 1. Syncope

- Solution of Ammonia (apply on the piece of cotton and use for inhalation through the nose)

#### 2. Collapse

- alpha- and alpha, beta-adrenomimetics: Mesatonum (IM, SC or IV), Noradrenalini hydrotartras (IV infusion), Adrenalini hydrochloridum (SC)
- analeptics: Cordiaminum (SC, IV), Camphora (SC), Sulfocamphocainum (IV, IM, SC)

#### 3. Shock

- narcotic analgesics: Morphini hydrochloridum (IV, SC), Phentanylum (IV), Promedolum (IV, SC, IM)
- alpha- and alpha,beta-adrenomimetics
- analeptics
- hemodynamic drugs for transfusion therapy: Reopolyglucinum (IV transfusion)

#### 4. Acute heart failure

- cardiac glycosides from Strophanthus group: Stophanthinum (IV), Corglyconum (IV)
- non-glycoside cardiotonics: Dobutaminum (IV infusion)

#### 5. Angina pectoris attack

- organic nitrates: Nitroglycerinum (sublingually)
- coronarolytic: Validolum (sublingually)

#### 6. Myocardial infarction

- narcotic analgesics: Omnoponum, Promedolum, Phentanyl
- organic nitrates: Nitroglycerinum (IV)
- beta-adrenoblockers: Propranolol (IV), Metoprolol (IV)
- antiarrhythmic drugs: Lidocainum (IV), Trimecainum (IV)
- direct-acting anticoagulants: Heparinum (IV)
- fibrinolytics and activators of fibrinolysis: Fibrinolysinum,

Streptoliasis (IV infusion)

- cardiotonics: Dobutaminum (IV infusion) (in cardiogenous shock)

## **7. Heart arrhythmia**

### **a) bradycardia, heart block**

- M-cholinoblockers; Atropini sulfas (IM, SC)
- beta-adrenomimetics: Isadrinum (sublingually, IV infusion)

### **b) tachyarrhythmia**

- cardiac glycosides: Strophanthinum, Corglyconum, Digoxinum (IV)
- potassium compounds: Pananginum (IV)
- beta-adrenoblockers: Anaprilinum (IV)
- calcium channels blockers: Verapamilum (IV)
- local anaesthetics: Lidocainum (IV), Trimecainum (IV)
- membrane depressants: Chinidini sulfas, Novocainamidum (IV, IM)
- blockers of potassium channels: Amiodaronum (IV)

## **8. Hypertensive crisis**

- central alpha 2-adrenomimetics: Clophelinum (sublingually, or IV)
- diuretics: Furosemidum (IV, IM)
- calcium channels blockers: Phenigidinum (sublingually)
- magnesium salts: Magnesii sulfas (IV, IM)
- spasmolytics: Papaverini hydrochloridum (IM, IV), Dibazolium (IM, IV)
- ganglia blockers: Pentaminum (IM)
- neuroleptics: Aminazinum (IM, IV)
- peripheral vasodilators (in severe hypertensive crisis): Nitroglycerinum (IV), Natrii nitroprussidum (IV infusion)

## **9. Trombosis**

- direct -acting anticoagulants: Heparinum (IV)
- fibrinolytics and activators of fibrinolysis: Fibrinolysinum (IV infusion), Streptokinasum or Alteplasmum (IV infusion)

## **10. Bleeding**

### **a) capillary bleeding**

- locally acting hemostatics direct -acting coagulants: Thrombinum, Spongia haemostatica; drugs from other groups: Adrenalinum hydrochloridum, Adroxonum, Sol. Hydrogenii peroxidum 3%

### **b) bleeding from bigger vessels**

- direct-acting coagulants: Fibrinogen (IV infusion), Calcii chloridum (IV)
- inhibitors of fibrinolysis: Acidum aminocapronicum (IV infusion), Contrykal (IV infusion)

### **11. Respiratory arrest**

- N-cholinomimetics: Cytitonum (IV), Lobelini hydrochloridum (IV)

### **12. Pulmonary edema**

- diuretics: Furosemidum (IV), Mannitum (IV infusion), Urea pura (IV infusion)
- drugs caused redistribution of blood: ganglia blockers (Hygronium, IV infusion; Pentaminum, IV or IM); peripheral vasodilators (Nitroglycerinum, IV; Natrii nitroprussidum, IV infusion)
- cardiac glycosides: Strophanthinum (IV), Corglyconum (IV)
- glucocorticoides: Prednisolonum (IM, IV)
- narcotic analgesics: Morphini hydrochloridum
- surfactants: Exosurf, Curosurf
- oxygen with vapor of Ethanol

### **13. Anaphylactic shock**

- adrenergic agonists: Adrenalini hydrochloridum (SC)
- glucocorticoides: Prednisolonum (IV, IM)
- antihistamines: Dimedrolum (IV, IM)
- Penicillinase (IM) (if anaphylaxis has developed after the administration of penicillin)

### **14. Hypoglycemic coma**

- Solution of glucose 40% (IV)
- hormonal preparations antagonistic to insulin: Adrenalini hydrochloridum (SC), Prednisolonum

### **15. Hyperglycemic coma**

- Insulinum (IV)
- correction of acidosis: Natrii hydrocarbonas (IV infusion)
- hemodilution: solution of Natrii chloridum 0,9% (IV infusion)

## REFERENCES

1. Dmitrieva A.A. Local anesthesia in oral and maxilla-facial surgery / A.A. Dmitrieva, A.V. Kuritsyn. – Kharcov, 2010. – 24 p.
2. Miloro M. Peterson's Principle of oral and maxillofacial surgery. Second Edition / M. Miloro, G.E. Ghali, P.E. Larsen, P.D. Waite. – Hamilton London, BC Decker Inc, 2004. – 1502 p.
3. Master dentistry / P. Coulthard, K. Horner PH. Sloan, E Theaker. – Edinburg, London, New York, Philadelphia, St Louis, Toronto, Churchill Livingstone, 2003. – 267 p.
4. Oral and maxillofacial surgery : textbook / Ed. by prof. V. Malanchuk / part one. – Vinnytsia : Nova Knyha Publishers, 2011. – 424 p.
5. Oral Surgery / Ed. by Fraiskos D. Fragiskos. – Springer-Verlag Berlin Heidelberg, 2007. – 367 p.
6. Principle of oral and maxillofacial surgery / Ed. by U.J. Moore. – Blackwell Science, 2001. – 276 p.
7. Tkachenko P.I. Propaedeutics of surgical stomatology and inflammatory diseases of maxillofacial region / P.I. Tkachenko, A.I. Pankevich, K.Yu. Rezvina. – Poltava, ASMI, 2011. – Part 1. – 284 p.
8. Pharmacology: textbook / Victor M. Bobyrov, Tetyana O. Devyatkina, Olena M. Vazhnicha, Vadim M. Khristyuk. – 3<sup>rd</sup> ed., updated. – Vinnytsya : Nova Knyha, 2015. – 520 p. : il.
9. Wray D. Textbook of general and oral surgery / D. Wray, D. Stenhouse, D. Lee, A. Clark. – Edinburg, London, New York, Philadelphia, St Louis, Toronto, Churchill Livingstone, 2003. – 322 p.
10. Рибалов О.В. Виробнича лікарська практика з хірургічної стоматології : методичний посібник // О.В. Рибалов, Л.М. Саяпіна, О.О. Розколупа, І.В. Яценко. – Полтава, 2006. – 87 с.
11. Тимофеев А.А. Руководство по челюстно-лицевой хирургии и хирургической стоматологии // А.А. Тимофеев. – Киев: ООО «Червона Рута-Турс», 2002. – 1024 с.: ил.

Підписано до друку 19 жовтня 2015 р. Формат \_\_\_\_\_

Папір \_\_\_\_\_. Друк – розографія.

Гарнітура Times New Roman

Тираж 500 примірників. Замовлення №175

Надруковано у СПДФО Гаража М.Ф.

Свідоцтво №1949605176 від 4.12.2006 р.

36029, м. Полтава, вул. Шведська, 20-Б