

вотных с диабетом снизилась на 35% и 50% соответственно по сравнению с контролем. Активность глюкозо-6-фосфатдегидрогеназы в эритроцитах взрослых и старых животных с диабетом снизилась на 27% и 45% соответственно по сравнению с контролем на 47-й день. Изменения могут быть следствием возрастных нарушений метаболизма глюкозы из-за нарушения механизмов свободных радикалов. Активность глутатионредуктазы в эритроцитах взрослых и старых животных с диабетом уменьшилась на 29% и 35% соответственно по сравнению с контролем на 47-й день. Вывод. Мы установили, что в ходе старения произошли изменения чувствительности активностей пируваткиназы, глюкозо-6-фосфатдегидрогеназы и глутатионредуктазы в эритроцитах крыс с аллоксановым диабетом к влиянию диабетического статуса (гипергликемия). Мы выдвинули гипотезу, что контроль гликемии является целевым назначением для пожилых пациентов с диабетом 1 типа для предотвращения осложнений, связанных со старением организма.

DOI 10.31718/2077-1096.20.3.173

UDC: 616.345-006.5+616.345-006.6]-074:577.112]-042.2

Shyshkin M.A.

## COMPARATIVE ANALYSIS OF CD44 EXPRESSION IN POLYPS AND ADENOCARCINOMA OF DISTAL COLON

Zaporizhzhia State Medical University

*Introduction. CD44 is one of the most used markers of cancer stem cells in colorectal cancer. Even though, the questions of its diagnostic and prognostic value remain open. The aim of the study was to compare CD44 immunohistochemical expression levels in polyps and adenocarcinoma of the distal colon. Materials and methods. Histopathological and immunohistochemical studies of biopsies from 40 patients and surgical material of colorectal adenocarcinoma from 30 patients were carried out. Results. It was figured out that distal colonic polyps are characterized by membranous CD44 expression with the medians of relative areas of CD44+ cells equal to 60,24 (50,22; 70,22) % stromal cells and 15,67 (12,47; 19,47) % epitheliocytes. Colorectal adenocarcinoma is characterized by membranous-cytoplasmic CD44 expression with the medians of relative areas of CD44+ cells equal to 61,26 (42,58 ; 79,15) % stromal cells and 30,60 (24,56 ; 36,45) % cancer cells. Comparative analysis of the data obtained for the pTNM stages of colorectal adenocarcinoma revealed some significant differences. The median of CD44+ stromal cells area on the I stage equals to 31,41 (19,87 ; 42,15) % vs. the median of CD44+ stromal cells area on the II stage equals to 48,26 (35,44 ; 61,45) % ,  $p < 0,05$ ; the median of CD44+ stromal cells area on the II stage vs. the median of CD44+ stromal cells area on the III stage equals to 78,36 (61,13 ; 80,06) % ,  $p < 0,05$ . The median of CD44+ cancer cells area on the III stage equals to 30,35 (21,19 ; 35,47) % vs. the median of CD44+ cancer cells area on the IV stage equals to 31,25 (30,22 ; 41,19) % ,  $p < 0,05$ . Moreover, it was revealed that the median of CD44+ epitheliocytes area in polyps two-fold smaller than the median of CD44+ cancer cells area in colorectal adenocarcinoma: 15,67 (12,47 ; 19,47) % vs. 30,60 (24,56 ; 36,45) % ,  $p < 0,05$ . Conclusions. Distal colonic polyps are characterized by membranous CD44 expression with the median of CD44+ epitheliocytes area that is two-fold smaller than the median of CD44+ cancer cells area. Colorectal adenocarcinoma is characterized by membranous-cytoplasmic CD44 expression with the median of CD44+ stromal cells area that significantly increases during the tumor progression from I to III stages and with the median of CD44+ cancer cells area that significantly go up during the tumor progression from III to IV stages.*

Key words: polyps, colorectal cancer, CD44 antigen.

The research is funded as a part of planned research project "Comorbidity, cardiovascular and oncological diseases in general clinical practice: development of modern diagnostic and therapeutic measures" in Zaporizhzhia State Medical University, number of state registration 0120U101587 (2020-2023).

Annually, approximately 1.3 million new cases of colorectal cancer (CRC) are diagnosed worldwide [1]. The CRC development is preceded by an abnormal proliferation of the colonic mucosa that forms a polyp in most cases. The excessive proliferation is considered to be a result of a combination of unfavourable external factors (smoking, alcohol abuse, lack of plant fibre in the diet) and genetic predisposition, which through molecular-genetic modifications can trigger the "polyp-carcinoma" se-

quence [2].

During the last decade, a significant amount of data regarding cancer stem cells (CSCs) subpopulation and their role in tumour initiation and progression has been accumulated [3-5]. CD44 is one of the most used markers of CSCs in CRC. Even though, the questions of its diagnostic and prognostic value for CRC patients are still remaining open [4].

CD44 is a transmembrane glycoprotein that is expressed by embryonic stem cells, as well as by some progenitor and mature cells, including cells of connective tissue and bone marrow [6]. According to the literature, the CD44 gene is a part of an intestinal stem cell gene signature [7]. In addition, it is known that CD44 expression is characteristic of the CSCs subpopulation [8]. The main ligand of CD44

is hyaluronic acid, one of the dominant components of the extracellular matrix. Binding of hyaluronic acid to CD44 leads to structural changes in CD44 intracellular domain that leads to enabling of the molecule to bind to the cytoskeleton and some adapter proteins, as a result, it affects cell adhesion and activity of a number of signalling cascades that are functionally connected with CD 44 [6].

Experimental studies have shown that cells expressing CD44 are tumour-initiating cells in xenografts. CD44+ cells have stem cell properties, i.e. each CD44+ cell is capable of self-renewal, as well as subsequent differentiation with the formation of a xenograft tumour similar to the original tumour [8]. Moreover, it was shown that CD44 expression level correlates with stage, presence of regional and distant metastases, prognosis, and survival of patients diagnosed with different carcinomas [6, 9-10]. A high level of CD44 expression is recognized as a hallmark of cell subpopulations with high tumorigenic potential [8].

At the same time, the data concerning the diagnostic value of CD44 expression in CRC vary. According to Wu Q., et al. (2015), decreasing CD44 expression leads to inhibition of tumour growth and metastasis of CRC cells [11]. According to Li X.D., et al. (2013), decreasing CD44 expression promotes the migration and realization of metastatic potential of CRC cells. However, in this work the variant forms of CD44 (CD44v), which are the results of alternative splicing, were studied [12]. There has been also found out that highly differentiated CRC is characterized by higher levels of CD44 expression in comparison with poorly differentiated CRC. However, a higher level of CD44 expression is associated with a worsening of prognostic parameters in the group of highly differentiated CRC [7]. Thus, the literature data are contradictory, and the data concerning CD44 expression in polyps-precursor of CRC are very limited [13-14].

### **Aim**

The aim of the study was to compare CD44 immunohistochemical expression levels in polyps and adenocarcinoma of the distal colon.

### **Materials and methods**

Histopathological and immunohistochemical (IHC) studies of biopsies from 40 patients (biopsies of polyps and histologically non-changed mucosa of the distal colon), as well as surgical material of colorectal adenocarcinoma from 30 patients, were carried out.

The biopsies and the surgical material were fixed in 10 % neutral buffered formalin and were paraffin-embedded. The features of histological structure in the samples were studied in sections stained by hematoxylin and eosin, and in sections stained by PAS-reaction as well.

During the histopathological examination microscopic features of the studied samples were estimated, and then divided into two study groups: 1

group was represented by distal colonic polyps (biopsies taken from 30 patients), 2 group included colorectal adenocarcinoma (CRA; surgical material taken from 30 patients). On the basis of the relevant WHO classification, the 1 study group was subdivided into 2 subgroups: 1.1 – serrated hyperplastic polyps (15 patients), 1.2 – adenomatous polyps (15 patients). On the basis of the actual pTNM classification, the 2 study group was subdivided into 4 subgroups according to the CRA stages: I stage (6 patients), II stage (9 patients), III stage (9 patients), IV stage (6 patients). 10 biopsies of histologically non-changed mucosa of the distal colon made up the control group.

IHC study was conducted according to the protocol provided by the manufacturer of used antibodies. Monoclonal antibodies against CD44 (CD44 Std. / HCAM Ab-4, Thermo Scientific, USA), as well as visualization system EnVision FLEX with diaminobenzidine (DAKO, USA), were used. The results of IHC reactions were studied using Axioplan-2 microscope (Carl Zeiss, Germany). In each case, the area of CD44-positive cells was estimated in 5 standardized microscope fields of view at  $\times 200$  magnification. The area was estimated by the method of photo digital morphometry: calculation of immunopositive pixels number in a digital image with further comparing to total pixels number in the image was carried out. As a result, the number of immunopositive pixels was expressed in percents (%).

The obtained data were statistically processed using the STATISTICA® for Windows 13.0 (StatSoft Inc., license no. JPZ8041382130ARCN10-J). The median (Me), the lower and upper quartiles (Q1; Q3) were calculated. Comparison between two study groups was carried out using the Mann-Whitney test. Comparison between 3 and more study subgroups was carried out using the Kruskal-Wallis analysis. The results were considered statistically significant at the 95 % level ( $p < 0,05$ ).

### **Results and Discussion**

It was figured out that distal colonic polyps are characterized by membranous CD44 expression in stromal cells, with the median of relative area of CD44+ cells equal to 60,24 (50,22 ; 70,22) % stromal cells. CD44+ epitheliocytes are revealed focally, in precursor-cells that locate into the basal part of crypts, as well as in dysplastic epitheliocytes, with the median of relative area of CD44+ cells equal to 15,67 (12,47 ; 19,47) % epitheliocytes.

Comparative analysis of the data obtained for the two studied polyps subgroups revealed an absence of significant differences: the medians of CD44+ stromal cells were equal to 60,03 (50,22 ; 68,36) % in hyperplastic polyps vs. 61,12 (48,96 ; 70,46) % in adenomas ( $p > 0,05$ ); the medians of CD44+ epitheliocytes were equal to 15,24 (11,36 ; 16,42) % in hyperplastic polyps vs. 16,34 (12,84 ; 20,13) % in adenomas ( $p > 0,05$ ).

Colorectal adenocarcinoma is characterized by membranous-cytoplasmic CD44 expression in stromal cells, as well as in cancer cells of the CRA II-IV stages. The median of relative area of CD44+ stromal cells in CRA equal to 61,26 (42,58 ; 79,15) %, while the median of relative area of CD44+ cancer cells equal to 30,60 (24,56 ; 36,45) %.

Comparative analysis of the data obtained for the studied CRA subgroups revealed a few significant differences. The median of CD44+ stromal cells area in CRA I stage equals to 31,41 (19,87 ; 42,15) % vs. the median of CD44+ stromal cells area in CRA II stage equal to 48,26 (35,44 ; 61,45) % ,  $p < 0,05$ ; the median of CD44+ stromal cells

area in CRA II stage vs. the median of CD44+ stromal cells area in CRA III stage equals to 78,36 (61,13 ; 80,06) % ,  $p < 0,05$ ; the median of CD44+ stromal cells area in CRA III stage vs. the median of CD44+ stromal cells area in CRA IV stage equal to 75,70 (69,35 ; 80,33) % ,  $p > 0,05$  (fig. 1).

The median of CD44+ cancer cells area in CRA II stage equals to 30,22 (23,53 ; 32,45) % vs. the median of CD44+ cancer cells area in CRA III stage equals to 30,35 (21,19 ; 35,47) % ,  $p > 0,05$ ; the median of CD44+ cancer cells area in CRA III stage vs. the median of CD44+ cancer cells area in CRA IV stage equals to 31,25 (30,22 ; 41,19) % ,  $p < 0,05$  (fig. 2).

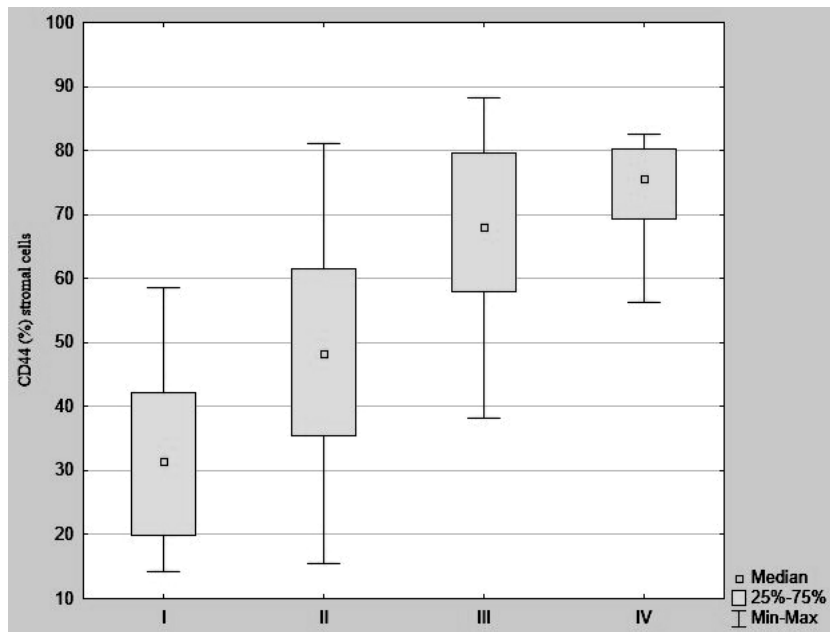


Fig. 1. The medians of CD44+ stromal cells area in colorectal adenocarcinoma I, II, III, and IV stages (pTNM).

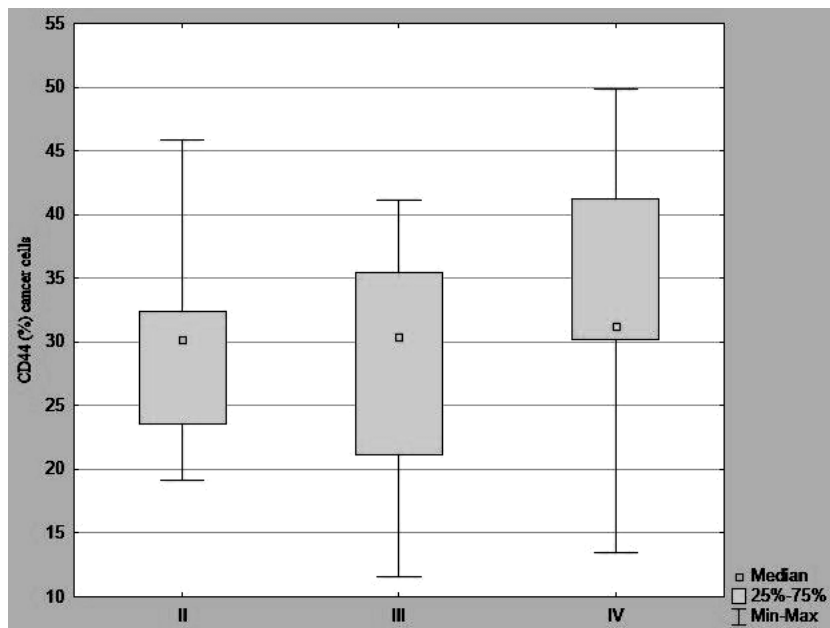


Fig. 2. The medians of CD44+ cancer cells area in colorectal adenocarcinoma II, III, and IV stages (pTNM).

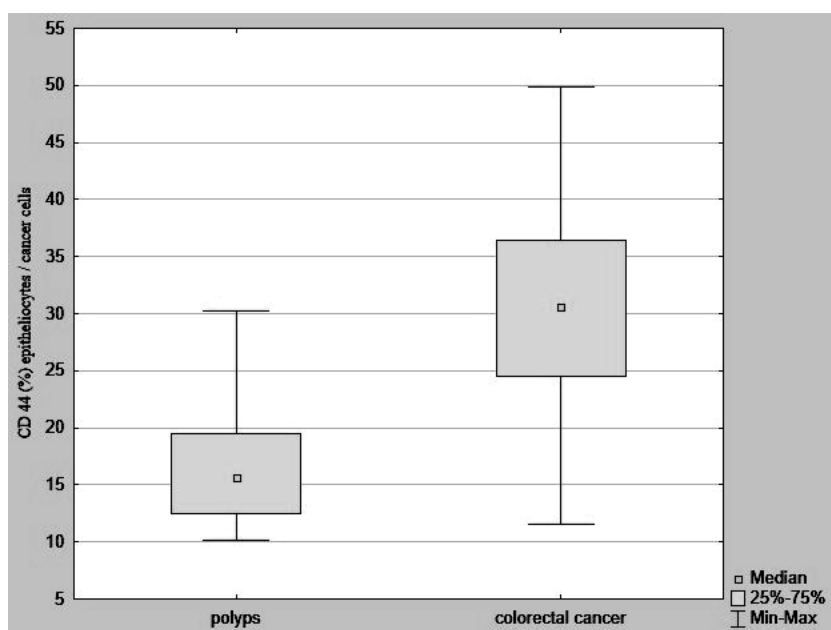


Fig. 3. The medians of CD44+ epitheliocytes in polyps and CD44+ cancer cells in colorectal adenocarcinoma.

Comparative analysis of the data obtained for the main two studied groups was carried out as well. It revealed that the median of CD44+ stromal cells in polyps did not significantly differ from the median of CD44+ stromal cells in carcinoma. However, the median of CD44+ epitheliocytes in polyps two-fold smaller than the median of CD44+ cancer cells: 15,67 (12,47 ; 19,47) % vs. 30,60 (24,56 ; 36,45) %,  $p < 0,05$  (fig. 3).

CD44 molecule contains hyaluronic acid-binding extracellular domain, transmembrane domain, and short cytoplasmic domain [6]. The study has shown that distal colonic polyps are characterized by membranous CD44 expression whereas colorectal adenocarcinoma is characterized by membranous-cytoplasmic CD44 expression. Based on the literature data, the most probable cause of the appearance of CD44 cytoplasmic expression in the carcinoma is proteolysis of the cytoplasmic domain with its further oligomerization. When the domain is not proteolyzed, it connects with the cytoskeleton. When the domain is exposed to disintegrins and ADAM-17, the proteolysis occurs that leads to disruption of the domain and the cytoskeleton, as well as to the fragmentation of the domain. These fragments may undergo oligomerization with further activation of some signalling cascades [12].

It is well known that CD44 is expressed by different cells of tumours stoma, including lymphocytes and CSCs [9]. The revealed tendency to increasing CD44 expression by stromal cells of the CRA I-III stages (pTNM) indicates the increasing functional activity of CD44 on the stages of colorectal carcinogenesis, which provide invasive and metastatic properties of the tumour. Based on literature, CD44 may bind to EGFR (HER1), HER2, HER3, and HER4. Binding of CD44 to HER2 and/or HER3 leads to its heterodimerization upon binding to neuregulin molecules that result in apoptosis re-

sistance. Moreover, the binding of CD44 to HER2 is one of the main mechanisms of Ras-Raf-Mek-Erk and PI3K-Akt-NF-kB cascades activation. These cascades provide regulation of cell proliferation, survival and promote invasive properties of cancer cells [15].

This study also described the expression of CD44 by cancer cells and its significant increasing on advanced III-IV CRA stages. CD44 expression by cancer cells reflects their acquisition of stem properties, since the molecule is involved in the activation of signalling cascades described earlier, which ensure high cell survival [15]. Furthermore, CD44+ cancer cells are cells that undergo epithelial-mesenchymal transition (EMT) [6, 8]. CD44 is involved in EMT which forms the basis for cancer metastasizing according to current literature data. One of the driver transcription factors for EMT is ZEB1. EMT-induced ESRP1-suppression controls CD44 alternative splicing that is the reason for switching from CD44v (variant forms) expression to CD44 standard form expression. What is interesting, CD44s able to control ZEB1 expression independently, that works as the main mechanism of CD44s expression supporting and EMT activation as well. It is so-called "CD44s-ZEB1-regulatory loop" main functions of which are: independent from external stimuli stimulation of ZEB1 expression, suppression of ESRP1, and supporting of CD44s expression [16].

As it was mentioned above, literature data concerning CD44 expression in polyps-precursor of CRC are very limited [13-14]. The present study has shown that the median of CD44+ epitheliocytes area in polyps is two-fold smaller than the median of CD44+ cancer cells area. Moreover, CD44 expression is revealed only in precursor-cells located in the basal part of crypts (that corresponds to the general idea of CD44 as a stem cells marker [15])

as well as in epitheliocytes with dysplasia. The appearance of CD44 expression in dysplastic epitheliocytes indicates the loss of certain differentiation properties and approach to the phenotype of progenitor cells and stem cells. These changes mean increasing survival rate and the ability of those cells to multiply, which can form the basis for their malignant transformation.

### Conclusions

1. Distal colonic polyps are characterized by membranous CD44 expression; herewith the median of CD44+ epitheliocytes area is 2 times smaller than the median of CD44+ cancer cells area.

2. Colorectal adenocarcinoma is characterized by membranous-cytoplasmic CD44 expression, wherein the median of CD44+ stromal cells area significantly increases during the tumour progression from I to III stages.

3. The median of CD44+ cancer cells area significantly increases during the tumour progression from III to IV stages that indicates a meaningful increase in number of cancer cells which acquire stemness on the advanced stages of colorectal adenocarcinoma.

### References

- Mármol I, Sánchez-de-Diego C, Pradilla Dieste A, Cerrada E, Rodríguez Yoldi MJ. Colorectal Carcinoma: A General Overview and Future Perspectives in Colorectal Cancer. *International Journal of Molecular Sciences*. 2017;18(1):E197.
- Asadzade-Aghdaei H, Pezeshkian Z, Atitappeh M, Nazemalhosseini-Mojarad E, Zali M. The Role of Angiogenesis in Colorectal Polyps and Cancer: a Review. *Medical Laboratory Journal*. 2018;12(4):1-6.
- Moharil RB, Dive A, Khandekar S, Bodhade A. Cancer stem cells: An insight. *J Oral Maxillofac Pathol*. 2017;21(3):463. [https://doi.org/10.4103/jomfp.JOMFP\\_132\\_16](https://doi.org/10.4103/jomfp.JOMFP_132_16)

- Kuşoğlu A, Biray Avcı Ç. Cancer stem cells: A brief review of the current status. *Gene*. 2019;681:80-85. <https://doi.org/10.1016/j.gene.2018.09.052>
- Capp J. Cancer Stem Cells: From Historical Roots to a New Perspective. *Journal of Oncology*. 2019;2019:1-10. <https://doi.org/10.1155/2019/5189232>
- Chen C, Zhao S, Karnad A, Freeman JW. The biology and role of CD44 in cancer progression: therapeutic implications. *Journal of Hematology & Oncology*. 2018;11:64. <https://doi.org/10.1186/s13045-018-0605-5>
- Zeilstra J, Joosten SP, Vermeulen L, et al. CD44 expression in intestinal epithelium and colorectal cancer is independent of p53 status. *PLoS One*. 2013;8(8):e72849. <https://doi.org/10.1371/journal.pone.0072849>
- Holah NS, Aiad HA, Asaad NY, Elkhouly EAB, Lasheen AG. Evaluation of the role of CD44 as a cancer stem cell marker in colorectal carcinoma: immunohistochemical study. *Menoufia Medical Journal*. 2017;30(1):174-183.
- Basakran NS. CD44 as a potential diagnostic tumor marker. *Saudi Med J*. 2015;36(3):273-9. doi: 10.15537/smj.2015.3.9622.
- Ouhtit A, Rizeq B, Saleh HA, Rahman MM, Zayed H. Novel CD44-downstream signaling pathways mediating breast tumor invasion. *Int J Biol Sci*. 2018;14(13):1782-1790. doi: 10.7150/ijbs.23586.
- Wu Q, Yang Y, Wu S, Li W, Zhang N, Dong X, et al. Evaluation of the correlation of KAI1/CD82, CD44, MMP7 and beta-catenin in the prediction of prognosis and metastasis in colorectal carcinoma. *Diagn Pathol*. 2015;10:176. doi: 10.1186/s13000-015-0411-0
- Li XD, Ji M, Wu J, Jiang JT, Wu CP. Clinical significance of CD44 variants expression in colorectal cancer. *Tumori*. 2013;99:88-92. doi: 10.1700/1248.13794
- Neumayer R, Rosen HR, Reiner A, Sebesta C, Schmid A, Tuchler H, Schiessel R. CD44 expression in benign and malignant colorectal polyps. *Dis Colon Rectum*. 1999;42:50-55. <https://doi.org/10.1007/BF02235182>
- Chai N, Zhang W, Wang Y, Zhou Z, Zhang Y, Liu H, Wan J, Qin J, Wang S, Wang Y, Pei X, Wu B, Linghu E. Lgr5 and CD44 expressions in different types of intestinal polyps and colorectal cancer. *Nan Fang Yi Ke Da Xue Xue Bao*. 2013;33(7):972-976.
- Morath I, Hartmann T, Orian-Rousseau V. CD44: More than a mere stem cell marker. *The International Journal of Biochemistry & Cell Biology*. 2016;81:166-173.
- Preca BT, Baidak K, Mock K, Sundararajan V, Pfannstiel J, Maurer J, Wellner U, Hopt U, T, Brummer T, Brabletz S, Brabletz T, Stemmler MP. A self-enforcing CD44s/ZEB1 feedback loop maintains EMT and stemness properties in cancer cells. *Int J Cancer*. 2015;137(11):2566-2577. <https://doi.org/10.1002/ijc.29642>

### Реферат

ПОРІВНЯЛЬНИЙ АНАЛІЗ ЕКСПРЕСІЇ CD44 В ПОЛІПАХ І АДЕНОКАРЦИНОМІ ДИСТАЛЬНОЇ ТОВСТОЇ КИШКИ

Шишкін М. А.

Ключові слова: поліпи, колоректальний рак, CD44 антиген.

Актуальність. CD44 є одним з найбільш поширених маркерів стовбурових клітин для колоректальної карциноми. При цьому питання щодо його діагностичної та прогностичної цінності лишаються відкритими. Метою цього дослідження було порівняти рівні імуногістохімічної експресії CD44 в поліпах і аденокарциномі дистальної товстої кишки. Матеріали та методи. Проведено патогістологічне та імуногістохімічне дослідження біопсій 40 пацієнтів і хірургічного матеріалу колоректальної аденокарциноми 30 пацієнтів. Результати. Встановлено, що поліпи дистальної товстої кишки характеризуються мембраною експресією CD44 з медіанами відносною площі CD44+ клітин, що дорівнюють 60,24 (50,22 ; 70,22) % клітин строми і 15,67 (12,47 ; 19,47) % епітеліоцитів. Колоректальна аденокарцинома характеризується мембрано-цитоплазматичною експресією CD44 з медіанами відносною площі CD44+ клітин, що дорівнюють 61,26 (42,58 ; 79,15) % клітин строми і 30,60 (24,56 ; 36,45) % ракових клітин. Порівняльний аналіз даних, що були отримані для рТНМ стадій колоректальної аденокарциноми, виявив низку достовірних відмінностей. Медіана площі CD44+ клітин строми на I стадії дорівнює 31,41 (19,87 ; 42,15) % vs. медіана площі CD44+ клітин строми на II стадії дорівнює 48,26 (35,44 ; 61,45) % , p < 0,05; медіана площі CD44+ клітин строми на II стадії vs. медіана площі CD44+ клітин строми на III стадії дорівнює 78,36 (61,13 ; 80,06) % , p < 0,05. Медіана площі CD44+ ракових клітин на III стадії дорівнює 30,35 (21,19 ; 35,47) % vs. медіана площі CD44+ ракових клітин на IV стадії дорівнює 31,25 (30,22 ; 41,19) % , p < 0,05. Окрім того, встановлено, що медіана площі CD44+ епітеліоцитів поліпів в 2 рази менша за медіану площі CD44+ ракових клітин колоректальної аденокарциноми: 15,67 (12,47 ; 19,47) % vs. 30,60 (24,56 ; 36,45) % , p < 0,05. Висновки. Поліпи дистальної товстої кишки характеризуються мембраною експресією CD44 з медіаною площі CD44+ епітеліоцитів в 2 рази меншою за медіану площі CD44+ ракових клітин. Колоректальна аденокарцинома характеризується мембрано-цитоплазматичною експресією CD44 з медіаною площі CD44+ клітин строми, що достовірно зростає при прогресії пухлини від I до III стадії, а також з медіаною площі CD44+ ракових клітин, що достовірно зростає при прогресії пухлини від III до IV стадії.

### Реферат

СРАВНИТЕЛЬНЫЙ АНАЛИЗ ЭКСПРЕССИИ CD44 В ПОЛИПАХ И АДЕНОКАРЦИНОМЕ ДИСТАЛЬНОЙ ТОЛСТОЙ КИШКИ  
Шишкин М.А.

Ключевые слова: полипы, колоректальный рак, CD44 антиген.

Актуальность. CD44 один из наиболее часто используемых маркеров стволовых клеток для колоректального рака. При этом вопросы о его диагностической и прогностической ценности остаются открытыми. Целью данного исследования было сравнить уровни иммуногистохимической экспрессии CD44 в полипах и аденокарциноме дистальной толстой кишки. Материалы и методы. Проведено патогистологическое и иммуногистохимическое исследования биопсий 40 пациентов и хирургического материала колоректальной аденокарциномы 30 пациентов. Результаты. Установлено, что полипы дистальной толстой кишки характеризуются мембранной экспрессией CD44 с медианами относительной площади CD44+ клеток равными 60,24 (50,22 ; 70,22) % клеток стромы и 15,67 (12,47 ; 19,47) % эпителиоцитов. Колоректальная аденокарцинома характеризуется мембранно-цитоплазматической экспрессией CD44 с медианами относительной площади CD44+ клеток равными 61,26 (42,58 ; 79,15) % клеток стромы и 30,60 (24,56 ; 36,45) % раковых клеток. Сравнительный анализ данных, полученных для pTNM стадий колоректальной аденокарциномы, выявил ряд достоверных различий. Медиана площади CD44+ клеток стромы на I стадии равна 31,41 (19,87 ; 42,15) % vs. медиана площади CD44+ клеток стромы на II стадии равна 48,26 (35,44 ; 61,45) % ,  $p < 0,05$ ; медиана площади CD44+ клеток стромы на II стадии vs. медиана площади CD44+ клеток стромы на III стадии равна 78,36 (61,13 ; 80,06) % ,  $p < 0,05$ . Медиана площади CD44+ раковых клеток на III стадии равна 30,35 (21,19 ; 35,47) % vs. медиана площади CD44+ раковых клеток на IV стадии равна 31,25 (30,22 ; 41,19) % ,  $p < 0,05$ . Кроме того, установлено, что медиана площади CD44+ эпителиоцитов полипов в 2 раза меньше медианы площади CD44+ раковых клеток колоректальной аденокарциномы: 15,67 (12,47 ; 19,47) % vs. 30,60 (24,56 ; 36,45) % ,  $p < 0,05$ . Выводы. Полипы дистальной толстой кишки характеризуются мембранной экспрессией CD44 с медианой площади CD44+ эпителиоцитов в 2 раза меньшей, чем медиана CD44+ площади раковых клеток. Колоректальная аденокарцинома характеризуется мембранно-цитоплазматической экспрессией CD44 с медианой площади CD44+ клеток стромы, которая достоверно возрастает при прогрессии опухоли от I к III стадии, а также с медианой площади CD44+ раковых клеток, которая достоверно возрастает при прогрессии опухоли от III к IV стадии.