

Case report

A Case of Bizarre Parosteal Osteochondromatous Proliferation (Nora's Lesion): A Brief Description

Borys Fylenko¹, Nataliia Roiko¹, Andriy Roiko², Ivan Starchenko¹, Dmytro Kuvichka²,
Volodymyr Koka^{1,2}

¹*Poltava State Medical University, Department of Pathological Anatomy with Autopsy Course, Poltava, Ukraine*

²*"Municipal Enterprise 1st City Clinical Hospital of Poltava City Council", Trauma Unit, Poltava, Ukraine*

SUMMARY

Introduction. Nora's lesion or bizarre parosteal osteochondromatous proliferation is a rare benign bone neoplasm that is usually localized on the small bones of the hands. The paper was aimed at clinical, morphological and structural analysis of Nora's lesion case, the second registered in Ukraine.

Case report. A 42-year-old male patient presented with complaints of painless swelling in the area of the distal 4th metacarpal bone and limited mobility of the ring finger. The diagnosis was based on a typical localization, combination of clinical, radiological, and histological methods; however, the right differential diagnosis was an important task in the present case, too.

Conclusion. As there is still not enough data in the literature on this issue, further studies of Nora's lesion etiology will improve its understanding, thus treatment modes and prevention of recurrence, too.

Keywords: Nora's lesion, clinical examination, radiological methods, histology

Corresponding author:

Borys Fylenko

e-mail: borysfylenko@gmail.com

INTRODUCTION

Nora's lesion or bizarre parosteal osteochondromatous proliferation (BPOP) is a rare benign bone neoplasm that is usually localized on the small bones of the hands and less often on the feet, and very rarely on the large tubular bones. The literature describes single and serial cases, presenting that this lesion occurs equally in both genders of all ages (1). BPOP grows rapidly, often recurs, and has unusual histological picture (2).

The paper was aimed on clinical and morphological analysis of the bizarre parosteal osteochondromatous proliferation case, the second registered in Ukraine.

CASE REPORT

The 42-year-old male patient was presented to a family doctor with complaints of painless swelling in the area of the distal 4th metacarpal bone and

limited mobility of the ring finger. He reported that the mass had appeared about 3 years before for no apparent reason and had been gradually increased in size. The past medical history revealed no injuries. No medical care was provided before applying. For diagnosis and treatment, the patient was referred to the Trauma Unit of the City Hospital.

Examination revealed an orbicular, dense, immobile and palpable untender tumor-like mass of about 3 cm in diameter. The skin over was intact and mobile (Figure 1a). Peripheral lymph nodes were mobile, painless and not enlarged. Sensitive, motor and vascular disorders were not detected. The X-ray examination revealed a neoplasm with heterogeneous mineralization, presented above the cortical surface of the 4th metacarpal bone (Figure 1b, 1c). Computed tomography was performed to clarify the diagnosis (Figure 1d). A CT slice image confirmed that the mass was not conjoined to the phalanx (Figure 1e, 1f).

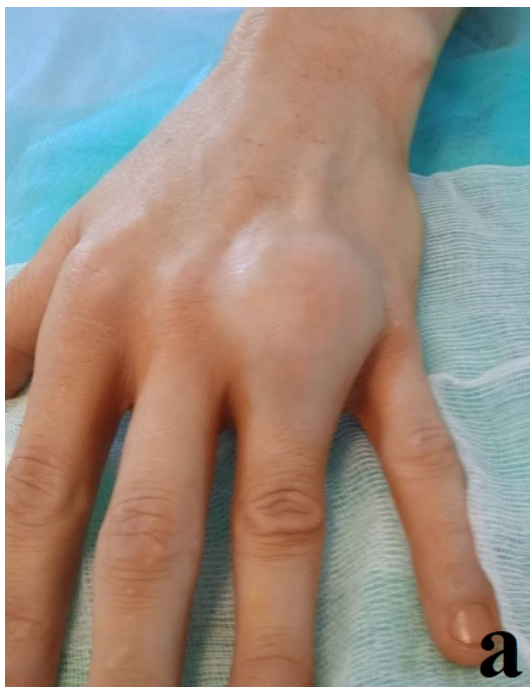

Figure 1a. *Clinical and radiological presentation of the case: visual presence of the hand with Nora's lesion*

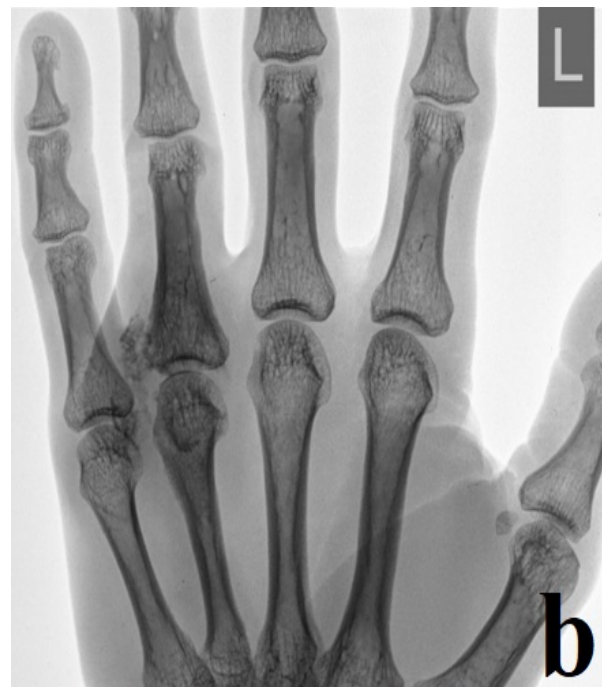

Figure 1b. *x-rays in direct projections*

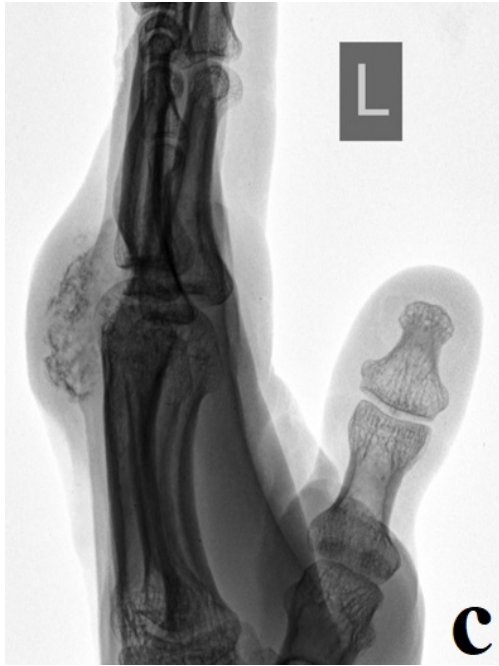

Figure 1c. *x-rays in side projections*

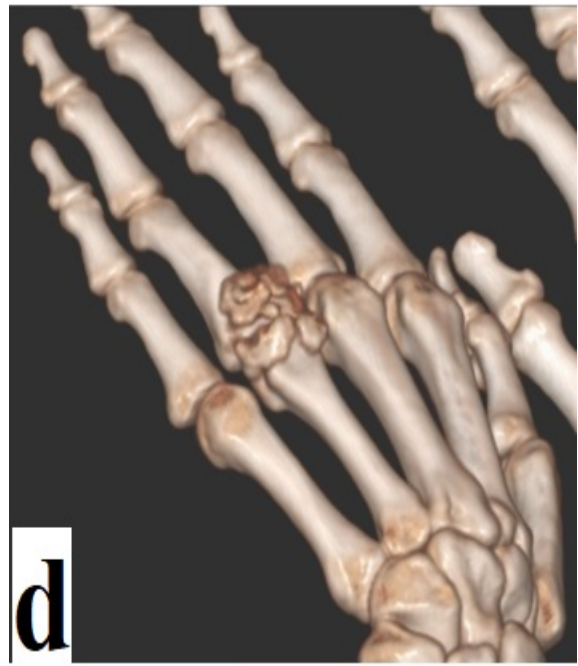

Figure 1d. *3D CT scan, a general view*

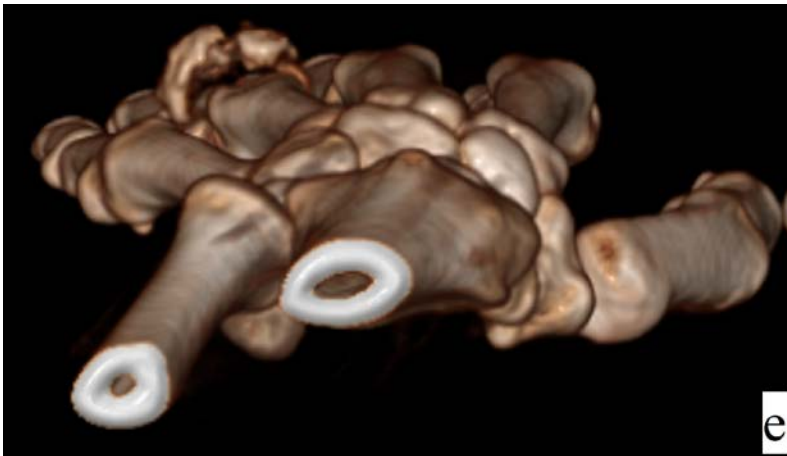


Figure 1e. *3D CT scan, an axial projection*

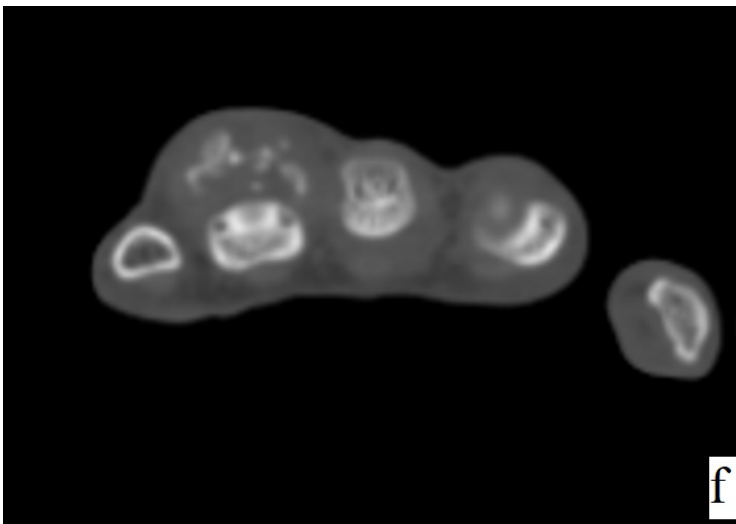


Figure 1f. *2D CT scan, an axial projection*

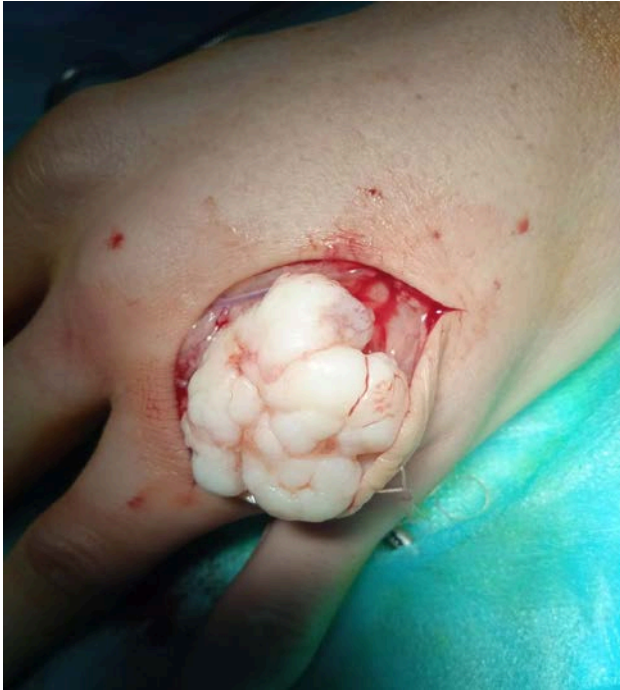

Figure 1g. Intraoperative presence of the Nora's lesion

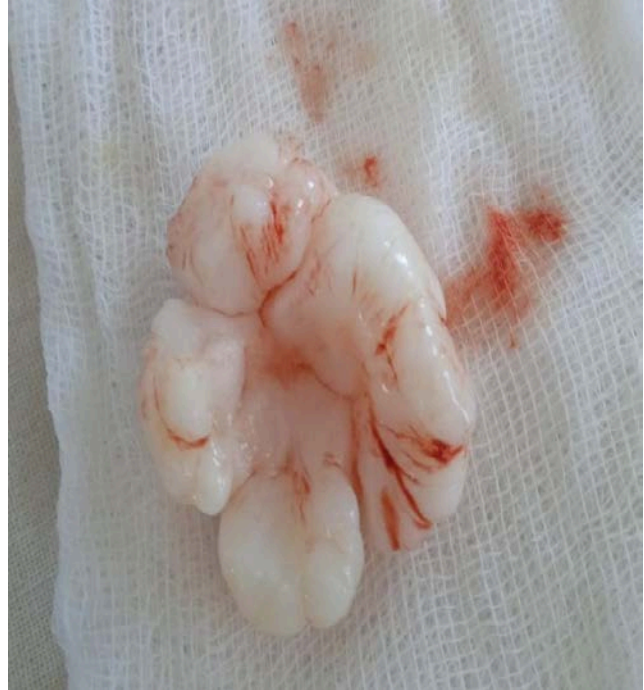

Figure 1h. Macroscopic presence of the neoplasm

Preliminary clinical and radiological diagnosis was made: Nora's lesion of the 4th metacarpal bone of the left hand.

Under the conduction anesthesia, the tumor-like mass was removed together with the pseudo-capsule. The neoplasm, represented by gray, tuberous mass (Figure 1g), was intimately close to a compact layer of the proximal phalanx, in which no defects were found. After the removal of the mass, its site was irrigated by 95% ethyl alcohol solution to reduce the risk of recurrence (3). The excised tissue was sent for pathohistological examination.

Macroscopically, encapsulated grayish mass of the flat circular shape and concave "cap" form, having a diameter of about 3 cm, with a lumpy

surface and dense consistency, was found intra-operatively adjacent to the bone (Figure 1h). The material was fixed in 10% neutral formalin solution, and decalcified in 5% nitric acid solution. Histological sections were stained with hematoxylin and eosin.

Microscopically, the mass was presented in irregular cartilage proliferations containing polymorphic and enlarged chondrocytes, without the signs of atypia, and some of them had two nuclei (Figure 2a). The foci of myxomatosis and areas of heterogenous calcification were found (Figure 2b). Peripherally, there was a formation of a primitive bone and loose connective tissue, containing spindle-shaped cells (Figure 2c).

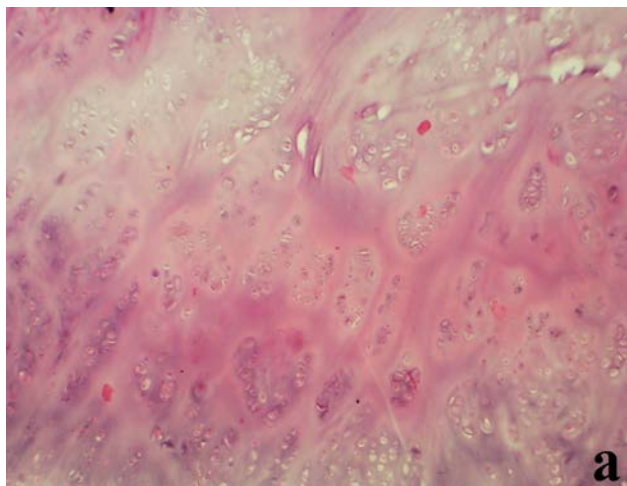


Figure 2a. Microscopic presence of the neoplasm groups of proliferating chondrocytes are enclosed in the homogenized stroma with different tinctorial properties, × 40 magnification; areas of calcification

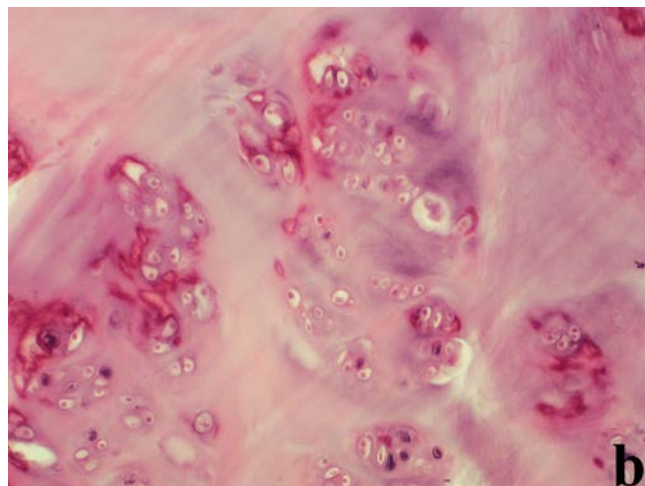


Figure 2b. Microscopic presence of the neoplasm groups of proliferating chondrocytes are enclosed in the homogenized stroma with different tinctorial properties, × 100 magnification

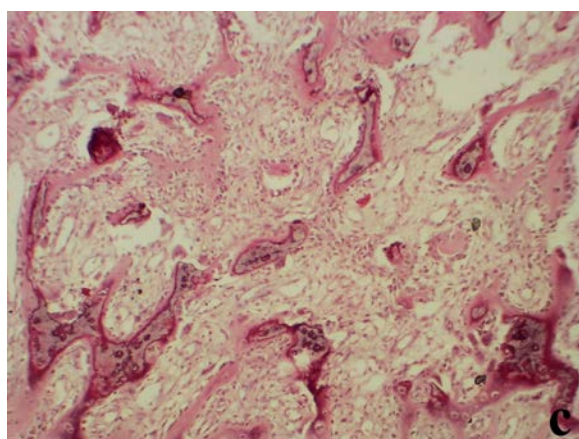


Figure 2c. Microscopic presence of the neoplasm with proliferation of the bone and fibrous tissue, × 100 magnification

The lesions, described above, especially the presence of atypical calcified cartilage, sporadically staining blue (the so-called “blue bone”), corresponded to the abnormal bizarre parosteal osteochondromatous proliferation, also known as Nora’s lesion.

DISCUSSION

One paper describing a case of bizarre parosteal osteochondromatous proliferation registered in Ukraine was found (4). However, since the Nora’s lesion cases are updated in the literature constantly, there were no difficulties in making the diagnosis for our case. Typical localization, clinical presentation, X-ray, CT and histological findings

contributed to the correct diagnosis. The right differential diagnosis focused on reactive periosteitis, cartilaginous exostosis, periosteal chondroma, osteomyelitis, sarcoidosis, osteosarcoma, chondrosarcoma or metastases is an important task in a such case, too (5, 6).

BPOP or Nora’s lesion (named after the author who first described it in 1983) is a rare recurrent disease that mainly affects the small bones of the hands and feet (7). However, cases of this disease were described on the long bones of the limbs and on the skull (8, 9). The etiology of this disease is debatable and has not been fully studied yet (1 - 3, 10, 11). Currently, several theories exist on the BPOP development, explaining its progression as an intermediate phase between periostitis and exostosis: as a

result of trauma-related hemorrhagic subperiosteal proliferation; neoplastic process characterized by a genetic disorder caused by t (1:17) (q32; q21) translocation, etc. However, none of them have been verified (10). In the present case, the patient denied any injuries to the hand in the past, so the development of this disease as a reactive proliferation was not possible to explain. Despite surgical excision of BPOP, the patient expressed eagerness to be monitored constantly for early recurrence of the disease (12). In addition, epidemiological indicators are of great importance, which are currently not available, as the literature describes about 200 cases (11), two of which were registered in Ukraine. In this regard, the group of authors decided to investigate the pre-

valence of this disease in Ukraine, followed by clinical, radiological and histological data analysis.

CONCLUSION

A combination of clinical, radiological and histological methods should be used to have the right diagnosis of bizarre parosteal osteochondromatous proliferation, and to have the right differential diagnosis, too. Further studies of Nora's lesion etiology will improve the treatment and recurrence prevention of such tumorous process, thus new epidemiological data and new published cases will give significant contribution in that improvement.

References

1. Başdelioğlu K, Toksöz Yıldırım AM, Reddy K, Özkan K. Bizarre Parosteal Osteochondromatous Proliferation (Nora's Lesion) of the Foot: A Case Report and Literature Review of Nora's Lesion of the Foot. *Cureus* 2022; 14(4):e24197. <https://doi.org/10.7759/cureus.24197>
2. Wittesaele W, Vanbecelaere L, Mombert M. Excision of a bizarre parosteal osteochondromatous proliferation ("Nora lesion") in the hand: A case report. *Int J Case Rep Orthop* 2021; 3(1):1-3. <https://doi.org/10.22271/27078345.2021.v3.i1a.38>
3. Lin CH, Wu K. Nora's lesion of the distal ulna: a case report. *J Int Med Res* 2021; 49(12):1-8. <https://doi.org/10.1177/03000605211064390>
4. Голобородько С. А., Криничанская М. И., Котлярова В. Е. Болезнь Нора: описание случая. *Ортопедия, травматология и протезирование* 2013; 3:61-3.
5. Rushing CJ, Rogers DE, Spinner SM, Gajzer DC. A Case Report of Heel Pain Mimicking Plantar Fasciitis and Osteosarcoma: A Unique Presentation of a Nora's Lesion. *J Foot Ankle Surg* 2017; 56(3):670-3. <https://doi.org/10.1053/j.jfas.2017.01.028>
6. Washington E, Menendez L, Fedenko A, Tomasian A. Bizarre parosteal osteochondromatous proliferation: Rare case affecting distal ulna and review of literature. *Clin Imaging* 2021; 69:233-7. <https://doi.org/10.1016/j.clinimag.2020.08.019>
7. Nora FE, Dahlin DC, Beabout JW. Bizarre parosteal osteochondromatous proliferations of the hands and feet. *Am J Surg Pathol* 1983; 7:245-50.

<https://doi.org/10.1097/00000478-198304000-00003>

8. Ganguly R, Jordan RC. Bizarre Parosteal Osteochondromatous Proliferation (Nora's Lesion) of Mandible With Recurrence: Case Report and Review of Literature. *J Oral Maxillofac Surg* 2021; 79(5):1074-80.
<https://doi.org/10.1016/j.joms.2020.10.035>
9. Matsui Y, Funakoshi T, Kobayashi H, et al. Bizarre parosteal osteochondromatous proliferation (Nora's lesion) affecting the distal end of the ulna: a case report. *BMC Musculoskelet Disord* 2016; 17:130.
<https://doi.org/10.1186/s12891-016-0981-3>
10. Albarracín Solórzano KS, Patiño Yugsi MR, Pineda Álvarez DM, Torres Calle MF. Literature review on bizarre parosteal osteochondromatous proliferation or Nora's Lesion: A clinical case study. *Res Soc Dev* 2021; 10(10):e109101018855.
<https://doi.org/10.33448/rsd-v10i10.18855>
11. Rottler P, Wilke A, Kasper HU, Hütter F. First presentation of a Nora-lesion of the talus in a paraossal fasciitis. *Orthop Rev* 2019; 11(1):7628.
<https://doi.org/10.4081/or.2019.7628>
12. Salna I, Solanki N, Proudman T. Appearances and Evolution of a Recurrent Nora's Lesion of the Hand. *Eplasty* 2019; 19:ic5.
<https://doi.org/10.1111/hsc.12311>

Received: March 15, 2022

Revised: February 6, 2023

Accepted: February 18, 2023

Online first: May 3, 2023

Slučaj neobične osteohondromatozne proliferacije (Norina lezija): kratak opis

Borys Fylenko¹, Nataliia Roiko¹, Andriy Roiko², Ivan Starchenko¹, Dmytro Kuvichka², Volodymyr Koka^{1,2}

¹Državni medicinski univerzitet u Poltavi, Departman za patološku anatomiju sa kursom iz autopsije, Poltava, Ukrajina

²Gradska ustanova „Prova gradska klinička bolnica gradskog veća Poltave“, Jedinica za traumatologiju, Poltava, Ukrajina

SAŽETAK

Uvod. Norina lezija ili neobična periostalna osteohondromatozna proliferacija je retka benigna neoplazma kostiju koja obično zahvata male kosti šake. Cilj rada bila je klinička, morfološka i strukturalna analiza slučaja Norine lezije. To je drugi registrovani slučaj u Ukrajini.

Prikaz slučaja. Četrdesetdvo godišnji pacijent se javio sa bolnim otokom u predelu distalne, četvrte metakarpalne kosti i sa ograničenom pokretljivošću domalog prsta. Dijagnoza je bazirana na tipičnoj lokalizaciji, kao i na kombinaciji kliničkih, radioloških i histoloških metoda. Takođe, prava diferencijalna dijagnoza bila je veoma važna u ovom slučaju.

Zaključak. Budući da u literaturi još uvek nema dovoljno podataka o ovoj temi, dalje istraživanje etiologije Norine lezije će poboljšati razumevanje ovog problema, načine lečenja, kao i prevenciju recidiva.

Ključne reči: Norina lezija, klinički pregled, radiološke metode, histologija