




REPORTS OF MORPHOLOGY

Official Journal of the Scientific Society of Anatomists,
Histologists, Embryologists and Topographic Anatomists
of Ukraine

journal homepage: <https://morphology-journal.com>



Features of anthropometric indicators and dimensions of the coronary sinus and relationships between these indicators in patients without coronary artery pathology

Liulka Ye. M., Bilash S. M.

Poltava State Medical University, Poltava, Ukraine

ARTICLE INFO

Received: 12 June 2023

Accepted: 11 July 2023

UDC: 611.142.06+572]:616-071.3-027.44

CORRESPONDING AUTHOR

e-mail: 0509539343@ukr.net

Liulka Ye. M.

CONFLICT OF INTEREST

The authors have no conflicts of interest to declare.

FUNDING

Not applicable.

Recently, in Ukraine, there has been a significant increase in the possibilities of invasive treatment of cardiovascular pathologies, the number of open-heart cardiosurgical operations and endovascular interventions is increasing. Each of these interventions requires endovascular catheterization of the coronary venous sinus of the heart, the variety of anatomical features of which requires a detailed study of the anatomy of the venous system of the heart. The purpose of the work is to establish the features of the coronary sinus dimensions and anthropometric indicators in men and women without coronary artery pathology, as well as the relationships between these indicators. Weight, body length, body mass index, anterior-posterior size of the chest, as well as the dimensions of the coronary sinus were determined (the length of the coronary sinus from the mouth to the oblique atrial vein, the transverse size of the coronary sinus in the area of the mouth in the sagittal and axial planes, the transverse size of the coronary sinus in the middle third in the sagittal and axial plane, the transverse dimension of the coronary sinus at the level of the oblique vein of the atrium in the sagittal and axial plane) in 15 men and 9 women aged 44 to 60 years (average age according to the age classification of the World Health Organization) without pathology of the coronary arteries, who underwent CT coronary angiography at the "Amosov National Institute of Cardiovascular Surgery NAMS of Ukraine". Statistical processing of the obtained results was carried out in the license package "Statistica 6.0" using non-parametric estimation methods. As a result of the conducted research, the limits of the percentile range of anthropometric indicators and the size of the coronary sinus in men and women without coronary artery pathology were established. When analyzing the value of these indicators between men and women, only significantly higher values of body mass and length were established in men. Therefore, when analyzing the relationship between the dimensions of the coronary sinus and the anthropometric parameters of the body, the distribution of indicators by sex was not carried out. When analyzing the correlations between age, sex, weight, body length, body mass index, signs of body mass index (indicates underweight, equivalent to normal body weight, indicates the presence of excess weight, or is a sign of obesity) and the anterior-posterior size of the chest with almost all dimensions of the coronary sinus, multiple reliable direct strong ($r=0.64$ and $r=0.67$) and medium strength ($r=0.44$ and $r=0.47$), as well as unreliable medium strength direct correlations with the anterior-posterior size of the chest were established ($r=0.40$ in both cases). In addition, multiple nonreliable average strength direct correlations of more than half of coronary sinus dimensions were established with body weight ($r=$ from 0.32 to 0.35). When analyzing the correlations between the sizes of the coronary sinus, multiple reliable direct strong ($r=$ from 0.60 to 0.65) and medium strength ($r=$ from 0.41 to 0.59), as well as unreliable medium strength direct ($r=$ from 0.30 to 0.40) correlations were established with half the size of these indicators.

Keywords: coronary sinus, CT coronary angiography, morphometry, anthropometry, correlations, men and women without coronary artery pathology, sex differences.

Introduction

Diseases of the cardiovascular system continue to occupy the first place in the mortality structure of the population of most countries of the world. Recently, in our country, there has been a significant increase in the possibilities of invasive treatment of cardiovascular pathologies, the number of open-heart cardiosurgical operations and endovascular interventions is increasing. As of the middle of 2023, there are 17 electrophysiological laboratories in Ukraine, which perform invasive electrophysiological interventions for heart rhythm disorders. Each of these interventions requires endovascular catheterization of the coronary venous sinus of the heart using an electrophysiological catheter to study the electrical activity of the heart. In addition, in certain cardiovascular diseases, resynchronization three-chamber artificial pacemakers are implanted, in which restoration of the synchronous contractility of the heart cavities is realized due to stimulation of the left parts of the heart through one of the tributaries of the coronary venous sinus. The variety of anatomical features of the coronary venous sinus requires a detailed study of the anatomy of the venous system of the heart, as well as the determination of certain regularities in the size of its individual parts in order to create tools for catheterization of the coronary venous sinus and its tributaries [1, 5, 7]. For a long time, the possibilities of anatomical research methods were limited to the analysis of sectional material, including after its fixation with formalin [11, 17, 21]. Coronary venous sinus size measurements on sectioned material differ from those in vivo, which is explained by the absence of intravital hemodynamic turgor [14]. For this purpose, some researchers used X-ray contrast angiography, which was first performed in 1951 [20], including retrograde filling of the coronary venous sinus, which made a significant contribution to the understanding of the morphology of the venous system of the heart [6, 10]. With the introduction of the technique of multispiral computer tomography - a method of obtaining spatial three-dimensional models of individual body structures, researchers gained the opportunity not only to assess the linear dimensions of the coronary venous sinus during life, but also other morphometric indicators that cannot be assessed on sectional material [4, 8, 13, 15, 18, 22]. In our opinion, this method of studying the venous system of the heart is the current standard, as well as magnetic resonance imaging, which allows obtaining three-dimensional models without the use of a contrast agent [19]. It has been proven that concomitant coronary artery pathology also changes the morphology of the venous system of the heart [3, 12, 16], therefore, in our study, the presence of coronary artery pathology during computed tomography was an exclusion criterion.

The purpose of the work is to establish the features of the coronary sinus dimensions and anthropometric indicators in men and women without coronary artery

pathology, as well as the relationships between these indicators.

Materials and methods

An examination of 15 men and 9 women aged 44 to 60 years (average age according to the age classification of the World Health Organization) without coronary artery pathology, who underwent CT coronary angiography based on SI "Amosov National Institute of Cardiovascular Surgery NAMS of Ukraine" was carried out.

Committee on Bioethics of Poltava State Medical University (protocol № 171 From 27.02.2019) found that the studies do not contradict the basic bioethical standards of the Declaration of Helsinki, the Council of Europe Convention on Human Rights and Biomedicine (1977), the relevant WHO regulations and laws of Ukraine.

Body weight and length were determined for all patients. Body mass index was calculated according to the formula:

$$\text{body mass index} = m/h^2,$$

where m - body mass in kilograms, and h - body length in meters.

A body mass index value of less than 18.5 kg/m² indicates underweight; from 18.6 kg/m² to 22.9 kg/m² is equivalent to normal body weight; from 23.0 kg/m² to 24.9 kg/m² - indicates the presence of excess weight; more than 30.0 kg/m² is a sign of obesity [9].

During CT coronary angiography, the following dimensions of the coronary sinus were determined (Fig. 1): KS_F - the length of the coronary sinus from the mouth to the oblique atrial vein (mm); KS_G - the transverse size of the coronary sinus in the area of the mouth in the sagittal plane (mm); KS_H - transverse size of the coronary sinus in the area of the mouth in the axial plane (mm); KS_I - transverse size of the coronary sinus in the middle third in the sagittal plane (mm); KS_J - transverse size of the coronary sinus in the middle third in the axial plane (mm); KS_K - the transverse size of the coronary sinus at the level of the oblique vein of the atrium in the sagittal plane (mm);

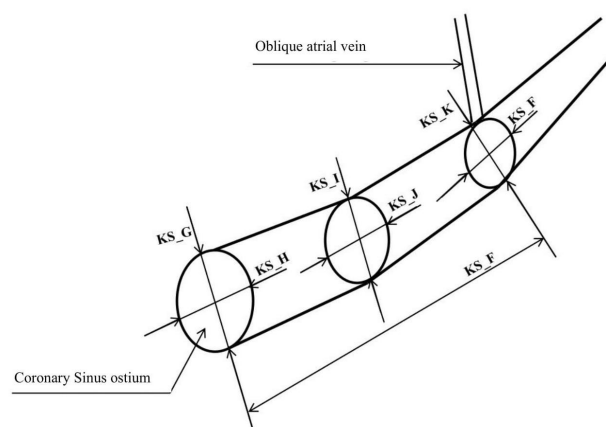


Fig. 1. Scheme of the coronary venous sinus dimensions' measurements.

KS_L is the transverse size of the coronary sinus at the level of the oblique atrial vein in the axial plane (mm). In addition, the anterior-posterior size of the chest (GR_KL, mm) was determined on computer tomograms.

Statistical processing of the obtained results was carried out in the license package "Statistica 6.0" using non-parametric estimation methods. After assessing the nature of the distributions for each of the variation series, the average values for each feature, the standard square deviation and the limits of the percentile range were determined. The reliability of the difference in values between independent quantitative indicators was determined using the Mann-Whitney U-test, and between independent qualitative indicators (body mass index signs) - according to the Weber E formula:

$$t = \frac{R_1 - R_2}{\sqrt{\frac{N_1 R_1 + N_2 R_2}{N_1 + N_2} \cdot \frac{100}{N_1 + N_2} - \frac{N_1 R_1 + N_2 R_2}{N_1 + N_2} \cdot \frac{1}{N_1 N_2}}}$$

where, P₁ and P₂ - percentages with which this or that indicator met; N₁ and N₂ - the number of indicators in the studied groups.

Correlations were evaluated using Spearman's non-parametric statistics [2].

Results

The limits of the percentile range (25.000th - 75.000th percent) of the body and coronary sinus dimensions in men and women without coronary artery pathology who underwent CT coronary angiography are:

for men - body weight 78.0-91.0 kg; body length 1.72-1.80 m; body mass index 25.2-30.1 kg/m²; anteroposterior size of the chest on a computer tomogram is 222-246 mm; the length of the coronary sinus from the mouth to the oblique atrial vein is 66-86 mm; the transverse size of the coronary sinus in the area of the mouth in the sagittal plane is 16-20 mm; the transverse size of the coronary sinus in the area of the mouth in the axial plane is 10-15 mm; the transverse size of the coronary sinus in the middle third in the sagittal plane is 8-11 mm; the transverse size of the coronary sinus in the middle third in the axial plane is 7-9 mm; the transverse size of the coronary sinus at the level of the oblique vein in the sagittal plane is 5-7 mm; the transverse size of the coronary sinus at the level of the oblique vein in the axial plane - 4-6 mm;

for women - body weight 61.0-71.0 kg; body length 1.59-1.65 m; body mass index 24.2-26.3 kg/m²; anteroposterior size of the chest on a computer tomogram is 208-245 mm; the length of the coronary sinus from the mouth to the oblique atrial vein is 58-80 mm; the transverse size of the coronary sinus in the area of the mouth in the sagittal plane is 14-20 mm; the transverse size of the coronary sinus in the area of the mouth in the axial plane is 9-14 mm; the transverse size of the coronary sinus in the middle third in the sagittal plane is 7-9 mm; the transverse size of the coronary sinus in the middle third in the axial plane is 6-8 mm; the transverse size of the coronary sinus at the level of the

oblique vein in the sagittal plane is 5-6 mm; the transverse size of the coronary sinus at the level of the oblique vein in the axial plane - 4-5 mm.

When analyzing sex differences in anthropometric indicators (Table 1) and coronary sinus sizes (Table 2), only significantly higher (p<0.001 in both cases) values of mass and body length were established in men.

Since practically no reliable sex differences were established between anthropometric indicators (only weight and body length are greater in men) or coronary sinus dimensions, no separate distribution of indicators by sex was carried out when assessing the relationships between these parameters.

Table 1. Anthropometric parameters in men and women without coronary artery disease (M±σ).

Indexes	Men	Women	p
Body weight (kg)	84.47±8.72	67.67±8.49	<0.001
Body length (m)	1.763±0.056	1.630±0.048	<0.001
Body mass index (kg/m ²)	27.27±3.52	25.42±2.16	>0.05
Anterior-posterior size of the chest (mm)	235.7±21.8	224.0±24.2	>0.05

Table 2. Computed tomographic dimensions of the coronary sinus in men and women without coronary artery disease (M±σ).

Indexes	Men	Women	p
KS_F (mm)	75.13±13.83	71.22±18.25	>0.05
KS_G (mm)	18.27±3.39	17.67±7.00	>0.05
KS_H (mm)	11.67±2.99	13.89±6.15	>0.05
KS_I (mm)	9.733±2.219	8.556±2.128	>0.05
KS_J (mm)	8.000±2.104	7.111±1.616	>0.05
KS_K (mm)	6.000±1.195	5.556±1.333	>0.05
KS_L (mm)	5.133±1.302	4.778±0.833	>0.05

Table 3. Correlations of coronary sinus dimensions with age, sex and anthropometric parameters in patients without coronary artery disease (n=24).

	AGE	SEX	MAS	ROST	IMT	IMT_1	GR_KL
KS_F	0.04	-0.22	0.35	0.09	0.34	0.22	0.67
KS_G	-0.04	-0.18	0.33	0.21	0.18	-0.01	0.44
KS_H	0.12	0.11	-0.06	-0.03	-0.11	-0.23	0.26
KS_I	-0.02	-0.33	0.34	0.42	0.16	0.10	0.40
KS_J	0.24	-0.22	0.32	0.23	0.21	0.13	0.64
KS_K	0.18	-0.18	0.07	-0.01	0.10	0.13	0.47
KS_L	0.23	-0.13	-0.01	0.04	-0.10	-0.02	0.40

Notes: AGE - age of patients (years); SEX - sex (1 - male, 2 - female); MAS - body weight (kg); ROST - body length (m); IMT - body mass index (kg/m²); IMT_1 - signs of BMI (1 - indicates underweight, 2 - equivalent to normal body weight, 3 - indicates excess weight, 4 - sign of obesity); GR_KL - anterior-posterior size of the chest on a computer tomography (mm); reliable correlations are highlighted in bold; unreliable correlations of medium strength are highlighted in bold italics; direct correlations are highlighted in yellow, orange, and red; feedbacks are highlighted in green.

Table 4. Correlations between coronary sinus dimensions in patients without coronary artery disease (n=24).

	KS_F	KS_G	KS_H	KS_I	KS_J	KS_L
KS_G	0.46					
KS_H	0.25	0.65				
KS_I	0.40	0.45	0.35			
KS_J	0.60	0.40	0.50	0.59		
KS_K	0.09	0.15	0.10	0.30	0.41	
KS_L	-0.06	0.06	0.09	-0.08	0.20	0.63

The results of correlations between the age, sex and anthropometric indicators of patients who underwent CT coronary angiography with the dimensions of the coronary sinus, as well as between the dimensions of the coronary sinus, are shown in Tables 3 and 4.

Discussion

We have established the limits of the percentile range of mass, body length, body mass index, anterior-posterior size of the chest on a computer tomogram, the length of the coronary sinus from the mouth to the oblique vein of the atrium, the transverse size of the coronary sinus in the area of the mouth, in the middle third and at the level oblique vein in sagittal and axial planes in men and women without coronary artery pathology. Significant differences in these indicators between men and women were established only between body weight and length (higher values in men, $p < 0.001$). Therefore, when analyzing correlations between the dimensions of the coronary sinus and with anthropometric parameters of the body, as well as when modeling the dimensions of the coronary sinus, a separate distribution of indicators by sex was not carried out.

When analyzing the correlations between age, sex, weight, body length, body mass index, signs of body mass index that indicate insufficient weight, equivalent to normal body weight, the presence of excess weight, or obesity and the anterior-posterior size of the chest on the computer computed tomography with almost all dimensions of the coronary sinus, multiple reliable direct strong and medium strength, as well as unreliable medium strength direct correlations with the anterior-posterior size of the chest ($r =$ from 0.40 to 0.77) were established. In addition, multiple nonreliable average strength direct relationships of more

than half of coronary sinus dimensions were established with body weight ($r =$ from 0.32 to 0.35). In other cases, correlations are isolated or absent at all.

When analyzing the correlations between the sizes of the coronary sinus in patients who underwent CT coronary angiography, multiple reliable correlations of strong ($r =$ from 0.60 to 0.65) and medium strength ($r =$ from 0.41 to 0.59), as well as unreliable correlations of medium strength ($r =$ from 0.30 to 0.40) are established with more than half of these indicators (most often with the transverse dimensions of the coronary sinus in the middle third in the sagittal and axial planes).

The conducted analysis makes it possible to determine certain regularities of the anatomy of the venous system of the heart, which can be used in the planning of surgical interventions for which the configuration of the coronary venous sinus is important, namely invasive electrophysiological studies, cardiac resynchronization therapy, etc. [1, 5].

Conclusion

1. The limits of the percentile range of anthropometric indicators and computed tomographic dimensions of the coronary sinus in men and women without coronary artery pathology have been established. Significant differences in these indicators between men and women were established only between body weight and length (higher values in men).

2. When analyzing the correlations between the age, sex and anthropometric indicators of patients who underwent CT coronary angiography with the dimensions of the coronary sinus, multiple reliable direct strong and medium strength, as well as unreliable direct relationships of medium strength ($r =$ from 0.40 to 0.67) were established only between virtually all with coronary sinus dimensions and anterior-posterior thoracic dimensions.

3. When analyzing the correlations between the dimensions of the coronary sinus, multiple reliable direct strong and medium strength, as well as unreliable direct relationships of medium strength ($r =$ from 0.30 to 0.65) were established with more than half of these indicators (most often with the transverse dimensions of the coronary sinus in the average third in the sagittal and axial planes).

References

- [1] Alkhouli, M., Lurz, P., Rodes-Cabau, J., Gulati, R., Rihal, C. S., Lerman, A., & Latib, A. (2022). Transcatheter coronary sinus interventions. *Cardiovascular Interventions*, 15(14), 1397-1412. doi: 10.1016/j.jcin.2022.05.039
- [2] Antonov, M. Yu. (2018). *Математическая обработка и анализ медико-биологических данных [Mathematical processing and analysis of biomedical data]*. К.: МИЦ "Мединформ" - К.: MIC "Medinform".
- [3] Bai, W., Xu, X., Ji, H., Liu, J., Ma, H., Xie, H., ... & Guo, Y. (2020). Evaluation of the anatomical variations of the coronary venous system in patients with coronary artery calcification using 256-slice computed tomography. *Plos One*, 15(11), e0242216. doi: 10.1371/journal.pone.0242216
- [4] Christiaens, L., Ardilouze, P., Ragot, S., Mergy, J., & Allal, J. (2008). Prospective evaluation of the anatomy of the coronary venous system using multidetector row computed tomography. *International Journal of Cardiology*, 126(2), 204-208. doi: 10.1016/j.ijcard.2007.03.128
- [5] Gach-Kuniewicz, B., Goncerz, G., Ali, D., Kacprzyk, M., Zarzecki, M., Loukas, M., ... & Mizia, E. (2023). Variations of coronary sinus tributaries among patients undergoing cardiac resynchronization therapy. *Folia Morphologica*, 82(2), 282-290. doi: 10.5603/FM.a2022.0044
- [6] Gilard, M., Mansourati, J., Etienne, Y. V. E. S., Larlet, J. M.,

- Truong, B., Boschat, J., & Blanc, J. J. (1998). Angiographic anatomy of the coronary sinus and its tributaries. *Pacing and Clinical Electrophysiology*, 21(11), 2280-2284. doi: 10.1111/j.1540-8159.1998.tb01167.x
- [7] Ho, S. Y., Sanchez-Quintana, D., & Becker, A. E. (2004). A review of the coronary venous system: a road less travelled. *Heart Rhythm*, 1(1), 107-112. doi: 10.1016/j.hrthm.2003.12.001
- [8] Jongbloed, M. R., Lamb, H. J., Bax, J. J., Schuijff, J. D., de Roos, A., van der Wall, E. E., & Schalij, M. J. (2005). Noninvasive visualization of the cardiac venous system using multislice computed tomography. *Journal of the American College of Cardiology*, 45(5), 749-753. doi: 10.1016/j.jacc.2004.11.035
- [9] Kataoka, K. (1995). Indices of obesity derived from body weight and height. *Nihon rinsho. Japanese Journal of Clinical Medicine*, 53, 147-153. PMID: 7563679
- [10] Meisel, E., Pfeiffer, D., Engelmann, L., Tebbenjohanns, J., Schubert, B., Hahn, S., ... & Butter, C. (2001). Investigation of coronary venous anatomy by retrograde venography in patients with malignant ventricular tachycardia. *Circulation*, 104(4), 442-447. doi: 10.1161/hc2901.093145
- [11] Miao, J. H., & Makaryus, A. N. (2019). *Anatomy, Thorax, Heart Veins*. Treasure Island (FL): StatPearls Publishing. PMID: 31747193
- [12] Mlynarski, R., & Mlynarska, A. (2022). Coronary Sinus Diameter as a Potential Marker of Right Ventricle Impairment. *International Journal of Environmental Research and Public Health*, 19(4), 2217. doi: 10.3390/ijerph19042217
- [13] Mlynarski, R., Mlynarska, A., & Sosnowski, M. (2011). Anatomical variants of coronary venous system on cardiac computed tomography. *Circulation Journal*, 75(3), 613-618. doi: 10.1253/circj.cj-10-0736
- [14] Noheria, A., Desimone, C. V., Lachman, N., Edwards, W. D., Gami, A. S., Maleszewski, J. J., ... & Asirvatham, S. J. (2013). Anatomy of the coronary sinus and epicardial coronary venous system in 620 hearts: an electrophysiology perspective. *Journal of Cardiovascular Electrophysiology*, 24(1), 1-6. doi: 10.1111/j.1540-8167.2012.02443.x
- [15] Sinha, M., Pandey, N. N., & Sharma, A. (2020). Anomalies of the coronary sinus and its tributaries: evaluation on multidetector computed tomography angiography. *Journal of Thoracic Imaging*, 35(2), W60-W67. doi: 10.1097/RTI.0000000000000456
- [16] Sirajuddin, A., Chen, M. Y., White, C. S., & Arai, A. E. (2020). Coronary venous anatomy and anomalies. *Journal of Cardiovascular Computed Tomography*, 14(1), 80-86. doi: 10.1016/j.jcct.2019.08.006
- [17] Sumalatha, S., Hari, V., Quadros, L. S., & D'Souza, A. S. (2015, December). Anatomical variations of coronary venous system and its tributaries: A cadaveric study. *In Journal of Cardiothoracic Surgery* (Vol. 10, No. 1, pp. 1-1). BioMed Central. doi: 10.1186/1749-8090-10-S1-A255
- [18] Tada, H., Kurosaki, K., Naito, S., Koyama, K., Itoi, K., Ito, S., ... & Taniguchi, K. (2005). Three-dimensional visualization of the coronary venous system using multidetector row computed tomography. *Circulation Journal*, 69(2), 165-170. doi: 10.1253/circj.69.165
- [19] Tingsgaard, J. K., Sorensen, M. H., Bojer, A. S., Anderson, R. H., Broadbent, D. A., Plein, S., ... & Madsen, P. L. (2023). Myocardial blood flow determination from contrast free magnetic resonance imaging quantification of coronary sinus flow. *Journal of Magnetic Resonance Imaging*. doi: 10.1002/jmri.28919
- [20] Tori, G. (1951). Radiological visualization of the coronary sinus and coronary veins. *Acta Radiologica*, (5), 405-410. doi: 10.3109/00016925109176991
- [21] Wilson, A., & Bhutta, B. S. (2020). *Anatomy, Thorax, Coronary sinus*. StatPearls Publishing. PMID: 32491498
- [22] Yamada, M., Jinzaki, M., Kuribayashi, S., Sato, K., Tanami, Y., Fukumoto, K., ... & Ogawa, S. (2008). Novel Post-Processing Image for the Visualization of the Coronary Sinus by Multidetector-Row Computed Tomography Before Cardiac Resynchronization Therapy Edge-Enhanced Image. *Circulation Journal*, 72(3), 487-488. doi: 10.1253/circj.72.487

ОСОБЛИВОСТІ АНТРОПОМЕТРИЧНИХ ПОКАЗНИКІВ І РОЗМІРІВ КОРОНАРНОГО СИНУСА ТА ЗВ'ЯЗКІВ МІЖ ДАНИМИ ПОКАЗНИКАМИ У ПАЦІЄНТІВ БЕЗ ПАТОЛОГІЇ КОРОНАРНИХ АРТЕРІЙ

Ліулька Є. М., Білаш С. М.

Останнім часом в Україні спостерігається значний зріст можливостей інвазивного лікування кардіоваскулярних патологій, збільшується кількість кардіохірургічних операцій на відкритому серці та ендоваскулярних інтервенцій. Кожне із таких втручань потребує ендоваскулярної катетеризації коронарного венозного синуса серця, різноманіття анатомічних особливостей якого потребує детального вивчення анатомії венозної системи серця. Мета роботи - встановити особливості розмірів коронарного синуса та антропометричних показників у чоловіків і жінок без патології коронарних артерій, а також зв'язки між даними показниками. Проведено визначення маси, довжини тіла, індексу маси тіла, передньо-заднього розміру грудної клітки, а також розмірів коронарного синуса (довжина коронарного синуса від гирла до косої вени передсердя, поперечний розмір коронарного синуса в ділянці гирла у сагітальній та аксіальній площині, поперечний розмір коронарного синуса в середній третині у сагітальній та аксіальній площині, поперечний розмір коронарного синуса на рівні косої вени передсердя у сагітальній та аксіальній площині) у 15 чоловіків і 9 жінок віком від 44 до 60 років (середній вік відповідно до вікової класифікації Всесвітньої організації охорони здоров'я) без патології коронарних артерій, яким виконували КТ-коронарографію на базі ДУ "Національний інститут серцево-судинної хірургії ім. М. М. Амосова НАМН України". Статистична обробка отриманих результатів проведена в ліцензійному пакеті "Statistica 6.0" із використанням непараметричних методів оцінки. В результаті проведених досліджень встановлені межі процентильного розмаху антропометричних показників та розмірів коронарного синуса у чоловіків і жінок без патології коронарних артерій. При аналізі величини даних показників між чоловіками та жінками встановлені лише достовірно більші значення у чоловіків маси та довжини тіла. Тому при аналізі зв'язків між розмірами коронарного синуса та з антропометричними параметрами тіла розподіл показників за статтю не проводили. При аналізі кореляцій розмірів коронарного синуса з віком, статтю, масою, довжиною тіла, індексом маси тіла, ознаками індексу маси тіла (свідчить про недостатню вагу, еквівалент нормальній маси тіла, вказують на наявність зайвої ваги, або є ознакою ожиріння) та передньо-заднім розміром грудної клітки з практично усіма розмірами коронарного синуса, встановлені множинні достовірні прямі сильні ($r=0,64$ та $r=0,67$) та середньої сили ($r=0,44$ та $r=0,47$), а також недостовірні середньої сили прямі зв'язки з передньо-заднім розміром грудної клітки ($r=0,40$ в обох випадках). Крім того, множинні недостовірні середньої сили прямі зв'язки більш ніж половини розмірів коронарного

синуса встановлені з масою тіла ($r=$ від 0,32 до 0,35). При аналізі кореляцій між розмірами коронарного синуса встановлені множинні достовірні прямі сильні ($r=$ від 0,60 до 0,65) та середньої сили ($r=$ від 0,41 до 0,59), а також недостовірні середньої сили прямі ($r=$ від 0,30 до 0,40) зв'язки більш ніж із половиною розмірів даних показників.

Ключові слова: коронарний синус, КТ-коронарографія, морфометрія, антропометрія, кореляції, чоловіки та жінки без патології коронарних артерій, статеві розбіжності.
