

## Possibilities of Using Phosphate Buffer in the Treatment of Chronic Apical Periodontitis: A Case Report

O.P. Kostyrenko<sup>1</sup>, V.L. Melnyk<sup>2</sup>, V.K. Shevchenko<sup>2</sup>, B.Yu. Sylenko<sup>3</sup>, Yu.I. Sylenko<sup>2\*</sup>

1. Department of therapeutic dentistry, Poltava State Medical University, Poltava, Ukraine.
2. Department of postgraduate dentists' education, Poltava State Medical University, Poltava, Ukraine.
3. Department of prosthodontics and implant dentistry, Poltava State Medical University, Poltava, Ukraine.

### Abstract

The use of nanocrystals for the treatment of chronic apical periodontitis is the contemporary level of medicine. The thesis presents a case of chronic apical periodontitis that show the effective author's treatment modality using phosphate buffer.

It showed that the tissue repair and healing of the apical and adjacent areas of the periodontium had positive dynamics in 14 days after the beginning of treatment.

The offered method of treatment requires further study in the distant future with the aim of wide implementation in practice.

Case report (J Int Dent Med Res 2023; 16(3): 1248-1252)

**Keywords:** Chronic apical periodontitis treatment, phosphate buffer, monocrystals.

**Received date:** 09 February 2023

**Accept date:** 05 June 2023

### Introduction

The goal of modern dentistry is to prevent caries progression by non-invasive management of non-cavitated carious lesions through remineralization. The processes of remineralization of enamel and dentin form calcium chemical bonds in the form of complex compounds. These products enhance the physical strength of the hard tissues of the tooth and the chemical resistance to external factors in the oral cavity. To prevent damage to enamel and dentin, the necessary substances are added to the toothpaste<sup>1</sup>.

The problem of improving treatment and preventive care for patients with chronic apical periodontitis remains one of the most important in modern dentistry. The achievements of practical endodontics provide effective treatment of both single-rooted and multi-rooted teeth with various forms of chronic apical periodontitis. However, according to the literature, after treatment of destructive forms of chronic periodontitis, a rather high percentage of complications remains<sup>2</sup>. In this regard, it is of great interest to study the

effectiveness of drugs that reduce the inflammatory reaction on the part of periapical tissues<sup>3</sup>. At present, patients have a very negative attitude to tooth extraction, therefore, conservative surgical interventions or repeated effective endodontic treatment are required<sup>2</sup>. Long-term exposure of cementum, root dentin, periodontium, and bone tissue to microflora often leads to their destructive lesions.

In the international scientific literature<sup>4-6</sup>, the authors have described various methods of formation and directed growth of apatite crystals on substrates of organic and inorganic origin in buffer environments under the influence of electric field gradients, different pH values, and temperature.

To identify the crystals, in this study we used the calcium-phosphorus ratio<sup>7</sup> — a well-known parameter that characterizes the state of calcium orthophosphates and its usage in dentistry. In the three-component system of the crystal, there are 11 non-ionically substituted orthophosphates with an ionic ratio of calcium to phosphorus from 0.5 to 2.0. For example, for calcium hydroxyapatite, the normal ratio of calcium to phosphorus per unit volume of the material is 1.67. Calcium-deficient apatites correspond to a reduced calcium-phosphorus ratio of 1.5.

The nucleation and formation of crystals occur on inhomogeneities of hard tooth tissues (microcracks, fractures) formed in the process of

#### \*Corresponding author:

Yuriy I. Sylenko, DMD, Professor,  
Department of postgraduate dentists' education,  
Poltava State Medical University, Poltava, Ukraine.  
E-mail: sylenko@gmail.com

dentin destruction<sup>8</sup>. At the same time, the source of calcium ions can be calcium hydroxyapatite of the surface layer of dentin, which has undergone destruction. The transfer of the substance from the cracks to the surface occurs due to the diffusion of ions that are part of the peri- and intertubular dentin. Dentinal fluid can be a donor of calcium ions. The latter ones settle on non-homogeneous dentin surfaces with subsequent formation of crystalline structures. Mechanical defects and areas of dentin destruction have an increased diffusion coefficient of calcium ions. Such a developed surface stimulates the growth of active centers of crystallization. Growing crystalline formations are the only source of formation of new dentin of the tooth root.

For a holistic perception of the processes that characterize mineralization in the hard tissues of the tooth, it is necessary to take into account the influence of oral fluid on the reparative processes in the periodontal tissues. In the same manner, calcium phosphate crystals are formed when the phosphate buffer interacts with periodontal fluid. In this aspect, saliva is a mineralizing liquid that is saturated with calcium ions and phosphate ions and is the source of these ions entering the enamel and dentin of the tooth. Phosphate is found in two forms: as "inorganic" phosphate and bound to proteins. The content of total phosphate in saliva reaches 7.0 mmol/l, inorganic phosphate is 70-95% (2.2-6.5 mmol/l), which is presented in the form of hydrogen phosphate and dihydrogen phosphate. The content of calcium in saliva is different and ranges from 1.0 to 3.0 mmol/l. Calcium, like phosphates, is in ionized form and in combination with proteins. It has been proven that saliva with a calcium/phosphorus ratio of 0.53-0.69 has the maximum mineralizing effect. Mixed saliva contains 2.2-6.5 mmol/l of inorganic phosphate; total phosphate 3.0-7.0 mmol/l. The content of inorganic phosphate in blood plasma is 1.0-1.6 mmol/l; total phosphate 3.0-5.0 mmol/l. Such a concentration of calcium and phosphates is necessary to maintain the stability of tooth tissues<sup>9</sup>.

Based on a review of literary sources and clinical observations<sup>10</sup>, we suggested applying the elements of nanotechnological treatment of chronic periodontitis with the use of a phosphate buffer, for which a corresponding patent was obtained<sup>10-11</sup>. The obtained results of the treatment of this pathology in the nearest and

distant terms are confirmed by positive dynamics<sup>12-13</sup>.

### Case Report

We represent a clinical case of the chronic apical periodontitis treatment according to our treatment modality. 62-year-old man was referred to the therapeutic dentistry department due to the presence of a destroyed tooth on the lower jaw. The man reported slight pain discomfort to biting. The tooth was earlier treated because of the carious process. The examination showed the crown part destruction of mandibular left first molar by 3/4, the painful to percussion, the painless probing of the tooth cavity and the orifice of the root canals. The reaction to thermal stimuli was negative. Palpation of soft tissue overlying mandibular left first molar was painless and had natural color.

The periapical X-ray revealed obliteration of all root canals, and the periodontal ligament space dilatation. In the medial roots periapical zone of mandibular left first molar, there was an oval with indistinct borders radiolucent area of the medium intensity. One should observe the notable sclerosis of the distal root canal, there were no destructive changes near apex. The following diagnosis was made: Chronic apical periodontitis (apical granuloma) of mandibular left first molar.

Method of treatment. We applied phosphate buffer according to our method of treatment of patients with obliterated root canals [4]. This method of treatment was described in the patent of Ukraine No. 137648 released on October 25, 2019 [4]. The latter included the use of phosphate buffer, which was prepared (ex tempore) as follows: in a dental glass crucible, first mix a 15% solution of ammonium phosphate ((NH<sub>4</sub>)<sub>3</sub>PO<sub>4</sub>) in the amount of 13 drops and 1 drop of a solution of phosphoric acid (37%, H<sub>3</sub>PO<sub>4</sub>), included in the set of any dental composite material for hard tooth tissues etching. The required amount of mixture was transferred from the crucible to the dental glass with a plastic spatula and mixed with white clay (quantum satis) until a paste of sour cream consistency was formed. Accordingly, the prepared tooth must be isolated from saliva with rubberdam. Root canals, which could not be passed through with an instrumental method during tooth preparation, should be instrumented to the

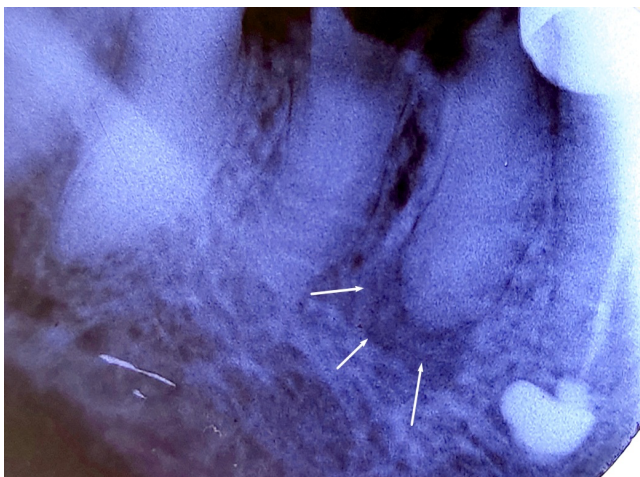
maximum possible working length and their orifices should be flared in a cone-like manner. The made pasty filling material was delivered with lentulo spiral or injectable syringe into the widened orifice and into the root canal of the tooth, then temporary seal with resin modified glass ionomer material was used.

The next appointment was scheduled in 7 days. On the second visit, the temporary seal was removed as well as the paste from the cavity and tooth canal, rinsed with distilled water and dried. The root canal was obturated according to generally accepted methods.

In our clinical case, impregnation with phosphate buffer was carried out 2 times with an interval of seven days for the purpose of phased deposition of calcium phosphate in the area of the root's apex. During the last visit, X-ray control was performed, which confirmed the positive result of the treatment.

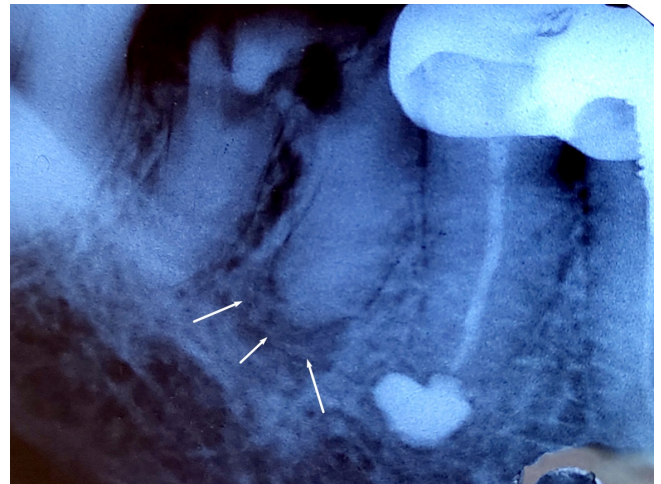
### Treatment results

During the treatment, clinical symptoms decreased. The description of periapical X-ray images (Figs. 1, 2) deserves special attention. In Figure 1, in the area of the mesial root apex of mandibular left first molar, an apparent zone of periapical and alveolar bone destruction was identified in the form of radiolucency zone with indistinct borders.

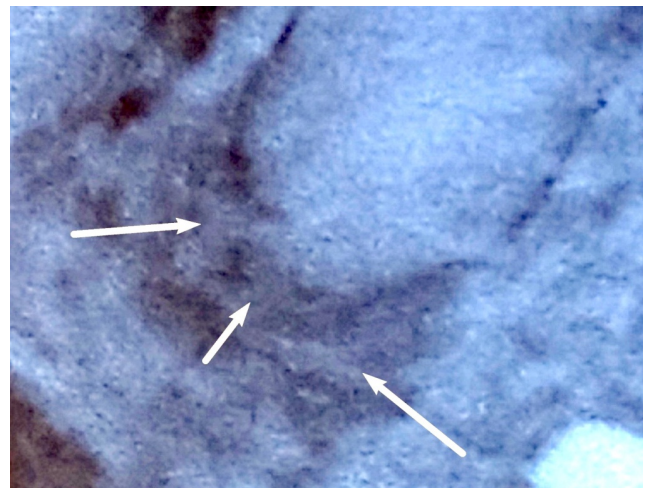


**Figure 1.** 62-year-old man. Periapical X-ray image of mandibular left first molar before treatment. Observations at magnification of 20 times. White arrows represent an apparent zone of periapical and alveolar bone destruction in the form of radiolucency with indistinct borders.

In fourteen days from the beginning of the treatment we observed in the periapical radiograph (Fig. 2) a densification in the focus of destruction: the last one was similar to certain dense shape irregular areas.



**Figure 2.** 62-year-old man. Periapical X-ray image of mandibular left first molar in fourteen days from the beginning of the treatment. Observations at magnification of 10 times. White arrows represent the densification in the focus of destruction.



**Figure 3.** 62-year-old man. Periapical X-ray image of mandibular left first molar in fourteen days from the beginning of the treatment. Observations at magnification of 20 times. White arrows represent a triangular-shaped zone near the anatomic apex of the root.

We suggest, such vague of shades characterized the zones of spongy bone mineralization, which is localized in the area of the radiographic apex and related to the



proliferation of alveolar bone. At magnification (x20), a triangular-shaped zone was found directly near the anatomic apex of the root, which is diffusely interspersed with the adjacent tissues (Fig. 3). We supposed that it correlate with the vascular-nerve bundle of the central root canal. The latter directly participates in the nutrition of the tooth canal and periodontium through the circulation of dentinal fluid saturated with calcium compounds. Moreover, alveolar bone mineralization related with reaction of this interstitial fluid with a phosphate buffer.

At the beginning of the treatment the widening of mesial root periodontal ligament space of mandibular left first molar was observed in the radiograph. During the treatment period (12 days), these areas of periodontal ligament space became tighter and modified its previous contours. At the same time, densification was noted in the form of a specific lightening of the adjacent tissues along the entire perimeter of the root to the apex, which conformed to healing process in the apical periodontal tissues.

## Discussion

The teeth hard tissues restoring in the oral cavity are facilitated by the composition of the periodontal tissues' fluid. It was able to combine chemically with the phosphate buffer due to diffusion and subsequent formation of calcium phosphate nanocrystals. In vitro [3,4,5] the authors noticed that crystals of calcium phosphates we re formed on the surface of dentin treated with an orthophosphoric acid conditioner and kept in an ethanol for 30 days at room temperature. Crystals changed the surface morphology and the composition of the initial material. The physical mechanism of the spontaneous calcium phosphate crystals formation on the inhomogeneity of the dentin surface due to the diffusion of the substance in the solution had been described, as a result of which the dentin subsequently becomes a spatially inhomogeneous substance. It has been found that the formation and growth of crystals occurred through the final ions' redistribution of diffused substances.

The mechanism of spontaneous formation of calcium phosphate crystals in the apical periodontal tissues occurred due to the diffusion of phosphate buffer and calcium ions. As a result, the apical periodontal fluid participated in the

formation of calcium phosphate crystals with subsequent regeneration of bone tissue in areas of its destruction. The obtained results of X-ray studies confirm the dynamics of the reparative process.

## Conclusions

The analysis of clinical and radiological datas of the periapical tissues recovery during the treatment of a patient with chronic apical periodontitis showed that the tissue repair and healing of the apical and adjacent areas of the periodontium has positive dynamics, despite the fact that the mechanical root canal preparation of the sclerosed ones could not be performed in full. The effectiveness of the treatment method we used for the patient was confirmed by the clinical results.

Thus, in the presence of obliterated root canals, this treatment modality of chronic apical periodontitis demonstrates effectiveness in the reduction of treatment timing based on the approximate results of the study. Despite significant successes in the field of crystal growth, the mechanisms of formation and growth of certain types of crystals, in particular apatite crystals in dentin structures, require further study.

## Acknowledgements

This study was supported by the Department of postgraduate dentists' education, Poltava State Medical University, Ukraine.

## Declaration of Interest

The authors report no conflict of interest.

## References

1. Thomas N, Shetty P, Thimmaiah C, Shetty S, Sabu N, Kripalani K. Comparative evaluation of the remineralization potential of Theobromine and Fluoride containing dentifrices using Scanning Electron Microscopy with Energy Dispersive X-Ray Analysis: An in-vitro Study. *J Int Dent Med Res.*2021; 14(4): 1314-1320.
2. Borysenko A, Antonenko M, Lynovyts'ka L, Sidelnikova L, Nesyn O, Dikova I, Rakhnij Zh, Skyba I. Dental diseases: therapeutic dentistry. Kyiv: Medytyna Publ. 2017: 232-664.
3. Kostyrenko O, Bublji T. Irrigation of the root canal system with citric acid solutions in the experiment. Materials of the international practical conference "Stomatological health of the child". - Omsk, 2016: 100 - 102.
4. Nelson D, Barry J, Shields C, Glenna R, Featherstone J. Crystal morphology, composition, and dissolution behavior of carbonated apatites prepared at controlled pH and temperature. *Journal of Colloid and Interface Science* 1989;130 (2):467-9.

5. Dhanaraj G, Byrappa K, Prasad V, Dudley M. Springer handbook of crystal growth. New York: Springer; 2009:315-1816.
6. Nykolaenko S, Tsypperle M, Lobauer U, Dasch W, Petschelt A, Frankenberg R. Investigation of hydroxyapatite biomimetic formation on the surface of dentin. *Stomatology* 2007; 6: 20-25.
7. Elliot J. Structure and chemistry of the apatites and other calcium orthophosphates. Amsterdam: Elsevier; 1994: 389.
8. Bessudnova N, Bylenko D, Venyh S, Galushka V, Zakharevich A. Mechanisms of formation and growth of calcium phosphate crystals on a dentin substrate. *Basics of Biomedical Engineering* 2012; 5-6 (23–24): 21-27.
9. Tarasenko L, Neporada K. *Biochemistry of oral cavity*. Poltava: Ukr. med. stomatol. akad.;2008: 50-72.
10. Kostyrenko O. Enamel and dentin remineralization's method of the tooth root. UA Patent and Trademark Office. <https://rb.gy/0q3ku4>.
11. Kostyrenko O, Mel'nyk V, Shevchenko V, Silenko Yu. The enamel and dentin remineralization method of the tooth root: an information sheet on innovations in the field of health care. Kyiv: Ukrmedpatentinform MOZ Ukrainy, 2021; 2(22):2-3.
12. Kostyrenko O, Mel'nyk V, Shevchenko V., Sylenko Yu.I., Yeroshenko G.A. Application of nanocrystals in treatment of chronic apical periodontitis. *World of medicine and biology*. 2020; 3(73): 61-65.
13. Melnik V, Kostyrenko O, Shevchenko V, Silenko Yu, Yeroshenko G, Shevchenko K, Ryabushko O. Rationale for chronic periodontitis therapy using phosphate buffer nanocrystals. *World of medicine and biology*. 2022; 1 (79): 99–103.