

TRAUMATOLOGY OF MAXILLOFACIAL REGION

УДК [616.716+617.52]-001:378.14=111

Розглянуті та затверджені :

Розглянута на засіданні кафедри хірургічної стоматології та щелепно- лищевої хірургії (протокол №14 від 05.03. 2008 р.), затвердженна ЦМК стоматологічного факультету (протокол № 2008 р.) , затверджена ЦМК ВДНЗУ «УМСА» протокол № від 2008 р.).

Навчальний посібник складений:

М. Г. Скікевич –к.мед.н , доцентом кафедри хірургічної стоматології та щелепно –лицевої хірургії ВДНЗУ «УМСА»

В. М. Гаврильєвим –асистентом кафедри хірургічної стоматології та щелепно –лицевої хірургії ВДНЗУ «УМСА»

Рецензент :

П .І.Ткаченко –д .мед. н, професор кафедри дитячої хірургічної стоматології і пропедевтики хірургічної стоматології та реконструктивної хірургії голови та шиї ВДНЗУ «УМСА»

Підручник для іноземних студентів четвертого курсу стоматологічного факультету з дисципліни «Хірургічна стоматологія » містить інформацію щодо питань черепно-щелепно-лицевої хірургії, зокрема ,клініки, діагностики та лікування переломів кісток лицевого скелету , пошкоджень м'яких тканин обличчя, які оперуються в ургентному порядку. Надаються особливості догляду за постраждалими .

Розрахований на іноземних англомовних студентів та викладачів, які викладають цей розділ на англійській мові.

УДК [616.716 +617.52]-001:378.14=111

ВДНЗУ «УМСА»

М.Г. СКИКЕВИЧ , В.М.ГАВРИЛЬЕВ

ТРАВМАТОЛОГІЯ ЩЕЛЕПНО-ЛИЦЕВОЇ ДІЛЯНКИ

НАВЧАЛЬНИЙ ПОСІБНИК ДЛЯ СТУДЕНТІВ

СТОМАТОЛОГІЧНОГО

ФАКУЛЬТЕТУ 111-1V РІВНІВ АКРЕДИТАЦІЇ

(АНГЛОМОВНОЇ ФОРМИ НАВЧАННЯ)

ПОЛТАВА-2008

ANATOMY OF THE HEAD AND NECK

The physician can easily identify certain bony prominences and foramina, providing quick reference points for important anatomic structures which enable the clinician to describe and localize cutaneous lesions on the face accurately.

The squamous portion of the frontal bone forms the foundation of the forehead. The superciliary arches located deep to the eyebrows form prominent ridges which unite medially forming in midline the glabella. The nasion, a craniometric point located just inferiorly to the glabella, is formed by the median articulation of the paired nasal bones with the frontal bone. On each side, approximately 2 cm laterally from the nasion along the superior margin of the orbit is the supraorbital notch or foramen, through which emerges the supraorbital nerve and artery. The lateral and inferior margins of the orbit are formed by the zygomatic bone with the malar portion forming the prominence of the cheek. The temporal process of the zygomatic bone joins the zygomatic process of the temporal bone to form the zygomatic arch. The maxillary bone forms the inferior and medial margins of the orbit, and located in the body of the maxilla approximately 5 mm below the inferior margin of the orbit is the infraorbital foramen, which transmits the infraorbital nerve and artery onto the face.

The tip of the chin is formed by the mental protuberance of the mandible. The body of the mandible lodges the lower dentition and presents an easily palpable sharp inferior margin. Lateral to the mental protuberance, the mental foramen is located midway in the height of the body of the mandible.

A vertical line drawn on the face, initiated at the supraorbital foramen and extended inferiorly to the inferior margin of the mandible, will intersect the infraorbital foramen 5 mm below the inferior margin of the orbit and the mental foramen midway in the height of the body of the mandible (Fig. 1). Note that in patients with dentures the position of the mental foramen is best located by measuring approximately 1 cm from the inferior margin of the mandible superiorly along the vertical line. This vertical line is a valuable reference line since it allows the clinician to identify quickly the surface anatomy of three foramina and their associated sensory nerves.

Posteriorly, the body of the mandible ends at the angle, and the mandible continues superiorly as the ramus. The ramus terminates as the condylar process, which is positioned directly anteriorly to the external auditory canal.

The mastoid process of the temporal bone is palpable just behind the auricular cartilage at the level of the external auditory meatus. The mastoid process of the adult protects the main trunk

of the facial nerve as it exits the skull through the stylomastoid foramen. In children, pneumatization of the mastoid region does not begin until approximately 5 years of age, rendering the facial nerve at risk during superficial surgical procedures in this region of the neck.

The use of facial diagrams and a millimeter ruler allows the dermatologic surgeon to use the fixed bony prominences to assist in providing exact localization of cutaneous surface tumors and lesions.

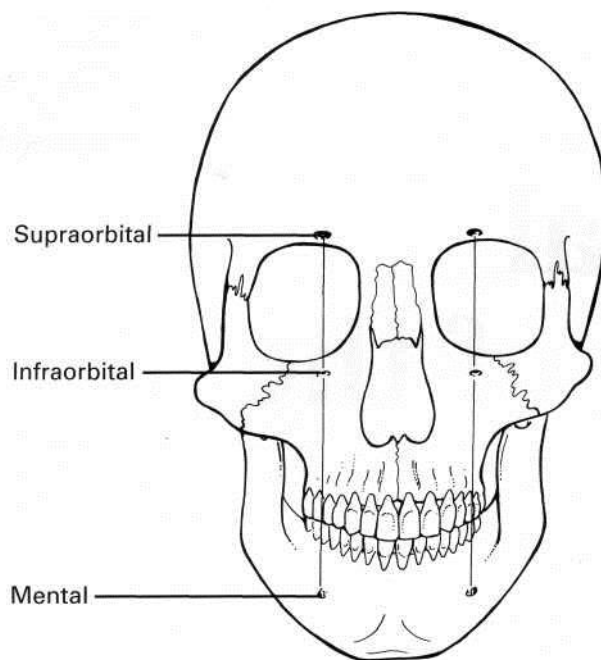


Figure 1. Bony prominences and foramina. Note vertical line intersecting supraorbital, infraorbital, and mental foramina.

FACIAL MUSCULATURE

The mimetic muscles are all innervated by branches of the facial nerve and in general arise from the facial skeleton to insert into the skin. These muscles are grouped with regard to the region of the face: mouth, nose, periorbital, ear, and scalp (Fig. 2).

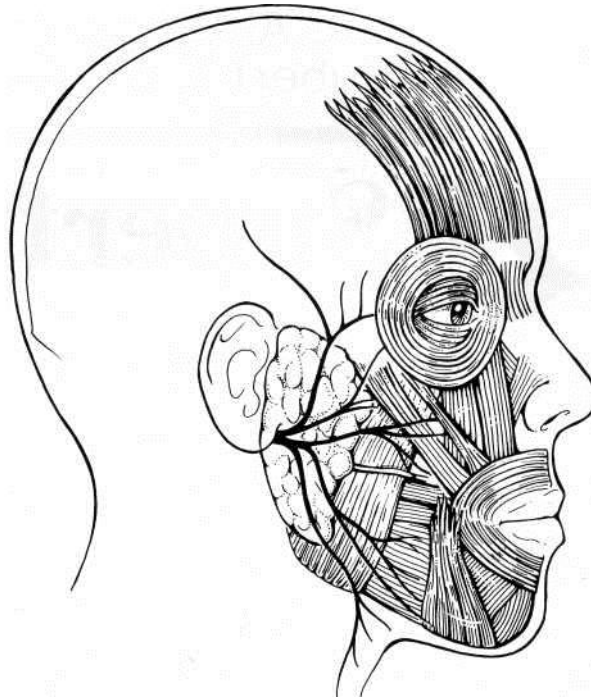


Figure 2. Facial muscles with associated branches of the facial nerve and parotid gland and duct.

Mouth

The oral musculature arises from different regions on the face inserting into the skin and mucosa of the mouth. Generally these muscles can be divided into four groups:

1. The muscles of the lower lip (depressor group)
2. The muscles of the upper lip (elevator group)
3. The cheek bulk muscle (buccinator muscle)
4. The orbicularis oris (lip proper muscle)

The Muscles of the Lower Lip (Depressor Group)

The muscles of the lower lip are the depressor anguli oris, the depressor labii inferioris, and the mentalis.

The depressor anguli oris muscle, originates from the anterolateral aspect of the body of the mandible, inserts into the skin and mucosa at the labial commissure, and depresses the corner of the mouth.

The depressor labii inferioris muscle arises from the mandible deep to the depressor anguli oris muscle; it inserts into the skin and mucosa of the lower lip and depresses the lower lip. The mentalis muscle, arising from the body of the mandible medially to the depressor labii inferioris muscle, inserts into the skin overlying the tip of the chin, effecting protrusion of the lower lip and dimpling of the skin.

All of the lower lip muscles are innervated by the marginal mandibular branch of the facial nerve with secondary innervation from the buccal branches of the facial nerve.

The Muscles of Upper Lip (Elevator Group)

The upper lip consists of the risorius, zygomaticus major and minor, levator labii superioris, levator labii superioris alaeque nasi, and levator anguli oris muscles.

The risorius muscle originates from the parotid fascia, inserts into the skin and mucosa at the corner of the mouth, and pulls the labial commissure laterally, widening the mouth.

The zygomaticus major muscle, originating from the posterolateral aspect of the zygomatic bone, inserts into the skin and mucosa of the lateral upper lip and elevates the labial commissure.

The zygomaticus minor muscle arises just medially to the zygomaticus major muscle, inserts into the skin and mucosa of the upper lip, and elevates the upper lip.

The levator labii superioris muscle arises from the maxilla just above the infraorbital foramen and inserts into the skin and mucosa of the medial upper lip; it is an elevator of the upper lip.

The levator labii superioris alaeque nasi muscle arises from the medial margin of the orbit, first yields fibers into the ala of the nose, and then continues inferiorly to insert finally into the medial aspect of the skin and mucosa of the upper lip. This muscle is an elevator of the lip and dilates the nares.

The levator anguli oris muscle originates from the maxilla just below the infraorbital foramen and inserts into the skin and mucosa at the labial commissure; this muscle elevates the corners of the mouth.

The muscles associated with the upper lip are innervated by the buccal branches of the facial nerve with secondary innervation from the zygomatic branches of the facial nerve.

The Cheek Bulk Muscle (Buccinator Muscle)

The key muscle of the cheek is the buccinator muscle, arising from the posterolateral aspect of the maxilla, the medial aspect of the mandible near the last molar, and the pterygomandibular raphe; it inserts into the skin and mucosa of the labial commissure and the upper and lower lips. This muscle flattens the lips and cheeks against the teeth. The buccinator is innervated by the buccal branches of the facial nerve and is the only muscle of facial expression to receive its innervation from the superficial aspect.

The Orbicularis Oris (Lip Proper Muscle)

The core musculature of the lips is formed by the orbicularis oris muscle, which consists of concentrically arranged fibers circumscribing the mouth. These fibers provide a sphincteric function allowing pursing and protrusion of the lips. The orbicularis oris muscle is innervated by the buccal branches of the facial nerve.

Nose

The muscles of the nose are highly variable in their development and consist of the nasalis and depressor septi muscles.

The transverse portion of the nasalis muscle originates from the body of the maxilla and along with its associate from the opposite side inserts into an aponeurotic sling which passes over the bridge of the nose. A smaller alar portion of this muscle inserts into the lateral crus of the alar cartilage of the nose. The transverse portion of the nasalis compresses the nares, while the alar portion dilates the nares. The nasalis muscle is innervated by the buccal branches of the facial nerve.

The depressor septi muscle, arising from the incisive fossa of the maxilla, inserts into the columella and nasal septum; it narrows the nares. This muscle is innervated by the buccal branches of the facial nerve.

Periorbital

The muscles of the periorbital region include the orbicularis oculi, corrugator supercilii, and the procerus. The orbicularis oculi muscle is a concentrically arranged muscle which is typically divided into two parts: palpebral and orbital. The palpebral part is that portion of the muscle which covers the eyelid; it originates from the superior and inferior aspect of the medial palpebral ligament. Fibers pass laterally in both the upper and lower lids to interdigitate finally at the lateral aspect of the eyelid, thereby forming the lateral palpebral raphe. The orbital part of the orbicularis oculi muscle originates from the medial palpebral ligament, the frontal process of the maxillary bone, and the nasal process of the frontal bone; its fibers extend out beyond the bony margins of the orbit in a series of concentric loops to insert into the overlying skin in the regions of the forehead, as well as the malar and infraorbital areas of the cheek. The palpebral part of this muscle acts to close the eyelid gently, while the orbital part is used for blinking and tight closure of the eyelid. The motor innervation of the orbicularis oculi muscle is from the temporal and zygomatic branches of the facial nerve. Paralysis of these nerve branches leads to ectropion of the lid and inability to close the lids. Reconstruction of various defects in this area may involve local flaps containing not only skin and subcutaneous tissue, but also including underlying muscle (i.e., myocutaneous flap).

The corrugator supercilii muscle arises from the medial part of the superciliary ridge to insert into the skin of the eyebrow; it pulls the eyebrow medially. This muscle is innervated by the temporal branches of the facial nerve.

The procerus muscle originates from the superior aspect of the nasal bones to insert into the skin overlying the root of the nose; it pulls the medial aspect of the eyebrows inferiorly. The procerus muscle is innervated by the temporal branches of the facial nerve.

Ear

The anterior auricular muscle, the superior auricular muscle, and the posterior auricular muscle arise from the scalp and insert into the skin and auricle as their names suggest. Functionally, these muscles are of no clinical importance and are innervated by posterior and temporal branches of the facial nerve.

Scalp

The most important epicranial muscle of the scalp is the occipitofrontalis muscle. The small occipital belly arises from the mastoid process and superior nuchal line of the occipital bone to insert into the galea aponeurosis of the scalp; this muscle pulls the scalp posteriorly. The frontal belly arises from the anterior aspect of the galea aponeurosis and inserts into the skin of the forehead and eyebrows; it acts to pull the scalp anteriorly and elevates the eyebrows. The occipital belly is innervated by the posterior auricular branch of the facial nerve, and the frontal belly is innervated by the temporal branch of the facial nerve. Selecting or removing a portion of the temporal branch will result in lack of innervation of the frontalis muscle with possible drooping of the eyebrow and ptosis of the upper lid.

THE SUPERFICIAL MUSCULAR APONEUROTIC SYSTEM

The *superficial muscular aponeurotic system (SMAS)* is defined as the combination of the muscles of facial expression and the investing layer of superficial fascia. This fascial layer envelops the facial muscles more distinctly and definitively in certain areas, specifically the lower face, mid-face, and forehead regions.

The fascial component of SMAS originates in the neck as the superficial cervical fascia, envelops the platysma muscle, sweeps over the mandible, and invests the muscles of the face. The fascia is tightly bound to the mastoid process of the temporal bone, the deep fascia investing the sternocleidomastoid muscle, and the fascia of the parotid gland approximately 1 to 2 cm anterior to the tragus, with points of attachment to the periosteum of the zygomatic arch via fine fasciculi. The fascia is very thin within the temporal zone and is difficult to separate from the deep temporal fascia.

The fascia provides a functional network which binds nearly all of the muscles of facial expression together, allowing them to act in concert with one another, providing a mechanism for evenly distributing the pull of the muscles upon the overlying skin, and acting as a fire screen preventing the spread of infection from superficial to deep areas of the face.

THE PRIMARY RESTING SKIN TENSION LINES

The muscles of facial expression insert into the overlying skin, causing the skin to fold or crease in a predictable pattern. These creases are referred to as *resting skin tension lines (RSTLs)*, and typically they occur perpendicular to the long axis of the underlying muscle (Fig. 3). Incisions made parallel to these lines produce a fine linear scar, while incisions made perpendicular to these lines will produce an irregular hypertrophic scar.

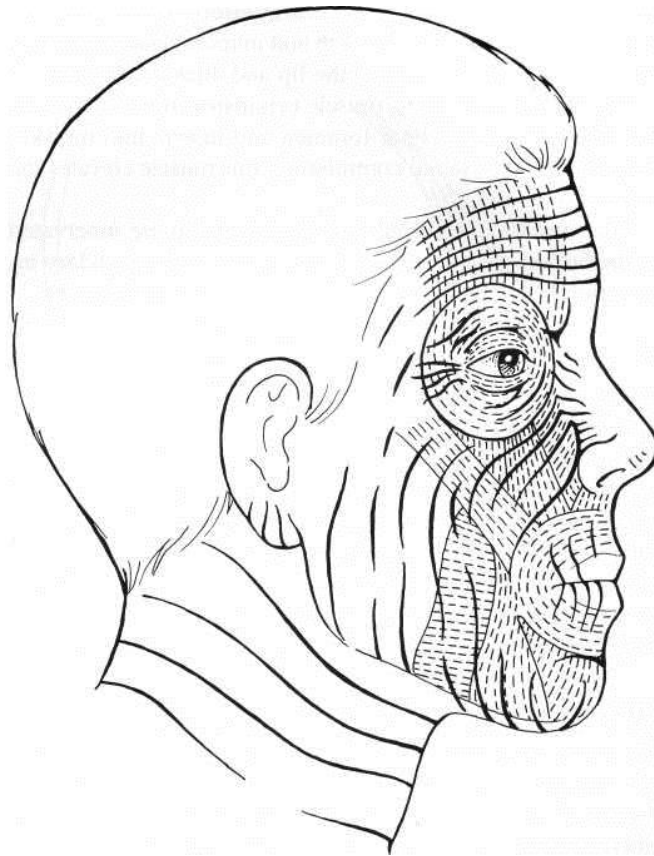


Figure 3. Primary resting skin tension lines of the face. Typically they occur perpendicularly to the long axis of the underlying muscles.

The position of RSTLs on the face is usually very predictable, although certain areas of the face seem to contradict the prediction formula for RSTLs (e.g., the periorbital region). However, since SMAS is very tenuous in the periorbital region, the muscle attachment to the overlying skin is very weak, thereby permitting RSTLs to be primarily influenced by gravity and muscles of the orbit. In order to best demonstrate the position of the RSTLs, the physician should ask the patient to perform a variety of exaggerated facial expressions which should help predict the position of the RSTLs.

The RSTLs of the forehead are oriented horizontally due to the frontalis muscle. In the region of the glabella, RSTLs can be found as vertical lines due to the corrugator supercilii muscle and transverse lines over the nasion due to the pull of the procerus muscle.

The periorbital regions demonstrate radial lines at the medial and lateral canthi due the orbicularis oris muscle. The RSTLs of the lids are horizontal due to the pull of gravity and the levator palpebrae superioris muscle of the orbit.

The skin of the nose demonstrates no predictable RSTLs.

The skin of the mid-face and perioral regions demonstrates the expected RSTLs. The pull of the orbicularis oris causes skin tension lines to radiate from the perimeter of the mouth. The zygomaticus muscles help accentuate the melolabial fold, while the risorius muscle helps create the vertical skin folds found over the cheek.

It should be remembered that some variation of the RSTLs will occur from one individual to the next. Secondary skin tension lines, which frequently occur perpendicular to RSTLs, can be due to aging of the skin, sun damage, altered states of hydration, or redundant folds of skin due to recent weight loss.

The placement of excision and/or closure lines within or parallel to RSTLs may provide a more favorable cosmetic result. However, on certain occasions, one may violate this principle in order to avoid or protect underlying critical anatomic structures (i.e., temporal branch of the facial nerve).

BLOOD SUPPLY OF THE FACE

The arteries supplying the face form a network derived from branches of the external carotid and the internal carotid arteries (Fig. 4).

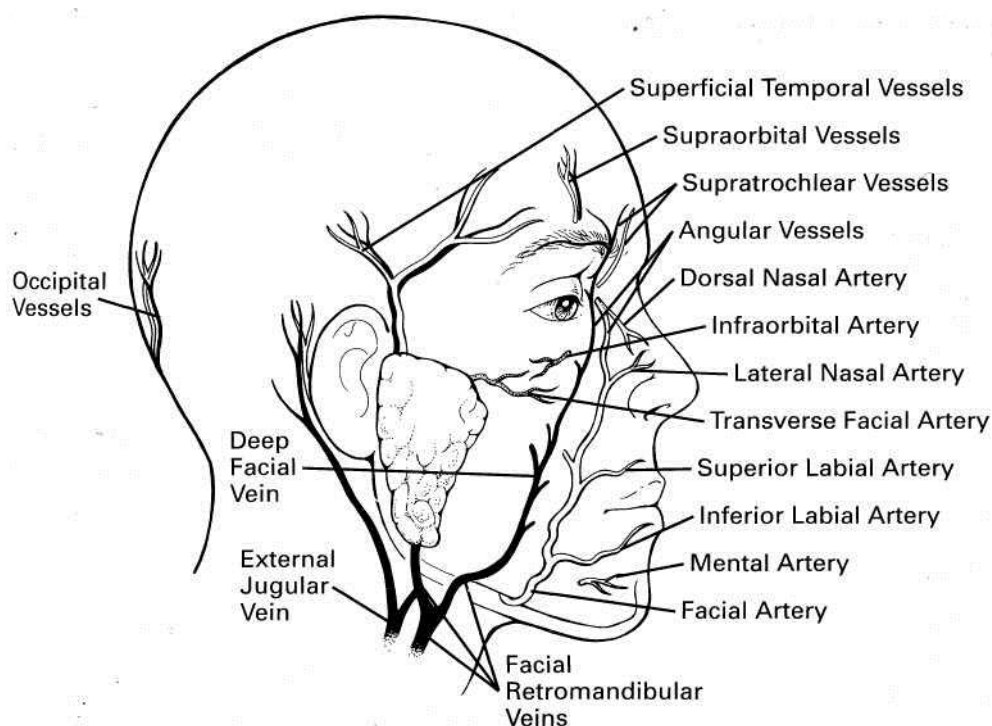


Figure 4. Vascular supply to the face. Both the external carotid and internal carotid systems contribute to facial vasculature.

The facial artery, a branch of the external carotid artery in the neck, grooves the submandibular gland to then hook upward around the mandible to reach the face. Palpable as it crosses the mandible at the anterior edge of the insertion of the masseter muscle, the facial artery passes superficially to the buccinator muscle and pursues a tortuous course toward the medial angle of the eye. The first branches arising from the facial artery are the inferior and superior labial arteries, which anastomose freely across the midline with their associates from the opposite side and weave sinuously through the muscle fibers of the orbicularis oris muscle. The facial artery

continues as the angular artery, and, as it runs along the lateral margin of the nose toward the eye, it supplies the lateral nasal artery, which supplies most of the external nose.

Numerous anastomoses exist between the facial artery and branches of the maxillary and superficial temporal arteries: the inferior labial artery with the mental artery from the inferior alveolar artery over the chin, as well as small muscular branches of the facial with the buccal and infraorbital arteries derived from the maxillary artery.

The facial artery terminates at the medial aspect of the eye as the angular artery. The angular artery freely communicates with the supraorbital artery, the supratrochlear artery and dorsal nasal arteries which are each derived from the ophthalmic artery via the internal carotid artery.

The temporal region is supplied by the superficial temporal artery. The forehead receives the frontal branch of the superficial temporal artery and is reinforced by the supraorbital and supratrochlear arteries. The posterior scalp is supplied by the occipital and postauricular arteries derived from the external carotid artery. The remainder of the scalp is supplied via branches from the occipital, postauricular, superficial temporal, and supraorbital arteries.

The facial venous system parallels the arterial distribution. The temporal and lateral forehead regions drain into the superficial temporal vein, while the medial forehead drains into the supratrochlear and supraorbital veins which communicate with the ophthalmic venous system and the angular vein at the medial aspect of the eye. The angular vein descends along the lateral aspect of the nose and receives the venous drainage of the nose. The angular vein is joined by the superior and inferior labial veins to form the anterior facial vein. The anterior facial vein crosses the mandible just posteriorly to the facial artery to join the internal jugular vein. The temporal and parietal scalp, anterolateral ear, and posterior facial regions drain into the superficial temporal vein which joins the maxillary vein to form the retromandibular vein. The retromandibular vein passes through the parotid gland and bifurcates into an anterior and a posterior branch. The anterior branch joins the anterior facial vein, while the posterior division joins the posterior auricular vein to form the external jugular vein.

LYMPHATICS OF THE HEAD

The lymphatic system of the scalp and face drains into regionally located lymph nodes found in close association with the primary venous pathways.

The occipital region drains into scattered occipital nodes found along the superior nuchal lines. The retroauricular nodes located over the mastoid process receive lymphatic drainage from the occipital, parietal, and temporal scalp as well as the posteromedial auricle (Fig. 5).

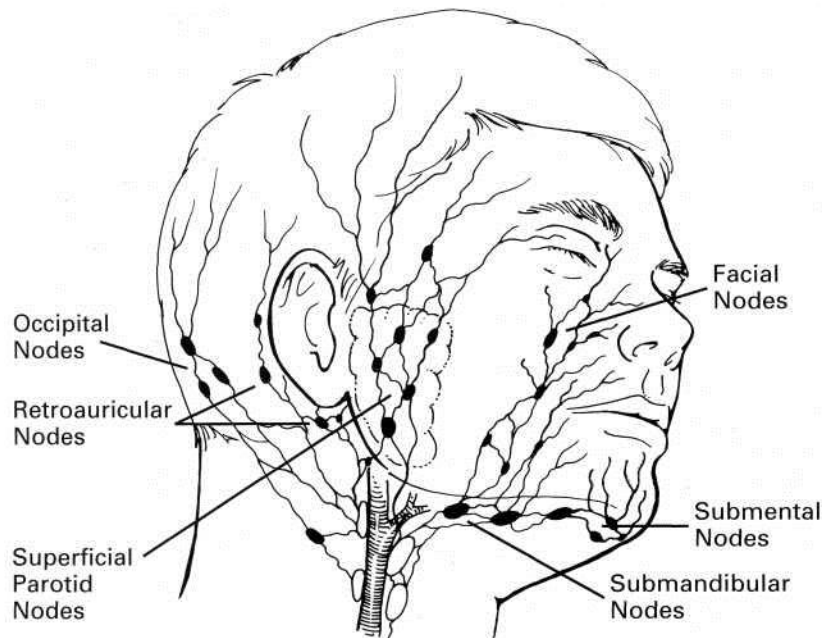


Figure 5. Lymphatics of the scalp and face. In the event of metastasis, most cutaneous squamous cell carcinomas of the face and scalp will spread initially to the draining lymph nodes.

The forehead, temporal, and lateral canthal regions drain into preauricular or superficial parotid nodes. The medial eyelids, nose, cheek, and upper lips drain into the scattered facial nodes which parallel the facial vein.

The lips and mental region drain into submental and submandibular nodes located within the neck. The upper lips drain into the ipsilateral submandibular nodes; the lateral aspect of the lower lips drains into the ipsilateral submandibular nodes, while the medial aspect of the lower lips drains into ipsilateral and contralateral submental and submandibular lymph nodes. Squamous cell carcinomas of the skin of the head and neck which metastasize normally do so to the first echelon lymph nodes; thus, evaluation of those nodes is critical.

THE PAROTID GLAND

The parotid gland is positioned superficially to the masseter muscle, just anteriorly to the ear, and has a somewhat triangular configuration (Fig. 6). The superior pole of the parotid gland is located just anteriorly to the ear and immediately below the zygomatic arch; the inferior pole extends inferiorly, nearly to the angle of the mandible. The gland's posterior margin parallels the posterior edge of the ramus of the mandible, while its isthmus lies wedged between the external auditory canal and the ramus of the mandible; the anterior margin extends a variable distance anteriorly over the masseter muscle toward the buccal region of the cheek. The parotid duct emerges from the anterior border of the gland, turns medially at the anterior edge of the masseter, and then penetrates the buccinator muscle to empty into the buccal vestibule opposite the second upper molar. The duct is easily palpable at the anterior edge of the masseter at a point midway

between the zygomatic arch and the labial commissure. At times, the duct may be injured when deep tumors are removed. Immediate repair is indicated if possible.

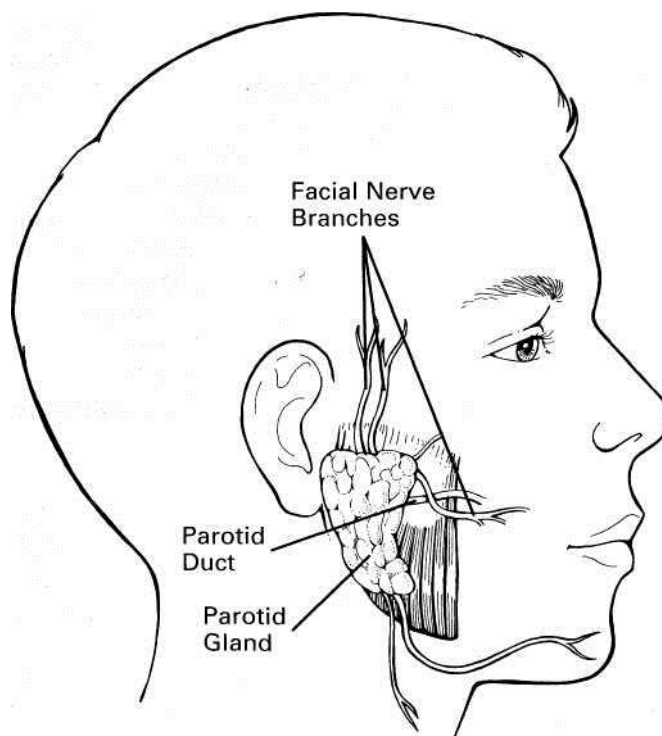


Figure 6. The parotid gland and duct. In many patients, the duct can be palpated at the anterior edge of the masseter muscle.

THE FACIAL NERVE

The facial nerve leaves the base of the skull via the stylomastoid foramen, coursing downward, laterally, and anteriorly. The first extracranial branch, the posterior auricular, passes posteriorly to supply the occipital belly of the occipito-frontalis muscle and the posterior auricular muscle. Continuing anteriorly, the facial nerve penetrates the deep surface of the parotid gland, which protects the nerve during its intra-glandular course. Within the parotid gland, the facial nerve divides into five major branches (temporal, zygomatic, buccal, marginal mandibular, and cervical), which then leave the parotid gland and are named for the region of the face they supply (Fig. 7).

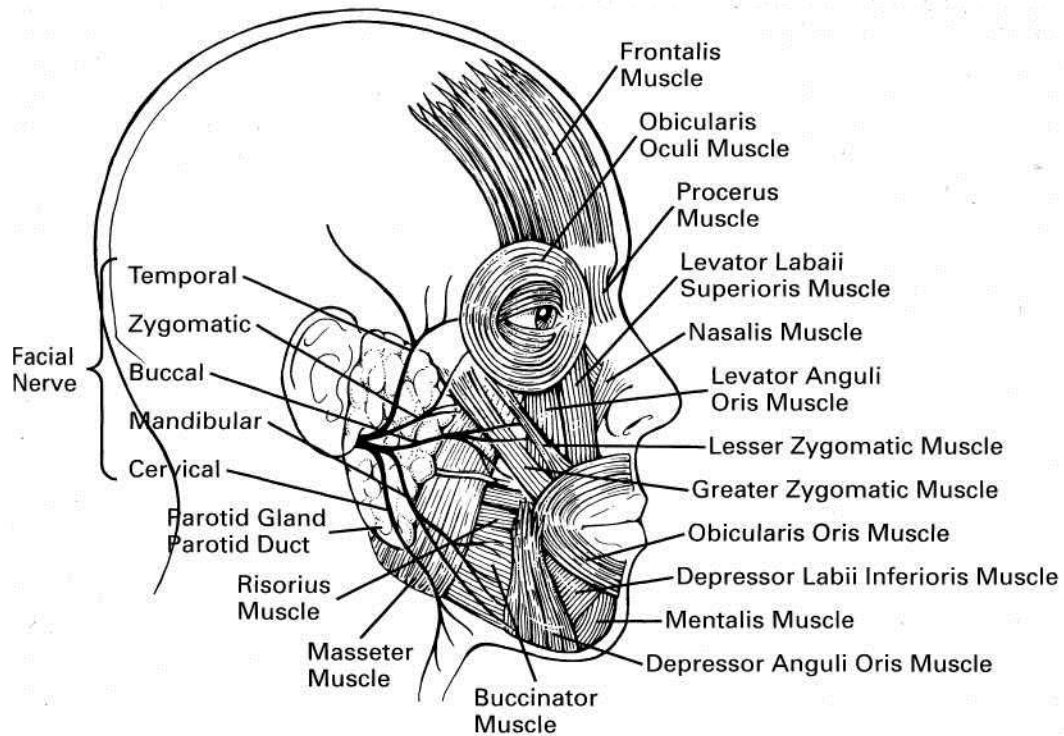


Figure 7. The five major branches of the facial nerve (temporal, zygomatic, buccal, marginal mandibular, and cervical).

The extraparotid course of the facial nerve branches may be divided into safe and danger zones. The branches of the facial nerve have not arborized extensively within its danger zone, and cutting a nerve branch in this area may cause a motor deficit. The area outside the danger zone is called the "safe zone" because the facial nerve branches have extensively arborized, and cutting a small peripheral branch creates no significant motor deficits. The danger zone is delineated by a line drawn 1 cm above and parallel to the zygomatic arch, starting at the auricle and finishing at the lateral margin of the orbit. A vertical line is drawn from the lateral margin of the orbit inferiorly to the inferior margin of the mandible at the insertion of the masseter muscle; this is connected to a line curving 2 cm below the mandible to terminate at the angle of the mandible posteriorly. The area circumscribed by these boundaries on the posterior face is defined as the *danger zone* of the facial nerve (Fig. 8).

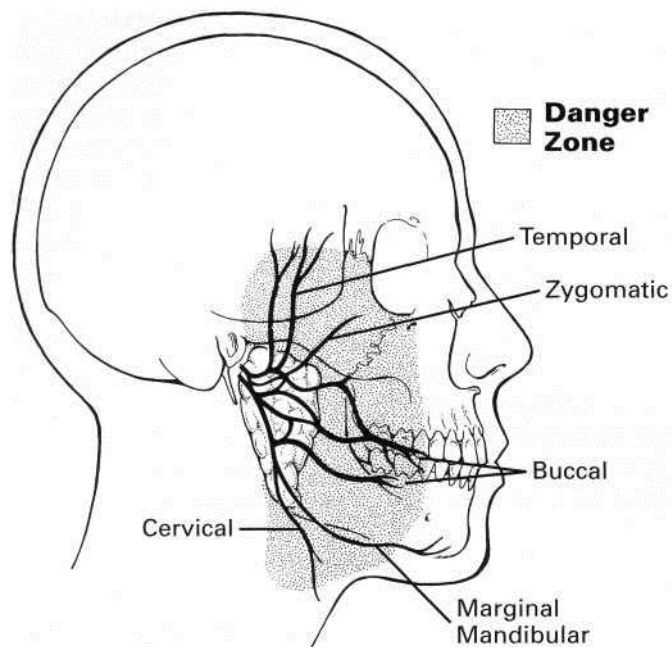


Figure 8. The danger zone area of the face where the branches of the facial nerve may be more at risk for damage during cutaneous and superficial surgical procedures (see text for boundaries).

The temporal branches of the facial nerve leave the superior pole of the parotid gland and pass superficially to the zygomatic arch to supply the anterior and superior auricular muscles, the orbicularis oculi muscle, the frontal belly of the occipitofrontalis muscle, the corrugator supercilii muscle, and the procerus muscle. Damage to the nerve may cause drooping of the ipsilateral eyelid and inability to close the lid tightly. In dermatologic surgery, this branch of the facial nerve is the one most commonly injured.

The zygomatic branches of the facial nerve leave the anterosuperior aspect of the parotid gland and proceed toward the lateral angle of the eye. These branches supply the orbicularis oculi muscle and the zygomaticus major and minor muscles, with secondary innervation to the levators of the lip. Damage to this branch results in an ectropion of the lower eyelid, weakness in blinking, inability for tight closure of the eyelid, and moderate facial asymmetry when smiling. The use of an eye patch may be indicated.

The buccal branches emerge from the anterior border of the parotid gland and parallel the parotid duct, supplying the buccinator muscle, risorius muscle, orbicularis oris muscle, levators of the lip, depressor septi muscle, and nasalis muscle, with secondary innervation to the depressor anguli and depressor labii inferioris muscles. Injury to these branches results in weakness in the oral sphincter (unable to whistle or pucker lips) and facial asymmetry related to unopposed pull from the normal side.

The marginal mandibular branches of the facial nerve exit the inferior pole of the parotid gland to parallel the inferior margin of the mandible. In elderly patients, these nerve branches may descend 2 cm below the inferior margin of the mandible before they ascend back up onto the face at the insertion site of the masseter muscle into the mandible. The marginal mandibular branches

continue forward, superficially to the facial artery and vein, finally to innervate the depressor anguli oris, depressor labii inferioris, and mentalis muscles. Damage to these branches causes facial asymmetry when talking or smiling. This branch may be more susceptible to damage toward the mid-face due to its lack of peripheral branches.

The cervical branches of the facial nerve emerge from the inferior pole of the parotid gland, descending behind the angle of the mandible into the neck to innervate the platysma muscle.

The use of local anesthetics may also cause temporary deinnervation of the various nerve branch or branches, with subsequent lack of muscle innervation and muscle drooping, asymmetry, and so forth. Depending on the type of anesthesia and duration of action (i.e., longer for long-acting local anesthetics such as Marcaine), this deficit may exist for several hours. Thus a patient with inability to close the eye due to local anesthetic action may require a temporary eye patch to protect the eye until the action of the local anesthetic has worn off.

SENSORY INNERVATION OF THE FACE AND SCALP

The sensory innervation to the skin of the face is primarily from the trigeminal nerve via its three divisions: ophthalmic, maxillary, and mandibular (Fig. 9).

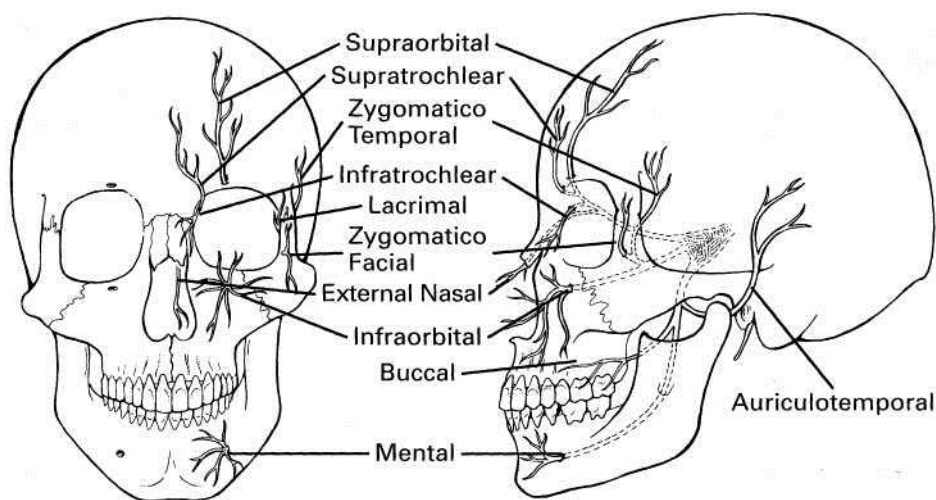


Figure 9. Sensory innervation to the skin of the face via branches of the trigeminal nerve.

Ophthalmic Division

The supraorbital and supratrochlear nerves supply the skin of the medial upper eyelid, forehead, and scalp as far superiorly as the crown. The infratrochlear nerve innervates skin over the medial upper eyelid and bridge of the nose. The lacrimal nerve supplies skin over the lateral upper eyelid.

The dorsal external nasal nerve is the terminal branch of the anterior ethmoidal nerve and supplies a strip of skin over the dorsum of the nose down to the tip.

Maxillary Division

The infraorbital nerve supplies the skin of the lower eyelids, lateral sides of the nose, upper lips, and buccal cheek.

The zygomatic nerve splits into zygomaticofacial and zygomaticotemporal nerves which supply skin over the malar region of the cheek and anterior temporal scalp region.

Mandibular Division

The mental nerve innervates the skin of the chin and lower lip extending laterally to the labial commissure.

The buccal nerve descends into the cheek between the temporalis and buccinator muscles, supplying the skin of the buccal cheek.

The auriculotemporal nerve passes posterior to the neck of the mandible to accompany the superficial temporal artery; it supplies the upper antero-lateral quadrant of the auricle, anterior half of the external auditory canal and tympanic membrane, and most of the temporal scalp region.

The use of nerve blocks (i.e., supraorbital, infraorbital, and mental) may offer advantages in dermatologic surgery in many instances.

THE NECK

Surface Anatomy of the Neck

Several landmarks are palpable in the neck and provide useful reference points (Fig. 10).

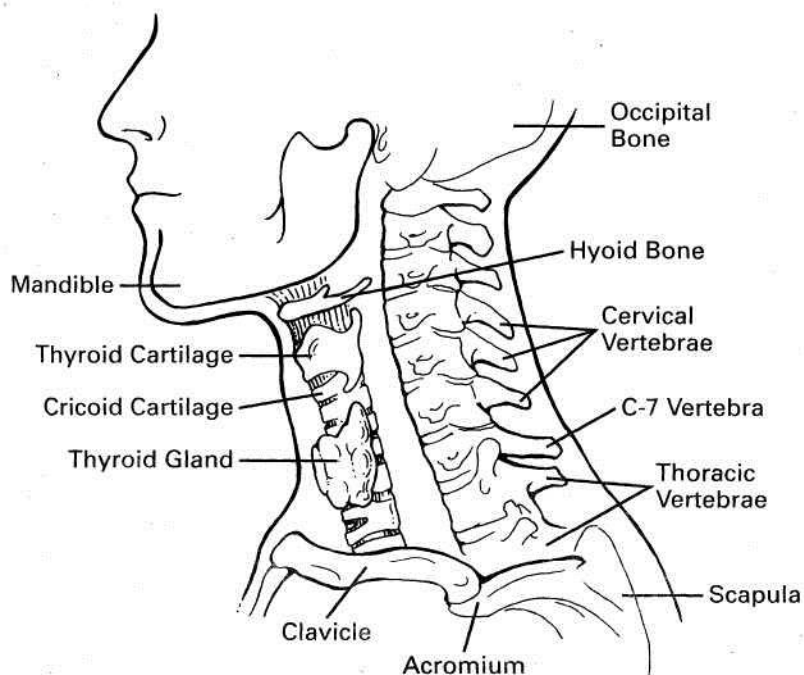


Figure 10. Palpable landmarks of the neck which can be utilized as reference points.

Approximately 2.5 to 3 cm below the chin, the body of the hyoid bone is identified in midline. Inferior to the hyoid bone, the prominence of the thyroid cartilage is palpated in midline. Just below the thyroid cartilage, the anterior lamina of the cricoid cartilage is easily identified. The

interspace between the thyroid and cricoid in midline is filled by the cricothyroid ligament and represents an important site for emergency access to the airway. Inferior to the cricoid are the prominent tracheal rings.

In the posterior neck, the superiormost reference point is the external occipital protuberance, palpable in midline on the occipital bone. When the patient's neck is flexed, the first palpable spinous process is the spinous process of the seventh cervical vertebra (*vertebra prominens*), demarcating the base of the neck.

Triangles of the Neck

The important landmarks of the *anterior triangle* (Fig. 11) of the neck are as follows: the mastoid process of the temporal bone, the tip of the chin, the midpoint of the manubrium, and the anterior border of the sternocleidomastoid muscle. The anterior triangle is further subdivided into four smaller triangles: the submandibular, the submental, the carotid, and the muscular.

The submandibular triangle is outlined by lines drawn from the mastoid process to the tip of the chin, to the lesser cornu of the hyoid bone, and back to the mastoid process. This triangle contains the submandibular gland, facial artery and vein, branches of the facial nerve (cervical and marginal mandibular), and lymph nodes.

The boundaries of the submental triangle are a line drawn from the tip of the chin to the middle of the hyoid bone, laterally to the lesser cornu of the hyoid, and back to the tip of the chin; it contains scattered lymph nodes.

The boundaries of the carotid triangle are identified by lines drawn from the mastoid process to the lesser cornu of the hyoid, from the hyoid to the junction of the lower one-third with the middle one-third of the anterior border of the sternocleidomastoid muscle, and back to the mastoid process. The major structures contained within the carotid triangle are the carotid arteries, the internal jugular vein, and associated lymph nodes. The muscular triangle, extending from the middle of the hyoid, inferiorly to the manubrium, along the anterior edge of the sternocleidomastoid muscle to its junction of the lower one-third with the middle one-third, back to the middle of the hyoid, contains the thyroid gland.

The *posterior triangle* of the neck, initiated at the mastoid process, is bounded posteriorly by the anterior edge of the trapezius muscle, anteriorly by the posterior border of the sternocleidomastoid muscle, and inferiorly along its base by the clavicle. An important superficial structure located within the posterior cervical triangle is the spinal accessory nerve, which emanates from the posterior border of the sternocleidomastoid muscle (Fig. 11) and traverses the triangle obliquely to penetrate the anterior edge of the trapezius muscle. The spinal accessory nerve is at risk for damage during its entire course through the posterior cervical triangle since it is covered only by the superficial cervical fascia and skin. The external jugular vein, formed near the angle of the

mandible, descends vertically across the sternocleidomastoid muscle, finally emptying into the subclavian vein at the base of the posterior cervical triangle.

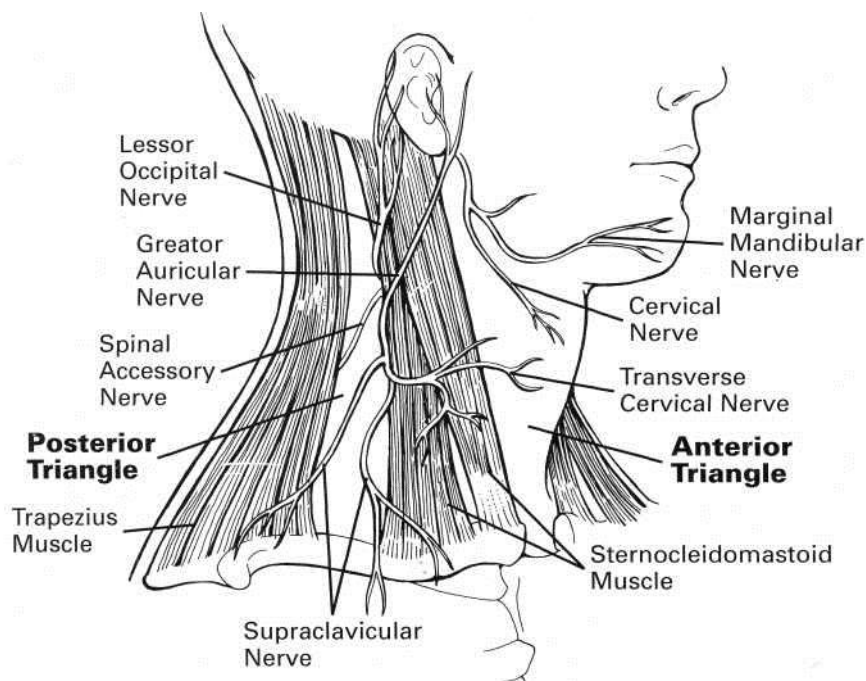


Figure 11. Anterior and posterior triangles of the neck with sternocleidomastoid muscle. Motor and sensory nerve supply.

SUPERFICIAL CERVICAL MUSCULATURE

Overlying nearly the entire anterior triangle of the neck from the clavicle to the mandible, the paper-thin platysma muscle arises from the upper thoracic fascia to insert into the skin of the lower face and lower lateral lip. The platysma tenses the skin over the neck, pulls the lower lip downward and laterally, and is innervated by the cervical branches of the facial nerve. This muscle never shelters the accessory spinal nerve within the posterior cervical triangle and covers only the most inferior aspect of the posterior cervical triangle. The most important landmark within the neck is the sternocleidomastoid muscle, which extends obliquely across the neck from the clavicle and sternum, inserting into the mastoid process of the temporal bone and innervated by the spinal accessory nerve.

BLOOD SUPPLY OF THE NECK

The deeply positioned external carotid artery and thyrocervical trunk supply penetrating branches to the overlying skin and superficial structures located within the anterior and posterior cervical triangles.

The superficial veins of the neck consist of the anterior and external jugular venous systems. The anterior jugular vein, small and irregularly placed, located just deeply to the platysma muscle, originates within the submental triangle, descends toward the lower aspect of the muscular triangle, and passes posteriorly to the sternocleidomastoid muscle to terminate in the external jugular vein.

The external jugular vein arises over the sternocleidomastoid muscle by the union of the postauricular vein and descends vertically to enter the subclavian vein within the posterior cervical triangle.

The superficial lymphatic system of the neck drains into the nodes of the superficial cervical lymphatic chain which parallels the external jugular vein. Scattered nodes located within the submental and submandibular triangles drain into the jugulodigastric node with direct drainage into the deep cervical lymphatic chain.

NERVES OF THE NECK

The most important motor nerve encountered in a superficial dissection of the neck is the spinal accessory nerve (Fig. 11). Emerging from approximately the junction of the upper and middle one-third of the posterior border of the sternocleidomastoid muscle, it passes inferiorly and obliquely across the posterior cervical triangle to innervate the trapezius muscle finally. The spinal accessory nerve is at risk for damage during its entire passage within the posterior cervical triangle because it is covered only by thin skin and a layer of fascia.

Another motor nerve which briefly traverses the neck is the main stem of the facial nerve. Emerging from the base of the skull through the stylomastoid foramen, the facial nerve quickly penetrates the posterior aspect of the parotid gland and splits into five terminal branches (temporal, zygomatic, buccal, marginal mandibular, and cervical). Only the cervical and marginal mandibular branches have important relationships in the neck. The cervical branches of the facial nerve exit the inferior pole of the parotid gland and descend below the angle of the mandible to innervate the platysma muscle. The marginal mandibular branch of the facial nerve normally parallels the inferior margin of the mandible, but in the elderly it frequently descends into the submandibular triangle of the neck before it ascends back up onto the face to supply the lower lip musculature.

The cutaneous sensory input is provided via branches of the cervical plexus (Fig. 11). These nerves emerge from the posterior edge of the sternocleidomastoid muscle at approximately its midpoint to supply the overlying skin of the anterior and posterior cervical triangles. The largest and most frequently injured of the cervical plexus branches is the greater auricular nerve; it crosses superficially to the sternocleidomastoid muscle to ascend directly toward the auricle, and supplies the skin overlying the upper half of the sternocleidomastoid muscle, posteromedial and anterolateral auricle, and the posteroinferior region of the face. The lesser occipital nerve passes along the posterior border of the sternocleidomastoid muscle supplying skin overlying the apex of the posterior cervical triangle, the posteromedial auricle, and occipital scalp. The transverse cervical nerves cross the superficial aspect of the sternocleidomastoid muscle horizontally, supplying the skin overlying the anterior cervical triangle. The supraclavicular nerves (medial, intermediate, and

lateral), descend to supply the skin overlying the lower half of the posterior cervical triangle, upper chest, and lower one-third of the anterior cervical triangle.

Knowledge of the normal superficial anatomy of the head and neck is critical to proper tumor removal, reconstruction, and dermatologic surgery.

WOUNDS

DEFINITION

Wounds (vulnus) are the mechanical damage of the organism, which occur from destroying the integrity of the covered tissues - skin or mucous membrane. During this damage there can be destroyed more deep tissues, inner organs (damage of the brain, liver, stomach, kidneys and others). The injury of the covered tissues separates the wound from other kinds of damage. For example the injury of the liver, which is caused by the dull trauma of the abdomen without destroying the skin, is the rupture and the damage during the stroke by a knife in the abdominal region-wound of the liver, because we observe the destroying of the skin.

The main features of the wounds

The main clinical features of the wounds are pain, bleeding and hiatus. Their development depends on the localization of the wounds, mechanism of the damage, volume and deepness of the injury, and common condition of the patient.

I. Pain (dolor)

It caused by direct damage of the nerves in the wounds region, and in result if it's freezing during the development of the swelling. The pain can be localized not only in the place of damage but also it can be spread over the whole region of innervation.

The intensity of pain syndrome in case of the wound by the next features is determined:

1. Localization of the wound.
2. Injuries of the big nerves trunks are present.
3. The character of the weapon and the frequency of causing and wound - the weapon is sharp

and the damage of the receptor is less, and the pain is less.

4. Nerves - psychological condition of the organism. Pain feeling can be decreased when the patient is in the condition of effect, shock, alcohol or narcotic influence. Pain is not present during the operation with anesthesia, and during such a disease, like syringomyelia (the damage of the gray instances of the spinal cord).

Pain is the protective reaction of the organism, but long and intense pain causes exhaustion of the central nervous system.

II. Bleeding (haemorrhagia)

Bleeding - the constant feature of the wound because of the damage of the tissue starts from skin and mucous tissues and it is accompanied by the disturbance of the integrity of vessels. The intensity of the bleeding can be different - from capillary to arterial bleeding.

It is determined by:

1. The presence of damage of big (or middle) vessels: arterial or vein ones. Localization of the wound. The most intensive bleeding is in injuring of the face, head, neck, manus -the tissue of these parts of the body has more blood than others.
2. The character of the weapon.
3. The condition of local and common hemodynamics. When the arterial pressure is decreasing or squeezing of the magistral vessel the intensity of the bleeding decreases.
4. The condition of the coagulation system.

III. Cleft (Hiatus)

The hiatus of the wound is caused by the contraction of the elastic fibers of the skin. Expressivities divergent of the skin's borders of a wound first of all is determined by correlation of its axis to the Langergan's lines. These lines show the main direction of the rough skin structures situation. For example, for decreasing of the hiatus during the operation of the extremities the surgeons choose the longitudinal directions of the incisions. The special means of direction of the incision is in cosmetic and plastic surgery during closed skin defects. For big hiatus of the wound (incisions of the festering) the incision is made perpendicularly to the Langergan's line.

CLASSIFICATION OF THE WOUND

1. Classification according to the origin

All the wounds are divided into two groups: operative and accidental.

Operative wounds are caused deliberately, with treatment or diagnostic aim, in special aseptical conditions, with minimal damage of the tissues, during the anesthesia, with thorough hemostasis and by joining with stitches of the incisive anatomical structures. In such condition the pain is not present in case of the operative wounds, the possibility of the bleeding is minimal, and the hiatus of

the wound is removed at the end of the operation by applying stitches, it means that the main wound features are removed artificially.

The operative wounds heal by the primary tension.

All other kinds of wounds are accidental. The common thing of the wounds is that they are caused contrary to the will.

2. Classification according to character of tissue injure :

1. cut or incised wound (vulnus incisum);
2. stab or pierced wound (vulnus punctum);
3. contused wound (vulnus contusum);
4. lacerated wound (vulnus laceratum);
5. crushed wound (vulnus conqvassatum);
6. sabre or slash wound (vulnus caesum);
7. bite wound (vulnus morsum);
8. mixed wound (vulnus mixtum);
9. gunshot wound (vulnus sclopetarium).

1. Cut wound (Vulnus incisum)

A sharp object causes these wounds. During the influence of the tissues the effort is concentrated on the concrete area, and this area has the high pressure, and this influence divides the tissue in the direction of sharp objects action. The surrounding tissues damage is not substantial. But the sharp object goes down to the internal organs and tissues. These wounds lead to a faint pain syndrome, big bleeding, and the hiatus depends on the correlation of the axis to the Langergon's lines. Cut wound is dangerous with the vessels damage; nervous damage if this trauma does not have such complications the wound is going to heal by primary tension.

2. Stab wound (Vulnus punctum)

Stab wound is caused by narrow and pointed object. The anatomical peculiarities are large depth and small area of the injured skin and mucous tissue.

The pain syndrome is slight, hiatus is absent, the external bleeding is absent, but hematoma can develop. Its special feature is damage of the inner vessels, nerves and organs. That's why this kind of wound has the difficult diagnostics. During the stab wound the injure can be simple or with serious complications of the liver, stomach and others - this condition can lead to death. This wound can lead to spreading of infection.

3. Contused wound (Vulnus consutum)

A blunt object causes these wounds. Before the damaging of skin, the blunt object has to injure the soft deep tissues or organs (muscles, bones). Around the wound appears the wide zone of damage saturated with blood and destroying life activity (necrosis). Contused wound causes pain syndrome (big and injured zone), but the external bleeding is small (vessel's wall is damaged spreading a large area being thrombosed fast), but there can be hemorrhages. According to these complications contused wound heals by secondary tension.

4. Lacerated wound

A blunt object causes these wounds but this object is directed under the acute angle to the skin. We can observe a big separation and sometimes to scalp of the skin. According to this separation skin can necrotize. Sometimes this kind of wounds can be caused by fractured parts of bones.

5. Crushed wound

The mechanism of this damage is equal to the vulnus consutum and vulnus laceratum, but the degree of injury is maximal. These wounds seldom can lead to the incision of the skin, because the injured zone is very large. Crushed wound heals worse, and there can be infections.

6. Slash wound

Slash wound caused by big and sharp object, that's why these wounds take the medium place between cut (incised) wound and contused wound. During this kind of wound the internal organs and bones are damaged very often. Such a wound may lead to spreading necrosis. Pain syndrome is very strong. Bleeding not severe, but massive diapedesis hemorrhages are present.

7. Bite wound

The special features of this wound are bite by animals or man. Bite wound is more infected than other wounds. This wound may be complicated by acute infection, but the zone of damage is small. Some toxins may intoxicate the saliva (snake bite). Besides that, the bite wound may be contamination by tetanus.

8. Mixed wound

These wounds may connect two and more kinds of wounds.

9. Gunshot wound

a) This wound has three zones of damaging.

For all kinds of wounds is characteristic the presence of 2 zones of damage: wound canal and traumatic necrosis. The observation of gunshot wounds determined that they differ by a long period of healing. The main difference of gunshot wound is high speed of object (bullet, splinter). Common knowledge is that the energy of free moving object is equal $mV^2/2$. According to this the damage of the tissues is very strong. A sharp bullet more easily goes through the tissues but if the bullet loses stability, it starts to "rummage". In such case the bullet returns its energy to the tissues. During the penetration of the bullet into the tissues the area of increased pressure is formed which has the compressed tissues. This compression expands from the bullet. This is the phenomenon of "side stroke". According to this a temporary cavity is formed. This cavity may be pulsatile and the tissues with great speed contact relax, mutually displace. The pressure in the inner part of the cavity is 1000 atm, and the load on the wall of a vessel is 120 kg/sm^2 . Such mechanism causes 3 zones of damage.

The zones of damage:

1. wound canal. In some cases there can be a bullet, or parts of necrotic tissue, blood and bacterias.

2. direct traumatic necrosis. Appears during the influence of kinetic energy. It consists of viable or unviable tissues, which are saturated with blood.
3. the zone of molecular contusion. It consists of tissues, which have malfunction of metabolism and of cellular structures. During the uncomfortable conditions, for example, the decreasing of perfusion, oxygenation, developing of the infection, the tissues devitalize (die). This zone is called "a stockpile of the following necrosis". This zone causes problems with treatment.

b) Complex anatomical character of damage

High kinetic energy causes not only presence of three zones, but also their complex anatomical character. What does it mean?

During the damage very often injure of some cavities of the organism is observed. Sometimes we can meet splinter fractures of the bones, and during injure of inner organs we can observe their rupture. Not always the wound canal is the direct line from the entrance to the exit aperture. It may look as indmeet line and may cause the damage of different organs.

c) High level of infection

Gunshot wound is very often complicated by the development of infection. High level of infection with the necrotic mass increases the risk of suppuration. And according to big damage of the muscle and small diameter of the entrance aperture, the access for the oxygen is very difficult, and this is the big evidence for the development of anaerobic infection.

d) Additional classification.

According to the character of wound canal:

1. A thorough damage - it has entrance and exit apertures (a bullet is out of the organism).
2. Blind injury - in has only entrance aperture (bullet is at the end of wound canal).
3. Tangential - the damage of superficial tissues, without the penetration to the cavities of the organism.

According to the factor of damage:

1. Small speed damage gunshot. The speed of the bullet is 600 m/s. The wound canal more often may be direct and blind. Such wound has, as a rule, a small entrance aperture and not big tissue damage.
2. High-speed damage. The speed of the bullet is 900 m/s and more. These wounds have small entrance aperture and wide, with defect of tissues, exit aperture. Wound canal winding, that's why we may observe the injury of many organs and tissues. More destroying effect may be caused by explosive shells.
3. Shot wounds. These wounds have many separate apertures, bleeding, the contusion of organs and tissues.

According to the zone of damage:

1. Wounds with a small zone of damage. These wounds have a small border of the incision and the necrotic zone is very small. The wounds with small zone have no complications, small hiatus.
2. The wounds with a large zone of damage. These wounds have insignificant hemorrhage, strong pain, long healing, and many complications.

Classification according to the level of infection

1. Aseptic.
2. Fresh infected.
3. Suppurative.

1. Aseptic wounds

This wound is caused in the operative room with norms of aseptic. Such wound heals soon, and they do not have any complications.

But the operative wounds may be different: for example the operation of the vessels - infection is minimal and appendicitis a high level of infection.

According to the level of microbial contamination all operation are divided into four kinds:

- Aseptic operation (planned primary operation without the opening of cavity of inner organs).
- Conditionally aseptic - there may be infection in some cases.
- Operation with big danger of infection - conditionally infected.
- Very high level of infection - infective operations (purulent processes).

2. Fresh-infected wounds

This is the wound, which was made outside of the operation or during 3 days from the moment of damage. The level of infection in this wound is different and it depends on the kind of an object, conditions of damage. Fresh-infected wound have quantity of microorganisms not more than 10^5 per 1g of tissue.

3. Suppurative wounds

They are infected too. But they differ from fresh infected with the presence of infective process. This infection causes inflammatory reaction, necrosis, formation the suppuration, and general intoxication.

4. Classification according to the serious:

There are simplex and complex wounds. Simplex wound is the damage of skin, skin and muscle.

Complex wound is the damage if inner organs, bones, magisterial vessels and ne trunks. For the diagnostics of the inner organs there are special symptoms. During damage of arterial vessels of the extremities -there absence of pulse, paleness, incr ing of the temperature in the region of bleeding. During Venous stagnation - there extremities become cold and swollen, cyanosis. During the cut of nerve trunks -1 loss of sensitivity and moving function of the extremities.

5. Classification in dependence of the relation of the wounded defect to cavities of the body:

There are penetrated and not penetrated wounds. Penetrated wounds -they ma connection between the cavity of the organism and environment. For this there sh be a damage of one of these membranes: hard membrane of the brain, parietal ph parietal peritoneum, and capsule of the joint.

Penetrated wounds are the most serious and dangerous. During the damage of rax there may be pneumothorax, hemothorax.

During the damage of the abdominal cavity it is necessary to exclude the injui parenchymatous organs, intra-abdominal bleeding. It is important to notice that du the penetrative injury there may be infection of the supplicative meningitis, empyen the chest, peritonitis, and supplicative arthritis. If the wound is not penetrative infection is not possible.

It is important to know what organs are injured in penetrative wound. That's such a patient has the operation: opening the cavity and making the revision of al gans and remove the injury.

6. Classification according to the region of saturation:

There are wounds of neck, head and trunks, upper and lower extremities and sometimes wounds connect two parts of the body, they are called complex worry.

According to the number of injuries they determine single and plural (S.V.P.)

7. Combinative damages

Besides the mechanical and other injures there can be combinative damages

CHARACTERISTICS OF WOUND PROCESS

Wound process - this is the complex of successive changes, which take plac wound, and connective reactions of all organism.

Conditionally, we may divide this into general reactions of the organism and ing of the wound.

1. General reaction

The complex of the biological reaction of the organism during the influen damage we may observe like 2 successive stages.

1). During 1 -4 days from the moment of trauma there is observed the excitation of sympathetic nervous system, the elimination of the hormones of adrenal glands - insulin, ACTE, and glucocorticoids, into the blood. According to this the process of life activity becomes stronger: increase the main change process; decrease the mass of the body; increase the destruction of the proteins, lipids, and glycogen, decrease the penetration of cellular membrane.

In the cavity of a wound there is some quantity of microorganisms and destroy tissues, which dissolve and phagocytes. According to this, all process, which is present in the surrounding tissue of the wound, causes the general reaction in the whole organism. As a result, in the first period there is observed the increase of the body temperature, weakness, decrease the workability.

The analyses of blood notes the increase of the leucocytes quantity, sometimes - a small shift of leukocyte formula to the left. In analysis of urine may be proteins. During the general bleeding there is observed the decrease of hematocrit, quantity of erythrocytes, hemoglobin.

2). Starting from 4-5 days, the character of general reactions depends on parasympathetic nervous system. The main important components are mineral-corticoids, so-matotrophic hormone, aldosterone, and acetylcholine.

They observe the increase of the body mass, the normalization of proteins, the mobilizing of reparative abilities of the organism. In 4-5 days when the complications are absent; the intoxication, inflammation, pain are decreased. The analysis of blood and urine becomes normal.

2. Healing of the wound

The reparation of the wound - the reparative process of damage tissue with resumption it's integrity and firmness.

For closing of the tissue defect there can be 3 main processes.

The formation of the collagen by fibroblasts. During the reparation of the wounds fibroblasts activates by macrophages. They proliferate and migrate to the place of injury, and connect with fibril structures through the fibronectin. In one time fibro plates synthesize the substance of extra cellular matrix. Collagens provide the liquidation of tissue defect and firmness of the stitch formation.

Epithelization of the wounds becomes under the influence of migration of the epithelial cells from the border of wound to its surface. The end epithelization of wound defect causes the barrier for microorganisms. But the migration from the border cannot close the defect, which does necessary in some cases to carry out a dermal plasty.

The decrease of the wound surface provides **effect of tissue tension** (the contraction of miofibroblasts).

Phases of wounds reparation

Rufanov differ 2 phases: hydration and dehydration.

Girgolav determined 3 period of wounds reparation:

1. preparing period.
2. the period of regeneration.
3. the period of stitch formation.

In present time the most popular classification is (Cusin, 1977 year):

1. The phase of inflammation (1-5 day). It has period of vessel's changes and period o purifying of the wound from necrosis.
2. The phase of regeneration (6-14 day).
3. The phase of formation and stitch reorganization (begin from 15-th day).

1) Inflammation phase

Period of vessel's changes

Trauma cause such destroys, which connects with microcirculatory vessels. Besides the rupture of vessels there may be short time contraction and after that the dilatation of micro-vessels. Biogenic amines, the system of complement cause the vasodilatation and increasing of penetration of vessels. According to this the blood stream becomes slower which makes the blood curdling harder and as a result the cellular and venous thrombosis takes place.

The increasing of perfusion provides to decreasing of oxygenation of tissues in region of wound. Acidosis, destroys the protein's change and develops. During the destruction of cell proteins with destruction of cell free ions of K^+ and H^+ , which increases the osmotic pressure in tissues, makes the setback of the water, hydration of the tissue:

Prostaglandines cause vasodilatation, pyrogenic reaction and pain syndrome. Such changes of microcirculation provide to appearance of extra-vessel changes: exudation of the plasma and lymph, excretion and migration of leucocytes in wound's region.

According to this develops the edema and leucocytes infiltration of tissues, prepares the condition for clean of the wound.

The period of the wound clean from necrotic tissues

The most important components in the period are blood elements and enzymes. First days appears leucocytes surround the wound. 2-3 days appears lymphocytes and macrophages.

Neutrophilic leucocytes make phagocytation of the microorganism's necrotic mass and make the extra cellular proteolysis, and excrete the mediators of inflammation.

The main functions of macrophages - are excreting proteolytic ferments at phagocytosis of destructive by leucocytes necrotic tissues, take part in immune reactions.

2) Phase of regeneration

Two main processes take place in a wound: wound's collagenisation, intensive growth of the blood and lymphatic vessels. In wound decrease the number of neutrophils, and increase the number of fibroblasts (cells of connective tissue which can synthesize the macromolecules of intracellular matrix). The main role of fibroblasts is synthesis of the components of connective tissues and formation of the collagens and elastic fibers. In this time the recanalisation and growth of blood and lymphatic vessels wound region starts. The proliferation of capillaries becomes. Inflammatory process becomes less.

3) Phase of formation and reorganization of the stitch (15day - 6 month).

In this phase the synthetic activity of fibroblasts and other cells stops, and the *mz* process led to strengthening of the stitch by the way of formation of the net by the help of elastic fibers, and appearance transferal between different bundles of collagen. Skin wounds recovered

only 70-90% of the primary skin. The tissues with difficult structure have less possibility to regenerate. There can be stitch, but it cannot do the same function.

The factors, which have influence on healing of the wound:

- age of the patient;
- the condition of nutrition and body mass;
- the presence of secondary infection of the wound;
- the condition of blood circulation in zone of damage and organism in general;
- the presence of destroys of water-electrolytic balance;
- the immune status of the organism;
- chronic bypasses diseases;
- using anti-inflammatory medications.

The best reparative process has the child organism, it caused by presence in period of development anabolic processes. In such condition the reparation is shorter and is not so dangerous.

Classical types of reparation:

- reparation by primary tension;
- reparation by secondary tension;
- reparation under the crust.

1. Reparation by primary tension

"Sanatio per primam intentionem" is the most profitable heal of the wound. In such case stitch is thin and strong. Operation wounds have primary tension when the borders of wound connected. The quality of necrotic mass is small and small inflammation.

After the inflammation and clean from death cells in phase of regeneration between the walls of wound canal form the connection by connective tissue and by collagen and vessels. In this time becomes the growth of epithelial tissue from the borders of wound, and this is the barrier for microbial penetration.

Wounds, which have small diameter (1 cm), can reparate by "primary fibrinous commissure".

Primary tension has only uninfected wounds, or wounds with small infection.

According to this there is some aspects for primary tension:

- no infection in wound;
- connection the borders of wound;
- absence of the hematoma and other objects in wound;
- absence of the necrotic mass;
- good condition of the patient.

2. "Sanatio per secundam intentionem" - heals by suppuration by the help of granulate tissue. In this type of heals we can observe inflammation.

a. Conditions to heal by secondary tension:

- big quantity of microbes in wound;
- big defect of the skin;
- the presence of some objects or hematoma;
- the presence of necrotic mass;
- unfavourable condition of the patient.

b. The specialties of the inflammatory phase

The inflammation is stronger. Phagocytosis and lysis of devitalized cells cause high concentration of toxins in surrounding tissue. This process causes bad microcirculation and increases the inflammation. This wound is characterized by invasion of microbes to surrounding tissues. On the border of this penetration is formed leukocytic accumulation.

After the cleaning of the wound starts second phase - this is phase of regeneration.

c. Structure and functions of the granulative tissue.

Granulative tissue - this is the special kind of connective tissue, which forms only during healing of the wound by second intention. In normal, granulative tissue does not develop without damage.

The formation of the granulative tissue.

During the regeneration by primary tension in second phase, wound process fills by granulative tissue.

The main component of the reparative process is the growth of the vessels. They go from deep to the surface and after that, make the land and go down to the fundus of the wound in this region blood elements form, form fibroblasts, which give the growth of the connective tissue.

The islands of the granulative tissue appear in not clean wound (during the necrosis 2-3 day). The granulative tissue may form not only by the help of infection but also in clean wounds. It may happen in such case, when diastasis can be more than 1 cm., and when the capillaries do not go to the other side of the wound.

Components of the granulative tissue

The main components are 6 layers:

- Superficial leukocytic-necrotic layer. It consists of leucocytes, detritus and skinned cells. This layer is the whole period of reparation.
- Layer of the band vessels. Besides the vessels it consists of polyblasts. In this layer collagenic fibers may be formed.
- Layer of the vertical vessels. It is constructed from perivascular elements.
- Developing layer. This is the deepest part of the previous layer; this layer is characterized by polymorphism of the cells formation.
- Layer of the horizontal fibroblasts. It consists of monomorphic cellular elements, collagen

fibers.

- Fibrous layer. It shows the process of granulative growing.

The means of granulative tissue:

1. Change the wound defect: the main plastic component.
2. This is the protection of the wound from microorganisms and some objects.
3. Sequestration and excretion of the necrotic mass.

During the normal process there develops not only granulative tissue but also starts the epithelization step by step, the granulative tissue transforms into rough connective tissue - scar forms.

Pathological granulation

During the influence of the "bad" factors, the process of granulation destroys. The granulation becomes pathological. Clinical symptoms are absence of the wound connection and appear the change of granulative tissue, which we observe. The wound becomes dim, acyanotic, sometimes cyanotic. It loses a turgor, becomes covered by a fur of a fibrin and pus.

The pathological granulation may be with formation of tubercles - hypertrophied granulations. They stop the granulation (S.V.Petrov).

Reparation under the crust

This reparation takes part during the small damage of the skin.

This process starts from the blood clotting, lymph clotting. Crust is the "biological bandage". Under the crust starts regeneration of the tissue (3-7 days). It's not necessary to cut crust if there is not inflammation.

But if under the crust there is necrotic mass, the operation is necessary.

"Crust is medial stage between primary and secondary tension".

TREATMENT OF WOUNDS

Despite many specific peculiarities of different wounds, main stages of their healing are mostly the same. There are also common tasks, that surgeon face while treating any wound.

1. Dealing with early complications.
2. Prophylaxis and treatment of infection in the wound.
3. Reaching the healing in the closest time.
4. Full stabilization of function of damaged organs and tissues.

Dealing with these tasks should be started at the very beginning of providing the first aid.

First Aid

While giving the first aid one should :

- exclude early complications of the wound that are dangerous to life of the patient,
- prevent the following infection of the wound.

(1) Fighting against complications threatening the life

The hardest early complications of the wound are:

bleeding,

development of traumatic shock,

injuring of life important organs.

Intensity of the hemorrhage depends on type of damaged vessel and its size. Massive blood loss is caused by injuring of magistral arteries and veins, which may lead to development of hemorrhagic shock with disorder of whole hemodynamics, incompatible to life. That's why in massive hemorrhage first task is to stop the bleeding using a tourniquet (if arteria is injured), or pressing of veins distally to injury on time of treating of the wound with later applying of a pressing bandage, or other temporary methods of stopping of the hemorrhage.

If there's a danger of development of traumatic shock during pre-hospital stage injection of strong analgesics is provided (including the narcotic ones) and contra-shock medications.

In case of penetrative injuring of thoracic cavity and development of hemothorax applying of hermetic (occlusive) bandage with using of special sterile gum fabric is necessary. In such way pleural cavity is hermetic and pneumothorax will not develop during the transportation.

In case of a big penetrative wound of anterior abdominal wall damage of internal organs may occur. To prevent the following falling out and infecting wide aseptic bandage should be applied.

(2) Prophylaxis of furthur infecting

Independently on character and localization all accidental wounds are contaminated with bacteria. But besides the primary infecting of the wound, further bacterial penetration from the patient's skin, air, different objects is possible. That's why for avoidance of additional invasion of

bacteria into the wound during providing of the first aid dirt from the surrounding skin covers cotton or cloth tampon, moistened with alcohol, ether or other solution that has antiseptic and clearing action, eliminates.

Then the margins of the wound should be smeared with 5% infusion of iodine (or alcohol, brilliant green etc.) and apply an antiseptic bandage, and a pressing one if needed.

One should not clean the wound and exclude foreign bodies from it.

Besides treatment of the wound in massive traumas of soft tissues of the limbs and also in fractures of the bones to avoid the development of injury transport immobilization should be provided.

Further measures of treatment of the wound are first of all determined by its kind according to stage of infecting. That's why there is a differentiation of treatment of operative (aseptic), fresh infected and purulent wounds.

Treatment of an operative wound

Treatment of an operative wound on the operation table starts, when the surgeon tries to provide the best condition for its healing.

(1) Providing conditions for healing by primary covering during the operation
Operative wounds are conditionally aseptic, cut. When these wounds occur, all the

conditions for healing by primary tension are provided: prophylaxis of infection, safe hemostasis, foreign bodies and necrotic tissues are absent in the wound. At the end of operation the margins of the wound are put close together by stitches. If the probability of accumulating of exudates occurs the drainage is left there. Applying of an aseptic bandage finishes the operation.

After applying of the stitches on a deep wound of the limb with damaging of muscles, tendons, vessels and neural trunks the immobilization with plaster languet is useful. This technique provides functional rest, acceleration of healing and decreasing of pain during the postoperative period.

The important moment is providing of antibiotics prophylaxis, the main principle of which is injection of antibiotic before an operation (or on the operation table) and during 6-48 hours after it. The most frequently used are cephalosporines of 2nd and 3rd generation. The scheme of introduction of antibiotics is presented on the scheme:

1. Clean operations - antibiotic prophylaxis is not indicated.
2. Clean operations with possible infecting - introduction of an antibiotic during the operation and during 8-24 hours after it (1-2 introductions).
3. Operations with high risk of infecting - introduction of an antibiotic during the operation and during 24-48 hours after it.
4. Operations with a very high risk of infecting - introduction of an antibiotic during the operation and during 3-5 days (treatment of main pathological process. The main conditions for

healing of the wound by primary covering are provided during the operation.

(2) Treatment of the wound in postoperative period

After the operation it is important to solve following four tasks:

anesthesia;

- prophylaxis of secondary infection;
- acceleration of healing processes in the wound,
- correction of general condition of the patient.

a) Anesthesia

Anesthesia in postoperative period can be provided by different methods depending on traumaticity of invasion and expression of the pain syndrome.

b) Prophylaxis of secondary infection

After the operation aseptic bandage is applied on the wound. It is has changed to be changed in 24 hours after the operation, and than according to needs.

For prophylaxis of infection complications it is important to look after the condition and functioning of drainages, they have to be removed in time (not functioning drainage may be a source of infection).

c) Acceleration of healing processes

For prophylaxis of hematome during the first 24 hours after the operation the ice bag is applied to the wound. Starting from the third day the heat procedures, physiotherapy is used (quartz).

For improving of blood circulation and metabolic processes early activation of the patient is necessary.

d) Correction of general condition

During postoperative period it is necessary to carefully watch after general condition of the patient to find out and correct any factors, harmful for healing in time (anemia, hypopro-teinemia, blood circulation insufficiency, discharge of water-electrolyte balance etc.).

(3) Healing of wounds and removing of stitches

Using of these methods of prophylaxis of complications and treatment of operative wounds in majority of cases provides their healing by primary covering. The end of this process is formation of postoperative scar.

Terms of healing of the wounds depending on their localization:

Face, head	3-4
Anterior surface of the neck	4-5
Posterior surface of the neck	6-7
Lateral surface of chest and abdomen	7-8
Wounds of the abdomen on medial line	10-11

Back	10-11
Shoulder	5-6
Forearm	6-7
Hand	5-6
Thigh	5-7
Shin	7-8
Foot	10-12 days

Formally a wound becomes a scar after removing of stitches. Terms of removing of stitches (therefore terms of healing of the wound) are determines by localization of the wound and condition of the patient.

Different terms of healing of wounds of different localization (see in table) are first of all explained by peculiarities of blood supply. On the face, anterior surface of the neck the blood supply is very good, wounds heal quickly. On the legs, especially on the feet, blood supply is worse and wounds heal longer.

Presence in general condition of factors, harmful for healing (old age, anemia, accompanying illnesses etc.), prolongs terms of healing.

Treatment of Fresh Infected Wounds

Taking into consideration all the accidental wounds are primarily infected, tactics of treatment depend on character and localization of the wound, on volume and remoteness of an injury. Fresh superficial wounds, scratches need only treatment by antiseptics and an aseptic bandage.

Such wounds heal by themselves without applying of stitches by primary covering or under a scab. Nevertheless even having such wounds one should not forget about possibility of penetration of causative agents of tetanus (usually if the wound or instrument have touched soil) and rabies (in animal bites). In such cases anti-tetanus serum and anti-rabies vaccine are injected.

In majority of fresh infected wounds surgeon faces a task of preventing of development of infection (suppuration) and providing conditions for its quick healing. According to this the main measure in treatment of fresh infected wounds is primary surgical treatment (PST) of a wound.

(1) Primary surgical treatment of a wound

a) Determination and stages

PRIMARY SURGICAL TREATMENT OF A WOUND

- is the first surgical operation, provided in aseptic conditions, with anesthesia, which contains the following stages:

- Cutting of the wound.

- Revision of the wound channel.
- Removing of the margins, walls and bottom of the wound.
- Hemostasis.
- Rehabilitation of injured organs and structures.
- Applying of stitches on the wound with leaving of drainages (according to indications).

Therefore thanks to primary surgical treatment of a wound accidental infected wound becomes cut and aseptic, which provides possibility of its quick healing by primary covering.

Cutting of the wound is necessary for total under eye control *revision* of zone of spreading of wound channel and character of injury.

Removing of margins, walls and bottom of the wound is held for removing of necrotic tissues, foreign bodies and also all wound surfaces, which was infected while injured. After providing of this stage the wound becomes cut and sterile. The following manipulations should be provided only after changing of instruments and gloves.

It is usually recommended to cut the margins, walls and bottom of the wound out by one block on around 0.5-2.0 cm. Also the localization of the wound, its depth and kind of damaged tissues should also be taken into consideration. In dirty and squashed wounds, wounds of lower extremities the cutting out should be wide enough. In wounds on the face only necrotic tissues are removed and in cut wound the cutting out of the margins is not provided at all. Livable walls and bottom of the wound are prohibited to cut out if they are presented by tissues of internal organs (brain, heart, intestine etc.).

After cutting out an accurate *hemostasis* is provided for prophylaxis of hematome and possible infection complications.

Recovery stage (stitching of nerves, tendons, vessels, connecting of bones etc.) should be provided during the PST, if qualification of a surgeon lets to do so. If no - it is possible to provide a repeated operation with a delayed stitching of a tendon or a nerve, provide a delayed osteosynthesis. Recovery measures in the whole volume should not be provided during the PST in wartime.

Sewing of the wound is the finishing stage of PST. There are such possible variants of finishing of this operation.

1. Layer-by-layer sewing of the wound.

It is provided in small wounds with a little zone of injury (cut, stab-wounds etc.), not much dirt, if the wound is localized on the face, neck, trunk and superior extremities and if not much time passed since the moment of injuring.

2. Sewing of the wound with leaving of drainage (drainages).

It is provided in case of risk of development of infection, but if it's small or the wound is localized on a foot or shin, or zone of damage is big, or PST is provided in 6-12 hours since the

moment of injury, or patient has an accompanying pathology, that is harmful for healing process etc.

3. The wound is not sewed

If there is a high risk of infection complications:

- late PST,
- massive dirtying of the wound with soil,
- massive damaging of tissues
- accompanying illnesses (anemia, immune deficiency, diabetes mellitus), «localization on a foot or shin,
- middle age of the patient.

Gunshot wounds and also any wounds if the aid is provided in wartime should not be sewed. Sewing of the wound closely with presence of harmful factors is a totally unwarranted risk and a clear tactic mistake of a surgeon!

b) Main kinds

The earlier since the moment of injury PST of the wound is provided; the lower is the risk of infection complications.

Depending on remoteness of the wound three kinds of PST are used: early, delayed and late.

Early PST is held in a term till 24 hours since the moment of wound formation, it includes the principal stages and usually finishes by applying of primary stitches. In massive damage of subcutaneous cellular tissue, impossibility of full stopping of capillary bleeding drainage is left in the wound for 24-48 hours. Later the treatment is provided like in clean postoperative wound.

Delayed PST is provided from 24 till 48 hours after injuring. In these period effects of inflammation is develop, edema and exudates appear. The difference from early PST is providing of the operation on the background of injection of antibiotics and finishing of operation leaving the wound open (not sewed) with following applying of primarily delayed stitches.

Late PST is provided after 48 hours, when the inflammation is close to the maximum and the development of infection process begins. Even after PST probability of suppuration stays high. In such situation it is necessary to leave the wound open (not to sew) and provide a course of antibiotic therapy. It is possible to applying early secondary stitches on 7* -20th day, when the wound is totally covered with granulations and obtains relative resistance to development of infection.

c) Indications

Presence of any deep accident wound during 48-72 hours from the moment of injury is the indication for providing of PST.

The following kinds of wounds are not objects of PST:

- superficial wounds, scratches, abrasions,

- little wounds with divergence of margins less than on 1 cm,
- multiple little wounds without damaging of deep tissues (like small shot injury),
- stab wounds without damaging of internal organs, vessels and nerves,
- in some cases through gunshot injuries of soft tissues.

d) Contraindications

There are only two contraindications for providing of PST of the wound:

1 . Signs of development of purulent process.

2. Critical conditions of the patient (terminal condition, shock of the III stage). (2) Kinds of stitches

Prolonged existing of the wound does not promote faster functionally advantageous healing. It is especially observed in massive injuries, when significant loss of fluid, proteins, and electrolytes takes part and there is a big risk of suppuration. Besides this filling of the wound with granulations and closing with epithelium go very slowly. That's why it's important to put the margins together as soon as possible using different kinds of stitches.

Advantages of applying of stitches:

- acceleration of healing,
- decrease of losses through the wound surface,
- decrease of probability of repeated suppuration of the wound,
- increasing of functional and cosmetic effects,
- facilitation of treatment of the wound.

There are primary and secondary stitches, a) Primary stitches

Primary stitches are applied on the wound before the beginning of development of granulations, the wound heals by primary cover.

Usually primary stitches are applied right after finishing of the operation or PST of the wound in absence of high risk of development of purulent complications. Primary stitches should not be used in late PST, PST in wartime and PST of gunshot wound.

Removing of the stitches is provided after development of rough connective tissue commissura and epithelization in certain terms.

Primarily delayed stitches are also applied on the wound before development of granulation tissue (wound heals like primary covered). They are used in case of risk of development of infection.

Technique: the wound should not be sewed after operation (PST), inflammatory process is under control and when it goes down primarily delayed stitches are applied on 1st-5th day.

A variety of primarily-delayed stitches are *tension stitches*: after the end of operation stitches are applied but threads are not knotted, in such way margins of the wound are not close. Threads are knotted on 1st-5* day when the inflammation process calms down. These stitches

neither differ from the usual ones in a neither way that there is nor need to do repeated anesthesia and sewing of the margins of the wound.

b) Secondary stitches

Secondary stitches are applied on granulative wounds, that heal by secondary cover. The sense of using of secondary stitches is to decrease or to remove a wound cavity. Decrease of volume of wound defect leads to decreasing of quantity of granulations, necessary for its healing. As a result terms of healing decrease, and content of connective tissue in healed wound is much smaller, comparatively to wounds that healed in an opened way. It is advantaging for appearance and functional peculiarities of a scar, its size, firmness and elasticity. Putting closer the margins of the wound diminishes potential entering gates for infection.

Indication for applying of secondary stitches is a granulative wound after elimination of inflammatory process, without purulent leaking and purulent content, without areas of necrotic tissues. For sureness of calmed down inflammation inoculation of the wound content can be used - if there is no growth, secondary stitches can be applied.

There are *early secondary stitches* (they are applied on 6th-21st day) and *late secondary stitches* (plying is provided after 21st day). The principal difference between them is in that till 3 weeks after operation in margins of the wound scar tissue is developed, that prevents both from touching of the margins and process of their joining. That's why while applying early secondary stitches (before scarring) it's enough simply to sew the margins of the wound and put them together knotting the needles. While applying late secondary stitches it is necessary to cut out scarred margins of the wound in aseptic conditions ("freshen up the margins"), and after that to apply stitches and tie the needles.

For accelerating of healing of granulative tissue besides applying of stitches, joining of the margins by stripes of plaster also can be used. This method doesn't as fully liquidate a wound cavity, but it can be used before absolute calming down of an inflammation. Joining of the margins of the wound by plaster is widely used for acceleration of healing of purulent wounds.

Treatment of purulent wounds

Treatment of purulent wounds consists of two directions - local and general treatment. Besides that character of treatment is determined by phase of wound process. (1) Local treatment of purulent wounds

a) Tasks of treatment in phase of inflammation

In first phase of wound process (inflammation stage) the surgeon faces the main problems:

- Fighting against microorganisms in the wound.
- Providing of adequate drainage of exudates.
- Assistance to fast clearing of the wound from necrotic tissues.

- Decrease of manifestation of inflammatory reaction.

In local treatment of a purulent wound methods of mechanical, physical, chemical, biological and mixed antiseptics are used.

In case of inflammation of postoperative wound it sometimes is enough to remove stitches and widely spread the margins. If this isn't enough, it is necessary to do secondary surgical treatment (SST) of the wound.

b) Secondary surgical treatment of the wound

The indication to SST is presence of purulent source, absence of adequate outflow from the wound (delay of puss), formation of wide zones of necrosis and purulent leaks. The contraindication is only terminally bad condition of the patient, in this case only opening and draining of purulent source is provided.

Tasks that surgeon providing SST of wound:

- opening of purulent focus;
- cutting of unlivable tissues.
- providing of adequate drainage of the wound.

Before the beginning of SST it is necessary to define the visible borders of inflammation, localization of region of purulent fusion, the shortest access to it taking into consideration situation of the wound, and also possible ways of spreading of infection (on the way of nerve-vascular bundles, muscular-fascia vaginas). In this case besides palpatory examination different kinds of instrumental diagnostics are used: ultrasound method, tomographic, x-ray (in osteomyelitis) and computer tomography.

Like primary surgical treatment, SST is an independent surgical interruption. It is provided in operating room by a brigade of surgeons with the usage of anesthesia. Only an adequate anesthesia allows solving all the tasks of SST. After the opening of the purulent seat a careful instrumental and finger revision on the way of the wound and possible leaks is provided. The leaks are later also opened through the main wound or a contraperture and than drained. Finishing the revision and determining the volume of necrosis and evacuation of pus is provided and cutting out of unlivable tissues (necrectomia). One has also to remember that closely to or in the wound itself major vessels and nerves may be situated, which should be saved. Before finishing of the operation the wound cavity is abundantly washed by antiseptics solutions (hydrogen peroxide, boric acid, etc.), tamponned by gauze napkins with antiseptics and drained. The most advantageous method of treatment in massive purulent wounds is washing-through draining. In case of localization of the injury on the limb the immobilization is necessary.

c) Treatment of a purulent wound after the operation

After performing of SST or simple opening of the wound on each redressing a doctor examines the wound and evaluates its condition, defining the dynamics of the process. The margins

are treated with alcohol and iodine containing solution. The cavity of the wound is cleaned from pus and free sequestered areas of necrosis by a gauze ball or napkin, necrotic tissues are cut out in a sharp way. Then they are washed by antiseptics, draining (according to indications) and tamponing.

In the first stage of healing, when massive exudation occurs, the ointment preparations can't be used as they form an obstacle for an outflow of detached substances, in which many bacteria are situated, products of proteolysis, necrotic tissues. In this period the bandage has to be maximally hygroscopic and contain antiseptics. They can be: 3% solution of boric acid, 10% solution of sodium chloride, 1% solution of dioxydine, 0.02% solution of chlorhexidine etc. Usage of water-soluble ointments: "Levomekolum", "Levosynum", "Levonorsynum", "Sulfamekolum" and 5% dioxudine ointment is available only on 2nd - 3rd day.

"Chemical necrectomia" with the help of proteolytic ferments that make a necrolytic and anti-inflammatory action have a certain meaning in treatment of purulent wounds. Tripsine, chymotrypsine, chymopsyn are used for this. Preparations are poured into the wound in dry condition or injected in solution of antiseptics. For active removing of purulent exudates sorbents are placed into the wound, the most widely spread of which is poliphepan.

To increase the effectiveness of SST and further treatment of purulent wounds in nowadays conditions different physical methods of influence are used. Ultrasound cavi-tation of wounds, vacuum treatment of purulent cavity, treatment by pulsing stream, different methods of using of laser are widely used. All these methods stimulate the cleaning from necrotic tissues and have a damaging effect on microbial cells.

d) Treatment in the phase of regeneration

In the phase of regeneration, when the wound is cleared from unlivable tissues and inflammation quiet down, a second stage of treatment takes place, the main tasks of which are suppression of infection and stimulation of reparative processes.

In the second phase of healing process of formation of granulative tissue plays the leading role. Despite it has a protective function; the repeated inflammation cannot be totally excluded. In this period in case of absence of complications, exudation decreases and necessity in hygroscopic bandage, using of hypertonic solutions and draining disappears. Granulations are very tender and vulnerable, that's why it is necessary to use preparation on ointment basis, which prevent mechanical traumatization. Antibiotics (syntomycine, tetracycline, hentamycine ointments etc.), stimulating substances (5% and 10% methyluracyl acid, "Solcoseryl", "Actovegyn") are introduced into the content of ointments, emulsions and liniments.

Multicomponent ointments are widely used. They contain anti-inflammatory, regeneration stimulative substances and substances wich improve the regional blood circulation, antibiotics. These are: "Levometoxyd", "Oxyzon", "Oxycyclozol", balsamic liniment after A.V. Vishnevsky.

For accelerating of healing methods of applying of secondary stitches (early and late) and also putting together of margins of the wound by plaster are used.

e) Treatment of the wounds in phase of formation and reorganization of a scar.

In the third phase of healing the main task is to accelerate the epithelization of the wound and to protect it from additional traumatization. Bandages with indifferent and stimulating ointments, physiotherapeutic procedures are used for this reason.

f) Physiotherapeutic treatment

Physiotherapeutic procedures play an important role in curing of purulent wounds.

In the first phase to decrease the acute manifestations of inflammation, to decrease edema, pain syndrome, to accelerate seizure of necrotic tissues it is used electric field of UHF (ultra-high frequencies) and ultraviolet radiation in erythematic dose, which also stimulates phagocytic activity of leucocytes and possesses an antimicrobial action. For local introduction of antibiotics, anti-inflammatory and analgesic preparations electro- and phonophoresis are used. In incomplete outflow of purulent content physiotherapeutic procedures lead to worsening of purulent-inflammatory process.

In the second and third stages of wound process UV-radiation and laser radiation by defocused ray are used for activation of reparative processes and epithelization. Magnetic field also possesses a vasodilative and stimulative activity. In the influence of pulsing magnetic field the growth of nervous fiber is activated, synaptogenesis is increased; the size of a scar is decreasing.

During the whole period of wound process hyperbaric oxygenation is used, which improves the oxygen supply of the tissues.

g) Treatment in abacterial environment

In massive wound defects and burns treatment in controlled bacterial medium is successfully used. There are isolators of common and local types. Isolation of the whole patient is necessary in treatment of patients with decreased tolerance to infection: after oncology operations, supported by massive chemical therapy or radiation treatment, in transplantation of the organs, combined with constant taking of immune depressants, that decrease the reaction of tearing away, and also in different diseases of blood, which cause the disorder and depressing of lymph— and leucopoiesis.

Treatment in abacterial environment is provided without applying of a bandage, which promote drying of the wound, which is damaging to microorganisms. The following parameters are maintained constant: temperature - 26-32°C, pressure - 5-15 mm Hg, relative humidity - 50-65%. They can be changed depending on character of proceeding of wound process (S.V.Petrov).

(2) General treatment

General treatment of wound infection has several directions:

- Antibacterial therapy.
- Desintoxication.

- Immune correcting therapy.
- Anti-inflammation therapy.
- Symptomatic treatment.

a) Antibacterial therapy

Antibacterial therapy is one of the components of complex therapy of purulent illnesses and purulent wounds in particular. It is mainly used at first and second stages of the wound process.

In case of absence of signs of intoxication, not large sizes of the wound, maintaining of integrity of bone structures, magisterial vessels and absence of accompanying illnesses it is usually enough to use only principles of local treatment. In other case antibacterial therapy has to be started as soon as possible.

One of the main principles of the therapy is using of a preparation to which micro flora of the wound is sensitive. But it sometimes takes more than 24 hours from the moment of taking of the material till receiving of the results of the tests. So, it is better to inject the antibiotic to which a supposed infection is usually most sensitive. In this case the definition of peculiarities of the pus, characterizing a particular microorganism may be useful.

Staphylococci usually form dense yellow pus, streptococci - liquid yellow-green or plasma-like pus, escherichia colli - brown pus with a specific smell. A rod of blue-green pus gives a corresponding color with a sweet smell. Proteus also possesses similar features but it doesn't have a green color. It is important to remember that there is usually a mixed kind of infection in a purulent wound, that's why it's better to prescribe antibacterial preparations with wide spectrum of the action at the primary stages of the treatment. After definition of sensitivity the change of an antibiotic or its dosage may be made.

A part of antibacterial therapy is also preparations, strictly directed to particular bacteria or their groups. Different bacteriophages are also used - streptococcal, staphy-lococcal, proteus, colli-phage and also complexed phages, like piophage, which contains several kinds of bacteriophages. For passive immunization antistaphylococci r-globulin, different kinds of plasma - hyperimmune antistaphylococci, antieschericia, antipolisaccharide (against gram-negative microorganisms) is introduced. Active immunization with anatoxins and vaccines is used with the prophylaxis aim to prepare the patient to struggle with infection by his own strength. As usual Staphylococci anatoxin, polyvalent vaccine and others are used.

b) Desintoxication

A big volume of necrosis and developing infection caused filling of the organism with toxins. In a patient with a purulent wound in first phase all the signs of intoxication are observed (chills, fever, sweating, weakness, headache, loss of appetite), inflammation changes grow in analyses of blood and urine. All these are the indications to providing of deintoxicating therapy,

which contains several methods, presented below in turn of growth of their difficulty and effectiveness:

- Infusion of salt solutions
- Method of forced diuresis
- Using of desintoxicative solutions
 - Extracorporal methods of detoxication.

The choice of the method of desintoxication depends first of all on expressiveness of intoxication and on difficulty of patient's condition.

In regeneration phase and phase of scar formation there is usually no need in providing of desintoxication therapy.

c) Immune correcting therapy

In case of appearing of purulent process in the wound and development of intoxication, we often observe the decrease of resistance of the organism, level of production of antibodies, phagocytic activity, deficiency of subpopulations of lymphoid tissues and slowing down of their differentiation. This is also caused by long-lasting usage of antibacterial preparation.

These changes lead to next development of infection, enlarging of a zone of secondary necrosis and progressing worsening of condition of the patient. To correct this temporary deficiency the immune-modulators are used.

Interferon, levamisol, preparations of thymus (thymalin, thymosyn, T-activin) are most widely used. Nevertheless in prolonged introduction and big dosage these preparations decrease the production of own immune cells. Lately, much attention is paid to method of gene engineering of cytokines, interleukines in particular, which have wide indications for using in immune deficiencies. Human recombinant interleukine-1 ("Betaleukine"), interleukine-2 ("Ronkoleukine") has been created and are used nowadays.

d) Anti-inflammation therapy

Anti-inflammation therapy is not a leading method of treatment of the wounds, is used rather rarely and contains introduction of preparation of salicylatis group, steroid and nonsteroid anti-inflammation remedies. Due to this signs of inflammation, edema cool down, perfusion and oxygenation of surrounding tissues increase, metabolism improves. This leads to speeding-up of formation of demarcation line and fast cleaning of the wound from necrosis.

e) Symptomatic treatment

In phase of inflammation due to edema of tissues pain syndrome develops. It significantly decreases in adequate draining of the wound. In case of necessity analgetics are additionally introduced (usually non-narcotic). In case of fever febrifugal preparations are used.

In patients with hard dysfunction of different organs and systems caused by trauma or complications of the purulent wound correction becomes necessary. In case of massive blood-loss hemotransfusion, transfusion of its components and blood substitutes is provided.

In case of massive wound defects with loss of fluid, proteins and electrolytes protein hydrolysates, native plasma, mixes of amino acids and pillion solutions are included into infusion substitution therapy. Into general therapy vitamins of different groups (C, B, E, A) and stimulators of regeneration (methylyracyl, .pentoxyl, potassium orotate, anabolic hormones) are used. At the same time treatment of accompanying illnesses that worsen general condition of the patient and heeling of wounds (correction of diabetes mellitus, normalization of blood circulation etc.)

Peculiarities of Treatment of Gun-Shot Wounds

Nowadays gunshot injuries are widely observed not only in war zones but also in everyday life. That's why patients with such injuries get both in military medical institution and in common hospitals.

Treatment of gunshot wounds has several principal differences. Each gunshot injury is considered highly infective. While providing PST, taking into consideration wide zone of injuring of tissues, cutting is done in big volume if possible, which is connected with presence of zone of molecular concussion. All the foreign bodies should be excluded. Bullets and splinters, which lay closely to vital organs, are the exceptions. They may be not excluded. Later covered by antibiotics therapy they become encapsulated and make no big harm for the organism. Although one has always to remember that any foreign body is the potential source of infection.

The peculiarity of small-shots injuries and consequences of using of special kinds of weapon (plastic mines etc.) is the presence of a big quantity of foreign bodies, placed in different parts of the organism. In such injuries without massive necrosis of tissues the PST is usually not provided and foreign bodies are excluded only if infectious complications appear.

The frequency of suppuration of gunshot wounds is very high, that's why after the PST of the wound primary stitches are not applied, and primary delayed or secondary stitches are used. Wounds are often treated in an open way and adequate draining has an important meaning. In some cases planned revision of the wound with narcosis is used for finding of sources of secondary necrosis in time.

During the treatment much attention is paid to creating of optimal conditions for oxygenation of surrounding tissues, which helps to minimize the zone of necrosis, which serves as a nutritive medium for bacteria, and to decrease the risk of development of anaerobe infection.

In traumatic amputation of the limb during the PST reamputation in healthy tissues is provided.

General treatment is different only in increased antibiotic and desintoxicative therapy, which is necessary in massive volume of necrotic tissues.

SURGICAL OPERATIONS

SUTURING TECHNIQUES

THE ELLIPSE

The ellipse is the workhorse of dermatologic excisional and reconstructive surgery of the skin. Nearly all simple excisions of the skin are done through the performance of the ellipse. Understanding and execution of the ellipse is a fundamental building block for performing more complicated dermatologic surgery procedures.

The basic principle of the ellipse is to close a round-to-oval defect in the skin by sewing the edges together (side to side); however, this will cause folds (dog-ears, darts) to form at either end (Fig. 12).

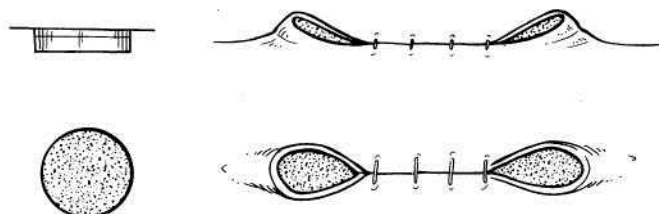


Figure 12. Horizontal and vertical views of the dog-ears formed by an elliptical closure.

These folds do not resolve spontaneously and require excision and lengthening of the scar line in order to obtain a smooth skin surface, thereby achieving good cosmesis. The excision of these folds turns the round-to-oval defect into an ellipse, which, on closure, will allow the skin to lie flat. The resulting closure line varies from a straight line to a curve, depending on the angle of the excision of the dog-ears from the closure line (Fig. 13).

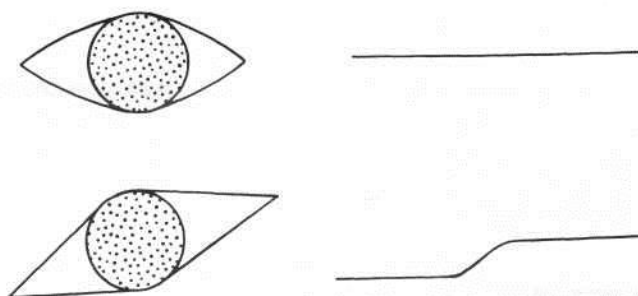


Figure 13. Example of closure lines resulting from the angle of excision of the dog-ears.

Cosmesis is best (a hidden, fine-line scar) when the final suture line is placed in a major skin fold, wrinkle line, or in the imaginary minimum skin tension line (MSTL). This makes the planning of the placement of the ellipse a most important stage in the procedure and probably the most important determinant to the achievement of excellent long-term cosmesis.

The determination of the MSTL for each procedure is based on a number of factors (Table 1). These include Langer's lines, gravity, direction of hair, wrinkle lines, and MSTL. The MSTLs usually agree with Langer's lines (Fig. 14a-b) but may vary from patient to patient, depending on age, obesity, laxity of the skin, gravity, and the muscles of expression (in the face).

MSTLs are determined by pinching the skin lightly between the fingers in different directions and noting where the resulting skin folds are finest [thin] (Fig. 14c).

The length of the ellipse is approximately three times the diameter of the primary excision defect. This differs from place to place on the surface of the skin, being less with thin skin (eyelid) and more with thick skin (back). Initially, a short ellipse can be planned and then, after the excision is completed, the flatness of the skin surface can be observed. Further lengthening of the ellipse may be necessary if dog-ears are apparent, indicating the presence of excess skin.

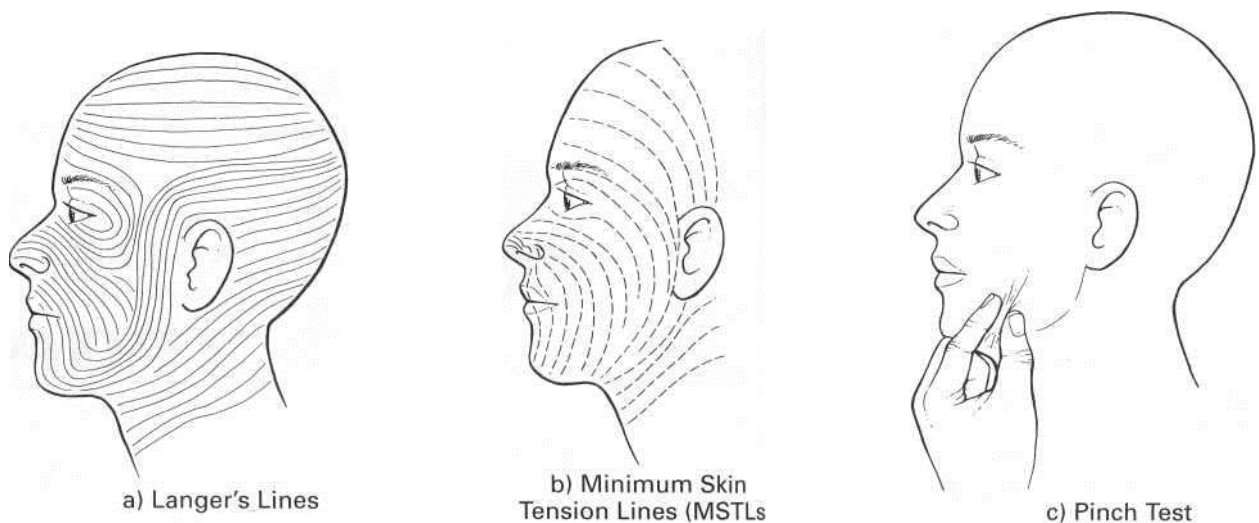


Figure 14. (a, b). Langer's lines and Minimum Skin Tension Lines (MSTLs) are used to determine the excision lines. (c) The "pinch test" is used to determine MSTLs.

The shape of the ellipse may vary from tangent-to-circle to fusiform. Figure 15a gives a narrower tip angle versus the wide tip angle of Fig. 15b. Less excess skin needs to be removed to achieve a flat surface when dog-ears are removed with the tangent-to-circle technique.

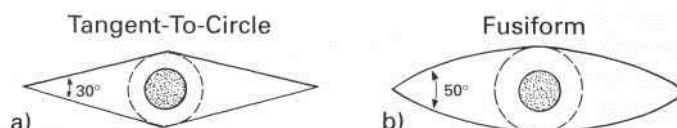


Figure 15. (a) Tangent-to-circle excision of dog-ears with 30° tip angle. (b) Fusiform excision of dog-ears has a wider angle at the tip and more skin is removed.

TABLE 1. Factors Influencing the Optimal Placement of an Ellipse

Major skin folds
Langer's lines
Wrinkle lines
Influence of underlying muscle groups on the skin
Patient positioning (gravity)
Direction of hair growth

SURGICAL METHOD

First, determine the direction and placement of the ellipse. The proposed elliptic incision lines are then marked with a marking pen. Local anesthesia is injected to encompass the area of the ellipse as well as an area up to 1 cm around the ellipse. Xylocaine 1% with 1:100,000 epinephrine is the standard solution used for anesthesia. It is preferable to buffer the solution with NaHCO₃ to reduce the pain during injection. It is important not to hurt the patient during the injection, and time should be taken injecting the anesthetic slowly, explaining the procedure to the patient, and engaging the patient in conversation to take his or her mind off what is going on, as well as to determine if the patient feels pain. When pain is felt, stop injecting and wait for several seconds for the pain to subside before resuming the injection process.

The injection is made into the dermis and less into the sub-dermal fat. Injecting into the subdermal fat is less resistant than the dermal injection, and there is no blanching of the skin, but the anesthetic effect is less.

The skin is then *cleansed* with Betadine, alcohol, or any antibacterial solution or soap of preference. The area may be draped and sufficiently bright lighting of the area arranged.

The skin to be excised is stabilized by the assistant's or surgeon's hands; the patient is asked to keep still and is advised that cutting is about to begin. The skin is then carefully incised through the full thickness of the dermis down to the subcutaneous fat. The incision is made at a 90° angle to the skin surface, providing right-angle skin edges. This is important so that closure of the edges will be perfect. If 90°-angled skin is approximated to 100°-angled skin, perfect closure will not be obtained (Fig. 16). Ask any carpenter to verify this! In order to cut the ellipse, the sharp end of the blade is pushed into the skin and pulled over the line of the ellipse. It is important to aim the blade over the line of the ellipse, moving the blade handle as the blade moves over the skin (Fig. 17).

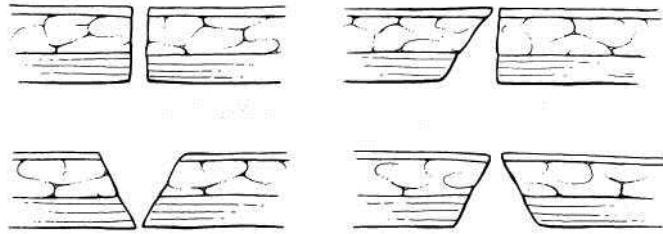


Figure 16. Illustration of the possible angles of excision to demonstrate the necessity of a 90° angle for perfect closure.

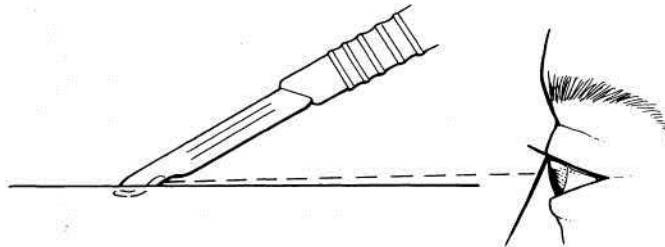


Figure 17. The scalpel blade handle is pulled over the line of the ellipse.

The scalpel handle must be kept parallel to the line that is being cut. If this is not done, a perfectly sharp 90° cut will not be made. When the entire ellipse is incised through the dermis into the fat, the elliptic skin is lifted up with toothed forceps and, by using either scissors or the blade, is dissected at the level of the dermal-fat junction.

Bleeding points are cauterized using the available method of electrocautery. It is preferable to pick up each bleeding vessel in the dermis with fine-toothed forceps, gently pull the vessel away from the base of the defect, and then cauterize the vessel by applying current to the forceps. The author's surgical unit uses a Valley Lab electrocautery machine. It is not necessary to cauterize all the small vessels of the dermis. These will stop bleeding when pressure is applied to them by approximation and sewing of the wound edges.

Be sure to confirm that the patient does not have a cardiac pacemaker which would make electrocautery hazardous.

Undermining

Undermining is a method of detaching the dermis and epidermis from the subcutaneous fat and fascia (Fig. 18). This is done to achieve greater movement of the dermal-epidermal unit (skin) over the underlying and less movable fat, fascia, and muscle, thus facilitating advancement, approximation, and closure of the wound edges.

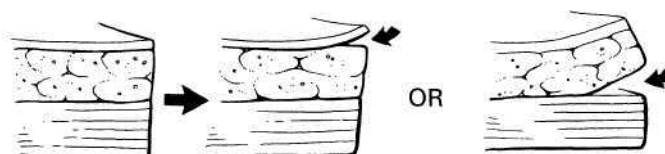

Figure 18. Undermining may be done at the dermal/fat junction or the fat/muscle junction.

Undermining is usually done at the dermal-fat junction or the fat-muscle junction with a blade or a scissors. When hair-bearing skin is to be moved (e.g., scalp, eyebrows, or beard), it is necessary to undermine below the level of the hair follicles which can be seen in the upper or midfat. The skin is lifted with a skin hook and the incision is made right under the dermis. The width of undermining is determined by the smoothing/flattening of the skin surface needed, the necessity to move the skin to obtain closure based on the size and location of the defect, and the surgeon's preference and experience. Undermining may need to be continued beyond the tip of the ellipse and up to 1 cm beyond the edges of the ellipse (Fig. 19). Undermining of the skin is not always necessary for exact placement of sutures.

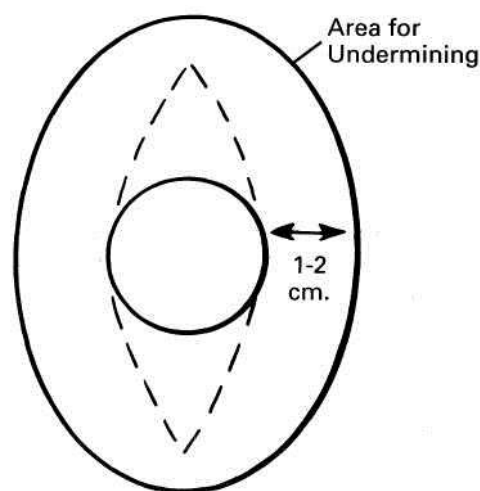


Figure 19. Hypothetical area for undermining, determined by amount of flattening needed, size and location of the defect, and surgeon preference.

Closure

After the skin is undermined, the blood vessels that have been severed in the process should be cauterized before closure is begun. A hook is used to lift up the skin edge. The light is shone under the skin surface, and bleeding points are sought and cauterized or, rarely, tied. When the wound is ready for closure, it is washed with saline which removes any debris that may have accumulated.

Almost all closures are done in two layers, beginning with subcutaneous absorbable sutures which hold the dermis together and followed by epidermal sutures which evert and close the skin edges.

Appropriate absorbable suture materials for subcutaneous placement include: PDS (polydioxanone), Vicryl, or Dexon. Five-0 or 4-0 strength should be adequate for dermatologic surgery. Generally, the suture is swaged onto a reverse-cutting, three-eighths circle, P1- or P3-size needle. When there is tension on the wound edges, 4-0 or 3-0 suture may be used. If too much

tension is applied to the skin, it will blanch and may necrose over the subsequent day or two due to lack of blood supply.

Commencing the Closure

A skin hook is placed at the end of the ellipse, and the edge is pulled upward and away from the center of the ellipse in the line of the closure (Fig. 20). This action will approximate the edges closer together and allow exact placement of the sutures. Subcutaneous sutures may be either individual or running, horizontal or vertical (Fig. 21). The methodology of each of these types is explained in Suturing Techniques, Chap. 16. Superficial "cutaneous" sutures are then placed on the surface to get exact leveling of the skin edges.

Careful placement of these sutures is very important, as they achieve the leveling of the skin edges and the smoothness of the skin, which determines the final cosmetic result.

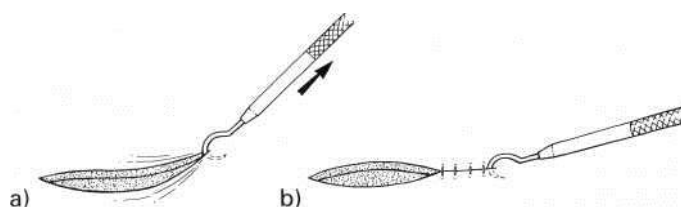


Figure 20. (a, b) The action of pulling the tip of the ellipse upwards and away from the center tends to approximate the edges, making closure easier.

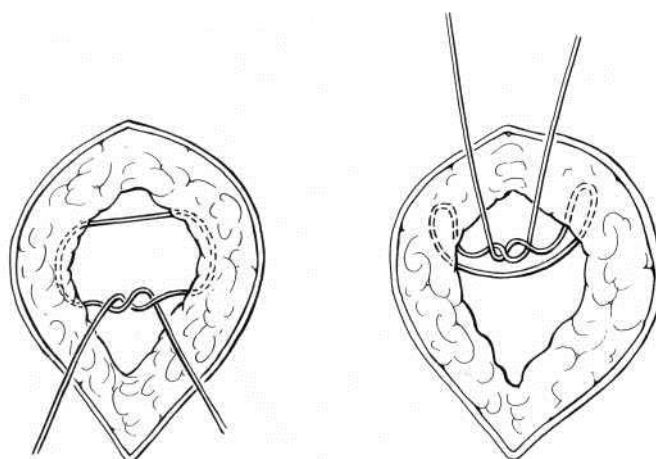


Figure 21. Horizontal and vertical subcutaneous sutures.

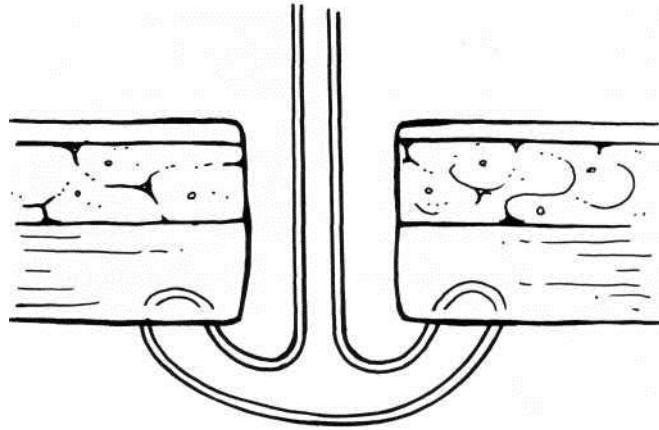


Figure 22. Proper placement of subcutaneous suture for perfect eversion of the skin edges.

When the subcutaneous suture is placed correctly at the *undersurface* of the dermis (Fig. 22), the skin edges will evert and approximate perfectly. This makes placement of the cutaneous or surface sutures very easy and exact. The subcutaneous suture is buried, does not show on the skin surface, and is absorbed over time. This suture pulls the skin edges together and holds the tension. It is easier to do interrupted subcutaneous stitches, as each suture may exert a different amount of tension. These sutures stay in place for weeks, giving the skin edges ample time to knit together and reducing to almost nil the risk of dehiscence (separation) of wound edges. The mastery of placement and tying of this stitch is an essential part of technique in dermatologic surgery.

Based upon the surgeon's personal preference, the skin surface of an ellipse may be closed from one tip to the other, or the method of halving may be used (Fig. 23).

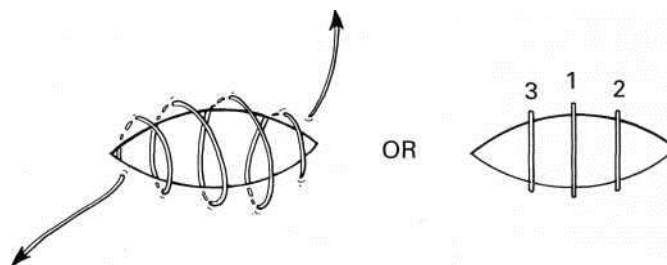


Figure 23. Closure of an ellipse may be accomplished by suturing from one tip to the other or by the method of halving.

Closure of the Skin Surface

The surface suture is used to level the epidermal surfaces so that the two edges are the same and healing will occur with a resulting smooth surface. This suture is placed very loosely in the skin, as it is not used as a tension suture to close the wound edge. Start the suture *beyond* the wound edge and end it beyond the wound edge on the other side. The progression of the suture may be made by any one of the three patterns in Fig. 24. A 6-0 nylon suture on a P1 or P3 needle is effective for closing the skin surface, using running sutures, which save time, or interrupted sutures.




Figure 24. Suture progression patterns for the ellipse.

A tip suture has recently been described which may assist in leveling dog-ears and thus may allow the surgeon to keep the length of the wound as short as possible. The author has not used this suture personally, but it may possibly be used fairly routinely in the future.

When the final sutures have been placed, gently squeeze the wound between gauze swabs for a few seconds to extrude any collected blood between the wound edges.

Drains: Drains are not routinely required; however, they are required when it is suspected that there may be oozing of blood or tissue fluid postoperatively because:

1. Not all of the dead space of an excision has been closed.
2. The excision is very large.
3. The patient has a tendency to bleed.

4. The patient has a possibility of having an infected wound. In this case, the drain may be placed and left in for 48 h and then removed. The drain can be constructed from the finger of a sterile glove or a Penrose drain can be used. It is also effective to leave a piece of sterile Vaseline or Xeroform gauze sticking into the wound to act as a wick and soak up any fluid which may collect within the wound.

It is helpful to photograph all excisions preoperatively and postoperatively for personal, teaching, and medicolegal reasons.

A pressure dressing is then placed over the ellipse consisting of a layer of antibiotic ointment covered with a Telfa (optional) gauze and silk tape, paper tape, or some form of elastic tape.

Instruct the patient to leave the operated area undisturbed for 48 h and then do postoperative wound cleaning and dressing once or twice daily for a week.

Remove cutaneous sutures at 5 to 7 days for convenience. Sutures may be removed from 3 to 14 days or even longer. Using this technique prevents both dehiscence of the wound and permanent suture marks in the skin from occurring.

Routine oral postoperative antibiotics are not necessary except under the following circumstances:

1. Patient's request
2. Cardiac valve disease
3. Permanent foreign body (e.g., pacemaker, artificial joint, etc.)
4. Immunosuppressed patient
5. Infected wound at time excision is performed
6. Long, arduous surgery under less than ideal conditions

Under these special circumstances, a broad-spectrum antibiotic is recommended, and very often the patient's cardiologist or internist will play a role in the choice of antibiotic. The antibiotic is taken 1 day prior to surgery and for 3 to 7 days postoperatively. Patients with frequently recurring herpes simplex outbreaks may be given acyclovir (Zovirax) orally starting on the day of surgery. A dose of 400 mg twice daily is recommended.

Given this course of care, at the time of suture removal, the wound will have healed with little or no redness at all. Although complications are rare, marked tenderness, swelling, oozing, pus formation, abscess, or symptoms of systemic infection can occur and must be promptly and appropriately handled.

PATIENT COMMUNICATION

It is appropriate to prescribe oral pain medication for the night of the surgery. Patients may be advised to apply an ice pack over the dressing for 15 min every hour and to apply pressure for any bleeding problems. Should bleeding occur and continue so that the bandage becomes soaked or drips with blood, the patient should be seen that night or as soon as possible. Calling patients after surgery at home the night of surgery to inquire about bleeding, pain, or other problems can be comforting for the patient and informative to the physician. If the patient describes acute swelling of the wound (possible hematoma), it is advisable to see the patient immediately. If a patient complains of swelling, redness, or pain prior to suture removal, it is wise to see the patient to rule out the possibility of wound infection.

Patients should be provided with a telephone number which will give them contact with the physician concerning any problem in the immediate postoperative period. It is preferable to examine a patient with a complaint of postoperative conditions which might signal complications as quickly as possible so that treatment can be undertaken before a serious condition develops (e.g., hematoma, infection, or dehiscence). Patients are greatly relieved to know that they have access to the physician if the need should arise.

The long-term (3 months and above) cosmesis and patient's acceptance of the ellipse depends on two major factors:

1. The smoothness of the surface
2. The fineness of the closure line

The smoothness of the surface depends on:

1. Complete removal of all excess skin (dog-ears)
2. Perfect approximation of skin edges from the horizontal viewpoint

The fineness of the scar line depends on:

1. Subcutaneous sutures that provide sufficient approximation of the dermis for adequate closure strength and approximation of the epidermis while assuring a lack of tension on the

epidermal closure.

2. Placement of the ellipse exactly in the MSTL, causing the scar to be under no tension to open. If the resulting scar is under continuous, long-term tension, a thicker or even hypertrophic scar will form. It is clear that the thicker scar will be much less acceptable to the patient.

The scar resulting from an ellipse or a simple side-to-side closure, which is basically an ellipse, is usually superior to that of any other closure because:

1. The suture lines can be placed completely within the MSTL and thus be almost completely invisible.
2. Less excess skin (dog-ears) needs to be removed with the closure.
3. Skin is not rotated, resulting in no additional skin folds which may need to be excised.
4. The direction of hair growth in the surrounding skin is not altered.

If the tip of the ellipse needs to be carried to an undesirable area such as the eyelid or other major cosmetic point, the direction of the point of the ellipse may be changed, or the ellipse may be shortened by an M-plasty or a O-T closure. These are described in detail elsewhere in the text.

Suture and scalpel techniques are learned skills which need to be honed and practiced on a regular basis if excellence of performance is to be obtained and maintained. Students, residents, and fellows are advised to practice these techniques at home, regularly, as would a musician or an athlete who practices to achieve and maintain peak performance. Fruit, especially oranges, bananas, and other thick-skinned and pliable fruits can be very effectively used to practice scalpel and suture technique. Keeping an instrument kit at home for practice is useful. Surgery, like other arts, must be practiced; it is not sufficient to do surgery only occasionally when the occasion presents itself.

SUTURING TECHNIQUES

Correct suture technique is crucial for functionally and cosmetically outstanding results in skin surgery. In addition to approximation of wound edges, properly placed sutures are important for skin edge eversion, minimization and redistribution of tension, elimination of dead space, and maintenance or restoration of natural anatomic contours while avoiding the formation of permanent suture marks on the skin surface. The suture technique chosen for a specific wound closure will depend on which of the above functions are most important as well as the anatomic location and wound edge thickness. Considering the importance of correct suture technique for successful wound closure, very little scientific study has been done on this subject. Most of the medical literature on suture techniques is based only on uncontrolled clinical studies.

Instrument tie

Proper knot tying is of paramount importance for correct suturing. Except for suture ligatures, sutures are tied with a needle-holder. The knot should be tied so as to lie flat against the surface with perfect apposition of the wound edges and without any significant tension or tightness. This will minimize the risk of wound edge strangulation and possible necrosis.

The instrument tie (Fig. 25) is started by pulling the long end of the suture taut. The needle-holder is looped once for a regular knot and twice for a surgeon's knot (Fig. 26a) around the suture pointing toward the suture's end. Next, the short end of the suture is grasped with the needle-holder and pulled through the loop(s) and pulled across the wound so that the loops lie flat against the wound without any bunching.

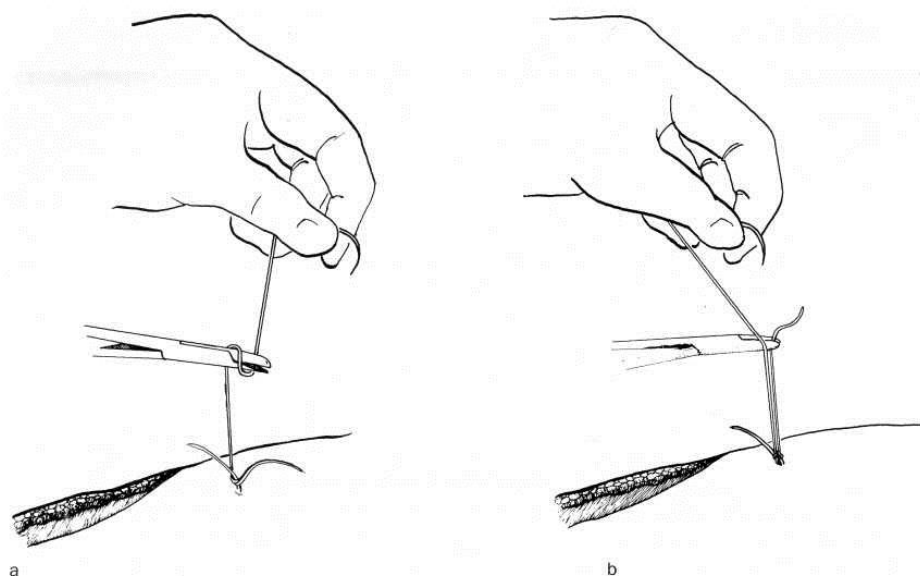


Figure 25. The instrument tie. (a) The needle-holder is ready to grasp the short end of the suture; (b) the suture has been tied down and is being held taut to make cutting it easier.

The tightness of the tie should take account of anticipated postoperative wound edge swelling (Fig. 26b-c). A square knot is created by looping the needle-holder around the long end of the suture in the opposite direction, grabbing the short end of the suture, pulling it through the loop, and tying it flat on the previous knot (Fig. 26b). Depending on the memory and thickness of the suture material being used, three to six knots may be needed to properly secure the suture in place. Thicker sutures and sutures with greater memory require more knots to be reliably secured in place. Tying the knot too tightly and failing to take account of expected wound edge edema may result in ischemia and permanent suture mark formation. To minimize this problem, the second knot may be tied loosely, leaving a small loop with the remaining knots squared off in the usual fashion (Fig. 26b). This loose loop allows the suture to adjust to any wound edema that may develop.

When suturing flaps or grafts in position, place the knot away from the flap or graft so as to minimize compression of the wound edge with compromised circulation. The knots are squared off to minimize the risk of suture loosening as well as strangulating. Granny knots should not be used because they are less secure and are easily tied too tight.

Some surgeons advocate the use of the surgeon's knot (Fig. 26a), in which the first knot consists of two loops, because of increased knot security before the knot is "locked" in place with the next squaring-off knot. This is especially helpful with monofilament sutures that have a lot of memory. Others feel that single-loop knots afford better control of knot placement and tightness. For buried sutures, the additional loop results in more foreign body material being buried in the wound. In most situations, the knot used is a matter of personal preference.

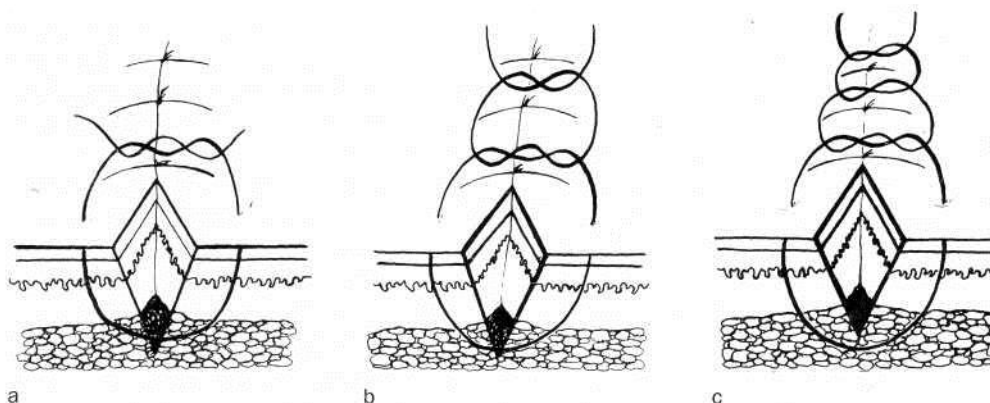


Figure 26. Loop throw. (a) Surgeon's knot; (b) second loop tied looser; (c) additional knots tied tighter. This allows the second loop to accommodate postoperative wound edge edema.

INTERRUPTED SUTURE

Simple Interrupted Suture

The simple interrupted suture is the most basic and versatile suture used by dermatologic surgeons. If the suture is placed close to the wound edges, very precise coaptation of the wound edges can be achieved even in wounds with edges of unequal thickness. If it is placed farther from the wound edges, deeper tissues can be pulled in with redistribution of tension across the wound. When the suture is properly placed in a flask-shaped configuration, wound edge eversion can be achieved.

The suture is placed by passing the needle through the epidermis into the deep dermis or subcutaneous fat, across the wound bed, and back up through the dermis and epidermis (Fig. 27). In order to maximize wound edge eversion, the suture starts close to the wound edge and moves farther away as it travels deeper. On the opposite side, the suture starts farther away from the wound edge and moves closer in as it travels toward the epidermis. This flask-shaped configuration brings in more deep tissue than superficial tissue to the wound edge with resulting wound edge eversion. One way to achieve this is to start the suture with the needle pointing away from the wound edge as it enters the skin and, on the opposite side, to consciously pull in deep tissue with the needle before piercing the epidermis on the way out. Wounds in which the edges are of unequal thickness can be aligned by taking a larger bite from the thinner edge and a smaller bite from the thicker edge. Wounds in which one edge appears higher than the other can be similarly aligned. The simple

interrupted suture can also be used as a temporary tacking suture to align complex wound edges or to properly position a flap.

The main disadvantage of the simple interrupted suture is the risk of Crosshatch marks across the suture line. This problem can be minimized by removing the sutures within 5 to 7 days before the formation of epithelial suture tracks is complete. Using minimally reactive monofilament suture such as polypropylene reduces suture marks. Elimination of tension across the wound with appropriate wound closure planning, adequate undermining, and the use of buried sutures will also reduce Crosshatch marks.

This suture has a tendency to cause wound edge inversion with resultant slowing or re-epithelialization and a noticeably depressed or grooved scar. This is most frequently seen when the skin is very thin or after the removal of a large amount of subcutaneous tissue as occurs in the removal of a large lipoma or epidermal cyst. This problem can be minimized by careful flask-shaped placement of the suture (Fig. 27). However, in extreme cases, an everting mattress suture may have to be substituted at strategic locations along the suture line.

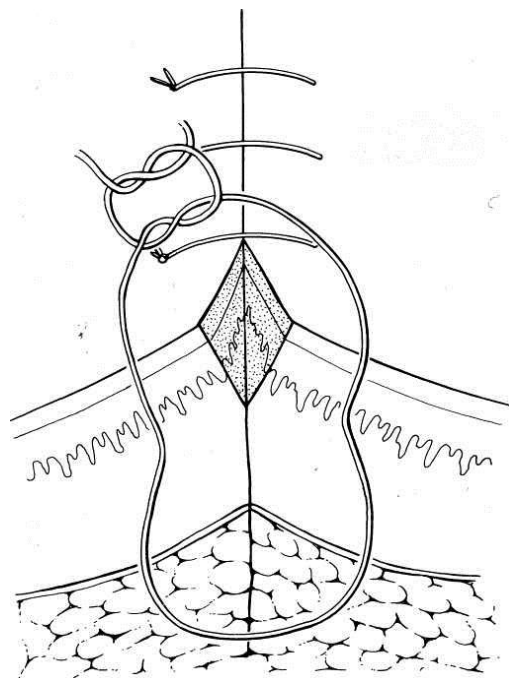


Figure 27. Simple interrupted suture with flask-shaped configuration to maximize wound eversion.

A minor problem when compared to a running suture is that the simple interrupted suture is more time consuming to place and remove especially for long suture lines. In settings where wound healing may be impaired due to advanced age or underlying disease, interrupted suture techniques may be preferred as interrupted sutures may have, with all other factors being equal, greater tensile strength, less edema, less induration, and less impaired microcirculation than running sutures.

Vertical Mattress Suture

The vertical mattress suture is one of the best sutures for wound edge eversion and that is the main indication for its use by dermatologic surgeons. It also reduces dead space and minimizes tension across the wound, doing the job of both a buried dermal suture and a skin suture. Because this suture requires four entry points in the skin, significant crosshatching can be expected if the suture is not removed within 5 to 7 days. Even though the vertical mattress suture can be used anywhere on the body, its use on the trunk and extremities results in significant suture marks because it has to be left in place longer than 7 days. On the face, some surgeons use vertical mattress sutures instead of two-layer closure, while others prefer two-layer closure of surgical defects. Even when deep dermal sutures are used, a few vertical mattress sutures can be placed along the wound for maximal wound edge eversion, while the intervening areas can be precisely approximated with simple interrupted sutures.

The vertical mattress suture (Fig. 28) is started by passing the needle into the skin 5 to 10 mm from the wound edge into the depth of the wound. Next, it is passed across the wound, entering the deep surface of the wound edge and passing up through the skin equidistant from the entry point. The needle is reversed on the needle-holder and the skin is entered 1 to 3 mm from the wound edge, passing superficially into the opposite side and exiting at a point equidistant from the entry point. The suture is then tied slowly so as to gather the tissue in without undue puckering. In the event when the suture is used for tension reduction rather than just wound edge eversion, a bolster should be placed between the suture and the skin so as to prevent the suture from digging into the skin which could lead to suture marks and wound edge necrosis. Whether to start the suture with the far or the near part first is a matter of personal preference. In either case, this is a relatively time-consuming suture to place.

Another variation of the vertical mattress suture is the near-far suture. The needle enters the skin 1 to 3 mm from the wound edge and passes out through the opposite side, wide of the wound edge. The needle is reversed entering near the wound edge and leaving the skin across the wound, wide of the wound edge. This modification may be helpful in elevating deep tissue.

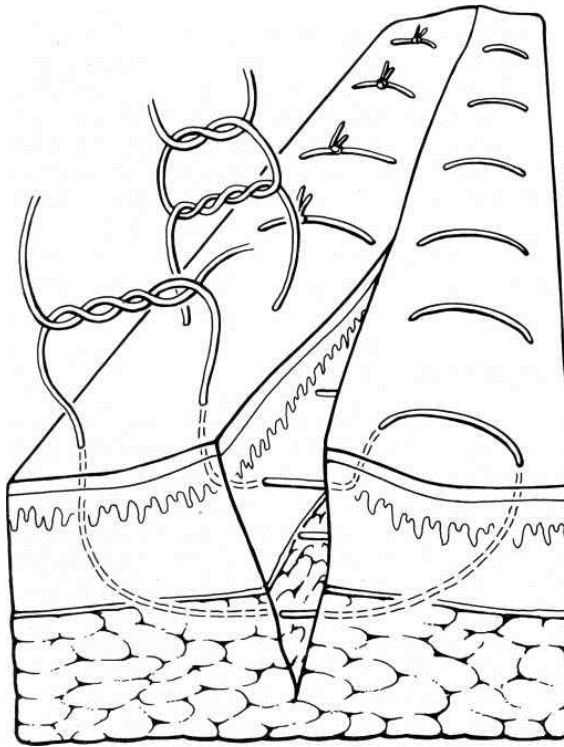


Figure 28. Vertical mattress suture.

Half-buried Vertical Mattress Suture

The half-buried vertical mattress suture is a modification of the standard vertical mattress suture designed to eliminate one-half of the four suture marks in areas such as the face where minimal scarring is important. This suture is intermediate between a simple interrupted and standard vertical mattress suture in terms of relieving tension across the wound and achieving eversion of the wound edges. It is sometimes used along the hairline where the buried component is placed on the face and the exposed part of the suture is placed in the hairline.

The half-buried vertical mattress suture (Fig. 29) is placed with the needle entering on one side of the wound edge, passing through the deep tissue on the opposite side, and back out through the side of entry. It is relatively difficult to properly align wound edges with this suture and as a result it is rarely used in dermatologic surgery.

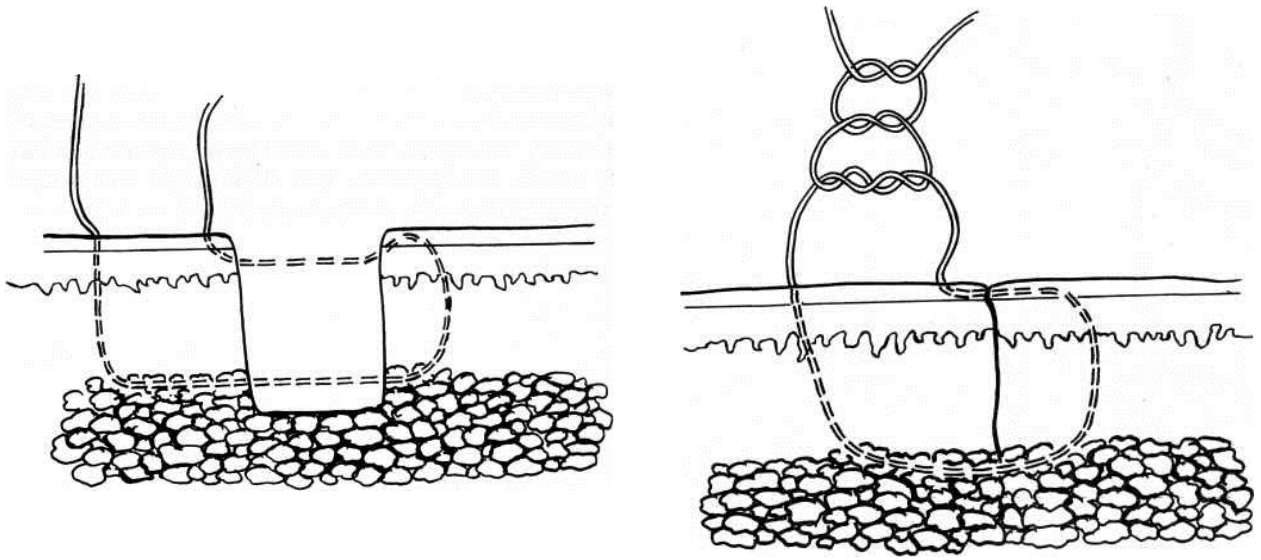


Figure 29. Half-buried vertical mattress suture.

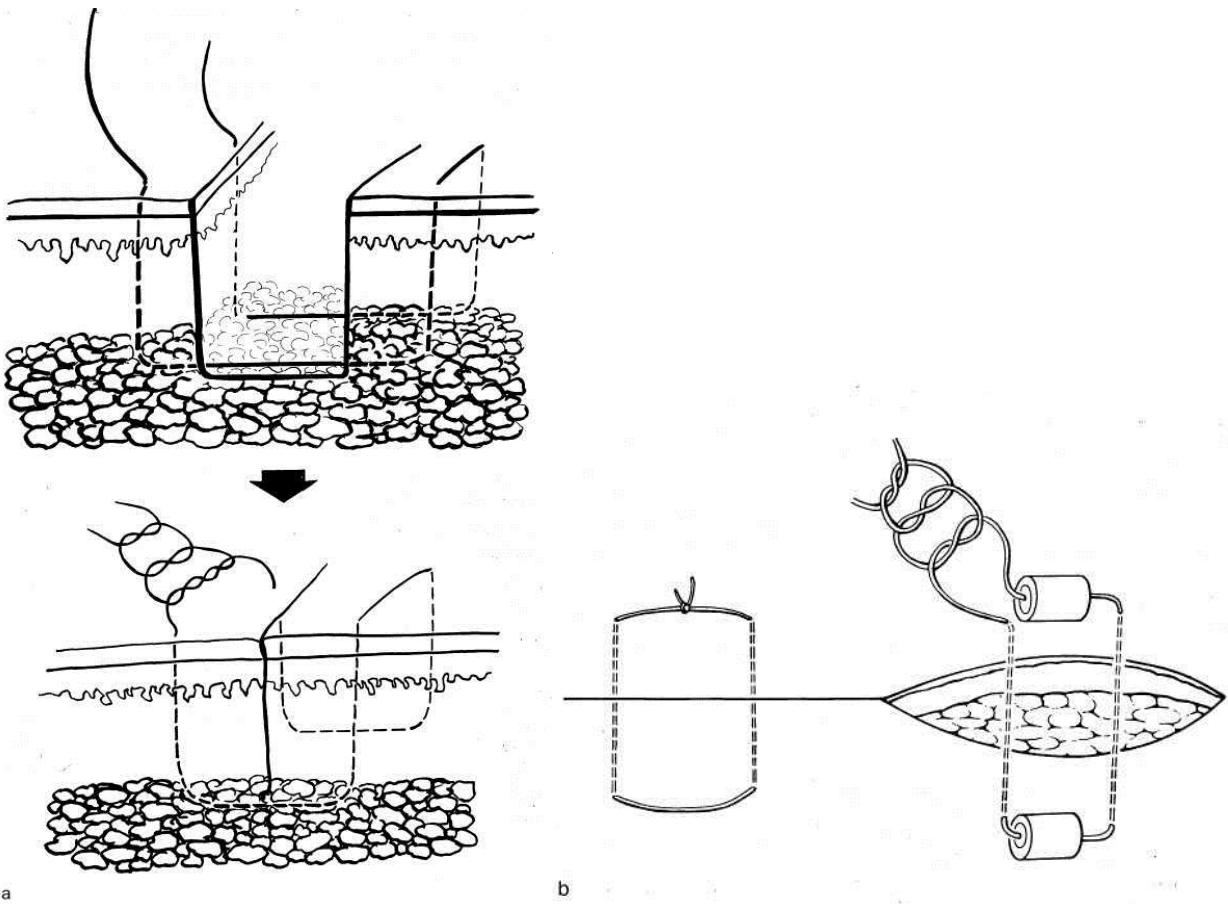


Figure 30. (a) Horizontal mattress suture; (b) horizontal mattress suture with a bolster in place.

Horizontal Mattress Suture

Classically, the horizontal mattress suture has been used for reducing tension across wound closures under significant tension. This suture can be placed as an initial tension-reducing or holding suture and to bring the wound edges closer together so that subcutaneous sutures can be placed to distribute tension and close the wound. At this point, if the tension has been adequately

distributed, the horizontal mattress suture may be removed. If tension across the wound persists, the horizontal mattress suture may be left in place for a few days while early wound healing proceeds and removed before suture tracks have had a chance to form. In areas at high risk for wound dehiscence, such as the lower extremities, the horizontal mattress suture may even be left in place for a few days after the skin sutures have been removed. However, when the horizontal mattress suture is left in place for more than 7 days and sometimes even less time, significant suture tracks are almost certain to form.

Alternatively, the horizontal mattress suture may be used to presuture 12 to 24 h before a proposed excision that may be under considerable tension. This short-term tissue expansion may allow as much as 30 percent more tissue to be removed at the time of definitive excision. Presuturing has been used successfully in alopecia reduction, rhytidectomy, and congenital nevus excision.

The suture is started a fair distance from the wound edge, with the needle passing deeply across the wound edge and exiting across the wound equidistant from the wound edge (Fig. 30). Next, the needle enters the skin some distance parallel with the wound edge and equidistant from the wound edge, crossing deeply under the wound to the opposite side where it is tied. If this retention suture is to be left in place, bolsters should be placed under the visible suture line on each side of the wound (Fig. 30*b*) so as to prevent the suture from cutting into the skin. Buttons can be very effective bolsters.

The main disadvantage of this suture is the possibility of wound edge necrosis as this suture can easily strangulate the dermal plexus between its limbs. This problem is minimized by taking large bites with the needle to encompass large amounts of tissue, by using bolsters, by tying the suture only as tight as necessary to accomplish the task of bringing the wound edges together, and by removing the suture as soon as possible, ideally within 2 days of wound closure. Prior to contemplating the use of a horizontal mattress suture for tension reduction, the surgeon should consider other means of reducing tension across the wound, including appropriate undermining and closure orientation, the use of flaps from areas of tissue excess, the use of preoperative or intraoperative tissue expanders, the use of serial excisions, and the use of subcutaneous sutures.

Another effect of the horizontal mattress suture is prominent wound edge eversion. This property can be utilized by using a relatively fine suture material and taking relatively small bites when the suture is placed across a tension-free wound that has been closed with buried sutures. This achieves wound edge eversion, and, if the suture is not tied too tightly, wound edge necrosis is unlikely to develop.

A cross-stitch variant of the horizontal mattress suture has been described to secure individual hair transplant punch grafts in their recipient holes. The suture is placed similarly to a regular horizontal mattress suture except that whenever the suture crosses the wound it is placed

diagonally across instead of directly across. The suture enters the skin only in the donor site dermis and only crosses across the punch graft. Thus, trauma to the graft is minimized. This time-consuming suture technique minimizes *cobble stoning* or elevation of the punch grafts and there is no need for postoperative dressings.

Half-buried Horizontal Mattress Suture

The half-buried horizontal mattress suture is primarily indicated for the positioning of various corners and tips, including flap tips, M-plasty tips, and V-Y closure tips. It can also align the edges of tangential flaps and flaps with ischemic wound edges. The buried limb of this suture is placed in the potentially ischemic area in order to minimize interference with the dermal vascular plexus. This reasoning has been challenged because a superficial simple interrupted suture through a flap tip does not appear to result in increased risk of flap tip necrosis.

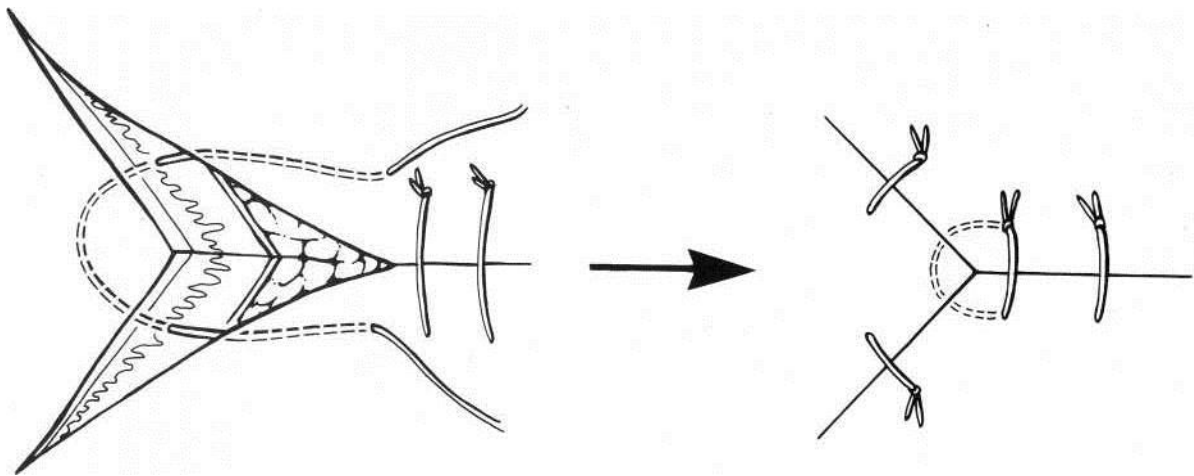


Figure 31. Half-buried horizontal mattress suture used to secure a corner in place.

The half-buried horizontal mattress suture should only be placed after all tension at the wound edge has been eliminated with other sutures. The needle enters the skin on the wound edge away from the tip and passes into the wound relatively superficially adjacent to the tip (Fig. 31). Next, the needle is passed horizontally through the tip at the same level. The suture is completed by passing through the opposite wound edge at the same level. The suture is tied very gently under minimal tension to minimize any trauma to the flap tip. Very fine 5-0 or 6-0 suture should be used for most tip stitches. The portion of the suture lying on the surface should not cross the tip itself as this may increase the risk of tip necrosis.

Interrupted Subcutaneous Suture

A wound gains only 7 percent of its final strength after 2 weeks. As most skin sutures are removed within 1 week of placement, absorbable buried sutures are used as part of layered wound closure. This provides support for the wound until tensile strength has increased sufficiently to prevent wound dehiscence.

Deep, buried sutures are placed into wounds to reduce or eliminate tension on the wound edges. On the trunk and extremities, where tension across wounds is greatest, the use of buried sutures may reduce the amount of scar spread. Buried sutures can align the wound edges so that the skin edges are closely approximated even before the placement of skin sutures. Deep sutures can eliminate dead space and align deep structures such as skeletal muscle or fascia. Deep sutures can also be used to anchor overlying tissue to underlying fixed structures such as periosteum to maintain proper facial contour and function. This is exemplified by the anchoring to the maxillary periosteum of a meilolabial flap used to close a nasal defect.

Buried Dermal Suture

The buried dermal suture is used routinely as part of layered closures in dermatologic surgery to eliminate tension across the superficial wound edges and to properly align the wound edges. A properly placed buried dermal suture will allow the easy placement of skin sutures without tension. As this suture is placed at the dermis-fat junction, the knot has to be buried so as to minimize tissue reaction to the suture and extrusion through the wound.

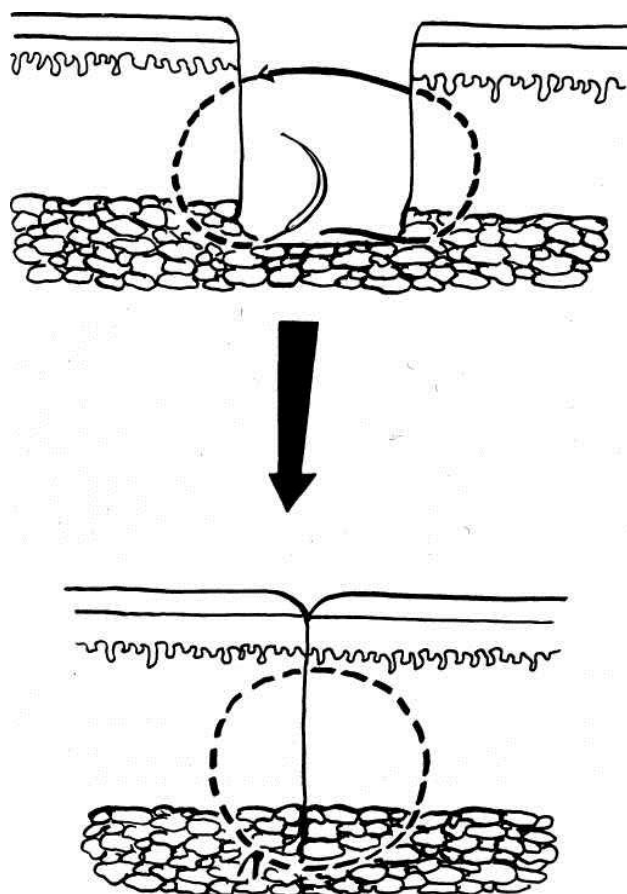


Figure 32. Standard buried dermal suture.

The suture is started with the needle entering the undermined deep surface of the wound up into the deep reticular dermis, across the wound, entering the opposite reticular dermis at the same

level, and passing down into the subcutaneous fat (Fig. 32). Therefore, when the knot is tied, it will be buried away from the surface of the wound.

If several buried sutures are placed in a wound with stiff and thick edges, the last few buried sutures may be difficult to place as the wound edges become closely approximated. In such cases, it may be easier to place all of the deep sutures before tying any of them. This allows better access to the wound as the wound edges remain separated.

Deep Subcutaneous Suture

The deep subcutaneous suture is entirely subcutaneous. It is used to decrease the amount of dead space, to anchor flaps, and to align deep structures. Because it is deep, tissue reaction to the suture or suture extrusion through the wound is very unlikely even if nonabsorbable suture material is used. Therefore, the knot need not be buried.

The suture is placed by passing the needle through the subcutaneous tissue from superficial to deep, across the wound, and up through the subcutaneous tissue on the other side (Fig. 33). In order to minimize fat necrosis and maximize the amount of tissue moved, the bite should be relatively large and ideally some fibrous tissue such as fascia should be included. To maximize the amount of dead space eliminated as the needle is passed across the floor of the wound, additional tissue may be picked up from the wound base before proceeding to the other side, resulting in a three-pointed vertical suture.

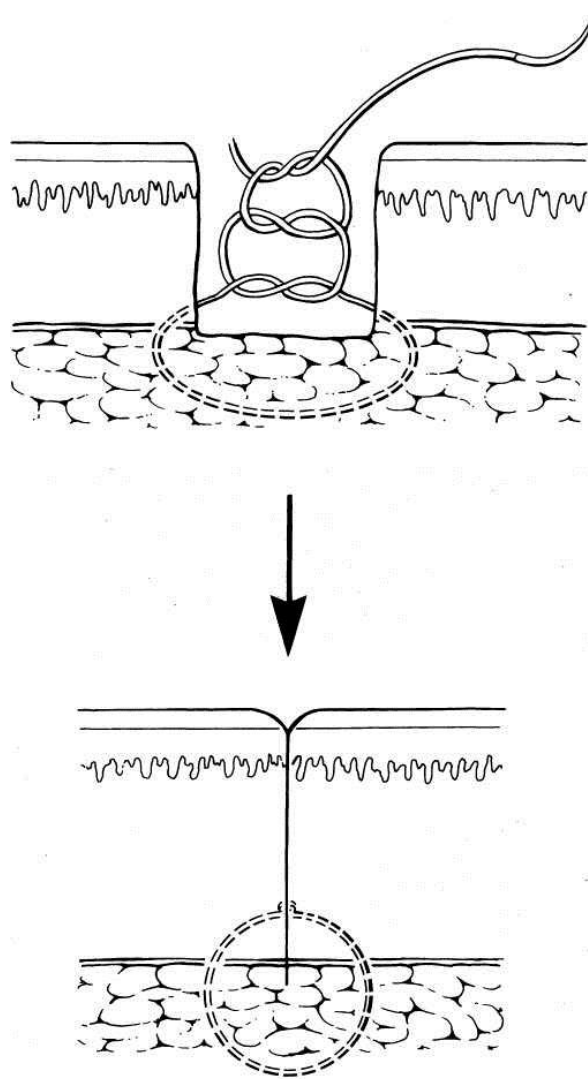


Figure 33. Deep subcutaneous suture.

Buried Horizontal Mattress Suture

The buried horizontal mattress suture is a purse-string suture that is occasionally used to eliminate dead space or reduce tension across wounds in areas where there is not enough room to place vertical sutures such as defects on the nose with its stiff dermis and minimal subcutaneous tissue. Also, it can be used as a purse-string suture to close off dead space such as is seen after the removal of an epidermal cyst. This suture has to be placed deeply and tied not too tightly as the enclosed tissue can become easily strangulated.

The needle enters the deep dermis or subcutaneous fat and is passed horizontally to pass back into the wound at the same level (Fig. 34). Next, it crosses the wound and passes horizontally through the opposite wound edge. Care is taken not to tie the suture too tightly.

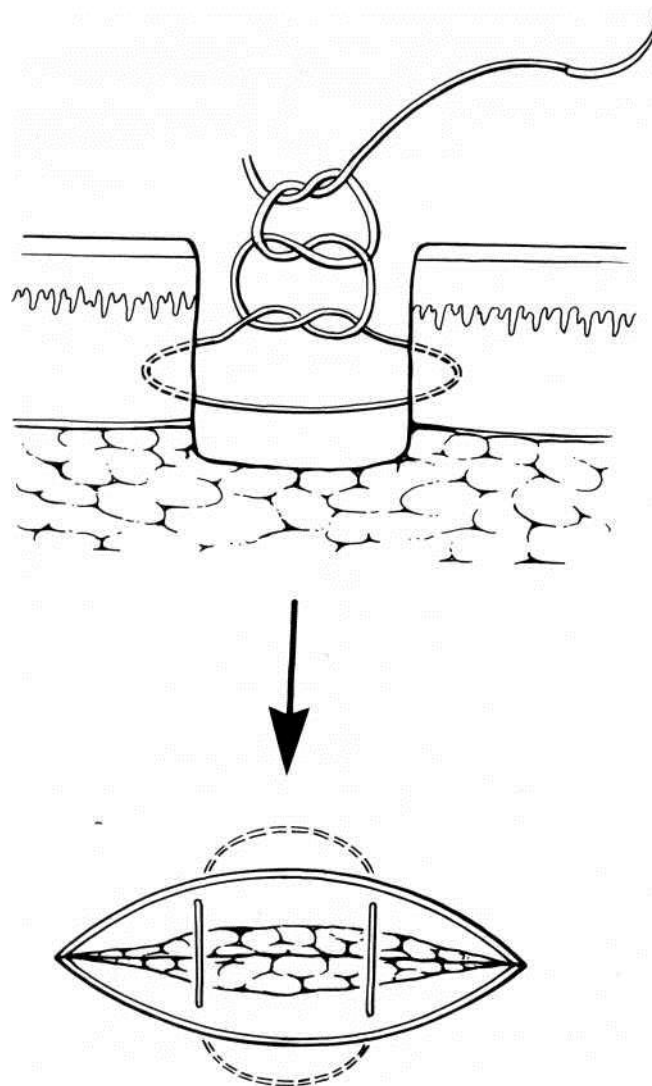


Figure 34. Buried horizontal mattress or purse-string suture.

Buried Vertical Mattress Suture

One disadvantage of the standard buried dermal suture is that the wound edges are pulled flat without significant wound edge eversion. The buried vertical mattress suture incorporates a modification of the buried dermal suture that maximizes prolonged wound edge eversion with resulting improved wound healing.

The buried vertical mattress suture (Fig. 35) can be visualized as a standard vertical mattress suture that is completely moved below the skin surface while maintaining its shape. The suture is more superficial farther from the wound edge than at the wound edge. The needle enters the wound edge from the deep undermined surface and is passed superficially and then turned to move toward the deep dermis where it reenters the wound. Next, it passes across the wound, entering the deep dermis, and passing first superficially and then deeply into the subcutaneous fat at the base of the undermined wound edge. As the suture is tied with a buried knot, the enclosed tissue from the superficial lateral sides is pulled in, resulting in significant wound edge eversion. It is important to avoid coming too closely to the underside of the epidermal surface with the suture as this may result

in puckering, suture extrusion, and necrosis in the area. In order to successfully place this suture, a half-circle needle is necessary.

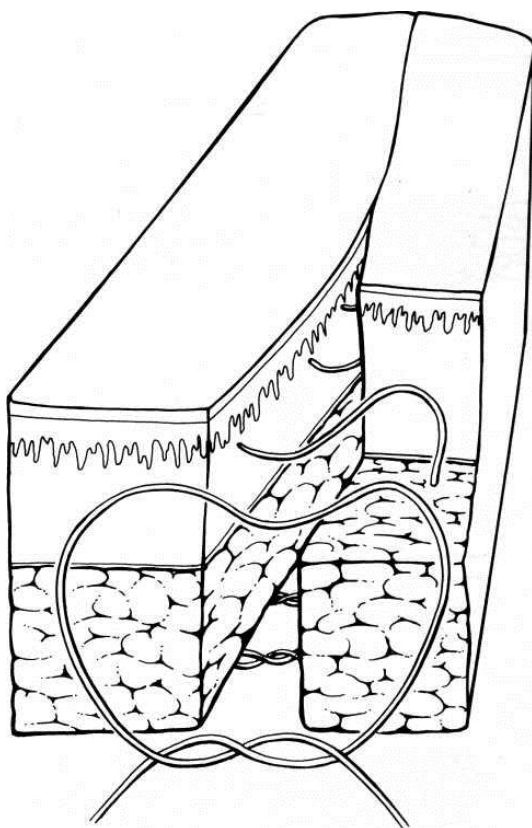


Figure 35. Buried vertical mattress suture.

RUNNING SUTURE

Simple Running Suture

The simple running suture can be used in situations where the wound edges are of equal thickness without tension, closely approximated, and with an absence of subcutaneous dead space. This usually implies that the wound has been substantially closed with buried sutures.

The simple running suture is started as a simple interrupted suture that is tied, but the end with the needle is not cut (Fig. 36a). The suture is continued by passing the needle through the dermis or into the subcutaneous fat from side to side, over and over, until the end of the wound has been reached (Fig. 36b). The suture is tied to the final loop of suture (Fig. 36c). It is important to constantly keep adjusting tension on the suture so that it is even without puckering or gaping of the wound edges. An assistant may be helpful in maintaining an appropriate amount of tension on the suture line and keeping the suture out of the surgeon's way by gently pulling on the loose suture material. The placement of the bites should be evenly spaced from the wound edges and along the suture line. Whether the perpendicular limb of the suture crosses the wound within the wound or along the surface is a matter of the surgeon's personal preference.

This suture is most useful for wounds that have already been closed by buried sutures, for the attachment of full-thickness or split-thickness skin grafts, and in areas of thin skin such as the

eyelids, ears, neck, and scrotum. This suture is relatively quick and easy to place, making it an ideal suture to close long suture lines. By eliminating all but two knots, there is less suture material resting against the skin, resulting in the development of less suture mark scars. However, fine adjustments along the suture line are difficult to make, and the suture has a tendency to pucker when one is suturing very lax and thin skin such as eyelid skin. In thin skin, the knots at each end may be tied over small bolsters to prevent the knots from cutting into the tissue.

Running Locked Suture

The running locked suture (Fig. 37) is a variant of the simple running suture in which, after the placement of each loop, the needle is passed through the previous loop prior to starting the next loop. It is also known as a *baseball stitch*. It is intended for the closure of well-vascularized wounds under a moderate amount of tension. The wound edges should be stiff and of equal thickness without a tendency for inversion. It is stronger than a simple running suture, but, if placed too tightly or if significant postoperative swelling develops, tissue strangulation with wound edge necrosis may ensue. Once a loop is locked in place, it is extremely difficult to adjust tension. It is used primarily on the scalp for the closure of scalp reduction defects and hair transplant donor sites. Occasionally, it has been used for defects of the forehead, back, and proximal thighs. This suture is strong and rather quick and easy to place but should be used sparingly and only when clearly indicated because of the potential for tissue strangulation if not placed properly.

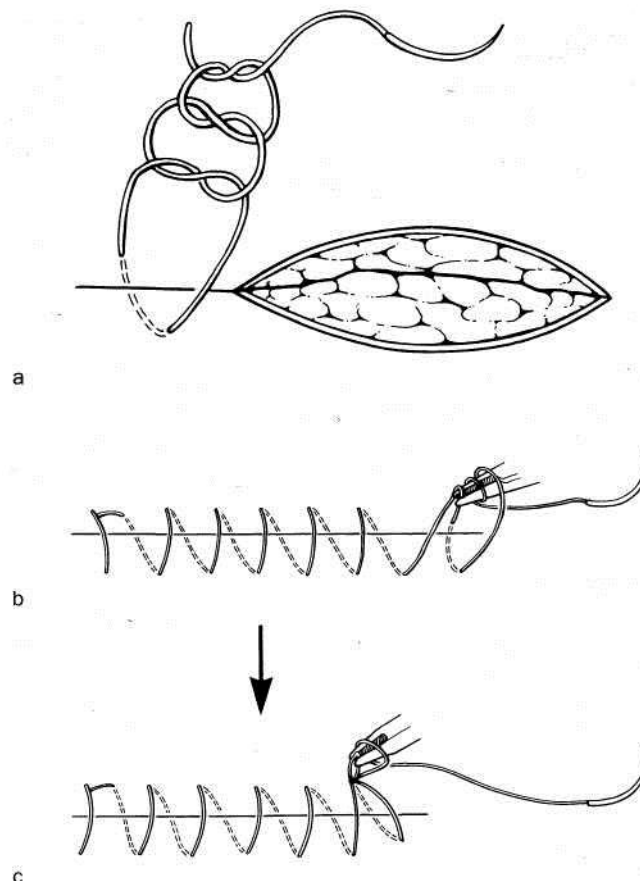


Figure 36. Simple running suture. (a) Start with simple interrupted suture; (b) continue with over-and-over running suture; (c) finish by tying the suture to the last preceding loop.

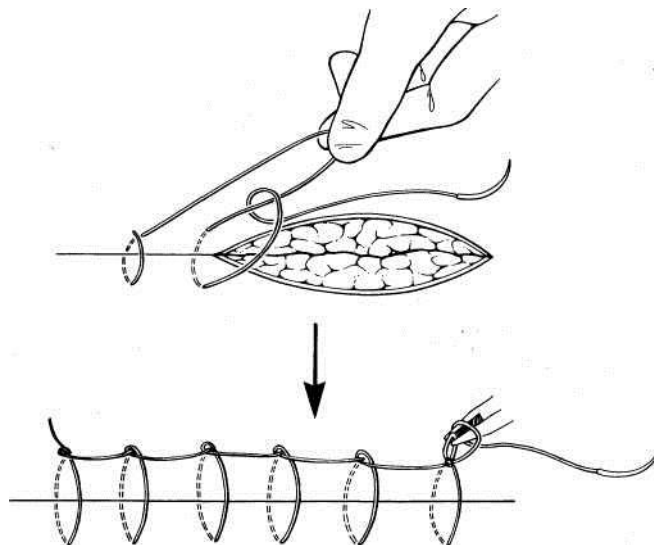


Figure 37. Running locked suture.

Running Horizontal Mattress Suture

The running horizontal mattress suture is primarily a skin edge everting suture. It is the ideal suture for closure of wounds with a significant tendency for wound edge inversion such as the thin skin of the eyelids, neck, scrotum, or dorsa of hands. In addition, by pulling in additional tissue to the wound edge, spreading of facial scars as seen in young patients can be minimized. At the other end of the age spectrum, surgical defects in elderly patients with very lax thin skin have naturally inverting wound edges. They may benefit from the maximal wound edge eversion achieved with a running horizontal mattress suture.

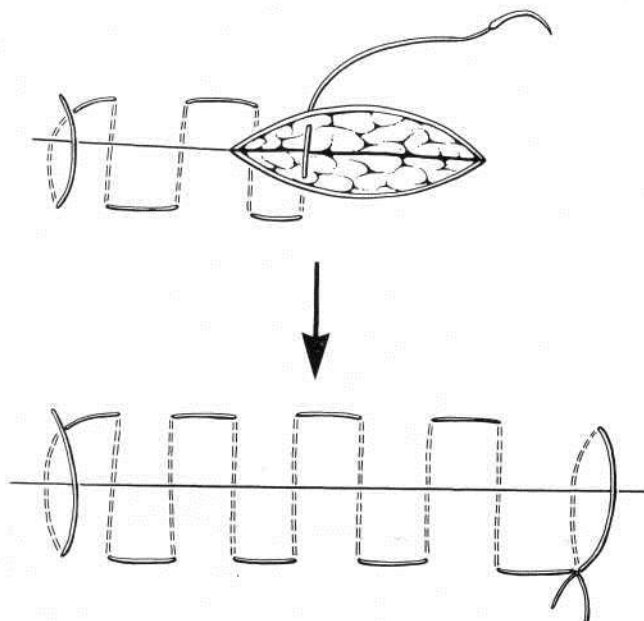


Figure 38. Running horizontal mattress.

The running horizontal mattress suture (Fig. 38) is started as a simple running suture, but, instead of crossing the wound with each loop, the needle reenters the skin farther along the wound on the same side where it exited the skin. Next, the needle passes in the dermis to the opposite side, exits the skin, and reenters on the same side. This is repeated along the entire suture line with the suture tied to the last loop that was placed.

This suture should be used only for wounds where the wound edges are relatively well approximated with buried sutures when maximal wound edge eversion is desired. If the suture is tied too tightly, wound edge strangulation and necrosis may develop. Therefore, meticulous placement is required, and the suture should be used sparingly in wounds that may be ischemic such as skin flaps and wounds on the trunk and extremities.

Running Subcuticular Suture

The running subcuticular suture is basically a buried running horizontal mattress suture. It is one of the more difficult sutures to place, but properly placed it results in a most elegant closure. It is ideal for the closure of wounds in areas where the suture has to remain in place for more than 7 days. As the suture is buried, there are no suture marks to worry about, and the suture may be left in place for several weeks without difficulty, or when absorbable suture material is used the suture may be left in place until it is absorbed. It is most useful for the closure of wounds on the trunk and extremities where prolonged wound support is essential to avoid wound dehiscence and to minimize scar spreading. As this suture is capable of only modest wound edge alignment, it should be reserved for wounds in which the tension has been eliminated with deep sutures and the wound edges are closely approximated and of approximately equal thickness. Even though it can be used on the face, other suture techniques provide better wound edge alignment and eversion. Also, as sutures are usually removed within 7 days on the face, suture marks are rarely a problem when nonreactive monofilament sutures are used.

The running subcuticular suture should be placed with a nonreactive monofilament suture such as polypropylene to facilitate suture removal and to prevent suture breakage within the wound.²⁶ The needle enters the skin 5 to 10 mm from one end of the wound and is passed into the wound at the tip (Fig. 39). Next, the needle is passed from one side of the wound to the other in the mid-dermis, taking a horizontal bite on each side and continuing down the length of the wound, backtracking slightly with each pass across the wound. As the distal end of the wound is reached, the needle is passed out from the wound, exiting approximately 5 to 10 mm from the edge. The smaller the bites that are taken with each pass, the better the wound edge approximation. If no wound gaping is evident, the two suture ends can be tied loosely together or affixed to the skin with surgical tapes. If any gaping is evident, each suture end is tied to itself, taking out any laxity as needed with multiple slipknots. Some surgeons prefer to tie the suture ends over a small bolster to minimize suture slippage and the possibility of the knots' sinking under the skin surface which

would make suture removal difficult. Another alternative is to tie the suture ends to a metallic suture tensor device that pulls the suture ends in opposite directions, maintaining the closure properly aligned. If some gaping still persists, it can be closed with a small simple interrupted suture that is removed within 7 days. For long wounds, one loop of suture should be brought out every 2 cm to the skin surface to facilitate suture removal.

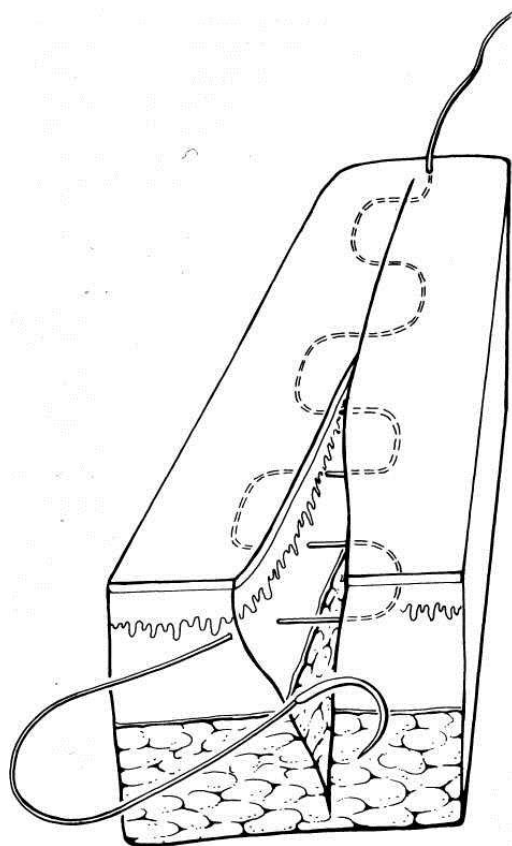


Figure 39 Running subcuticular suture.

An alternate method for running subcuticular suture placement is the use of absorbable sutures. In this case, the suture is started within the wound at one end as a buried dermal suture, but only one end is cut. The suture is continued as a regular running subcuticular suture. At the other end of the wound, the suture is ended by tying it to the last loop that has been placed. Thus, this suture is entirely buried, not requiring suture removal. However, if the patient develops a suture reaction, pruritus, suture abscesses, and suture spitting may develop. Some surgeons advocate the use of permanent sutures left in place indefinitely as this can reduce scar stretching. If nonabsorbable sutures are to be used for totally buried sutures, clear nonreactive suture material such as polypropylene should be used.

Running Subcutaneous Suture

The running subcutaneous suture is designed for the closure of the deep component of relatively long surgical defects that are only under moderate tension. It replaces the buried dermal interrupted suture in selected situations.

The suture is started with a buried dermal suture that is tied, but only one end is cut (Fig. 40). The other end with the needle is used for a vertical running suture starting in the subcutaneous

fat and moving up into the reticular dermis. Next, the needle crosses across to the other wound edge and enters the reticular dermis, moving down into the subcutaneous fat. This is repeated over and over until the wound is closed. At each step, the suture is tightened to eliminate tension and gaping of the wound. The suture is completed by tying the loose end to the last loop placed.

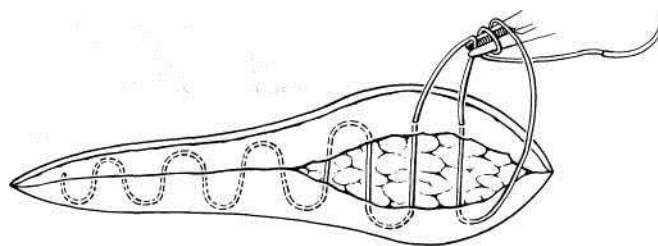


Figure 40. Running subcutaneous suture.

The main advantage of this suture is the speed of placement over that of interrupted sutures. However, if the suture material were to rupture anywhere along the suture line, the entire wound might dehiscence or a subcutaneous dead space could form under the skin edge without being apparent at the surface. Therefore, this suture should be reserved for wounds under a relatively small amount of tension.

BASTING SUTURE

Interrupted Basting Suture

The interrupted basting suture is designed to help a skin graft adhere to its wound bed, especially when the surgeon is grafting a concave wound bed.

After the periphery of the graft has been sutured in place, the suture is placed vertically through the graft into the wound bed, taking a bite of tissue from the wound bed and exiting back out through the graft. The suture is tied snugly. To maximize graft adherence to the wound bed, the suture is often tied over a bolster such as a piece of cotton or a dental roll covered with antibacterial ointment.

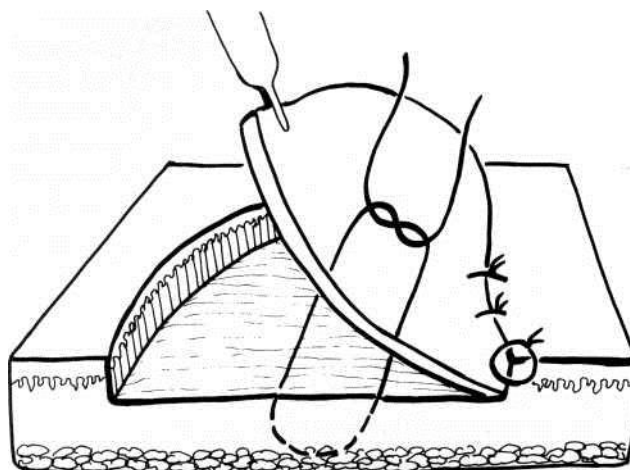


Figure 41. Visualized basting suture.

When a basting suture is placed blindly, a blood vessel may be lacerated in the wound bed with resulting bleeding and possible hematoma formation. To eliminate this possibility, the suture should be placed under direct visualization (Fig. 41). The graft edge is only partially sutured in place, and the basting suture is placed through the graft and, with the graft elevated, the bite through the wound bed is made under direct visualization. After all of the basting sutures have been placed, the remainder of the graft margin is sutured in place. The basting suture can be placed by using either an absorbable or nonabsorbable suture material such as polypropylene or mild chromic gut, respectively.

Buried Basting Suture

The buried basting suture is used as a flap- or skin graft-anchoring suture. The needle is passed under direct visualization horizontally through the undersurface of the flap or graft, staying relatively deep (Fig. 42). Next, the needle is passed horizontally, taking a bite through the wound bed, and is tied in place. If anchoring is necessary to maintain a concavity, the deep bite has to encompass some immobile structure such as the periosteum. In anchoring a flap, the suture has to be placed along the long axis of the flap so as not to compromise the vascular pedicle.

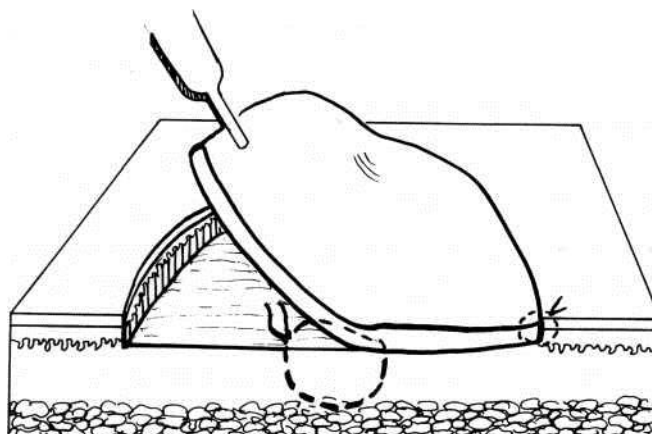


Figure 42. Buried visualized basting suture.

Running Basting Suture

The running basting suture is designed to quickly secure large skin grafts to the wound bed so as to minimize the risk of grafts shearing from the wound bed. The suture is started as an interrupted basting suture, but the needle end of the suture is not cut and the suture is continued. The needle enters through the graft, into the wound bed, and back out farther along. This is repeated until the graft is secured in numerous locations, and the suture is finally tied to the last preceding external loop or to the starting point of the suture. The most common suturing design is a spiral basting suture from the center of the graft to its periphery. To eliminate the need for suture removal with the risk of graft displacement, this suture is usually placed by using absorbable suture material.

A variant of this technique, called the *upper dermal running stitch*, has been described to secure rows of standard hair transplant grafts in their recipient sites, prevent cobblestoning of the grafts, and eliminate the need for postoperative dressings. The suture is run through the dermis of the recipient area between each recipient hole, and each graft is placed under the suture into each recipient hole with the overlying suture securing it in place without passing through the graft itself.

SUTURE REMOVAL

Suture marks are due to epidermal downgrowth along the suture track seen within 5 to 7 days of suture placement and aggravated by sutures being tied too tightly. Sutures should be removed at the earliest possible time to prevent or minimize suture reaction and suture marks. However, they should remain in place long enough to prevent wound dehiscence and scar spread. In general, the less blood supply to an area and the greater tension across a wound, the longer the sutures should be left in place. On the face and ears, most skin sutures should be removed within 5 to 7 days, with eyelid sutures being removed in 3 to 5 days. Neck sutures should be removed in 7 days and scalp sutures in 7 to 10 days. On the trunk and extremities, risk of wound dehiscence takes precedence over suture marks. Sutures on the trunk and upper extremities should be left in place for 10 to 14 days. Lower extremities may require 14 to 21 days of suture support.

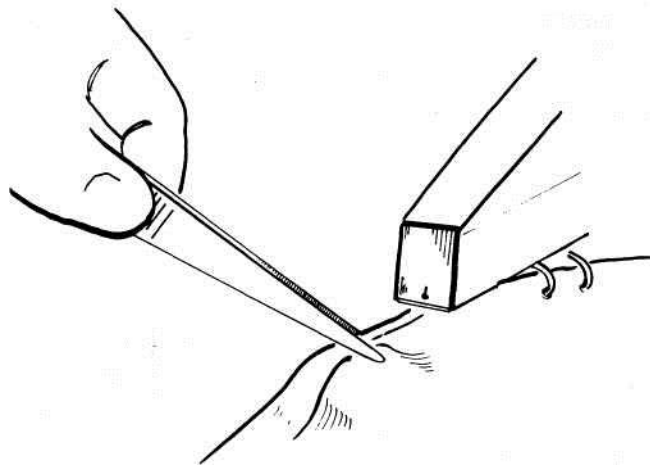


Figure 43. Correct suture removal.

For proper suture removal, the suture line should be cleansed with an antiseptic. The interrupted suture is grasped with fine forceps at the knot, and it is cut on the side opposite the knot at the suture entry point into the skin. Next, the suture is gently pulled out by pulling toward the wound edge (Fig. 43). This will minimize tension away from the wound edge that could possibly cause the wound to dehisce, and no exposed and possibly contaminated suture will pass through the wound. A running suture is removed by cutting it at every other loop and grasping the intervening loop with forceps and pulling it out. This will minimize shearing forces across the wound and contamination of the wound. A running subcuticular suture is removed by cutting the knot at one

end and pulling the suture out slowly from the other end to minimize the risk of suture breakage in the wound.

Absorbable sutures are left in place. However, some patients develop suture reactions consisting of suture abscesses and suture extrusion through the wound. If this happens, the suture should be carefully picked up with small forceps and cut out of the wound. Any purulent material should also be drained.

STAINLESS STEEL STAPLE CLOSURE

Staple closure of wounds is an alternative to suture closure. The staples have the advantage of very quick placement, minimal tissue reaction to the staples, and a very strong wound closure. It is most often used for closure of long wounds, especially on the scalp where the suture line is hidden by scalp hair. Potentially contaminated wounds that are closed with staples appear to be more resistant to infection than wounds closed with sutures.

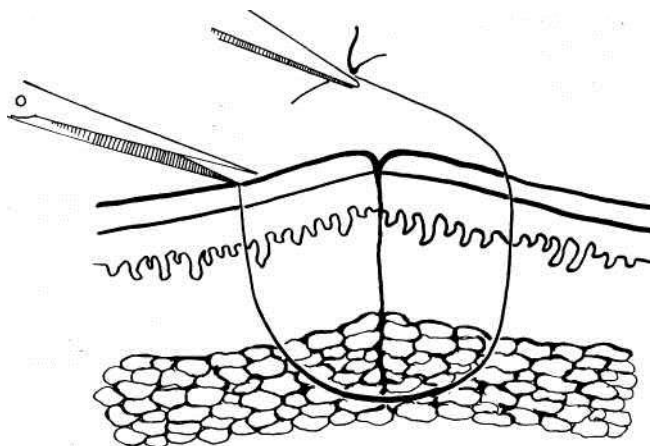


Figure 44. Staple wound closure. Skin edges are everted with forceps, and the staples are placed by squeezing the staple gun while straddling the incision line.

Proper placement of staples requires careful alignment and eversion of wound edges before the staple gun is placed firmly against the skin and discharged (Fig. 44). As the staple closes, it pulls tissue toward the wound edge, closing the wound and everting the wound edges. Staples are removed with a staple remover. If a staple remover is not available, they can be removed with a hemostat. The hemostat is inserted closed under the visible staple and forcefully opened, releasing the staple from the skin. Staples provide efficient wound closure, but when exact wound edge alignment is required sutures should be used instead. Also, surgical staples are far more expensive than suture material.

WOUND CLOSURE TAPES

Wound closure tapes are used to provide additional support to a suture line, especially when a running subcuticular suture has been used. In addition, they are helpful in supporting the wound

edges after the skin sutures have been removed. Wounds closed with wound closure tapes have a lower risk of wound infection than sutured wounds. However, as they fail to achieve adequate wound edge eversion and tension reduction, wound closure tapes are rarely used as primary wound closure materials.

Wound closure tapes are applied after the surface has been prepared by painting with Mastisol or tincture of benzoin to improve adhesion. Many surgeons prefer Mastisol as it provides stronger adhesion, and tincture of benzoin has been associated with allergic contact dermatitis. The tape is applied perpendicularly to the suture line on one side of a wound and pulled toward the opposite side where it is attached to the surface (Fig. 45a). Whether the tapes are placed purely perpendicularly across the wound or in a crisscross pattern is a matter of personal preference, but it is important to use numerous tapes so as to maximize wound support. As the wound closure tapes become dislodged, the patient may be instructed in applying new ones for several weeks after the sutures have been removed. Wound closure tapes are removed by picking up one edge and lifting it off toward the suture line and then picking up the opposite edge and lifting it also toward the suture line until the two loose tape edges meet and the tape is lifted off the skin (Fig. 45b). Removing the wound closure tape all from one side generates undesirable shearing forces on the immature and relatively weak suture line as the tape is pulled off the opposing wound edge away from the suture line.

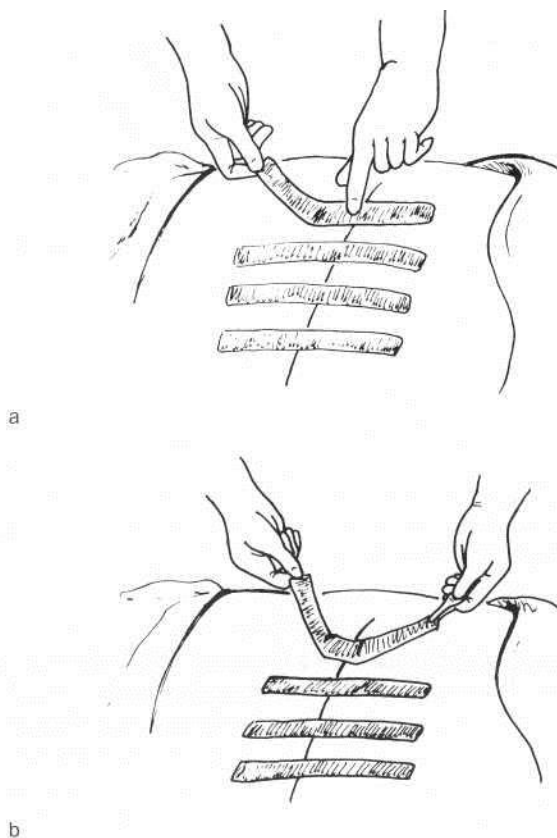


Figure 45. Wound closure tapes. (a) Placement; (b) removal.

Wound closure tapes will rarely provide sufficient support, wound edge alignment, and eversion to replace skin sutures but can be used as an adjunct. Keeping them in place for several weeks may reduce the amount of scar spreading.

FRACTURES OF THE FACIAL SKELETON

ETIOLOGY, SURGICAL ANATOMY AND CLASSIFICATION

The facial skeleton can be roughly divided into three areas: the lower third or mandible, the upper third, which is formed by the frontal bone, and the middle third, an area extending downwards from the frontal bone to the level of the upper teeth or, if the patient is edentulous, the upper alveolus.

Fractures of the middle third area have also been called 'upper jaw fractures' or 'fractures of the maxilla', but in view of the fact that bones adjacent to the upper jaw are almost invariably involved in such injuries, these terms are not strictly accurate. It is better to use the term 'mid-facial'. Fractures of the facial skeleton are but one component of a spectrum of 'maxillofacial injuries' and they are associated with varying degrees of involvement of the overlying soft tissues and such neighboring structures as the eyes, nasal airways, Para nasal sinuses and tongue. They can vary in severity from a simple crack in the upper alveolus to a major disruption of the entire facial skeleton.

Fracture of the mandible worldwide occurs more frequently than any other fracture of the facial skeleton apart from the nose. Fractures of the zygomatic complex are also common and are often associated with facial lacerations. All doctors working in Accident and Emergency departments should therefore be able to recognize these injuries and be familiar with the basic management. Fractures of the lower jaw or alveolus may present to a dental surgeon in his practice or, albeit rarely, be a complication of a difficult tooth extraction. The study of the management of facial bone fractures has therefore a real practical application which is not merely relevant to those studying for higher qualifications or pursuing a career in oral and maxillofacial surgery.

The mandible has a basic structure similar to a long bone with a strong outer cortex and a cancellous centre. In contrast, the bones of the middle third, while presenting a superficial appearance of strength, are in fact comparatively fragile and they fragment and comminute easily. In view of the fact that they articulate and interdigitate in a most complex fashion, it is difficult to fracture one bone without disrupting its neighbours. This gross comminution is difficult to visualize, for mid-facial injuries are usually closed injuries, but in a severe fracture the skeleton may be comminuted into 60 or 70 separate fragments.

Fractures of the facial skeleton may broadly be divided into two main groups:

- 1 . Fractures with no gross comminution of the bone and without significant loss of hard or

soft tissue.

2. Fractures with gross comminution of the bone and with extensive loss of both hard and soft tissue.

The majority of fractures fall into the first category. Those in the second group typically result from missile injuries in war situations, industrial injuries involving machinery or major road accidents where there is direct injury from sharp objects moving at relatively high velocity.

Although arbitrary, this broad division is useful because the general management of the second group is entirely different from the first, both in the primary and in the reconstructive phases.

ETIOLOGY

The contemporary causes of fracture of the facial bones are, in order of frequency: interpersonal violence, sporting injuries, falls, road traffic accidents, and industrial trauma. For 30 years after the Second World War road traffic accidents were found to be the major cause of these injuries, accounting for between 35 and 60 per cent of fractures of the facial bones (Rowe and Killey, 1968; Vincent-Townend and Shepherd, 1994). Perkins and Layton (1988) reviewed the aetiology of maxillofacial injuries in general and emphasized the changes which had occurred during the previous 20 years. More recently this changing pattern of maxillofacial trauma has been reviewed by van Beek and Merckx (1999), who have compared their own longitudinal studies from The Netherlands with similar data from Hamburg and Great Britain. Economically prosperous countries all show a striking reduction in the broad category of road traffic accidents and the increasing influence of interpersonal violence and sports injuries.

The relative importance of the various factors which affect the incidence of facial bone fractures is influenced by:

1. Geography.
2. Social trends.
3. Alcohol and drug abuse.
4. Road traffic legislation.
5. Seasons.

Geography

Van Hoof *et al.* (1977) analyzed the differing patterns of fracture of the facial skeleton in four European countries and observed considerable variation in the experience of the treatment centres from which they collected statistics. Injuries caused by fights were commoner in German urban areas than from a unit in Holland, whereas the latter centre experienced a much higher incidence of road traffic trauma. In developing countries with a rapid increase in road traffic, motor

vehicle-related trauma is still the major cause of fractures (Adekeye, 1980; Zachariades and Papavassiliou 1990). Champion *et al.* (1997) have recently reported that in the USA gunshot trauma now exceeds road traffic injuries in 15 states.

Social trends

In urban areas in more recent years particularly, interpersonal violence has accounted for an increasing proportion of facial bone fractures. Data from a number of centres around the world suggest that interpersonal violence now accounts for more than half of all craniofacial injuries seen in accident departments. In the UK between 1977 and 1987 there was a 47 per cent increase in maxillofacial injuries caused by assault, while during the same period there was a 34 per cent decrease in road accident victims with facial bone fractures. The relative incidence of other facial bone fractures and facial lacerations has been influenced by this trend, and in some urban centres zygomatic fractures have for some years been more common than those of the mandible (Brook and Wood, 1983).

Alcohol and drugs

Alcohol and drug abuse are major factors in the aetiology of traumatic injuries. Maxillofacial injuries are commoner in young men than any other group, and to a large extent this is a reflection of increased alcohol consumption by this section of society (Shepherd, 1994). Alcohol and drugs are also a consistent major factor in maxillofacial injuries related to road users (Bradbury and Robertson, 1993; Nakhgevany *et al.*, 1994). In 1997 the British Association of Oral and Maxillofacial Surgeons carried out the first prospective survey of one nation's facial injuries (Hutchison *et al.*, 1998). During the period of observation (1 week) facial injuries (6114) represented 4 per cent of total injuries presenting in 163 Accident and Emergency Departments. Forty per cent of facial injuries were caused by falls, a large proportion of which were in under-five year olds within the home. Twenty-four per cent of the injuries were caused by interpersonal violence, mainly young adults and related to alcohol consumption in 55 per cent. Only 5 per cent of facial injuries were caused by road traffic accidents (RTAs). The 15 to 25-year age group suffered the greatest number of facial injuries caused by assault and RTA, and had the highest number associated with alcohol consumption.

Road traffic legislation

Vehicle design has been influenced both by research and legislation, and in some countries the use of seat belt restraint has been made compulsory in law. Seat belts have resulted in a dramatic decrease in injury in general, and severe injury in particular (Thomas, 1990), and that trend has been reflected in the incidence of facial injury (Sabey *et al.*, 1977).

Grattan and Hobbs (1985) have reported on the beneficial effects of improved car design and the use of seat belts, although there is some evidence that seat belts are not entirely effective in reducing the incidence of mandibular fractures (Reath *et al.*, 1989). Enforced low speed limits do not appear to carry the same benefit as far as facial fractures are concerned, compared with other types of injury (Olson *et al.*, 1982).

Season

Facial fractures show a seasonal variation in most temperate zones, which reflects the increased traffic and increased urban violence during summer months and adverse road conditions in the presence of snow and ice in midwinter. Sporting injuries also show a marked seasonal variation (Hill *et al.*, 1998).

INCIDENCE

Maxillofacial injuries are not particularly common, but it is difficult to arrive at any accurate estimate of their incidence, for many of the authorities who have reviewed series of such injuries do not state the period over which the cases were collected. Mallett (1950) reviewed 2124 cases of jaw fracture treated at the Boston City Hall Hospital from 1919 to 1948. Harnisch (1959) collected 532 fractures between 1952 and 1957 at the Rudolf Virchow Hospital in Berlin. Lindstrom (1960), of the Department of Dentistry of the University of Finland, reviewed 649 patients seen from 1948 to 1958. Simpson and Maclean (1995) estimate the annual incidence of craniomaxillofacial trauma in New South Wales to be at least 80 per 100 000 population.

Mandibular fractures used to be more common than middle third injuries. In 1966 Schuchardt *et al.* found that the mandible was fractured either alone or in combination in no less than 2103 out of 2901 facial bone injuries. In this series 774 fractures involved the middle third and 156 the middle third and mandible - a total of 930 cases. Oikarinen and Lindqvist (1975) studied 729 patients with multiple injuries sustained in traffic accidents; 11 per cent of the patients had fractures of the facial bones. The most common facial fractures were in the mandible (61%), followed by the maxilla (46%), the zygoma (27%) and the nasal bones (19.5%).

Middle third fractures include both fractures of the zygomatic complex and fractures of the nose, and these two common fractures can have a disproportionate influence in some recorded series. For example, the upsurge of interpersonal violence in urban areas has increased the incidence of zygomatic complex fractures, while nasal fractures are often treated in isolation by departments of otorhinolaryngology. Rowe and Killey (1968) analysed 1500 facial fractures, and in this series 501 involved the middle third and 128 affected both the mandible and the middle third - a total of 629 fractures of the middle third. However, Kelly and Harrigan (1975) analysed 3324 patients

admitted with fractures of the facial skeleton, many of which were multiple. Of the total 4317 fractures, only 594 involved the mid-facial skeleton.

Vincent-Townend and Shepherd (1994) have analysed trends in the pattern of maxillofacial injuries from a number of reported series. Surprisingly in Britain the incidence of middle third fractures compared to mandibular fractures had risen, due entirely to an increase in zygomatic fractures compared to isolated mandibular injuries. Between 60 and 70 per cent of middle third fractures are fractures of the zygomatic complex.

The change in emphasis of the various aetiological factors outlined above is reflected in a reduction in the relative incidence of fractures of the mandible. Brook and Wood (1983) examined this trend over four decades in a retrospective study. During this period personal assaults increased by 75 per cent and fractures of the zygoma became more common than fractures of the mandible, facts which may well be related. Although fracture of the condyle is the commonest site for mandibular fracture, the angle fracture is the most frequent site when only one fracture is present (Halazonetis, 1968; Ellis *et al.*, 1985). Among patients sustaining general injury as a result of personal assault, Shepherd *et al.* (1990) found that 83 per cent of all fractures and 66 per cent of all lacerations were facial. More recently Down *et al.* (1995) carried out a prospective study of 1088 severely traumatized patients. Fifteen per cent of these had sustained maxillofacial injuries, and of this subgroup one-third died at the scene of the accident and another 21 per cent died subsequent to hospital admission. Although the main cause of death was the general severity of the trauma, there was evidence of poor resuscitation in 32 per cent of the patients.

SURGICAL ANATOMY

The surgical anatomy of the facial skeleton and adjacent structures is extremely important in understanding the pattern of fracture, the displacement of the fractured bone fragments and the factors necessary for uncomplicated healing. The traditional division of the facial skeleton into an upper third, middle third, and lower third is only useful when considering the detailed treatment of particular fractures. A fracture of the upper third, for example, may be confined to the skull vault and is only a component of a maxillofacial injury when the bones of the orbit and naso-ethmoidal regions are simultaneously involved. The facial skeleton in relation to the skull as a whole can be usefully reduced to a simple model which is helpful both in understanding the pattern of injury and the principles of treatment.

Viewed from in front the facial skeleton can be compared to a framed picture. The 'frame' is made up of the rigid frontal bone above, two vertical lateral struts made up by the lateral orbital margins and the zygomatic complex, and a lower horizontal mandibular platform, which is of course hinged and mobile. The frame contains a complicated 'picture' made up of the multiple bones of the middle third, the orbital contents, paranasal sinuses and the teeth. The overlying soft tissues,

including the cartilaginous nasal skeleton, complete the composition. The analogy is useful, for if a framed picture is damaged it is logically repaired in a certain order. The frame is first reconstructed, followed by detailed restoration of the contents and finally the protective 'glass' is replaced. Treatment of a maxillofacial injury is accomplished in a similar order, which is represented diagrammatically by the concentric circles in Fig. 46.

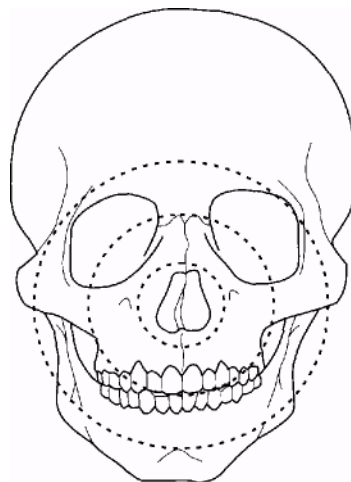


Figure 46. Diagram to illustrate the frame of the facial skeleton. The three concentric circles are used as a guide to the reduction of multiple facial fractures. The bones crossed by the line of the outer circle make up the frame of the face and it is these which are reduced and immobilized first. Those within the middle ring are next repositioned and finally the nasal complex within the inner circle is reconstructed.

The upper facial skeleton

The so-called upper third of the facial skeleton is chiefly the frontal bone making up the superior orbital margin and orbital roof. The base of the skull extends backwards and is angled downwards at approximately 45° where the frontal bone articulates with the sphenoid. The mid-facial complex articulates with this sloping plane and the cribriform plate of the ethmoid extends upwards to make contact with the meninges of the brain and transmit the olfactory nerves. The frontal bone, the body and greater and lesser wings of the sphenoid are not usually fractured. In fact, they are protected to a considerable extent by the cushioning effect achieved as the fracturing force crushes the comparatively weak bones comprising the middle third of the facial skeleton. When fractures of the cranial component of the facial skeleton do occur there are important consequences:

- 1 . The brain may have sustained direct injury.
2. The brain may be at risk from indirect injury secondary to bleeding at the fracture site.
3. A fracture may involve the posterior wall of the frontal sinus, the orbital roof or the cribriform plate, which in turn may be associated with a breach of the dura mater and leakage of cerebrospinal fluid.
4. Displacement, particularly in a caudal direction, will interfere with reduction of the facial bones as a whole.

The mid-facial skeleton

The mid-facial skeleton is defined as an area bounded superiorly by a line drawn across the skull from the frontozygomatic suture across the frontonasal and frontomaxillary sutures to the frontozygomatic suture on the opposite side, and inferiorly by the occlusal plane of the upper teeth, or, if the patient is edentulous, by the upper alveolar ridge. It extends backwards as far as the pterygoid plates of the sphenoid, which are usually involved in any severe fracture.

This area of the facial skeleton is made up of the following bones:

- two maxillae;
- two zygomatic bones;
- two zygomatic processes of the temporal bones;
- two palatine bones;
- two nasal bones;
- two lacrimal bones;
- vomer;
- ethmoid and its attached conchae;
- two inferior conchae;
- pterygoid plates of the sphenoid.

Physical characteristics of the mid-facial skeleton

- 1 . The mid-facial skeleton is made up of a considerable number of bones which are rarely, if ever, fractured in isolation (Fig. 47).
- 2 . The composite structure of this complex of bones is so ordered that it will with stand the forces of mastication from below and provide protection in certain areas for vital structures, notably the eye. If the comparatively thin areas of bone comprising the outer walls of the maxillary sinuses are removed from the maxillae, it will be seen that the mid-facial skeleton consists of a series of bone struts passing upwards from the upper teeth to the bone of the skull. The forces of mastication are thus distributed round the fragile area of the nose and para-nasal sinuses to the base of the skull (Fig. 48).
- 3 . This type of structure is able to withstand considerable force from below but the bones are easily fractured by relatively trivial forces applied from other directions. Nahum (1975) conducted experiments in which fracture of the middle third occurred with forces between one-fifth and one-third of those required to produce simple fracture of the mandible. The facial bones as a whole have a very low tolerance to impact forces. The nasal bones are least resistant, followed by the zygomatic arch, while the maxilla itself is very sensitive to horizontal impacts.
- 4 . Because of the relative fragility of the mid-facial skeleton, it acts as a cushion for trauma directed towards the cranium from an anterior or anterolateral direction. It is analogous to a

'matchbox' sitting below and in front of a hard shell containing the brain, and differs quite markedly from the rigid projection of the mandible below (Fig. 49). These physical differences are extremely important for survival after head injury. An impact directly applied to the cranium may be sufficient to cause severe brain injury or death. This same force applied to the mid-facial skeleton is cushioned sufficiently so that it may not even lead to loss of consciousness, though causing considerable damage to the bones and soft tissue of the face. If, however, the mandible alone withstands the impact, the cushioning effect is reduced and brain injury will result in a manner comparable with a boxer's knockout punch.

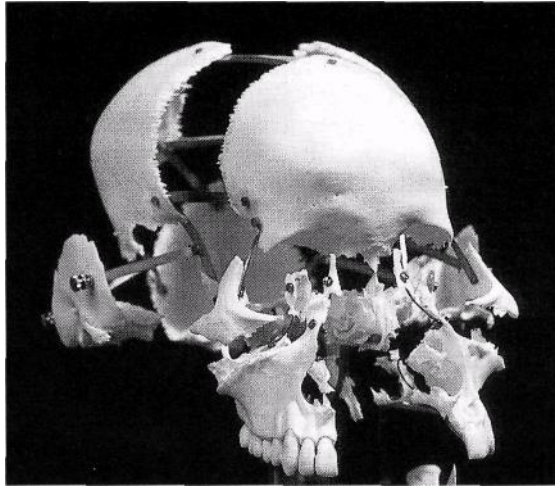


Figure 47. Anatomical specimen showing the disarticulated bones of the skull exploded and mounted to demonstrate their complex interrelationship. Note that the bones of the mid-facial skeleton are all comparatively fragile. They comprise, from above downwards, the ethmoid, flanked by the two lacrimal bones. Next are the paired nasal bones, palatine bones, maxillae and inferior conchae with the zygomatic bone laterally on each side. The vomer is missing. Courtesy of the Anatomical Museum, Royal College of Surgeons of England.

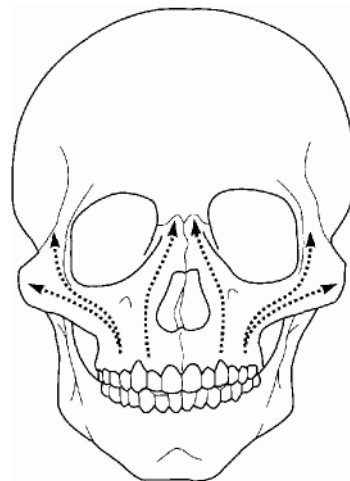


Figure 48. Diagram showing the directions of distribution of the forces of mastication within the skeleton of the mid-face.

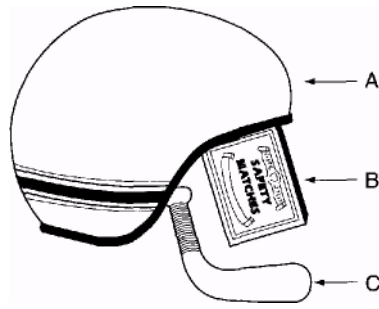


Figure 49. Diagrammatic representation of the strength of the bones of the skull and face. The 'matchbox' structure of the mid-facial skeleton cushions the effect of impact force B. Impact force A is transmitted directly to the brain producing the most severe injury. Impact force C is transmitted indirectly to the cranial base via the rigid structure of the mandible (represented here as a bent baseball).

The articulation with the base of the skull

1. If the bones comprising the mid-facial skeleton are removed from the skull, it will be seen that the frontal bone and body of the sphenoid form an inclined plane which slopes downwards and backwards from the frontal bone at an angle of about 45° to the occlusal plane of the upper teeth (Fig. 50a). The bones of the mid-facial skeleton articulate with these strong foundation bones and when fracture occurs they are crushed or sheared off the cranial base. The amount of backward displacement is usually only slight but because of the steep slope of the base of the skull the posterior teeth of the maxillae contact the posterior mandibular teeth prematurely and produce an anterior open bite (Fig. 50b). Occasionally this displacement is sufficient to cause lengthening of the face, and in extreme cases the soft palate may be pushed down upon the dorsum of the tongue causing embarrassment to the airway. The situation is compounded by swelling of the soft tissues and occlusion of the nares by blood clot. It must be remembered that although physical impairment of the airway is a serious threat to life, a conscious patient will be able to compensate and survive. The real danger to life exists when there is coincident head injury and depression of the level of consciousness. In this situation the patient will rapidly suffocate unless the airway is cleared and maintained by placing the patient in a lateral or prone position. Fractures of the mid-facial skeleton are invariably multiple as far as the individual bones of the face are concerned. The pattern of fracture of these bones is, however, remarkably consistent and follows the lines of weakness within the face described classically by Guerin (1866) and Le Fort (1901). The terms used to describe mid-facial fractures, Le Fort I, II and III, refer to the level of the fracture relative to the skull base, and are derived from these classic papers (see 'Classification' below). Severe trauma can impose considerable comminution of the more superficial bones on the underlying classical Le Fort pattern. The bones of the naso-ethmoidal complex and anterior maxillae are particularly affected and it is this inward crushing which produces the characteristic 'dish-face' deformity rather than total posterior displacement of the whole maxillary complex (Fig. 50c).

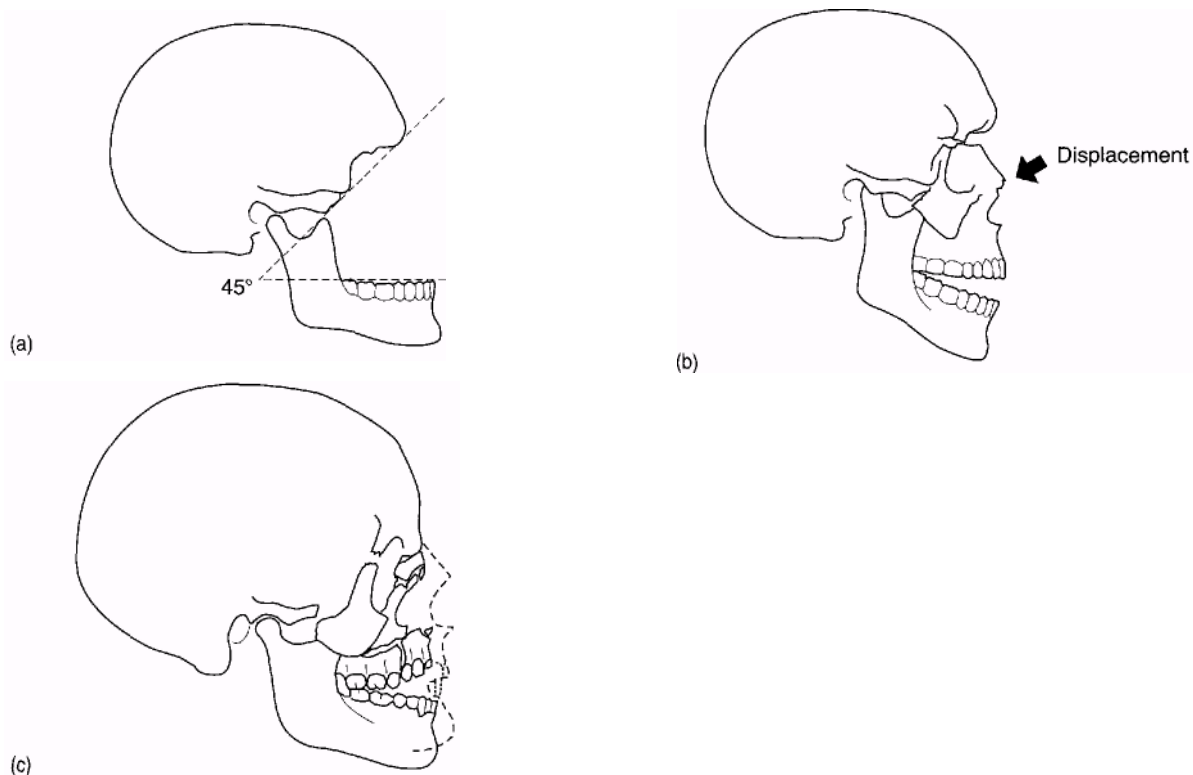


Figure 50. (a) Diagram of the skull and mandible with the mid-facial skeleton removed. The frontal bone and body of the sphenoid form an inclined plane which lies at an angle of about 45° to the occlusal plane, (b) In the Le Fort II and III types of fracture, downward and backward displacement of the bones of the mid-facial skeleton occurs along this inclined plane, resulting in gapping of the posterior teeth. On rare occasions, when extreme displacement of the bones occurs, the oral airway is occluded when the tissues of the soft palate meet the tongue, (c) The soft anteriorly placed complex of bones in the mid-face is frequently comminuted producing a 'dish-face' deformity. This often gives the impression of greater posterior displacement than has actually occurred.

Involvement of the brain and cranial nerves

1. Comminution of the ethmoid occurs with Le Fort II and III fractures and some severe fractures of the nasal complex. This may lead to a dural tear in the region of the cribriform plate of the ethmoid resulting in cerebrospinal rhinorrhoea (Fig. 51). A dural tear may also occur adjacent to fractures involving the posterior wall of the frontal sinus. Cerebrospinal fluid may also escape into the soft tissues via coincident fractures of the orbital roof without appearing in the nasal cavity. More rarely, a profuse cerebrospinal fluid rhinorrhoea occurs as a result of a fracture which passes through the base of the sphenoid, communicating with the sphenoidal sinus and via a crack in the roof of this structure with the middle cranial fossa.

2. Damage to the infra-orbital and zygomatic nerves may occur with zygomatic and Le Fort II fractures either unilaterally or bilaterally. This gives rise to anaesthesia or paraesthesia of the skin of the cheek and upper lip. Full recovery of sensation may be delayed for up to two years. The anterior, middle and posterior superior alveolar nerves are frequently damaged leading to anaesthesia of the upper teeth and gingiva.

3. Cranial nerves within the orbit may sustain damage in zygomatic, Le Fort II and III fractures.

The sixth cranial nerve is most frequently involved but sometimes the contents of the superior orbital fissure are all damaged, in which case ophthalmoplegia, dilation of the pupil and anaesthesia within the distribution of the ophthalmic branch of the fifth cranial nerve are severally noted. Rarely the orbital apex is fractured with resultant damage to the optic nerve and blindness.

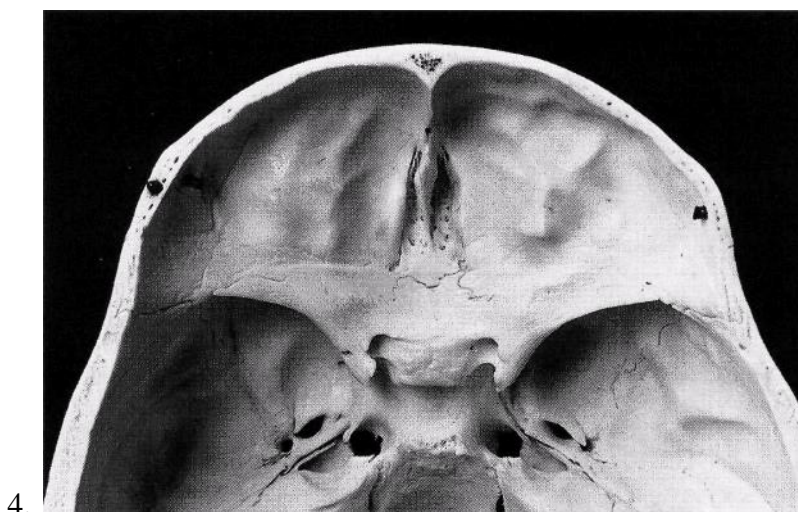


Figure 51. The cribriform plate of the ethmoid. This fragile bone is fractured in Le Fort II and III type fractures and also in severe injuries of the naso-ethmoidal complex.

Involvement of the orbit

1. The globe of the eye and the optic nerve are remarkably well protected by the physical structure and arrangement of the bones of the orbit. The prominence of the zygomatic bone acts as a protection for the globe from all impinging objects other than very small projectiles. The optic foramen is a ring of compact bone and in high level or Le Fort III injuries, fractures almost invariably pass around it. Rupture of the globe or tearing of the optic nerve are fortunately therefore rarely found with other than the most severe middle third fractures.

2. Fractures involving the orbit may give rise to alteration in the position of the globe of the eye. The level of the globe is normally maintained by the suspensory ligament of Lockwood, which passes from its medial attachment on the lacrimal bone to be inserted laterally into Whitnall's tubercle situated on the inner aspect of the zygomatic bone just below the frontozygomatic suture. Zygomatic and Le Fort III fractures commonly result in separation at this suture line with a resulting drop in the level of the globe of the eye.

3. If the bone comprising the floor of the orbit is fractured, orbital contents may herniated through into the maxillary sinus below. The resulting entrapment of these tissues may result in restriction of movement of the inferior rectus and inferior oblique muscles although, anatomically, the muscles themselves are not actually ensnared by fragments of bone. Alternatively, the muscles may become bound down adjacent to the damaged bone by subsequent fibrous tissue formation. In either event, temporary or permanent diplopia results due to prevention of the upward and outward rotation of the eye. The lateral rectus muscle may be partially paralysed by haematoma formation or

sixth nerve neuropraxia adjacent to a fracture line resulting in lateral diplopia. Diplopia results mainly from interference with the activity of the ocular muscles rather than physical displacement of the globe. Extreme displacement of the latter will, however, result in such distortion of the visual axis that the muscles will be unable to compensate and double vision will be inevitable.

4. Orbital contents may also herniate through the thin lamina papyracea of the ethmoid bone on the medial wall of the orbit. Any significant increase in the orbital volume occurring as a result of fracture of the walls of the orbit will lead to enophthalmos. Enophthalmos, particularly if accompanied by inferior displacement of the lateral canthal attachment, may give rise to pseudoptosis, a physical sign traditionally referred to as 'hooding of the eye'.

5. Le Fort II and III fractures and severe nasal complex injuries may involve the naso-lacrimal duct with resulting epiphora. This complication is not noticed at the time of injury, but may become apparent later.

6. Detachment of the medial canthal attachment of the eye may occur in severe naso-ethmoidal injuries, giving rise to traumatic telecanthus.

7. Haemorrhage within the orbit is a frequent occurrence in facial injuries. In the absence of actual damage to the globe of the eye it is not usually significant. However, haemorrhage within the muscle cone of the eye (retrobulbar haemorrhage) can very rarely lead to loss of vision. Ord (1981) conducted a comprehensive review of this complication. It is now thought that blindness occurs as a result of spasm of the short posterior ciliary arteries, causing ischaemia of the optic nerve head over a limited but critical area.

Disturbance of the occlusion

1. As the mid-facial skeleton is pushed down the inclined plane formed by the frontal bone and the body of the sphenoid, the mandible is forced open with bilateral gagging of the molar teeth, and the formation of an anterior open bite.

2. The maxillae may be separated by a split of the bony palate usually, but not always, in the line of the median palatal suture. This injury often results from a blow transmitted upwards via the mandibular teeth. Maxillary alveolar fractures may occur in isolation or as part of a more complex injury.

3. A depression of the body of the zygomatic complex or in-fracture of the zygomatic arch may cause the fractured bones to impinge on the coronoid process of the mandible and so interfere with the normal range of excursion of the lower jaw.

The paranasal sinuses

In zygomatic complex and Le Fort I, II and III fractures, the maxillary sinuses are involved. The thin bony walls of the sinuses are often grossly comminuted with bleeding into the cavity and

not infrequently inward herniation of the buccal pad of fat. This results in one or more of these paranasal sinuses appearing opaque on radiological examination. Apart from the routine reduction and repositioning of the fracture, no other special treatment is required and the radiological appearance of the sinuses will clear after about 6 weeks. Kreidler and Koch (1975) carried out an endo-scopic study of the maxillary sinus after mid-facial fractures in 25 patients and found 35 per cent had chronic mucosal changes, but all were free of symptoms. No similar studies appear to have been carried out to confirm these observations.

Uncommonly, air may escape into the soft tissues of the face following a fracture which extends into one or other paranasal air sinus. This usually affects the flaccid tissues of the eyelids and leads to 'surgical emphysema'. This in turn gives rise to the physical sign of 'crepitation' of the soft tissues when palpated. Whenever air gains entry into soft tissue planes it is contaminated and adds to the risk of subsequent infection. Air within the cranial cavity and meninges or in the mediastinum is particularly dangerous and can rarely occur as a complication of facial trauma.

Important blood vessels

The third part of the maxillary artery and its terminal branches are closely associated with the lines of fracture in Le Fort I, II and III-type injuries. Occasionally the artery or its greater palatine branch is torn in the region of the pterygomaxillary fissure or pterygopalatine canal resulting in severe life-threatening haemorrhage into the nasopharynx. Packing of the nose via the anterior nares, whilst usually sufficing in more minor nasal haemorrhage, will be ineffectual in this event. A post-nasal pack must be inserted, which will apply direct pressure to the bleeding point without embarrassing the airway through the mouth. It is necessary to retain this pack for 24 hours and to replace it if necessary. Such a pack is a potent source of infection and is not well tolerated by the patient. Adequate reduction of the fracture will fortunately prevent further bleeding in most cases.

The mandible

Although the mandible is embryologically a membrane bone its physical structure resembles a bent long bone with two articular cartilages and two nutrient arteries. This arch of cortico-cancellous bone projects down and forwards from the base of the skull and constitutes the strongest and most rigid component of the facial skeleton. It is, however, more commonly fractured than the other bones of the face, a fact directly related to its prominent and exposed situation. Furthermore, unlike the 'matchbox-like' mid-facial skeleton, which readily absorbs direct trauma, blows to the mandible are transmitted directly to the base of the skull through the cranio-mandibular articulation. This in turn means that relatively minor mandibular fractures may be associated with a surprising degree of head injury; hence the effectiveness of the boxer's knockout punch. If there is an

associated head injury, fractures of the mandible may constitute a threat to the airway in the early period after injury. A patient whose level of consciousness is depressed is less able to protect his own airway from the embarrassment of blood, broken teeth and displaced dentures. Furthermore, bleeding into the floor of the mouth and base of the tongue causes swelling, which may threaten to obstruct the oropharynx.

Mandibular fracture sites

The anatomical configuration of the mandible approximates to a rigid semicircular link but with hinge joints at its free ends. Nahum (1975) measured the forces required to produce fractures of the facial bones in a series of cadaver experiments. Fracture of the maxilla occurred with forces as low as 140 lb (65 kg), whereas the lowest tolerance level of the mandible to frontal impact was 425 lb (190 kg), which consistently produced fracture of the condylar neck. Fracture of the neck of the condyle can be regarded as a safety mechanism which protects the patient from the serious consequences of middle cranial fossa fracture. Such a fracture can happen on rare occasions when the condylar head is driven through the glenoid fossa. Nahum observed that a frontal force of 800-900 lb (350-400 kg) was required to produce fracture of the symphysis and both condylar necks. He further demonstrated that the mandible was much more sensitive to lateral than to frontal impacts, and concluded that a frontal impact at the symphysis was substantially cushioned by opening and retrusion of the jaw.

The teeth are most important in determining where fracture occurs. The long canine tooth and the partially-erupted wisdom tooth both represent lines of relative weakness, and unerupted teeth such as premolars are important in the same way. Oikarinen and Malmstrom (1969) analysed 600 mandibular fractures by taking tracings from panoramic tomographs. On analysis it was found that 33.4 per cent of fractures took place in the subcondylar area, 17.4 per cent at the angle, 6.7 per cent were alveolar, 5.4 per cent were in the ramus, 2.9 per cent in the mid-line and 1.3 per cent in the coronoid process, while 33.6 per cent occurred in the body of the mandible, mostly in the canine region.

Analysis of fracture patterns where urban interpersonal violence is the major cause shows a reduced overall incidence in fractures of the condyle and an increase in the frequency of body fractures (Ellis *et al.*, 1985; Busuito *et al.*, 1986). Similarly when the mandible is fractured at a single site only, the angle area seems most vulnerable (Halazonetis, 1968). The implication of these observations seems to be that the lesser direct violence from personal assaults tends to cause fracture at the usual point of impact on one side or other of the body of the mandible. Where the force of impact is greater, as in most road traffic accidents, the larger indirect force transmitted to the condylar region results in an increase in the number of fractures at this site. The alveolar resorption which follows tooth loss weakens the mandible and fracture of the edentulous body will

result from much smaller impact forces. Extreme alveolar resorption can lead to a situation where essentially a pathological fracture takes place. Fractures of this nature in a bone perhaps no thicker than a pencil are notoriously difficult to treat.

The teeth

In contrast to the maxilla, tooth sockets constitute lines of relative weakness in the lower jaw, and the teeth themselves are a potential source of infection of many mandibular fractures. In its physical structure the mandible resembles a long bone, but a long bone which is subjected to a series of compound fractures each time a tooth is extracted. Such an assault on a bone of similar structure such as the femur would lead inevitably to intractable osteomyelitis, whereas in the mandible uneventful healing usually takes place in spite of the wound being bathed in bacteria. The bones of the jaw have developed a special resistance to infection during the course of evolution, the mechanism of which is not really understood.

A fracture of the body of the mandible with a tooth in the fracture line is nevertheless a compound fracture and the tooth, which may have been devitalized, represents a potential source of infection. It is important to take account of this in treating the injury.

Muscle attachments and displacement of fractures

The periosteum is a most important structure in determining the stability or otherwise of a mandibular fracture. The periosteum of the mandible is stout and unyielding and gross displacement of fragments cannot occur if it remains attached to the bone. Periosteum may be stripped from the bone ends by the extremity of the force applied, but frequently it yields to the accumulation of blood seeping from the ruptured cancellous bone. Once the periosteal splint has been removed displacement of the bone ends is free to occur under the influence of the attached muscles.

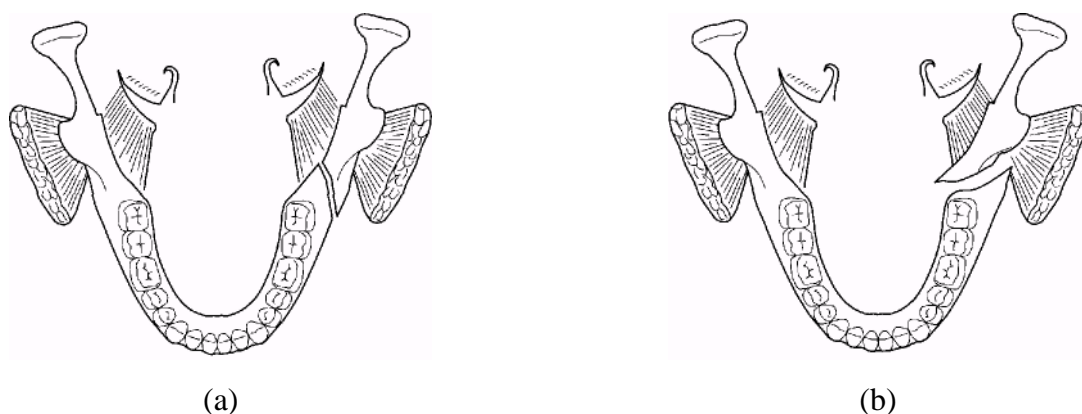


Figure 52. (a) Vertically favourable fracture at the left angle of the mandible, (b) Vertically unfavourable fracture at the left angle of the mandible.

Fractures at the angle of the mandible

Fractures at the angle of the mandible are influenced by the medial pterygoid-masseter 'sling' of which the medial pterygoid is the stronger component. Fractures in this region have been classified as vertically and horizontally favourable or unfavourable (Figs 52 and 53). If the vertical direction of the fracture line favours the unopposed action of the medial pterygoid muscle, the posterior fragment will be pulled lingually. If the horizontal direction of the fracture line favours the unopposed action of the masseter and medial pterygoid muscle in an upward direction, the posterior fragment will be displaced upwards. It must be remembered that vertically and horizontally unfavourable fractures will be undisplaced if the periosteum is undisturbed. The concept is only important wide area. Such a fracture is readily displaced posteriorly under the influence of the genioglossus muscle and to a lesser extent the geniohyoid (Fig. 56). It is often stated that such a fracture removes the attachment of the tongue to the mandible and allows the tongue to fall back and obstruct the oropharynx. This is in fact not the case, as the tongue is still firmly attached to the hyoid bone, which in turn remains connected to the mandible by the posterior parts of the mylohyoid muscle. In addition, the intrinsic muscles of the tongue continue to exert control and the tongue remains forward in the oral cavity. Voluntary tongue control is lost only when the patient's level of consciousness is depressed, and consequently it is only in these circumstances that the detached symphysis constitutes a threat to the airway.




Figure 53. (a) Horizontally favourable fracture at the angle of the mandible, (b) Horizontally unfavourable fracture at the angle of the mandible.

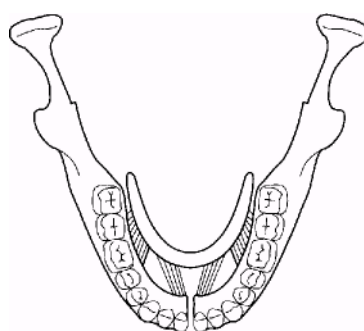


Figure 54. Fracture in the midline of the mandible. Minimal displacement occurs in such injuries as the fracture line passes between the genial tubercles.

Fractures at the symphysis and parasymphysis

In the symphysis region muscle attachments are also important. The mylohyoid muscle constitutes a diaphragm between the hyoid bone and the mylohyoid ridge on the inner aspect of the mandible. In transverse midline fractures of the symphysis the mylohyoid and geniohyoid muscles act as a stabilizing force (Fig. 54). An oblique fracture in this region will tend to overlap under the influence of the geniohyoid/ mylohyoid diaphragm (Fig. 55).

When a bilateral parasymphyseal fracture occurs it usually results from considerable force which disrupts the periosteum over a

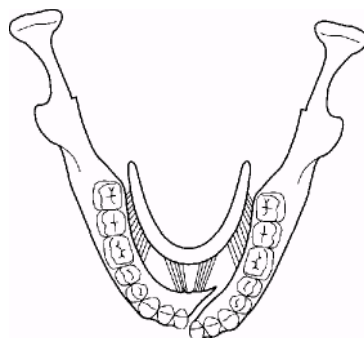


Figure 55. Fracture lateral to the midline in the incisor area. The fragment with the genial tubercles is displaced lingually by the pull of the geniohyoid and mylohyoid muscles.

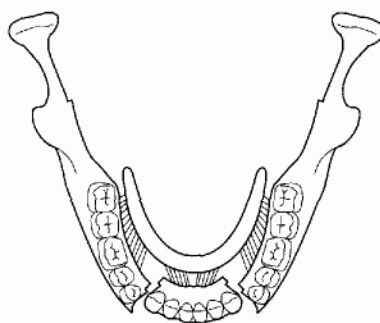


Figure 56. Bilateral fracture of the body of the mandible. The anterior fragment is displaced backwards by the pull of the muscles attached to the genial tubercles

Fractures of the condylar process

When a fracture of the condylar neck occurs the condylar head is frequently displaced and is sometimes displaced from the articular fossa. This is often, but incorrectly, referred to as a fracture dislocation. The craniomandibular articulation is a 'hinge and slide' joint and is not anatomically stable like a 'ball and socket' joint such as the shoulder. A 'dislocation' of the former is more accurately a subluxation which fails to reduce spontaneously because of muscle spasm, a fracture of the condylar neck or both. The most frequent direction of displacement is medially and forward under the influence of the lateral pterygoid muscle. The importance of this muscle as a displacing force is more dramatically illustrated in those cases where anteromedial subluxation occurs some days after injury in a previously undisplaced fracture.

Fracture of the coronoid process

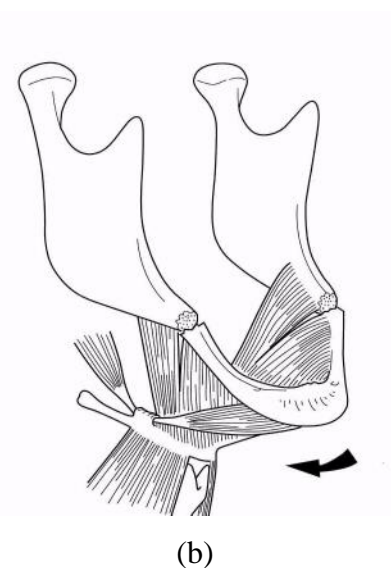
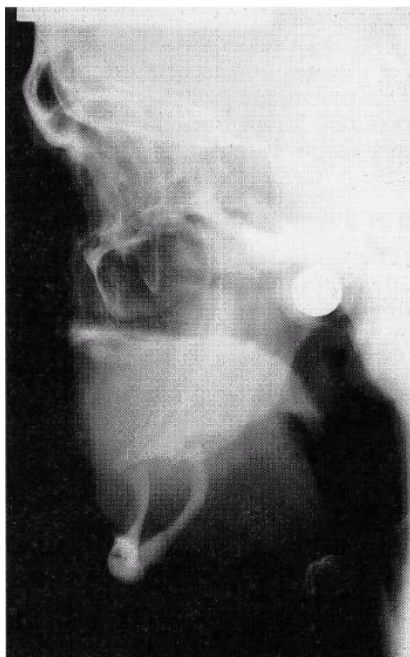
This is a rare fracture which is said to be brought about by reflex muscular contraction of the strong temporalis muscle, which then displaces the fragment upwards towards the infra-temporal fossa.

Comminuted fractures

Extensively comminuted fractures, such as occur following missile injuries, may involve a considerable area of mandibular bone. Where there are strong muscle attachments, as exist over the ramus and angle, the amount of displacement of the comminuted segment is often remarkably little. This is explained by the fragmentation at the site of the muscle attachments. The small fragments are pulled away by the contracting muscle leaving the bulk of the comminuted bone relatively undisplaced.

Fractures of the edentulous mandible

Following alveolar resorption the molar areas of the edentulous mandible become much less resistant to fracture. It is not unusual to see bilateral fractures of the body of the edentulous mandible each occurring near the posterior attachment of the mylohyoid diaphragm. The mylohyoid muscle in the edentulous jaw is attached relatively higher up on the lingual side than when the teeth are present. These factors combine to create a situation whereby extreme downward and backward angulation of the anterior part of the mandible takes place under the influence of the digastric and the mylohyoid muscles. Extreme displacement may lead to respiratory distress, particularly in an elderly patient (Seshul *et al.*, 1978). This 'bucket handle' displacement peculiar to the thin edentulous mandible is illustrated in Fig. 57a,b.



(a)

Figure 57. (a) Lateral radiograph showing a bilateral fracture of a thin edentulous mandible with a severe 'bucket-handle' type of displacement, (b) Diagram illustrating the probable mechanism producing the type of fracture illustrated in (a). The fracture occurs in the resorbed body of the mandible in front of the posterior attachment of the mylohyoid muscle.

Blood supply of the mandible

An effective blood supply is one of the most important factors in the healing of a fractured bone. The mandible receives an endosteal supply via the inferior dental artery and vein, and these vessels are important in young patients. Occasionally a fracture of the body of the mandible will cause a complete rupture of the inferior alveolar artery. Whereas this vessel usually goes into spasm with spontaneous arrest of haemorrhage, this is not always the case and prolific bleeding can occur, which is difficult to control. In these rare emergencies the mandible fracture needs to be reduced immediately by manipulation and the bone ends held in rough alignment by a wire ligature around adjacent teeth.

The other and more important blood supply to the mandible derives from the periosteum. The periosteal supply becomes increasingly important with ageing as the inferior alveolar artery, as visualized on an arteriogram, slowly diminishes in size and eventually disappears (Bradley, 1972). This fact may have considerable significance for the healing of fractures in the elderly. The apparent atrophy of the inferior alveolar artery does not correlate with histo-logical findings in cadavers (Heasman and Adamson 1987; McGregor and McDonald, 1989). It seems, therefore, that the reduction in central blood supply to the edentulous mandible is functional rather than anatomical. Open reduction of fractures in this age group involves elevation of periosteum from the bone ends and further deprivation of blood supply to the fracture site with resultant risk of delayed union or non-union.

Other important anatomical structures related to the mandible

Nerves

The inferior dental nerve is frequently damaged in fractures of the body and angle of the mandible producing anaesthesia or paraesthesia within the distribution of the mental nerve on the side of the injury.

There are numerous reported cases where the facial nerve has been damaged by direct trauma over the mandibular ramus. Facial palsy of the infranuclear type results. In certain instances the mandibular condyle may impact with such force against the temporal bone that a fracture of the temporal bone results, and in these rare circumstances the facial nerve may be damaged within its

bony canal (Goin, 1980). Occasionally the mandibular division of the facial nerve is damaged in isolation in association with a fracture of the body or angle.

Blood vessels

Apart from haemorrhage from the inferior dental vessels, which has been mentioned, injury to major blood vessels is unusual in association with mandibular fractures.

A large sublingual haematoma may result from rupture of dorsal lingual veins medial to an angle fracture.

The facial vessels are vulnerable to direct trauma where they cross the lower border of the mandible anterior to the angle.

Temporomandibular joint

Acute traumatic arthritis can occur without a fracture of the condyle, from indirect transmitted violence. A synovial effusion occurs with widening of the joint space on radiographs. The joint is extremely painful and mandibular movement very restricted.

An intracapsular fracture of the condylar head will frequently cause a haemarthrosis. If this occurs in a young child it can lead to fibrous or bony ankylosis of the temporomandibular articulation and interference with the growth potential of the condyle.

The meniscus is a most important component of the temporomandibular joint. Routine radiographs do not delineate this structure, which can, however, be visualized quite accurately by magnetic resonance imaging (MRI). Nevertheless, knowledge of the incidence of meniscal damage in mandibular trauma remains incomplete. Disruption of the meniscus itself or the meniscal attachments may be important as regards the subsequent function of the joint. There is some evidence that tearing of the meniscus along with haemarthrosis predisposes to later fibrous or bony ankylosis.

Not infrequently a fractured condylar head is driven backwards with sufficient force to tear the adjacent external auditory meatus and cause bleeding from the external ear. Such bleeding must be carefully distinguished from the middle ear bleeding which signifies a fracture of the base of the skull. Very rarely the glenoid fossa is fractured as the mandibular condyle is driven against this thin part of the temporal bone, but usually a fracture of the condylar neck prevents the other more serious injury occurring.

CLASSIFICATION

Fractures of the facial skeleton are broadly classified according to the most commonly observed pattern of injury. Mandibular fractures bear more resemblance to a long bone with the

added complexity of carrying teeth in most instances. The mid-facial skeleton on the other hand is a complex of bones and fractures have been classified in a much more artificial fashion.

Le Fort classification

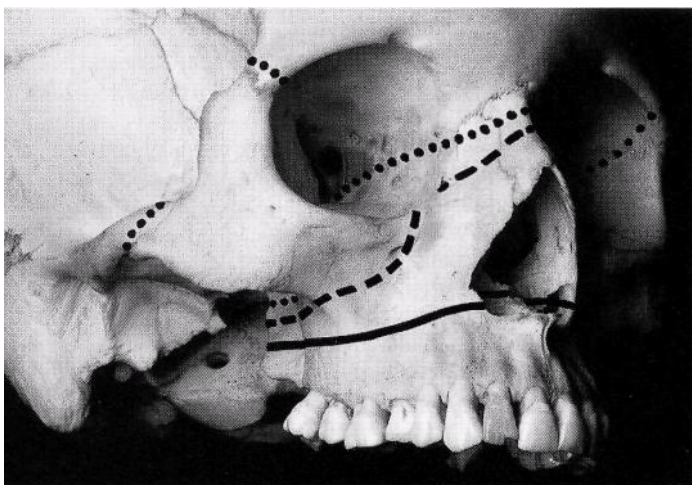
Following experimental trauma to the cadaver head and removal of the soft tissues, Le Fort discovered that the complex fracture patterns produced in this way could be broadly subdivided into three groups (Fig 58a,b).

Le Fort I (low-level fracture)

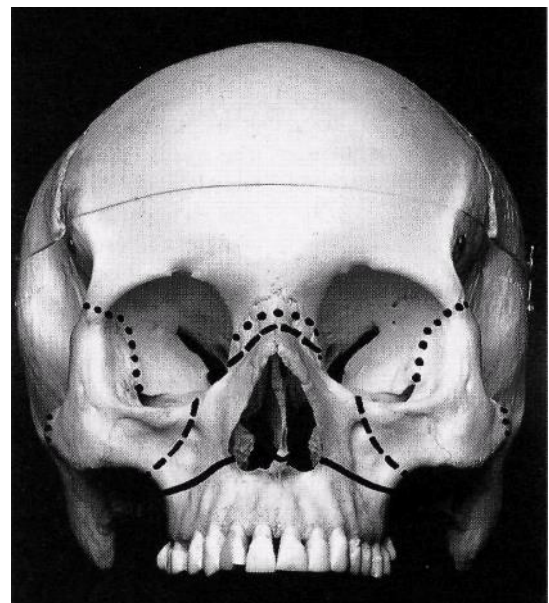
This is a horizontal fracture above the level of the nasal floor. The fracture line extends backwards from the lateral margin of the anterior nasal or piriform aperture below the zygomatic buttress to cross the lower third of the pterygoid laminae. The fracture also passes along the lateral wall of the nose and the lower third of the nasal septum to join the lateral fracture behind the tuberosity.

Le Fort II (pyramidal or subzygomatic fracture)

This fracture runs from the thin middle area of the nasal bones down either side, crossing the frontal processes of the maxillae into the medial wall of each orbit. Within each orbit, the fracture line crosses the lacrimal bone behind the lacrimal sac, before turning forwards to cross the infra-orbital margin slightly medial to or through the infra-orbital foramen. The fracture now extends downwards and backwards across the lateral wall of the antrum below the zygomatico-maxillary suture and divides the pterygoid laminae about halfway up. Separation of the block from the base of the skull is completed via the nasal septum and may involve the floor of the anterior cranial fossa.



(a)



(b)

Figure 58. The Le Fort lines of fracture. *Solid line:* Le Fort I, Guerin, or low-level. *Broken line:* Le Fort II, pyramidal, or infrazygomatic. *Dotted line:* Le Fort III, high-level, or suprazygomatic.

Le Fort III (high transverse or suprazygomatic fracture)

The fracture runs from near the frontonasal suture transversely backwards, parallel with the base of the skull and involves the full depth of the ethmoid bone, including the cribriform plate. Within the orbit, the fracture passes below the optic foramen into the posterior limit of the inferior orbital fissure. From the base of the inferior orbital fissure the fracture line extends in two directions: backwards across the pterygo-maxillary fissure to fracture the roots of the pterygoid laminae and laterally across the lateral wall of the orbit separating the zygomatic bone from the frontal bone. In this way the entire mid-facial skeleton becomes detached from the cranial base.

Other classifications

The Le Fort lines of fracture are most helpful in understanding the major fractures of the central middle third but other fractures and fracture combinations occur. A more exact classification is described by Bowerman (1994), as detailed below.

A. Fractures not involving the occlusion

1. Central region:

a. Fractures of the nasal bones and/or nasal septum.

1) Lateral nasal injuries,

2) Anterior nasal injuries.

b. Fractures of the frontal process of the maxilla.

c. Fractures of types (a) and (b) which extend into the ethmoid bone (naso-ethmoid).

d. Fractures of types (a), (b) and (c) which extend into the frontal bone (fronto-orbito-nasal dislocation).

2. Lateral region:

Fractures involving the zygomatic bone, arch and maxilla (zygomatic complex), excluding the dento-alveolar component.

B. Fractures involving the occlusion

1. Dento-alveolar.

2. Subzygomatic:

a. Le Fort I (low-level or Guerin).

b. Le Fort II (pyramidal).

3. Suprazygomatic:

Le Fort III (high level or craniofacial dysjunction).

Addenda

1. These fractures may occur unilaterally or be associated independently with a fracture of the zygomatic complex.
2. There may be a midline separation of the maxillae and/or extension of the fracture pattern into the frontal or temporal bones.
3. The above classification is comprehensive, but for ordinary practical purposes in discussing signs and symptoms and planning treatment, a simpler classification is adequate and will be used in the ensuing text (Figs 58 and 59):

- 1) Dento-alveolar fractures.
- 2) Zygomatic complex fractures.
- 3) Nasal complex fractures.
- 4) Le Fort I, Guerin, or low-level fractures.
- 5) Le Fort II, pyramidal, or infrazygomatic fractures.
- 6) Le Fort III or suprazygomatic fractures.
- 7) Craniofacial fractures.

It should be remembered that in the more severe injuries several categories of fractures may coexist and the fractures may be unilateral or bilateral.

Mandibular fractures

There is no completely satisfactory classification of mandibular fractures. They may, however, be considered under three main headings:

- 1 . Type of fracture.
2. Site of fracture.
3. Cause of fracture.

Type of fracture.

Simple

These encompass closed linear fractures of the condyle, coronoid, ramus and edentulous body of the mandible. The greenstick fracture is a rare variant of the simple fracture and is found exclusively in children. found exclusively in children.

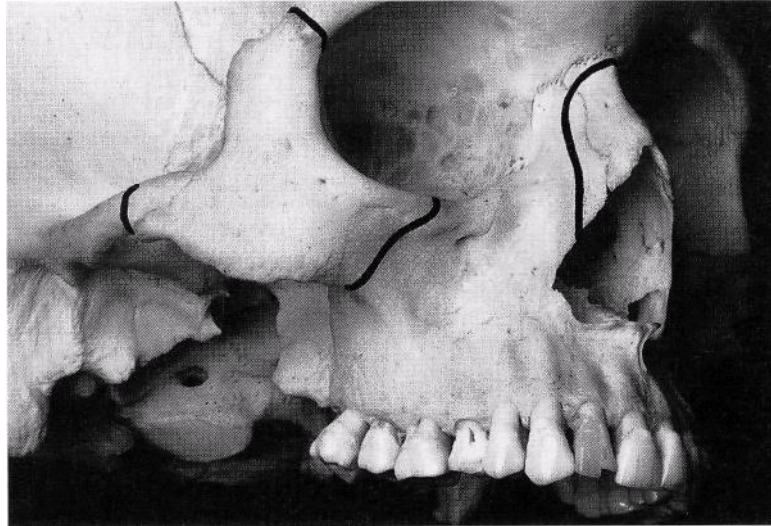


Figure 59. Classification. Nasal complex and zygomatic complex fractures.

Compound

Fractures of the tooth-bearing portions of the mandible are nearly always compound into the mouth via the periodontal membrane, and some severe injuries are compound through the overlying skin.

Pathological

Fractures are termed pathological when they result from minimal traumas to a mandible already weakened by a pathological condition such as osteomyelitis, neoplasms or generalized skeletal disease (Fig. 60).

Comminuted

Direct violence to the mandible from penetrating sharp objects and missiles may cause limited or extensive comminution. Such fractures are usually compound and may be further complicated by bone and soft-tissue loss.

Site of fracture

The most useful classification for practical purposes is based on the anatomical location of the injury, for the signs and symptoms vary according to the site of fracture as does the treatment. Fractures of the mandible occur at the following sites (Fig. 61):

The above represents a useful subdivision for consideration of linear fractures, but whenever there is even limited comminution such a classification becomes relatively meaningless.

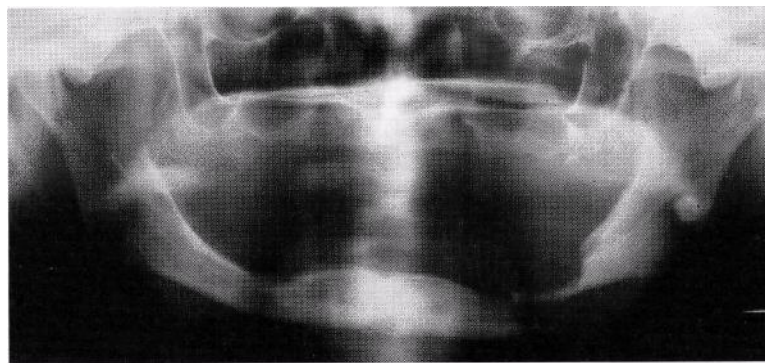


Figure 60. Pathological fracture of the mandible associated with a carcinoma.

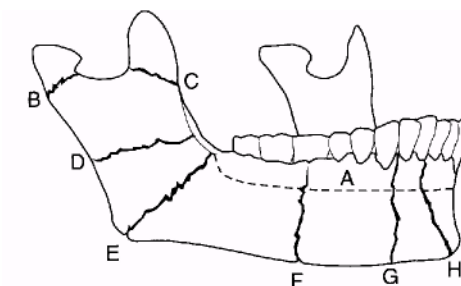


Figure 61. Classification of mandibular fracture sites. A-Dento-alveolar; B-Condylar; C-Coronoid; D-Ramus; E-Angle; F-Body (molar and premolar areas); G-Parasymphysis; H-Symphysis.

Cause of fracture

The direction and type of impact is more important in considering fractures of the mandible than other areas of the facial skeleton as it is the factor which determines the pattern of mandibular injury. Fractures of the mandible result from:

1. Direct violence.
2. Indirect violence.
3. Excessive muscular contraction.

Because of the shape of the mandible any direct violence to one area produces an indirect force of lesser dimension in another usually opposite part of the bone. This latter indirect violence may be sufficient to cause a second or third fracture as a result. From the point of view of treatment the pattern of the mandibular fracture is extremely important and can be considered under the following headings:

1. Unilateral fractures.
2. Bilateral fractures.
3. Multiple fractures.
4. Comminuted fractures.

Unilateral fractures

Unilateral fractures are usually single, but occasionally more than one fracture may be present on one side of the mandible, and if this occurs there is often gross displacement of the fragments. A unilateral fracture of the body of the mandible is most frequently caused by direct violence, but in the case of the weak condylar neck an indirect force may cause fracture while the site of direct impact remains intact.

Bilateral fractures

Bilateral fractures frequently occur from a combination of direct and indirect violence. Common bilateral fractures resulting from such a mechanism are those involving the angle and opposite condylar neck or the canine region and opposite angle. However, every possible combination and variation of the linear fractures already mentioned can occur bilaterally.

Multiple fractures

The same association of direct with indirect violence may give rise to multiple fractures. The most common multiple fracture is that caused by a fall on the mid-point of the chin resulting in fractures of the symphysis and both condyles. These fractures are commonly seen in epileptics, elderly patients who lose consciousness as a result of general disease, and occasionally in soldiers who faint on parade, from which the fracture combination derives its name of 'guardsman's fracture'.

Oikarinen and Malmstrom (1969), in a series of 600 mandibular fractures, found 49.1 per cent were single, 39.9 per cent had two fractures, 9.4 per cent had three fractures, 1.2 per cent had four fractures and 0.4 per cent had more than four fractures.

Comminuted fractures

Comminution of a fracture site is almost invariably the result of considerable direct violence at the site of fracture, as is commonly the case in war missile injuries (Fig. 62). In civilian practice this degree of comminution is most common in the symphysis and parasymphyseal regions. Such fractures require special management and should therefore be considered in a category of their own. It is not unknown for severe missile injuries to cause comminution of the whole of the mandible from one condylar neck to the other.

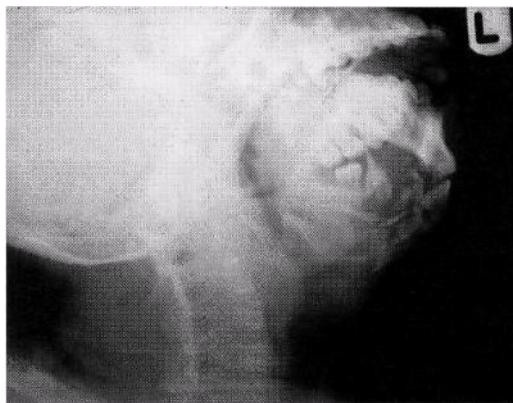


Figure 62. Lateral oblique radiograph showing comminuted fracture of the left body of the mandible following a medium-velocity missile injury

TRAUMA SURVIVAL

Facial injuries are but one component of a spectrum of morbidity and mortality resulting from trauma. World Health Organisation mortality data show that 5 per cent of all deaths worldwide are caused by trauma, and at least 1 per cent of gross national product is consumed in even the poorest countries in the treatment of injuries. The management of a patient with a facial injury has to be seen in the context of the treatment of injuries in general, and the first priority is obviously ensuring survival. The emergency treatment of even the simplest maxillofacial injury involves securing an airway and an assessment of cervical spine and head injuries, all of which are of vital importance in the general management of a patient whose injuries do not necessarily include the face and jaws. It is pertinent therefore to give a brief outline of the modern approach to managing general acute trauma as a preliminary to a more detailed discussion of the immediate treatment of maxillofacial injuries.

Following trauma there are three recognized peaks of mortality. The first occurs within seconds of injury as a result of irreversible brain or major cardiovascular damage. The second peak occurs between a few minutes after injury and about 1 hour later. It is during this 'golden hour' that modern methods of resuscitation have shown dividends in improved survival. A third peak is found some days or weeks after injury as a result of multi-organ failure despite good medical management. In recent years attention has been directed to the second of these peak periods, mainly as a result of a system of Advanced Trauma Life Support (ATLS), originally introduced and widely taught by the American College of Surgeons Committee of Trauma. Their aggressive interventionist approach to trauma management has also reduced mortality in the third group as active resuscitation leads to less late organ failure.

Organization of trauma services

Triage

Triage is a confusing word. It was originally used to describe the process of sorting goods according to quality, but has been adopted into the vocabulary of warfare to describe the classification of

patients according to medical need. In trauma services generally, triage retains its military connotation and is important at three levels:

- field triage;
- inter-hospital triage;
- mass casualty triage.

Triage decisions are crucial in determining individual patient survival and for this reason need to be made at the highest possible level of medical expertise.

Pre-hospital care

Active and appropriate pre-hospital care delivered by fully trained paramedical personnel improves survival during the vital first hour after injury. This means firstly that trained personnel have to arrive at the scene of the accident as rapidly as modern transport permits. They must be trained at the highest level in airway management with cervical spine control, securing intravenous access and initiating fluid resuscitation. Their prime duty is to stabilize the patient prior to rapid transport to a dedicated trauma centre. **Hospital care**

A suitable receiving hospital must have senior medical staff organized as a trauma team. Their first duty is further triage to ensure that medical resources are deployed to maximum overall benefit. Accepted resuscitation procedure is in the following order of priority/

Primary survey

A: Airway and cervical spine control

An unconscious patient involved in a road traffic accident or fall has an approximately 10 per cent chance of having sustained a cervical spine injury. Witness statements, where they are able to describe the exact circumstances of the injury, are very important in assessment. Because of the potential catastrophic consequences of this type of injury the neck should be immobilized in a neutral position by a semirigid collar until damage has been excluded.

Early verbal response to a simple question 'Are you all right?' signifies not only that a satisfactory airway is present but also that cerebral function and by implication breathing and ventilation and circulation are adequate. The several techniques available to secure an unobstructed airway are integral to the management of all maxillofacial trauma whatever the degree of severity and are described in detail later.

B: Breathing and ventilation

An adequate airway is an obvious prerequisite for ventilation. Serious chest injuries such as pneumothorax, haemopneumothorax, flail segments and rupture of the diaphragm prevent adequate ventilation and must be recognized early. Cardiac tamponade, which may also accompany serious chest injury, affects cardiac output rather than ventilation. Key signs alone or in combination are:

- deviated trachea
- absence of breath sounds

- dullness to percussion
- paradoxical movements
- hyper-resonance with a large pneumothorax
- muffled heart sounds.

A chest radiograph is essential and will demonstrate where present:

loss of lung markings deviation of the trachea raised hemi-diaphragm fluid levels fracture of ribs.

Emergency treatment will in the majority of cases require chest drainage. Open 'sucking' chest wounds are occluded by a sterile pad and unstable 'flail chest' injuries are managed by endotracheal intubation and intermittent positive-pressure ventilation. Needle decompression of the pericardium relieves cardiac tamponade.

Gastric dilation is a consequence of poly-trauma and constitutes an impediment to respiration and a risk to the airway if vomiting occurs. A wide-bore nasogastric tube is used to decompress and aspirate stomach contents.

C: Circulation

Circulatory deficiency leads to low blood pressure, increasing pulse rate and diminished capillary filling at the periphery.

Fluids for resuscitation

- Adequate venous access at two points is essential.
- Hypotension should always be assumed to be due to hypovolaemia.
- Resuscitation fluid can be crystalloid, colloid or blood.
- Recognizable surgical shock will require a blood transfusion, preferably with cross-matched blood or in emergency Group O negative.
- Urine output must be monitored as an indicator of cardiac output.

D: Neurological deficit

A rapid assessment of neurological disability is made by noting the patient's response on a four point scale:

- Responds Appropriately, is Aware
- Responds to Verbal stimuli
- Responds to Painful stimuli
- Does not respond, Unconscious

In the absence of direct damage to the eye, pupil response must be recorded.

E: Exposure

All trauma patients must be fully exposed, if necessary by cutting away clothing, and the environment accordingly must be warm and protected to ensure the patient suffers no further harm.

At some point, unless indicated earlier, the patient must be turned in order that the back and other hidden areas can be properly examined.

Secondary survey

At some point after successful resuscitation of an injured patient a period of stability will be reached when the airway is secure with adequate circulation and vital tissue perfusion maintained. At this point a secondary and detailed survey of the whole body is carried out and repeated at regular intervals until the patient is fully stabilized. The objectives of the secondary survey are:

- accurate diagnosis of injuries;
- maintenance of a stable state;
- determining priorities in treatment;
- appropriate specialist referral.

The assessment of maxillofacial injuries will be part of the secondary survey although a maxillofacial surgeon may have become involved at an earlier stage if the airway has been compromised by direct facial trauma. The most important features of the secondary survey are a full assessment of:

- head injury;
- abdominal injury;
- injury to the extremities.

MANAGEMENT OF FACIAL INJURIES

The preliminary management of a patient with facial injuries is part of the general assessment of the patient after trauma. However, the majority of fractures of the facial bones encountered in civilian practice are relatively simple and not associated with other more serious injury elsewhere in the body. It is unusual for such patients to suffer excessive local haemorrhage, and evidence of acute circulatory collapse is itself indicative of damage to other important structures. Even uncomplicated trauma to the mandible does, however, frequently cause concussion from transmitted violence to the base of the skull.

In the period immediately following the accident, no treatment of the facial fracture is required unless it has a direct bearing upon the patency of the patient's airway or the control of haemorrhage. The definitive reduction and fixation of the facial fracture is never a life-saving measure, and the immediate treatment should be directed to the patient's general medical condition.

Even though most patients with maxillofacial injuries have not sustained polytrauma, their local injury may nevertheless in some circumstances constitute a threat to life. Management of maxillofacial injuries therefore takes place in three stages:

1. Immediate assessment and treatment of any life-threatening specific injury.
2. General clinical examination of the patient.
3. Local examination of facial bone fractures.

Immediate treatment

The airway

Obstruction of the patient's airway will lead rapidly to asphyxia and death and it is therefore the clinician's first concern. The most important factor controlling the patency of the airway in a patient with facial injuries is the level of consciousness. A fully conscious patient is able to maintain an adequate airway in the presence of severe disruption of the facial skeleton, whereas a semiconscious or unconscious patient will rapidly suffocate from the presence of blood and mucus in the airway, because of inability to cough or adopt a posture which allows the tongue and soft plate to be held forwards away from the posterior pharyngeal wall. Relatively minor injuries which cause intra-oral bleeding and fracture of teeth or dentures can lead to airway obstruction in an unconscious or semiconscious patient. Accordingly, the most important measures required are the clearing of blood and mucus from the mouth and nasopharynx and the placing of the head in such a position that further bleeding and secretions can escape from the nose and oral cavity. In most cases this can be achieved by placing an unconscious patient on his side in the position used routinely during recovery from a general anaesthetic. A fully orientated patient with facial bone injuries will frequently want to sit up with the face held forwards; in such a patient this posture should be encouraged and maintained by adequate support.

Contrary to popular belief it is rare for the upper jaw to be pushed significantly downwards and backwards along the inclined plane of the base of the skull as a result of injury. Indentation or 'dishing' of the face results mainly from comminution of the thin bones of the anterior facial skeleton following severe impact. In such an event there is considerable bleeding from the nose and nasopharynx and the attendant degree of head injury may be quite serious. It is a combination of these factors which threatens to asphyxiate the patient rather than physical obstruction from displacement of the facial skeleton as a whole. In Le Fort II and III fractures and with severe injuries to the nasal complex the nares are blocked with blood clot or are bleeding profusely. It may be necessary to arrest nasal haemorrhage by anterior or posterior nasal packing causing complete occlusion.

The airway should in the first instance be secured by clearing the mouth and oropharynx. A careful examination should be made in case dentures or portions of dentures are still in situ, and these should be removed together with avulsed, loose or broken teeth, which are so mobile that there is a risk of their being inhaled. Blood and mucus should be cleared using a wide-bore blunt-ended pharyngeal sucker. If the symphysis region is fractured in a patient who has lost voluntary control of the intrinsic musculature, and particularly if it is comminuted, there is some danger of the tongue falling back and obstructing the airway. Occasionally a suture passed through the dorsum of the tongue may assist in controlling its position.

Artificial airways are not well tolerated other than by unconscious patients, owing to the stimulus they invoke from contact with the posterior one-third of the tongue and soft palate. The immediate management of patients with Le Fort II and III fractures is facilitated by use of a nasopharyngeal airway. The nares should be carefully cleared of blood clot and the nasopharyngeal tube placed in position.

Nasopharyngeal tubes should, where possible, be inserted by an experienced operator as it may be difficult to direct the tube into the correct position in the presence of a fractured distorted nasal skeleton. It is still imperative that the patency of the tube is maintained by periodic aspiration using a plastic disposable suction catheter of 8 or 10 French gauge attached to the end of the suction apparatus. These flexible disposable sucker ends are invaluable for keeping the pharynx clear in facial injuries. They can be inserted either through a nasopharyngeal tube or via the mouth even in the presence of intermaxillary fixation.

Continuous supervision of the patient is necessary at this stage either by the operator or by an experienced member of the paramedical staff. The patient's lips should be liberally coated with sterile petroleum jelly to prevent them adhering together with blood clot, and so interfering with respiration. This simple measure should be continued throughout treatment because it does much to ensure the comfort of the patient as well as facilitating oral respiration.

Endotracheal intubation

The simple measures outlined above are sufficient to ensure a patent airway in most patients with fractures of the facial skeleton. The problems of airway maintenance are increased considerably in the unconscious patient, particularly if the facial bone fractures are extensive and involve both jaws. In this situation the rapid passage of an endo-tracheal tube is by far the most effective way of clearing and preserving the airway. Endotracheal intubation is usually required in patients with multiple injuries, particularly of the head, face and chest. Such patients are often unconscious on admission. Occasionally intubation is needed after extensive soft-tissue destruction by a high-velocity missile such as occurs in war. Rather than carry out a tracheostomy it is, in general, preferable to pass an endotracheal tube in the first instance. In a modern intensive care unit a seriously injured patient can be artificially ventilated and monitored for an indefinite period during recovery from head and other injuries additional to the facial trauma. A tracheostomy or cricothyroidotomy is performed if the level of consciousness remains depressed and the maxillofacial injuries require active treatment, or there are chest injuries or infection.

In contrast when there are extensive soft-tissue lacerations, particularly after missile injury, these require urgent attention as local blood loss can be considerable. Obvious bleeding points such as the facial vessels should be secured with artery forceps, ligated if possible, and a temporary dressing applied. Occasionally brisk and persistent haemorrhage originates from a grossly displaced fracture of the body of the mandible. This can only be controlled by manual reduction of the fracture and temporary partial immobilization by means of a suture or wire ligature passed around teeth on each side of the fracture line.

Epistaxis of some degree is an inevitable consequence of injury to the central mid-face. It usually stops spontaneously or is easily controlled by packing the nose via the anterior nares. Profuse haemorrhage into the nasopharynx from terminal branches of the maxillary artery occurs on very rare occasions in association with a Le Fort I, II or III fracture. This may be life threatening both from the point of view of actual blood loss and also obstruction of the airway. A postnasal pack is needed in this situation as a matter of extreme urgency (Fig. 63).

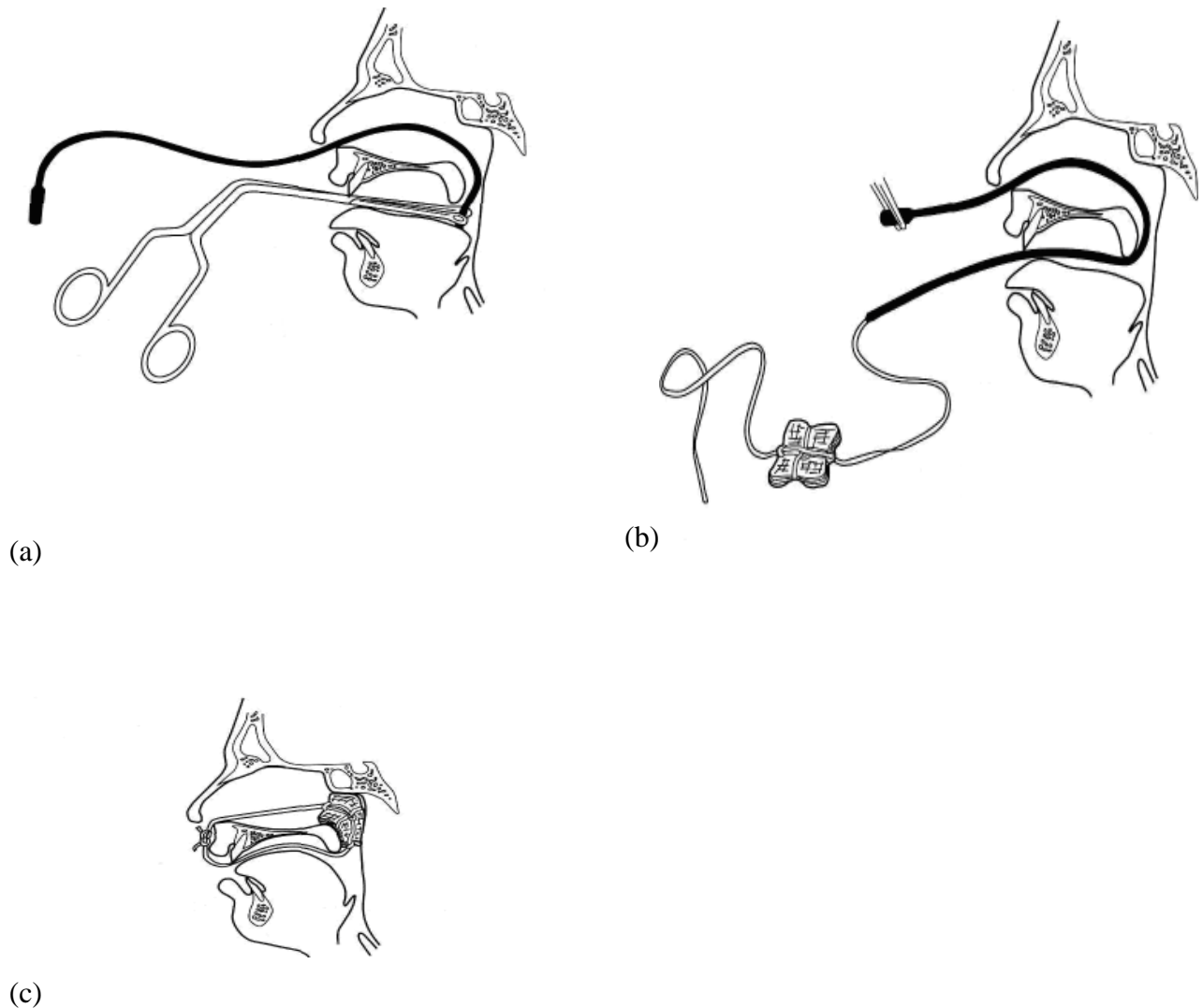


Figure 63. Method of insertion of a postnasal pack, (a) A flexible aspiration catheter 3 mm in diameter is passed via one nasal aperture and retrieved with Magill forceps from the oropharynx whence it is led out through the mouth, (b) A pack of about 4 cm in diameter is made from folded gauze swabs and this is tied like a parcel with tape. Two long ends are left, one of which is passed into the end of the catheter which is then withdrawn back through the nose, (c) The pack is pushed up behind the soft palate and the two ends of the tape secured together firmly below the anterior nares.

Preliminary examination and determination of priorities

After the operator has established a satisfactory airway and controlled haemorrhage, a secondary survey of the patient will be carried out as outlined in the introduction to this chapter. The definitive treatment of a facial bone fracture is hardly ever an urgent procedure and the purpose of this preliminary general examination is to establish the presence or otherwise of other more important injuries.

Fractures of the facial bones are, of course, caused by trauma of varying degrees of severity and it is reasonable to consider the possibility that this degree of trauma may also have caused injury elsewhere in the body. This is especially true if the patient has been involved in a major road traffic accident or a fall from a considerable height. However, a simple blow on the lower jaw as a

result of a fight or during the course of some game may result in force being transmitted to the cranium which results in serious injury or even death of the patient. The mere fact that a patient is ambulant and apparently unaffected by the injury does not necessarily preclude the presence of more serious underlying damage.

Killey (1974) described a patient who sustained a simple crack fracture at the angle of the mandible during a game of rugby football.

The blow was not sufficient to cause loss of consciousness at the time of the injury and the patient was ambulant when first seen and apparently in good health. Shortly after admission, however, he exhibited signs of cerebral haemorrhage, and in spite of neurosurgical intervention, died the following day from a sub-arachnoid haemorrhage. Similar examples can be quoted from the statistics of fatalities following amateur and professional boxing injuries. It is imperative, therefore, that all traumatic cases should have a careful physical examination and no operative procedure should be carried out to treat a fracture until the operator is certain that the patient has not sustained an additional and more serious injury. Treatment of such an associated condition should, of course, take precedence over the mandibular fracture, but occasionally it may be treated concurrently. It should be remembered that elderly patients may fall and injure their face as a result of a cerebral or cardiac event, and this possibility must always be considered in such cases. Fortunately, most major injuries are fairly obvious and careful inspection and gentle palpation of the unclothed body in a good light will usually reveal their presence.

In the presence of facial injuries, in addition to the systematic examination of the patient which takes place as part of the secondary survey, particular attention must be paid to eye injuries and facial lacerations.

Soft-tissue lacerations

The most common priority for patients with fractures of the facial skeleton is the repair of associated soft-tissue lacerations. Ideally these should be sutured before too much oedema has occurred, i.e. within 8 hours of injury. Delay beyond 24 hours can certainly adversely affect outcome. Simple lacerations can be dealt with under local analgesia. Extensive soft-tissue damage to the face requires a general anaesthetic for accurate repair and it is important the operator does not get carried away by the desire to produce a perfect cosmetic result to the detriment of the patient as a whole. If there is any doubt about the general condition of the patient the facial lacerations should be cleaned and closed as rapidly as possible, bearing in mind that the underlying fractures can be treated at a later date and scars eventually revised if necessary.

1. Medication:

If possible all current medication should be recorded. Information as to whether the patient was being treated with insulin, steroids or anticoagulants prior to the accident is particularly important.

2. Consumption of food or drink:

Recent alcohol consumption and a history of recent food intake should be obtained from either the patient or accompanying persons.

A detailed history is obtained when the patient can talk more comfortably.

HISTORY AND LOCAL EXAMINATION

History of the injury and description of the patient's symptoms

If the patient is unconscious or confused, any relevant facts concerning the accident and the subsequent management of the patient must be obtained from eye-witnesses, ambulance persons, or medical and dental practitioners who may have attended the patient following the injury.

If the patient is conscious and co-operative a history can be obtained, but as patients with facial injuries may experience some difficulty in talking owing to the discomfort and mobility of the fractures the interrogation should be brief at this stage:

1. Loss of consciousness:

It is essential to ask if loss of consciousness has occurred and, in that event, whether the patient can remember up to the moment of the accident or whether there is a memory gap. Pre-traumatic or anterograde amnesia is failure to remember up to the time of injury and post-traumatic or retrograde amnesia is loss of memory following the accident - both are indicative of cerebral damage.

2. Symptoms:

It is also important to enquire whether the patient has any difficulty in breathing or swallowing and whether he or she has a headache or pain elsewhere in the body.

Local clinical examination of the facial injury

The examination of a patient with a recent severe injury to the facial skeleton will be greatly facilitated if the patient's face is gently washed with warm water and cotton-wool swabs to remove caked blood. The congealed blood in the palate and buccal sulcus can be removed with cotton wool held in non-toothed forceps. Sometimes cotton-wool swabs dipped in hydrogen peroxide will facilitate the removal of any particularly tenacious clots in the mouth and upon the teeth. If a denture is fractured, the fragments should be assembled to make sure that no portion is missing - possibly displaced down the throat. Only after careful cleaning has been carried out, both extra-orally and intra-orally, is it possible to evaluate the full extent of the injury. It is surprising how often the magnitude of the surgical problem diminishes as the overlying blood is removed and accurate visualization becomes possible.

External examination

The operator should take careful note of oedema, ecchymosis and soft-tissue lacerations. Any obvious bony deformities, haemorrhage or cerebrospinal fluid leak should be recorded. Many of the physical signs of a fractured bone result from the extravasation of blood from the damaged bone ends. This results in rapid early swelling from the accumulation of blood within the tissues and subsequent even greater swelling resulting from increased capillary permeability and oedema. Swelling and ecchy-mosis often indicate the site of individual fractures, particularly of the mandible or zygoma. There may be obvious deformity in the bony contour of the mandible, and if considerable displacement has occurred the patient is unable to close the anterior teeth together and the mouth hangs open. A conscious patient may seek to support the lower jaw with his hand. Many fractures are compound into the mouth and blood-stained saliva is frequently observed dribbling from the corners of the mouth, particularly if the fracture is recent.

The eyelids are gently separated and, if the patient is conscious, visual acuity is tested in each eye. The patient is asked to follow the clinician's finger with his or her eyes and to report if diplopia occurs. A note is made of any alteration in the size of the two pupils, and the light reflex is tested. The extent of any sub-conjunctival ecchymosis is recorded.

Gentle palpation should begin at the back of the head, and the cranium should be explored for wounds and bony injuries. The fingers should then be run lightly over the zygomatic bones and arch, and around the rim of the orbits. Areas of tenderness, step deformities, and unnatural mobility are noted. The nasal complex is next examined in the same manner.

Palpation should continue bilaterally in the condylar region and continue downwards and along the lower border of the mandible. Bone tenderness is almost pathognomonic of a fracture, even an undisplaced crack, but if there is more displacement it may be possible to palpate deformity or elicit bony crepitus.

Areas of loss of skin sensation should be noted. The infra-orbital nerve is frequently contused when the zygomatic complex has been fractured producing anaesthesia or paraesthesia of the cheek, lateral aspect of the nose, and half of the upper lip. Fractures of the body of the mandible are often associated with injury to the inferior dental nerve, in which case there will be reduced or absent sensation on one or both sides of the lower lip.

Intra-oral examination

It is impossible to assess intra-oral damage if the parts are obscured by blood. Conscious co-operative patients may be given a lukewarm mouthwash but in most cases the clinician will have to remove the clotted blood by gently cleaning the whole area with moistened swabs. Congealed blood and any fragments of teeth, alveolus or dentures are removed carefully by forceps, assisted by gentle suction if available.

A good light is essential. The buccal and lingual sulci are examined for ecchymosis. Submucosal extravasation of blood is often indicative of underlying fracture, particularly on the lingual side (Fig. 64).

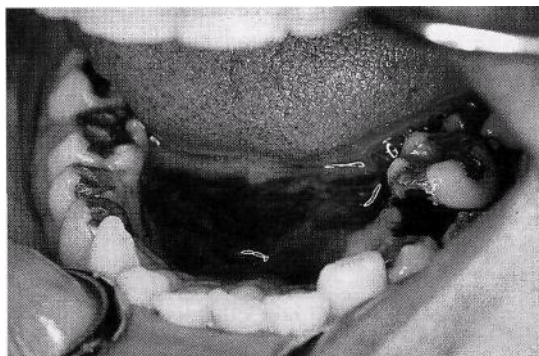


Figure 64. Haematoma in floor of mouth as a result of a mandibular fracture.

Ecchymosis in the buccal sulcus is not necessarily the result of a fracture as there is considerable soft tissue overlying the bone in this area and extensive bruising may follow a blow insufficient to cause a fracture. However, on the lingual side the mucosa of the floor of the mouth overlies the periosteum of the mandible which, if breached following a fracture, will invariably be the cause of any leakage of blood into the lingual submucosa. This then is a most valuable sign of bony injury in the body of the mandible.

Small linear haematomas, particularly in the third molar region, are reliable indicators of adjacent fracture. The mucosa overlying the root of the zygoma should be carefully examined as fractures of the zygomatic complex and Le Fort I fractures frequently produce a haematoma in this area. A haematoma in the palate is a reliable sign of a bony split associated with a fracture of the mid-face.

The occlusion of the teeth is next examined or, if the patient is edentulous, the alveolar ridge. Premature contact of the posterior teeth with a resultant anterior open bite will be obvious. Step defects in the occlusion or alveolus are noted along with any obvious lacerations of the overlying mucosa. It is important to examine all the individual teeth and to note any luxation or subluxation along with missing crowns, bridges or fillings. Individually fractured teeth must be assessed for involvement of the dentine or pulp. Finally, all teeth should be carefully examined with a mirror and probe to detect loose fillings, fine cracks or splits in the tooth substance. If teeth, portions of teeth, dentures, fillings, etc. are not accounted for, a radiograph of the chest must be ordered in case they have been inhaled.

Possible fracture sites in the mandible are gently tested by placing a finger and thumb on each side and using pressure to elicit unnatural mobility. If the patient can co-operate, he or she is asked to carry out a full range of man-dibular movements and any pain or limitation of movement recorded. Occasionally, even this detailed examination fails to confirm a man-dibular fracture

which is thought to be present from the history and presence of haematoma. In such cases the flat of both hands should be placed over the two angles of the mandible and gentle pressure exerted. This manoeuvre will always elicit pain when even a crack fracture is present, but the procedure should be one of last resort as it produces extreme discomfort if a mobile fracture is present.

In the upper jaw the tooth-bearing segment is gently manipulated to elicit unnatural mobility. A finger and thumb are then placed over the frontonasal suture line and any mobility of the facial skeleton tested by pressure from the fingers in the palate. A false impression of mobility of the mid-facial skeleton can be obtained, especially in the unconscious patient, by pressure in the palate alone, for the upper part of the head moves inside the epicranial aponeurosis producing the illusion of movement of the mid-facial skeleton. If the dento-alveolar segment moves independently of the remainder of the mid-facial skeleton, particularly if crepitus is elicited, it is indicative of a Le Fort I type fracture. The upper teeth should be tapped with the handle of a dental mirror. A characteristic 'cracked-pot' sound is elicited if there is a fracture above the teeth.

Control of pain

There is surprisingly little pain from maxillo-facial injuries but when present it is important to give adequate analgesia. It is, however, extremely important to avoid giving powerful analgesics, which depress the level of consciousness and respiration. The risk of respiratory obstruction is increased when drugs such as morphine and its derivatives are given to a patient with injuries of the maxillofacial region. Morphine also depresses the cough reflex and so encourages the aspiration of blood into the trachea. In addition it causes constriction of the pupil, which may mask an early sign of rise in intracranial pressure. It is, however, most important to minimize discomfort in the early stages after injury, as a patient is readily exhausted by efforts both to keep his airway clear and to obtain nourishment. Diclofenac, which can be administered rectally, is well tolerated and useful in maxillofacial trauma. Local toilet, support of mobile fractures, posture, availability of suction and administration of intravenous fluids are all of great importance in the early care of the patient.

The majority of patients with mandibular fractures do not appear to suffer much pain, perhaps owing to the frequently associated neuro-praxia of the inferior dental nerve. Some mobile fractures of the body of the mandible are, however, extremely uncomfortable and a potent cause of restlessness in a cerebrally irritated patient. This situation is one of the rare indications for giving priority to immobilization of the mandible in the presence of other serious injury.

Cerebral irritation is often considerable in patients with severe facial bone fractures as a consequence of associated head injury. They may be disorientated and intolerant of interference. In the past there was much debate about how such patients might be safely sedated in order to complete a detailed examination and take appropriate radiographs and impressions. Advances in anaesthesia and intensive care have made these considerations obsolete. It is important first and

foremost to find out why the patient is disorientated, which means that after the baseline neurological status has been recorded the patient will need a CT scan. 'Sedation' is now achieved by intubation, anaesthesia and artificial ventilation, which in turn allows detailed examination of the facial region to be completed and CT or MRI scans to be carried out.

Control of infection

All fractures of the body of the mandible involving teeth are compound into the mouth and therefore a potential source of infection. Fractures of the central mid-face are compound into the mouth, nose and paranasal sinuses. In addition, Le Fort II and III fractures are often associated with damage to the dura mater, cerebrospinal fluid rhinorrhoea and the risk of meningitis. It is widely accepted that prophylactic antibiotics should be administered in the form of a broad-spectrum penicillin, usually amoxicillin, together with metronidazole. This regime takes account of the importance of anaerobic bacteria in infections caused by contamination with mouth organisms. Both antibiotics may be administered parenterally but also achieve good blood levels when given by mouth. Although penicillin does not pass into the cerebrospinal fluid in adequate therapeutic concentrations, this is no longer considered to be important in the prevention of meningitis. Neurosurgeons take the view that antibiotics effective against potential pathogens within the nasopharynx can penetrate the meninges in sufficient quantity when a breach has occurred. However, it should be noted that there is increasing evidence from retrospective studies that these and other antibiotics given prophylactically do not significantly affect either the short- or long-term incidence of meningitis in patients with proven CSF leaks.

Food and fluid

Food and fluid should, of course, be withheld if an immediate operation under general anaesthesia is contemplated, otherwise fluid may be given as part of a soft diet using a feeding cup with a spout or tube attachment, if necessary. A fluid balance chart should be started and kept until such time as the patient is stabilized on a satisfactory fluid intake.

Cerebrospinal fluid rhinorrhoea

The possibility of cerebrospinal fluid rhinorrhoea should be considered in all Le Fort II and III fractures. In these types of fracture the escape of cerebrospinal fluid into the nose is the result of a dural tear associated with fracture of the cribriform plate of the ethmoid. In most of these instances the cerebrospinal fluid leak arrests within the first few days, either spontaneously or as the result of reduction and fixation of the fracture.

Whenever there is a tear in the dura mater there is a risk that the patient will develop meningitis either in the early days after injury or even many years later. This fact was first established by Lewin and Cairns (1951) in what has become a classical study. As a follow-up to this work, Lewin (1954) analysed 308 cases of non-missile-head injuries with associated fracture of the paranasal sinuses. Of these 84, or 72.3 per cent, developed cerebrospinal fluid rhinorrhoea, which usually occurred within the first few days, but in a number of cases was delayed in onset until the 14th day or later. Of these 84 patients with cerebrospinal fluid rhinorrhoea, 16 developed meningitis at some stage and six of them died. The incidence of late meningitis was virtually eliminated by operative repair of the dura mater.

Since the publication of these papers, argument has persisted concerning the indications for elective repair of the dura mater in cases of cerebrospinal fluid rhinorrhoea. Major fractures of the central mid-face treated in maxillofacial centres are associated with cerebrospinal fluid rhinorrhoea in about 20-25 per cent of cases (Dawson and Fordyce, 1953; Rowe and Killey, 1968). The cerebrospinal fluid leak in these and similar series lasts for about 7 days on average before it either arrests spontaneously or stops after operative reduction of the fracture (Leopard, 1971). Maxillofacial surgeons have not reported meningitis as other than a rare complication in such cases, although it is possible that patients presenting at a later date have been treated elsewhere. Nevertheless, where long-term follow-up of mid-face fractures has been reported (Dawson, 1962), there have been no cases of subsequent meningitis.

The reason appears to be that neurosurgeons are reporting a different type of case; that in which the injury is predominantly to the head.

Summary of management of CSF rhinorrhoea

1. In most maxillofacial injuries cerebrospinal fluid rhinorrhoea is assumed to be present when there is a combination of the right type of fracture with a persistent thin discharge of fluid from the nose. Confirmation of the diagnosis by laboratory investigations, CT or MRI scans requires sophisticated equipment.
2. Reposition and immobilization of the fractures seems to occlude the cerebro spinal fluid fistula safely in the majority of cases.
3. Neurosurgical advice and possible operative repair of the dura mater should be considered in the following cases:
 - Combined frontomaxillary-orbital fractures, particularly those involving the posterior wall of the frontal sinus.
 - Those mid-face fractures in which the connection with the cranial cavity is so large that an arocele develops.
 - Cases in which the cerebrospinal fluid leak persists for more than 14 days or cases in

which the rhinorrhoea is of late and persistent onset.

4. In view of the fact that central nervous system capillaries are usually impermeable to large molecules, a blood-brain barrier exists. Antibiotics will, however, reach adequate concentrations adjacent to any dural tear. The value of prophylactic antibiotics in the prevention of meningitis in those patients with actual or suspected cerebrospinal rhinorrhoea is doubtful. However, all patients with maxillofacial injuries of sufficient severity to be associated with a dural tear and CSF rhinorrhoea, should be given prophylactic antibiotics as part of the general management of the facial injury.

MULTIPLE FACIAL INJURIES: AN OVERVIEW

Most texts relating to maxillofacial trauma take the student step by step through the clinical presentation and management of injuries as they may occur in each of the anatomical subdivisions of the face. However, maxillofacial trauma is often a complex of multiple types of injury involving soft tissues, bones, teeth and specialized structures, particularly the eye.

After basic life support has been achieved and priorities established, where other injuries have occurred, there comes a point when definitive management of the facial trauma can begin. There is often confusion even among relatively experienced surgeons about how to approach the more complex facial injury - in which order should soft-tissue lacerations and fractures of individual bones be treated? It is well therefore to consider the general principles of the management of trauma to the face as a whole before describing the definitive treatment of each of its parts. It may not be possible for definitive treatment to be completed in a single operative session. For example, many facial injuries are seen first in accident departments where a maxillofacial surgeon is not immediately available and priorities are accordingly imposed by the situation.

The general order of priority for treatment of a facial injury is:

- Injuries to the eye.
- Soft-tissue lacerations.
- Reconstruction of the facial skeleton.

SOFT-TISSUE INJURIES

General considerations

Soft-tissue injuries of the face frequently occur without any underlying facial fracture and receive treatment either in an Accident and Emergency department or, when more severe, by appropriate specialists. When there are coexistent fractures of the facial skeleton the question arises

as to whether the whole injury should be treated early. There are a number of apparent advantages in this:

- 1 . The pattern of lacerations may provide access to the underlying bone.
2. The soft-tissue repair will take place after the normal bony contour has been reestablished.
3. There will be no need to reopen repaired wounds later in order to gain access to fractures.
4. The whole injury will be treated under a single anaesthetic, although, as previously stated this is no longer as important a consideration as it used to be.

Where the maxillofacial injury is a simple one uncomplicated by other bodily injury and where the appropriate skills are immediately available, the above treatment procedure will be followed. Often, in practice, this does not happen for a number of reasons:

- 1 . There are other significant injuries apart from the face.
2. Any underlying fractures are not recognized and remain undiagnosed until the radiologist reports on the radiographs.
3. The facial fractures are complex demanding more operating time than is practically available.
4. A suitably trained maxillofacial surgeon is not immediately available.

It is important to realize that, with one or two exceptions, facial bone fractures do not require early treatment. In contrast, soft-tissue injuries should in the main be treated within 24 hours of injury to achieve the best results. Facial lacerations which have been contaminated by dirt need to be adequately debrided and repaired within 12 hours to avoid tattooing. Even when the patient's general condition is serious, the facial wounds can be repaired or carefully dressed under local analgesia after immediate life-threatening problems have been dealt with. Accordingly, the treatment of soft-tissue injury of the face takes precedence over definitive treatment of facial bone fractures. Repaired facial lacerations do not significantly compromise the later management of fractures.

Facial wounds of special significance

There are a number of soft-tissue facial injuries where repair should not be attempted by those without special training and knowledge. It is important that these are recognized so that appropriate referral can take place. Special consideration must then be given to:

- 1 . Any wound with tissue loss. Gunshot wounds and other high-velocity missile injuries in particular may not be suitable for primary repair because of tissue death and contamination. Delayed primary repair after an intensive dressing regime is often the treatment of choice.
2. Animal and human bites. The bacterial and saliva contamination of these injuries interferes with healing, and repair may need to be delayed.
3. Shelved avulsion wounds such as those produced by glass fragments.
4. Lacerations of the eyelids, particularly those involving the lacrimal canaliculi.

5. Lip lacerations involving the red margin, where accurate realignment of both the muscle layer and the vermilion is critical.
6. Cheek lacerations transecting major branches of the facial nerve or parotid duct. Early microvascular repair of the main branches of the facial nerve should be carried out.
7. Lacerations of the pinna of the ear involving cartilage.
8. Haematomas of the pinna or septum of the nose. Untreated haematomas of the pinna can lead to the formation of the 'cauliflower ear'. The nasal cartilage beneath a haematoma may necrose producing a saddle deformity. In each case early aspiration is essential.

Reconstruction of the facial skeleton

Effective reduction and fixation of the facial skeleton can be carried out at any time within the first 2 weeks of injury. There may indeed be considerable advantages in delaying treatment of comminuted mid-face fractures, which are more difficult both to assess and reduce in the presence of the considerable facial oedema which is often an early feature.

There are a few fracture patterns which demand early reduction even if fixation has to be compromised in the short term. These are:

1. Mobile, painful, nearly always multiple, mandibular fractures which interfere with swallowing and increase restlessness in a patient with a significant head injury.
2. Facial fractures associated with continuing haemorrhage into the airway.
3. Upper mid-face fractures accompanied by profuse cerebrospinal fluid leakage.
4. Impaction of the mandibular condyle into the middle cranial fossa.
5. Dento-alveolar fractures with subluxed or fractured teeth.

The principles which determine the sequence of reduction and fixation of multiple fractures of the facial skeleton are based on the surgical anatomy. The mid-face is represented by a complex of bones which have to be contained in their correct positions within that outer frame, and finally the projecting nasal complex must be reassembled on a firm foundation. The techniques of reduction and fixation of the individual components of the face will be described in later chapters, but the sequence of reduction and fixation needs to be understood from the outset.

The outer frame of the facial skeleton

The upper cranial component of the face that is the supra-orbital ridges is rarely disrupted, except in craniofacial injuries. When it is, it can normally be reconstructed with precision even if a craniofacial approach is required.

The upper part of the lateral framework is made up of the lateral orbital rim and the body of the zygoma, which are braced in a forward position by the components of the zygomaxillary arch. The zygomaxillary complex must then be disimpacted laterally if necessary and reconstructed vertically in

continuity with the lateral wall of the orbit. It is additionally important to make sure the forward position and support is secured by reconstruction, and if necessary by bracing of the zygomatic arch, which is frequently crumpled in a major injury.

The mandible makes up the lower border of the frame which, of course, in normal function is hinged at the cranio-mandibular joints and therefore mobile. In a complex multiple facial injury it is important that the mandibular reduction and fixation is designed to be independent of the upper jaw. It cannot otherwise provide a platform for the reassembled bones of the middle third.

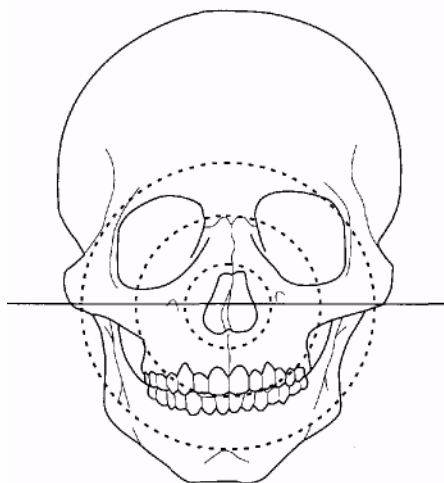


Figure 65. Diagram to illustrate the frame of the facial skeleton. The middle circle, which comprises the central part of the mid-facial skeleton excluding the nasal complex, should be considered as an upper and lower half when planning reduction and fixation of very comminuted fractures.

The mid-facial complex

After the outer frame of the face has been reconstructed, the bones of the mid-face are assembled within it. Where there is extensive comminution, it is best to deal with the components as an upper and lower half (Fig. 65). The upper part of the middle third, which comprises the orbit and the naso-ethmoid region, can be built downwards from the upper border of the facial frame, i.e. the supra-orbital ridges. The lower half is located onto the mandibular platform by re-establishing the occlusion of the teeth, or an acceptable intermaxillary relationship if teeth are missing.

Summary

Acute facial injuries should be managed in the following order:

1. **Emergency** measures to secure the *airway*.
2. **Immediate** management of any injury to the *eye*.
3. **Early** treatment of *facial lacerations* or other soft-tissue damage.

Planned reduction and fixation of *facial bone fractures*.

CLINICAL ASSESSMENT

DENTO-ALVEOLAR FRACTURES

Dento-alveolar injuries are defined as those in which avulsion, subluxation or fracture of the teeth occurs in association with a fracture of the alveolus. Dento-alveolar injuries may occur as an isolated clinical entity or in conjunction with any other type of facial bone fracture. The detailed examination of the oral cavity usually follows the examination of the facial bones, unless it is obvious that the injuries are confined to the dento-alveolar component.

Andersson *et al.* (1984) reported a series of 795 jaw fractures presenting at dental clinics in an urban area. Injuries to the teeth occurred in 36 per cent of the cases. In the maxilla isolated fractures of the alveolar process, usually the incisor region, were the commonest injury comprising 40 per cent of the maxillary fractures. No nasal or zygomatic fractures were included in the series. The vast majority of dento-alveolar injuries are minor and occur in isolation, usually involving only a tooth and its periodontal membrane. The prevalence of traumatized permanent incisor teeth has been extensively documented (Hamilton *et al.*, 1997) and is estimated to be as high as 40 per cent in the age range 8 to 15.

Damage to teeth

The importance of dental trauma is that it frequently requires immediate treatment both to relieve pain and often to preserve the dentition. Early treatment is imperative if there is exposure or near exposure of the pulp chamber or sub-luxation of an individual tooth or teeth. The dental injury will therefore take precedence over most other facial bone fractures.

Fracture of the crown of individual teeth may occur as a direct result of trauma or by forcible impaction against the opposing dentition. Anterior teeth are frequently damaged by direct impact, in which case there is often a ragged associated laceration of the upper lip or de-gloving of the alveolus. Posterior tooth injury may be caused by impaction of the two jaws together. When the lower teeth are forced against the occlusal surfaces of the upper, this may cause vertical splitting of one or more teeth. Meticulous dental examination is essential and any missing fragments of crown or missing fillings noted. Where missing teeth are noted it is important to be sure no retained roots are present. Fragments of teeth may become embedded in lip or tongue lacerations, or they may be swallowed, or rarely inhaled. Subluxation of teeth may cause derangement of the occlusion. Individual teeth may be missing and an empty tooth socket suggests that the tooth concerned has been knocked out. If a tooth or fragment of tooth cannot be accounted for, a chest X-ray should be ordered. This is particularly important if the patient was unconscious for any period after the injury as inhalation of a foreign body is much more likely in these circumstances. Fractures of the roots of teeth may be present which are difficult to diagnose clinically. Excessively mobile teeth which do not appear to be subluxed are suspect and should be earmarked for later periapical radiographs.

Occasionally molar and premolar teeth appear superficially normal but close inspection reveals either a vertical split or a horizontal fracture just below the gingival margin resulting from indirect trauma against the opposing dentition or violent impact by a small hard object such as a missile.

Electrical or thermal vitality tests at this stage of injury are unreliable and of little use in determining the eventual prognosis for the pulp. A blow of sufficient force to disrupt the alveolus will usually disturb the function of the nerve endings supplying individual teeth whose blood supply may nevertheless be intact.

Alveolar fractures

Alveolar fractures in the mandible are frequently associated with complete fractures of the tooth-bearing segment whereas in the maxilla they are more often isolated injuries. Unusually there may be no associated injury to the teeth. However, teeth within an alveolar fracture should be presumed to have been devitalized until evidence to the contrary emerges during the period of follow-up. Severe trauma in either jaw may result in gross comminution of the alveolus but more often the alveolar fracture consists of one or two distinct fragments containing teeth (Figs 66 and 67).

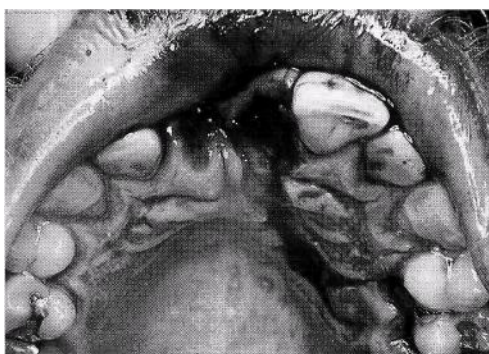


Figure 66. An alveolar fracture of the left maxilla.
The segment has separated as a single block of bone with contained teeth.

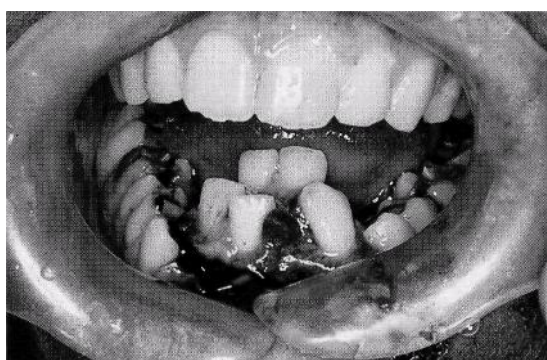


Figure 67. A comminuted alveolar fracture of the anterior mandible.
In this case the individual teeth have been subluxed within the alveolar segment

During the initial examination it may be possible gently to reposition loose alveolar fragments, and the earlier this is achieved the better the prognosis for individual teeth.

In lower jaw fractures a complete alveolar fragment may be displaced into the soft tissues of the floor of the mouth and can on occasions be completely covered by mucosa. In the symphysis region it may be difficult to determine whether a loose alveolar fracture is part of a complete fracture of the mandible. An associated fracture through the lower border may be only a crack and less mobile than the alveolar segment.

Maxillary alveolar fractures occur most often in the incisor region in which case there may be obvious deformity of the alveolus and disturbance of the occlusion. This is not always the case as some of these fractures are impacted into the relatively soft bone of the maxilla and may be virtually immobile. Where dental examination reveals damage to teeth or bruising of the alveolus, careful palpation is necessary to exclude any underlying alveolar fracture. Sometimes crepitation can be detected on palpation and a 'cracked pot' note detected when the teeth within the impacted alveolar fracture are percussed.

A midline split of the palate converts a Le Fort I fracture into two large dento-alveolar segments. A split palate may be suspected if there is a linear haematoma visible beneath the palatal mucosa. Movement of the fragments may be detected by firm digital separation of the two sides and confirmed by an occlusal radiograph. This is an important finding because the injury will have a fundamental bearing on the management of any other associated facial bone fractures.

Fracture of the maxillary tuberosity and fracture of the antral floor are recognized complications of upper molar extractions (Fig. 68).

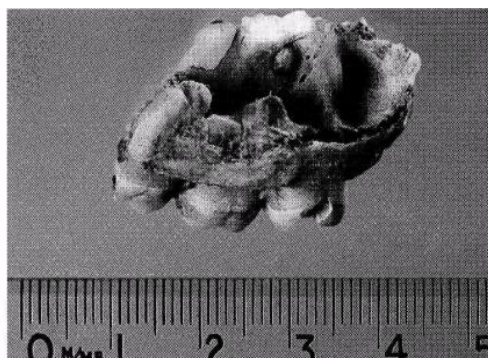


Figure 68. Dento-alveolar fracture of the antral floor with avulsion of the fragment as a result of an extraction accident

Associated soft-tissue injuries

Anterior dento-alveolar fractures are usually associated with significant damage to the lips. There is usually substantial bruising and there may be portions of tooth or foreign bodies embedded in the soft tissues. Inspection may reveal a full-thickness perforating wound of one or other lip or a ragged laceration on the inner aspect caused by impaction against the anterior teeth.

Over the alveolar margin itself there will usually be lacerations of the gingiva and deformity of the alveolus. In the anterior region of the mandible a 'degloving' injury may occur as a result of impaction of the point of the chin on some resilient surface such as soft earth. The jaw does not

fracture but the soft tissue is rotated violently over the point of the chin and a horizontal tear occurs in the buccal sulcus at the junction of the attached and free gingiva.

FRACTURES OF THE MANDIBLE

Complete fractures of the mandible can be divided according to their anatomical location into seven main types. These are:

1. Condylar.
2. Coronoid.
3. Ramus.
4. Angle.
5. Body (molar and premolar areas).
6. Symphysis and parasymphysis.
7. Multiple and comminuted fractures.

Fractures in each of these situations have clearly defined signs and symptoms which can be readily elicited even in cases of multiple injury.

Condylar fractures

These are the most common fractures of the mandible and are the ones most commonly missed on clinical examination. Condylar fractures may be unilateral or bilateral and they may either involve the joint compartment as intracapsular fractures or the condylar neck when they are regarded as extracapsular. The latter are the more common. The extracapsular fracture may exist with or without dislocation of the condylar head, and the upper fragment may either remain angulated on the lower portion of the ramus or be displaced medially or laterally. The commonest displacement is antero-medial owing to the direction of pull of the lateral pterygoid muscle, which is attached to the antero-medial aspect of the condylar head and also to the meniscus of the temporo-mandibular joint.

In the immediate post-traumatic phase most fractures in the condylar region exhibit similar signs and symptoms.

Unilateral condylar fractures *Inspection*

Any movement of the lower jaw is likely to be restricted and painful. There is often swelling over the temporo-mandibular joint area and there may be haemorrhage from the ear on that side. Bleeding from the ear results from laceration of the anterior wall of the external auditory meatus, caused by violent movement of the condylar head against the skin in this region. In the normal subject the close relationship of the condyle to the skin of the external auditory meatus can be appreciated if the little finger is placed within the external ear and the jaw moved. It is important to

distinguish bleeding originating in the external auditory canal from the more serious middle ear haemorrhage. The latter signifies a fracture of the petrous temporal bone and may be accompanied by cerebrospinal otorrhoea. In all cases of suspected condylar fracture the ear should be examined carefully with an otoscope. The appearance may be extremely confusing even to an experienced maxillofacial surgeon, and there should be no hesitation in asking the opinion of an otologist in these circumstances.

The haematoma surrounding a fractured condyle may track downwards and backwards below the external auditory canal. This gives rise to ecchymosis of the skin just below the mastoid process on the same side. This particular physical sign also occurs with fractures of the base of the skull, when it is known as 'Battle's sign'. It is vital not to confuse the aetiology when an ecchymosis at this site is discovered (Fig. 69).

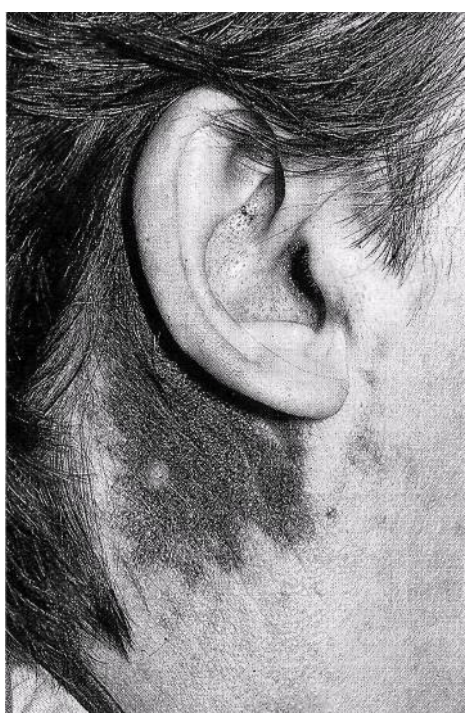


Figure 69. A genuine 'Battle's sign' - a haematoma below and behind the mastoid process in a patient with a fractured base of the skull. Most haematomas seen in this position occur secondary to a fracture of the mandibular condyle.

On the very rare occasion when the condylar head is impacted through the glenoid fossa, the mandible will be locked and middle ear bleeding may present externally.

If the condylar head is dislocated medially and all oedema has subsided due to passage of time, it may be possible to observe a characteristic hollow over the region of the condylar head, but in the immediate post-traumatic phase this physical sign is obscured by oedema.

Palpation

In the recently injured patient there is invariably tenderness over the condylar area. When post-traumatic oedema is present it is difficult to palpate the condylar head and what is believed to

be the condylar head may, in fact, be that portion of the condylar neck continuous with the lower portion of the ramus. It may be possible to determine whether the condylar head is displaced from the glenoid fossa by palpation within the external auditory meatus. Standing in front of the patient both little fingers can be hooked into each external auditory meatus and the position and movement of each condylar head compared.

Intra-orally

Displacement of the condyle from the fossa or over-riding of the fractured condylar neck shortens the ramus on that side and produces gagging of the occlusion on the ipsilateral molar teeth (Fig. 70). The mandible deviates on opening towards the side of the fracture and there is usually painful limitation of protrusion and lateral excursion to the opposite side.

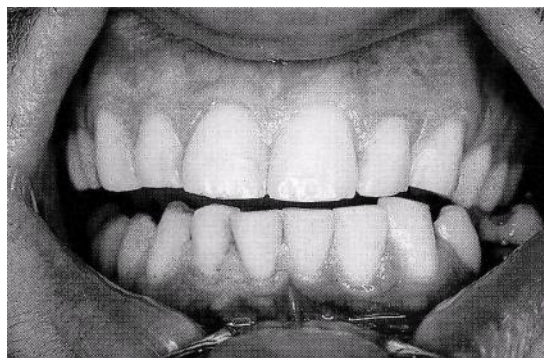


Figure 70. Occlusal disturbance produced by a unilateral displaced fracture of the condylar neck. The fracture has occurred on the left side with resultant shortening of the ramus and premature contact of the molar teeth.

Bilateral condylar fractures

The signs and symptoms already mentioned for the unilateral fracture may be present on both sides. Overall mandibular movement is usually more restricted than is the case with a unilateral fracture.

Intra-orally

It only requires one condyle to be displaced with shortening of the ramus to lead to premature contact of the posterior teeth on the side of injury. Accordingly derangement of the occlusion is more usual with bilateral than with unilateral condylar fractures. Intracapsular fractures produce little if any shortening and the occlusion is often found to be normal. If both fractures have resulted in displacement of the condyles from the glenoid fossa or overriding of the fractured bone ends, an anterior open bite is found to be present (Fig. 71). In all cases of bilateral fracture there is pain and limitation of opening with restricted protrusion and lateral excursions.

Bilateral condylar fractures are frequently associated with fracture of the symphysis or parasymphysis and these areas should always be carefully examined.

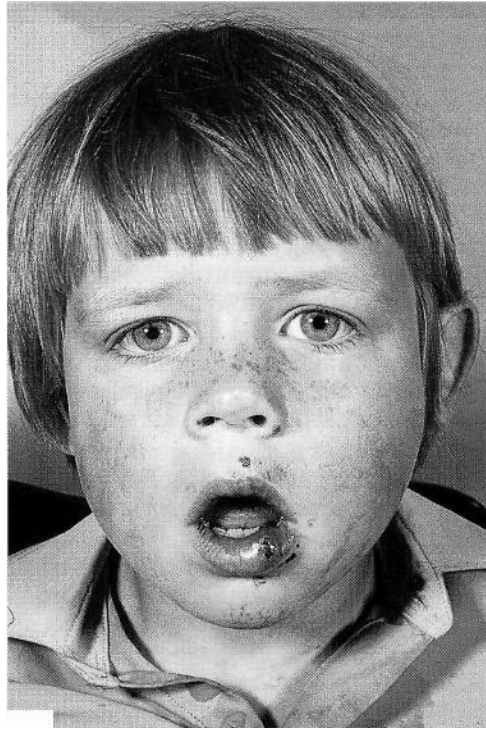


Figure 71. A patient with bilateral displaced fractures of the condylar necks. There is an anterior open bite swelling over both fracture sites and all movements of the lower jaw are restricted.

Fracture of the coronoid process

This is a rare fracture which is usually considered to result from reflex contraction of the powerful anterior fibres of the temporalis muscle. The fracture can be caused by direct trauma to the ramus but is rarely in isolation in these circumstances. If the tip of the coronoid process is detached, the fragment is pulled upwards towards the infratemporal fossa by the temporalis muscle. The coronoid process is sometimes fractured during operations on large cysts of the ramus.

This is a difficult fracture to diagnose clinically but there may be tenderness over the anterior part of the ramus and a tell-tale haema-toma. There may be painful limitation of mandibular movement, especially protrusion.

Fracture of the ramus

Fractures confined to the ramus are not common and there are two main types:

- 1 . Single fracture. This is an uncommon injury. It is usually in effect a very low condylar fracture running almost vertically downwards from the sigmoid notch. Occasionally as a result of direct violence a more horizontal single fracture can occur with both the coronoid and condylar processes on the upper fragment.
2. Comminuted fracture. Such a fracture always results from direct violence to the side of the face. It is a relatively common fracture in missile injuries but is uncommon in civilian practice. The fragments tend to be splinted between the masseter and medial pterygoid muscles and little displacement occurs unless there has been extreme violence.

Clinical features

Swelling and ecchymosis are usually noted both extra- and intra-orally. There is tenderness over the ramus and movements produce pain over the same area. Severe trismus is usually present.

Fracture of the angle

In contrast to other fractures of the tooth-bearing portion of the mandible, the signs and symptoms are not markedly influenced by the degree of displacement of the bone ends, firm gingival attachment, fractures between adjacent teeth tend to cause gingival tears. When there is gross displacement, the inferior dental neurovascular bundle may be torn and this can give rise to severe intra-oral haemorrhage in addition to anaesthesia or paraesthesia within the distribution of the inferior dental nerve. Molar teeth in particular may be split longitudinally in the fracture line and can cause considerable discomfort when the inferior dental nerve remains functional.

Inspection

Movements of the mandible are painful and trismus is frequently present to some degree. There is swelling at the angle externally and there may be obvious deformity. Within the mouth a step deformity behind the last molar tooth may be visible, which is more apparent if no teeth are present in the molar region. When teeth are present the occlusion is often deranged. Undisplaced fractures are usually detected by the presence of a small haematoma adjacent to the angle on either the lingual or buccal side or both. Anaesthesia or paraesthesia of the lower lip may be present on the side of the fracture.

Palpation

There is always bone tenderness on palpation of the angle externally. Movement or crepitus at the fracture site can be felt if the ramus is steadied between finger and thumb and the body of the mandible moved gently with the other hand. A step may be palpated even if it is not evident on inspection.

Fracture of the body (molar and premolar regions)

The physical signs and symptoms are similar to those of fractures of the angle as far as swelling and bone tenderness are concerned. In the dentate mandible even slight displacement of the fracture causes derangement of the occlusion. Premature contact occurs on the proximal fragment as a result of the displacing action of the muscles attached to the ramus. Because of the

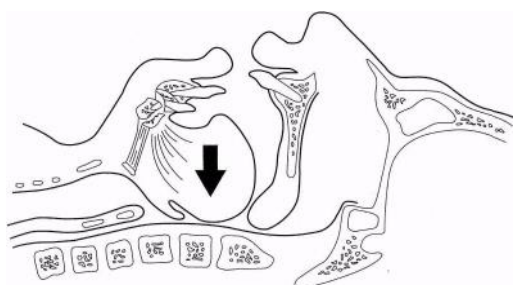
Fractures of the parasymphysis and symphysis

These fractures are commonly associated with fractures of one or both condyles. The thickness of the anterior mandible between the canine regions often ensures that these fractures are fine cracks which are little displaced and may be missed if the occlusion is undisturbed locally. The presence of bone tenderness and a small lingual haematoma may be the only physical signs.

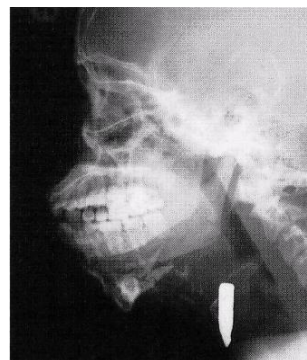
More severe impact over the symphysis can lead to considerable disruption of the anatomy. A single fracture line is often oblique, which allows over-riding of the fragments with lingual inversion of the occlusion on each side. Frequently trauma of this degree results in bilateral parasymphyseal fractures or comminution of the whole symphyseal bone. There is often associated soft-tissue injury of the chin and lower lip since these fractures are always caused by direct violence.

These fracture patterns are often associated with quite severe concussion, in which case the separation of the fragment to which the genio-glossus muscle is attached may contribute to loss of voluntary tongue control and obstruction of the airway (Fig. 72a). If consciousness is not impaired, considerable disorganization of the anterior mandible and the adjacent soft tissue can take place without any significant loss of voluntary control of the tongue. Direct impact by a small high-velocity missile would produce this type of injury without impairment of consciousness (Fig. 72b,c).

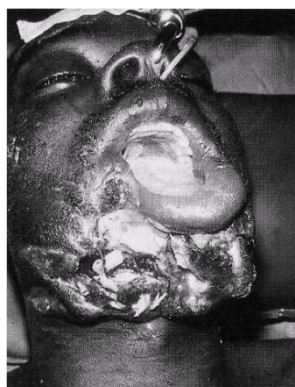A fracture of the symphysis is not accompanied by anaesthesia of the skin of the mental region unless the mental nerves are injured after emergence from their foramina.



(a)



(b)



(c)

Figure 72. (a) Diagrammatic illustration of the mechanism which allows the tongue to fall back and obstruct the airway following a fracture of the symphysis. This is most likely to occur if the patient is unconscious and lying on his or her back, (b) Lateral radiograph showing symphysis fracture produced by the bullet that still lies within the tissues. The patient's level of consciousness was not affected by the injury. In spite of the reduced tongue support it can be seen that the shadow of the posterior third of the tongue is postured well forward and the airway is not obstructed, (c) Gunshot injury of anterior part of mandible. The patient was not rendered unconscious at the time of injury and had survived 1 week without any airway problems. Under anaesthesia in the supine position control of the tongue is immediately lost and it drops downwards and backwards against the posterior pharyngeal wall

MULTIPLE AND COMMUNUTED FRACTURES

The physical signs of multiple and comminuted fractures depend on the site and number of the fractures. Multiple and comminuted fractures result from extreme direct violence and are usually associated with severe soft-tissue injury. The precise pattern of bony injury may be impossible to determine from the clinical examination. When there is unexpected mobility of what at first sight appears to be a single fracture, a second fracture on the same side should be suspected. In general comminuted fractures of the ramus, angle and molar regions are not associated with gross displacement of the fragments. However, comminution of the symphysis allows the lateral segments to collapse and presents a much more serious problem of management.

FRACTURES OF THE MID-FACIAL SKELETON

Fractures of the zygomatic complex

Classification

The zygomatic bone is intimately associated with the maxilla, frontal and temporal bones, and as they are usually involved when a zygomatic bone fracture occurs it is more accurate to refer to such injuries as 'zygomatic complex fractures'. Many texts and clinical departments refer to these injuries as 'malar complex fractures', malar being the generic term pertaining to the cheek.

The zygomatic bone usually fractures in the region of the frontozygomatic, the zygomatico-temporal and the zygomatico-maxillary sutures. It is unusual for the zygomatic bone itself to be fractured, but occasionally it may be split across and when there has been extreme violence the bone may even be comminuted. The arch of the zygoma may be fractured in isolation from the rest of the bone.

A classification of fractures of the zygomatic complex is most usefully based on the extent of involvement of the structures within the orbit. All fractures of the body of the zygomatic complex must involve the orbit but the importance of that involvement depends on the degree and direction of displacement.

Downward displacement with separation at the frontozygomatic suture means that the lateral attachment of the suspensory ligament of the eye to Whitnall's tubercle is also displaced downwards with alteration of the visual axis (Fig. 73a).

Inward and posterior displacement does not produce this effect, but these fractures may also interfere with eye movement because of entrapment of orbital adnexae in the orbital floor (Fig. 73b).

Rarely the body of the zygomatic complex (usually on both sides) is displaced outwards following a central blow to the face with impaction of the central block of the mid-face (Fig. 73c).

The fractures of the zygomatic complex may be classified, therefore, as follows (Fig. 73).

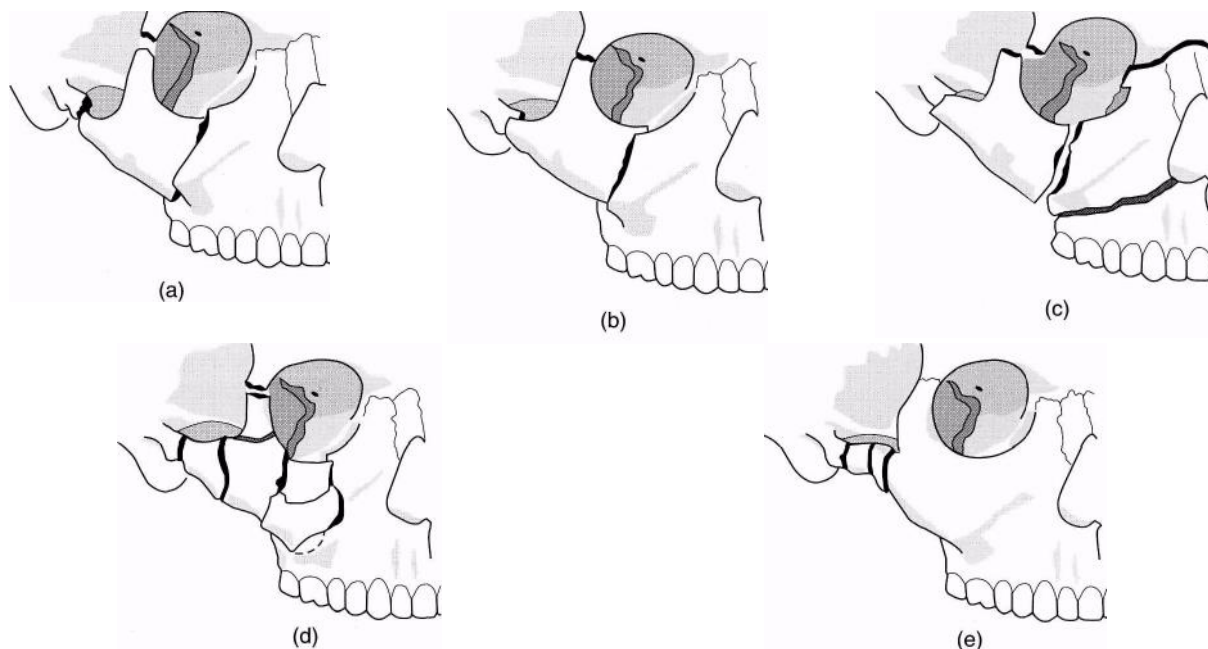


Figure 73. The main types of displacement in fractures of the zygomatic complex, (a) Inward and downward displacement: Whitnall's tubercle is depressed together with the suspensory ligament of the eye. (b) Inward and posterior displacement: the level of the suspensory ligament is unchanged but the floor of the orbit may be extensively damaged, (c) Outward displacement of the zygomatic complex occurring in conjunction with impacted central mid-face fractures, (d) Comminution of the whole zygomatic complex with considerable depression, (e) Fracture of the zygomatic arch alone not involving the orbital walls.

Fractures of the body of the zygomatic complex involving the orbit:

- 1 . Minimal or no displacement.
2. Inward and downward displacement.
3. Inward and posterior displacement.
4. Outward displacement.
5. Comminution of the complex as a whole.

Fractures of the zygomatic arch alone not involving the orbit:

- 1 . Minimal or no displacement.
2. V-type in-fracture.
3. Comminuted.

An understanding of the nature of the displacement of the zygomatic complex is of value when planning the disimpaction of the fracture and in evaluating the probable stability of the fragments after reduction.

Rowe (1985) has pointed out that when the zygomatic complex is displaced around a vertical axis running through the frontozygomatic suture and first molar tooth, it tends to be stable after simple reduction. However, if displacement occurs round a horizontal axis running through the infra-orbital foramen and the zygomatic arch, simple reduction of the fracture is unstable. It will readily be appreciated that in the latter group of fractures there is separation at the frontozygomatic suture. Fractures of the zygomatic complex which are either comminuted or in which the periosteum of the frontozygomatic suture is torn are inherently unstable after simple reduction and therefore need direct fixation by surgical intervention.

Signs and symptoms

The signs and symptoms of a fracture of the zygomatic bone are closely related to the surgical anatomy of the part.

Flattening of the cheek

When the zygomatic bone is fractured as a block near its principal three suture lines, it forms a tripod most often displaced inwards to a greater or lesser extent. There may be minimal displacement or an obvious unsightly flattening of the cheek on that side. Tenderness is noted at the fracture lines, particularly over the frontozygomatic suture, and an obvious step may be present at the infra-orbital margin (Fig. 74).

The amount of depression may be masked if the patient normally has full cheeks; on the other hand, certain ethnic types, such as the Slavonic race, who normally have prominent cheek bones, may exhibit marked flattening of the face with only moderate inward displacement of the underlying skeleton.

The physical sign of flattening of the cheek bone is best seen by viewing the patient either from above by standing behind and above the patient and comparing the two sides of the face, or by viewing the two cheek bones from below. Flattening is most obvious either immediately after the accident before the area has become oedematous, or after the swelling has subsided.

The speed with which oedema occurs varies considerably. In some thin, elderly patients, flattening may be obvious up to about an hour after the injury; on the other hand, young plump-faced individuals swell up almost immediately. It is always possible to palpate the zygoma at the point of maximum prominence of the cheek. If oedema is masking the flattening, the examiner should view the cheek prominence from above and behind the patient with each forefinger placed on the point of maximum prominence on each side. The relative position of the tips of the two

fingers can then be readily compared with an unaffected contour such as the mid-point of the forehead or tip of the nose. Even with marked oedema this manoeuvre enables an assessment to be made of the degree of flattening. Most of the overlying swelling subsides in about a week, but the full extent of the flattening is not apparent until all oedema has completely disappeared, which takes up to three weeks.

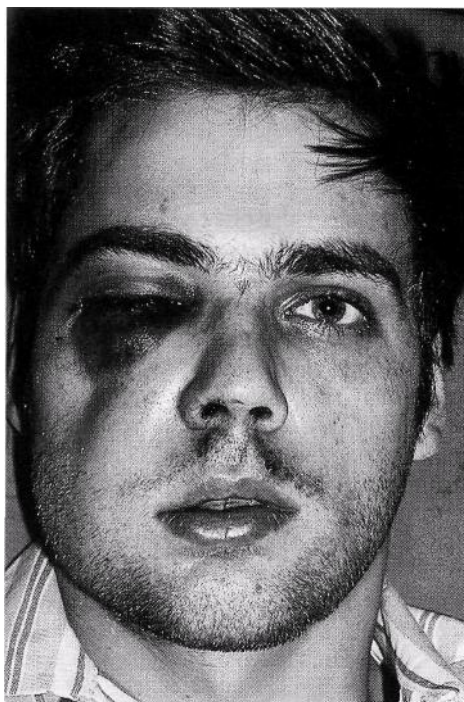


Figure 74. Patient with gross depression of the zygomatic complex and obvious flattening of the cheek

Enophthalmos

Enophthalmos is a troublesome sequel to some fractures of the zygomatic complex. This sinking inwards of the eye may itself be a cause of diplopia. Enophthalmos occurring immediately after injury is the result of an increase in the volume of the orbit due to fracture of its walls. It is made worse by herniation of fat from the orbit via defects usually in the floor or medial wall. Fat can also escape from the orbit via the inferior orbital fissure without there being evidence of bony injury in that area.

In recent years important advances have been made in the understanding of the anatomy of the tissues supporting the globe of the eye. Koornneef (1977) demonstrated the presence of a network of connective tissue organized into fibrous septa within the orbital fat. Condensation of this connective tissue constitutes the suspensory ligament and also completes the cone formed by the extrinsic ocular muscles. Post-traumatic scarring of this supporting tissue can cause inward and downward displacement of the globe and contribute to late-developing enophthalmos.

Computed tomographic scanners can be used to measure precisely the volume of the orbit and its various soft-tissue components (Bite *et al.*, 1985; Manson *et al.*, 1986). Manson *et al.* (1986) have compared the volume of injured with normal orbits in a group of patients and related their findings to a detailed anatomical investigation of the mechanisms of global support. These studies demonstrate conclusively that fat atrophy is not a significant feature in most patients with post-traumatic enophthalmos. Enophthalmos is caused either by escape of orbital fat or by an increase in the volume of the bony orbit. Increased orbital volume usually results from fractures which involve the orbital floor and which produce a change in the sagittal contour of the posterior part of the floor from a convex to a concave outline.

Fractures of the zygomatic arch can be divided into two main varieties:

- 1 . The triple fracture of the arch with adepressed V-type of displacement (Fig. 75a,b).
2. Comminution of the arch.

In the V-type of displacement the apex of the V may impinge on the coronoid process and impede mandibular movements, especially lateral excursion to the injured side. In the absence of surgical correction this depression persists and constitutes a cosmetic deformity.

When the zygomatic arch is comminuted, the fragments usually reposition themselves presumably as a result of movements of the tempor-alis muscle and coronoid process beneath them. Signs and symptoms may be minimal or absent.

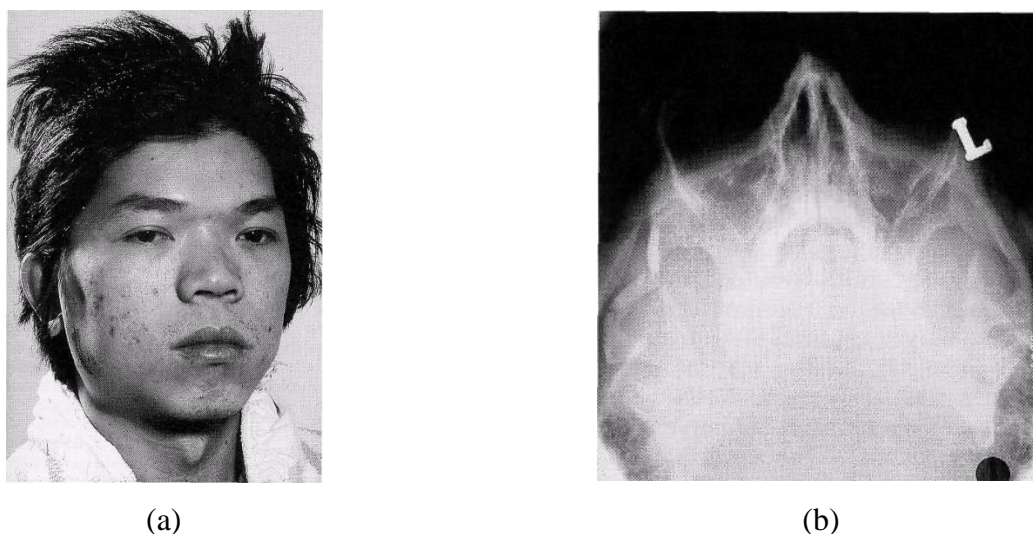


Figure 75. (a) Marked indentation of the skin of a patient with an isolated fracture of the underlying zygomatic arch, (b) The occipitomental radiograph of the patient shown in (a). The fracture of the right zygomatic arch is clearly seen.

Summary of possible clinical findings in nasal complex fractures

- 1 . Bruising of skin over nasal bones.
2. Laceration of skin of bridge of nose.
3. Bilateral medial orbital ecchymosis.
4. Epistaxis.

Deformity of nose.

Crepitus of bones of nasal complex.

Unilateral or bilateral telecanthus.

Airway obstruction.

Septal deviation.

Septal laceration or haematoma.

Cerebrospinal rhinorrhoea.

Le Fort I (low-level, or Guerin)-type fractures

The Le Fort I fracture may occur as a single entity or in association with Le Fort II and III fractures. It is not infrequently present in association with a downwardly displaced fracture of the zygomatic complex. In this situation the upper tooth-bearing segment is either wholly or partially sprung downwards and the fracture may easily be missed by the unaware. A Le Fort I fracture that often escapes diagnosis is the impacted type, which results from violence transmitted via a blow to the lower jaw, and is often therefore associated with a fracture of the mandible.

Signs and symptoms of an isolated Le Fort I fracture

In a recent injury there may be slight swelling of the upper lip, but there is none of the massive oedema of the face which characterizes Le Fort II and III fractures. Typically ecchymosis is present in the buccal sulcus beneath each zygomatic arch. The occlusion is disturbed and a variable amount of mobility may be found in the tooth-bearing segment of the maxilla. Some Le Fort I fractures are so mobile that the whole fragment drops and the patient may have to keep the mouth slightly open to accommodate the increased vertical dimension of the bite. This situation may result from a direct blow from a sharp object in the front of the mouth above the apices of the teeth. When this happens a soft-tissue laceration is often present, and in extreme cases the resulting down-fracture of the maxilla may be so gross that it may be possible to see directly into the nares and the maxillary antra through the upper lip.

Most Le Fort I fractures are not as mobile as this. Indeed, the impacted type fracture may be almost immobile and it is only by grasping the maxillary teeth and applying slight but firm movement, that a characteristic grate can be felt which is diagnostic of the fracture. The maxillary cheek teeth should be moved apart in the same way to make sure there is no associated midline split in the palate.

In the impacted type of fracture there may be damage to the cusps of individual teeth, usually in the premolar region, caused by the impaction of the mandibular teeth against them. Percussion of the

upper teeth results in a distinctive 'cracked-pot' sound, similar to that produced when cracked china is tapped with a spoon. This sign is present whenever there is a fracture of the central mid-face, but is particularly valuable in the diagnosis of Le Fort I fractures.

All possible variations of open and closed type fractures may occur and it is possible to see the condition unilaterally when it involves only one maxilla, the tooth-bearing portion being split along the median palatal suture. The complete Le Fort I fracture is often associated with a split in the palate, sometimes along more than one line so that each of two or more fragments may be mobile. Multiple alveolar fractures of this nature are frequently complicated by damaged or subluxed teeth.

Le Fort II and III fractures (pyramidal and high transverse fractures)

Although in many cases it is possible to distinguish between these two fractures by clinical examination, the signs and symptoms are so similar that they can be considered together. Le Fort II (pyramidal) and Le Fort III (supra-zygomatic) fractures frequently coexist, one with the other, or with associated Le Fort I or zygomatic complex fractures.

Signs and symptoms common to Le Fort II and III fractures

1. At first sight patients with either of these varieties of fracture are seen to have gross oedema of the soft tissues overlying the mid-facial skeleton, giving rise to the characteristic 'moon-face' appearance. This ballooning of the features is not seen in isolated Le Fort I fractures, and occurs within a very short time of injury although it is rarely maximal until the next day (Fig. 76).
2. Bilateral circumorbital ecchymosis is invariably a feature of both fractures and this also develops quite rapidly after injury. The associated rapid swelling of the eyelids makes examination of the eyes difficult but it is absolutely essential to do this at an early stage to exclude damage to the globe of the eye. Steady but gentle pressure upon the swollen eyelids, sustained for 1 or 2 minutes, will diminish the oedema sufficiently to allow them to be parted. This manoeuvre also allows the orbital rim to be palpated with accuracy.
3. Subconjunctival ecchymosis usually develops rapidly, but it sometimes requires several hours to become fully established. Subconjunctival haemorrhage tends to occur adjacent to those parts of the orbit where fracture has occurred, but the pattern is so variable that it is of little diagnostic value.
4. Oedema of the conjunctiva or chemosis is frequently seen in association with a periorbital haematoma. This causes the swollen conjunctiva to bulge out from between the eyelids, a feature which becomes more obvious as the eyelid swelling subsides.
5. Both Le Fort II and III fractures involve the orbit and if they coexist, the orbit itself is usually extensively damaged (Fig. 76). It is essential that the eyes are examined at an early stage by an ophthalmologist. Fortunately, it is extremely rare for the fracturing force to damage the optic nerve, as the nerve is protected by a strong ring of compact bone which forms the optic foramen, and the

fracture line goes around the foramen rather than through it. Nevertheless vision can be impaired as a result of the injury, and it is therefore imperative to test it as soon as possible. Careful note should be made of any variation in the size of the pupils, which may be the result of peripheral damage to the oculomotor nerve in the superior orbital fissure, or more seriously be an early sign of intracranial haemorrhage.

In the early stage of the injury it is often difficult to test ocular movements or test for diplopia, but diplopia is usually present and ocular movements may be limited.

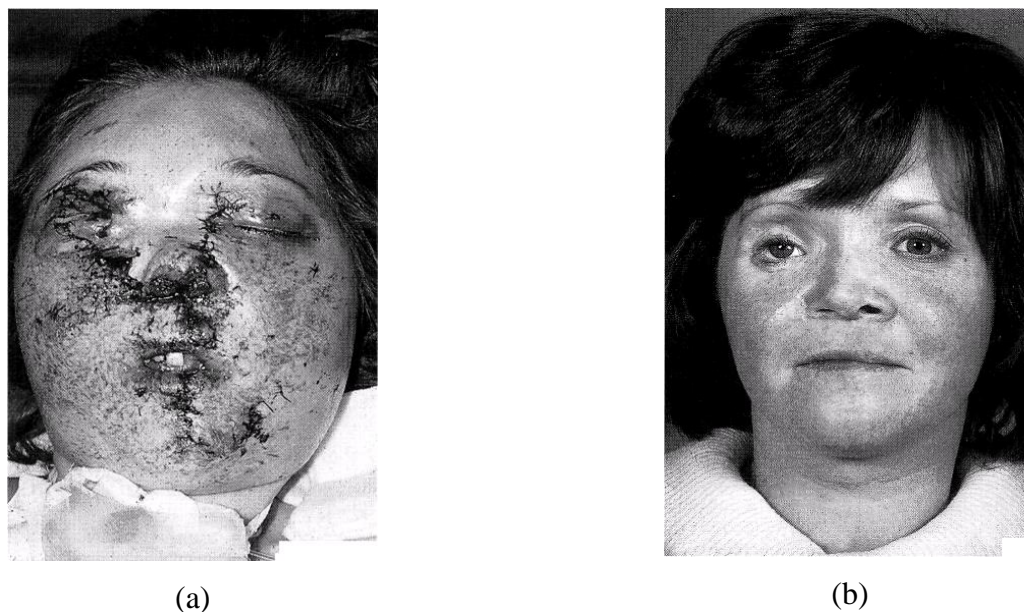

Figure 76. (a) A patient with a very severe facial injury. The mid-facial skeleton has been fractured at the Le Fort I, II and III levels and both zygomatic bones displaced. There is extensive damage to the right orbit and comminution of the naso-ethmoid complex with traumatic telecanthus. A tracheostomy has been carried out and the facial lacerations sutured, (b) Full-face view of patient shown in (a) after initial treatment. This view gives some idea of the amount of facial oedema associated with the original injury.

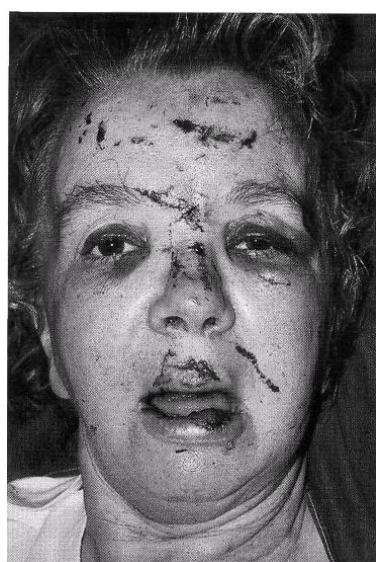6. Both fractures pass through the nasal complex of bones at their base, and may extend backwards to involve the cribriform plate area. The nasal complex itself exhibits varying degrees of comminution, but in general when a Le Fort III fracture is present, the damage in this region tends to be more extensive than in the Le Fort II fracture alone. Usually the pattern of nasal fracture is characteristic of an anterior rather than a lateral blow, when associated with Le Fort II and III fractures. It is accordingly usually flattened over the bridge and there may be spreading of the intercanthal distance. There may sometimes be lengthening of the nose where the mid-face fracture is very loose, and where it has dropped, as a whole, away from the skull base. The nares tend to be filled with clotted blood and there may be a steady trickle of straw-coloured fluid from the nose, suggesting a cerebrospinal fluid leak mixed with serum.

7. In both types of fracture, the bones of the mid-face have been separated from the inclined plane of the base of the skull and forced downwards and backwards to a variable degree. A very large

impacting force tends to cause comminution of the bones in the anterior parts of the face, rather than an increase in the posterior displacement, a fact demonstrated quite clearly by Le Fortin his original experiments. Hence, the backward and downward displacement of the tuberosity area of the maxilla and palate is rarely, if ever, sufficient to obstruct the nasopharynx as classically described. This fact can be readily appreciated by passing a finger around the posterior edge of the soft palate in an anaesthetized patient prior to reduction of the fracture of the mid-face. The posterior nares are in almost every case clearly defined even when the impact has caused considerable concavity of the anterior part of the face. However, even slight downward displacement of the maxillary molar teeth is sufficient to cause gagging of the occlusion, and there will usually be some retroposition of the maxilla as a whole.

Occasionally there is wide separation of the mid-face from the skull base. Clinicians frequently refer to a 'floating' maxilla in such cases. When this occurs, there is usually an additional fracture at the Le Fort I level, although the maxillae may be very loose in some pure Le Fort II and III fractures. In such cases there will be extreme lengthening of the face (Fig. 77a,b). It should be appreciated that extreme mobility of Le Fort II and III fractures is the exception rather than the rule. A lesser degree of mobility of the mid-face is readily detected by grasping the maxillary alveolus and gently moving it forwards and backwards. Tapping of the upper teeth will give a characteristic 'cracked-pot' sound.

8. In both Le Fort II and III fractures there may be extensive bruising of the soft palate, particularly when the maxillae have separated in the midline. Blood clot frequently accumulates around the teeth and particularly in the vault of the palate, where it causes the patient considerable discomfort.



(a)



(b)

Figure 77. (a) Extreme lengthening of the face in a patient with mobile Le Fort I and II level fractures.(b) Same patient as shown in (a) after treatment. The facial dimensions have been restored following reduction of the fractures.

Signs and symptoms peculiar to Le Fort II fractures

1. The most obvious difference between the Le Fort II and III fractures, from the clinical point of view, is the detection of a step deformity in the bone of the infra-orbital margin. This is made more apparent when the zygomatic complex on each side is intact.
2. As the fracture line passes across the inferior orbital rim, there is likely to be associated injury to the infra-orbital nerve resulting in anaesthesia or paraesthesia of the cheek.
3. Similarly the fracture line in the orbital floor may result in limitation of orbital movement in an upward direction with diplopia and possibly enophthalmos.
4. Because the line of fracture is below the lateral attachment of the suspensory ligament of Lockwood, alteration of the pupil level does not occur unless there is an associated fracture of the zygomatic complex.
5. Gapping of the occlusion and retropositioning of the maxilla as a whole will be noted on intra-oral examination, but when the maxillary teeth are grasped, it will be noted that the mid-facial skeleton moves as a pyramid, the movement being detected at the infra-orbital margins and nasal bridge.
6. The Le Fort II fracture may be impacted in the same manner as the Le Fort I, in which case little or no mobility can be detected. There is frequently a midline or paramedian split in the pyramidal block.
7. The passage of the fracture line across the zygomatic buttress gives rise to haematoma formation in the upper buccal sulcus on each side, opposite the first and second molar teeth.
8. Unless the fracturing force was applied directly to the nasal region, the comminution of this part of the pyramidal block is usually minimal. In the same way there is less danger of extensive associated fracture of the anterior cranial fossa in the region of the cribriform plate, and cerebrospinal fluid rhinorrhoea is therefore not a constant clinical finding. However, when a Le Fort II fracture is present, it must be assumed that a breach of the dura mater has occurred, even if overt leakage of cerebrospinal fluid is not detected.

Signs and symptoms peculiar to Le Fort III fractures

Superficially the Le Fort III fracture appears very similar to the Le Fort II fracture, but it is usually obvious that the injury is very much more severe. It is, however, very unusual to find a Le Fort III fracture occurring in isolation. A frontal blow of sufficient force to separate the facial bones at the Le Fort III level, usually produces coexistent fracture at Le Fort II and I levels together with extensive comminution of the nasal complex. Indeed, in injuries of this severity the Le Fort classification becomes meaningless other than as a general guide to the fracture pattern. An isolated Le Fort III fracture is most likely to be produced by an oblique blow from a lateral direction, in

which case there may be tilting and some lengthening of the facial skeleton due to separation at the frontozygomatic suture line (Fig. 78).

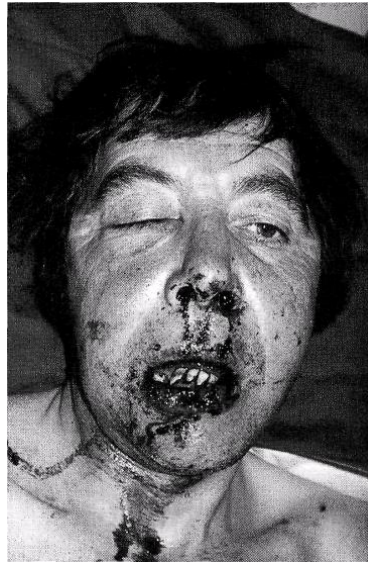

Figure 78. Mid-facial Le Fort type fracture at more than one level. Note lengthening of face and deviation of nasal complex to the left. There has been some fall in the level of the right eye with the upper lid following it down producing the physical sign of 'hooding'.

The clinical features of the Le Fort III fracture are then superficially similar to the Le Fort II with the following differences:

- 1 . There is tenderness and often separation at the frontozygomatic sutures. The amount of separation may not be symmetrical in which case the facial skeleton will be tilted to the side opposite to the direction of the fracturing force.
- 2 . Separation of both frontozygomatic sutures produces lengthening of the face and lowering of the ocular level, due to the fracture passing above Whitnall's tubercle, removing the support given to the eye by Lockwood's suspensory ligament. As one or both eyes drop, the upper lid follows the globe down, producing unilateral or bilateral pseudo-ptosis described as 'hooding' of the eyes (Fig. 78).
- 3 . A complete fracture at the Le Fort III level cannot occur without fracture of each zygomatic arch. Coincident independent fracture of one or other zygomatic complex occurs almost invariably. The displacement of the zygomatic complex will be detectable by palpation, which will reveal flattening and a step deformity at the infra-orbital margin. The arch of the zygoma will exhibit tenderness and some deformity in a pure Le Fort III fracture.
- 4 . If a finger and thumb are placed over the frontonasal suture region, and the dento-alveolar portion of the upper jaw is grasped with the other hand, movement of the entire face can be demonstrated. As mentioned previously the zygomatic bones may often be independently mobile.
- 5 . Intra-orally there is gagging of the occlusion in the molar area, as in other fractures of the mid-face. When lateral displacement has taken place, the molar teeth will be found to be gagged

on one side only with a posterior open bite on the opposite side, and deviation of the upper midline. The entire occlusal plane may have dropped, holding the mandible open, a dramatic but rather unusual finding.

6. A very loose Le Fort III fracture is usually associated with disruption of the cribriform plate area, and this type of fracture may therefore produce a profuse cerebrospinal fluid rhinorrhoea. In this situation the possibility of an intracranial aerocele must be considered seriously, and serial radiographs of the skull should be taken during the first few days after injury.

Unilateral Le Fort I, II and III-type fractures

It is possible for a unilateral fracture of the mid-facial skeleton to occur, which may be of the Le Fort I, II or III variety. The physical signs are similar to those already described but they are, of course, only present on one side.

Many combinations of fracture patterns may be present. For example, there may be a fractured zygomatic complex associated with a Le Fort I fracture, or a Le Fort I fracture with unilateral Le Fort II fracture, or Le Fort III, II and I fractures with midline palatal split and fracture of one or both zygomatic complexes. If the clinical features of each individual fracture are understood, it should be possible to determine what combination has occurred in an individual patient.

CRANIOFACIAL FRACTURES

In 1977 Matras and Kuderna pointed out that the rising number of road traffic accidents had added to the incidence of unusual combinations of facial fractures. Among these the frontomaxillary fracture as described by Pape (1969) is the most severe. Such fractures often extend from the anterior base of the skull to the mandible, thus involving the facial skeleton in the upper, lower and mid-facial regions. Cantore *et al.* (1979) reported that of 387 acute head injuries admitted to their neurosurgical unit during a 3-year period, 8 per cent had cranio-orbito-facial fractures.

There is both an increase in the incidence of these craniofacial fractures together with an improved chance of survival. Extensive disruption of the anterior cranial fossa, often involving the posterior wall of the frontal sinuses, means that reconstruction must be undertaken in a hospital equipped for craniofacial surgery. No maxillofacial injury can be treated in isolation from a coexistent cranial component, not only because of the need to treat the cranial injury but also because the displacement of the frontal bones, particularly the orbital roofs, prevents correct repositioning of the facial skeleton.

DIAGNOSTIC IMAGING

SPECIFIC IMAGING FOR FACIAL BONE FRACTURES

Fractures of the mandible

The treatment plan for fractures of the mandible is very dependent on precise radiological diagnosis. It is, for example, most important to know the exact relationship of teeth to a fracture line; to know accurately whether a fracture of the condyle involves the joint space; or to determine the presence or otherwise of comminution of the lower border of the body of the mandible when deciding whether or not to insert a plate or transosseous wire.

Panoral tomography

Equipment for panoral tomography of the mandible has now become standard in all maxillofacial departments and most patients with mandibular fractures are sufficiently mobile to be placed in the machine. Apparatus has been developed for producing these important diagnostic films in a modified unit which allows the radiograph to be taken with the patient lying down.

Panoral tomograms represent the best single overall view of the mandible and are especially valuable for demonstrating fractures in the condylar region. The combination of a postero-anterior (PA) view and a panoral tomogram obviates the need for further radiographs and significantly reduces the overall radiation dose to the patient (Ching and Hase, 1987).

In the unlikely event that panoral tomography is unavailable, left and right oblique lateral views in combination with a rotated PA projection can be substituted.

Postero-anterior (PA) projection

The projection demonstrates fractures of the body and angle together with the type of displacement. It is difficult to see the undisplaced condylar head in a normal postero-anterior view as it is obscured by superimposition of the mastoid process. For this reason the standard 30° antero-posterior Townes projection has been used. This view demonstrates the condylar region very well along with the posterior fossa of the skull. In order to avoid changing the position of the patient, a reverse Townes projection may be used to achieve the same effect. The central ray is angled at 30° to the normal postero-anterior projection, which throws the shadow of the condylar head clear of the dense bony structures of the base of the skull.

Both the panoramic and PA projections may show the symphysis region poorly, and if a fracture is suspected in this area, a supplemental occlusal view may be needed.

Intra-oral

1. Periapical films are required to demonstrate the relationship of teeth to the line of fracture and any damage to the teeth themselves.

2. Occlusal films across the fracture line help to evaluate the relationship of a tooth root to the fracture. They are also invaluable for demonstrating midline fractures of the body of the mandible with minimal displacement.

Temporo-mandibular joint (TMJ) injury *Standard linear tomography*

In the acute management of a patient with suspected TMJ injury, tomography (other than panoramic tomography) is seldom required. The PA projection and a panoramic radiograph, examined carefully, will provide adequate information in the majority of cases.

Computed tomography and magnetic resonance imaging

CT axial scans have proved invaluable in the assessment of complex facial trauma, especially that of the upper mid-facial region. They offer very little advantage as a diagnostic tool in the lower third of the face and are not justified for isolated mandibular fractures on either clinical or economic grounds. It should, however, be noted that these techniques will demonstrate some details of temporo-mandibular joint injury, such as an undisplaced vertical fracture of the condylar head, which are not shown on standard radiographs. With MRI it is possible to demonstrate the meniscus within the temporo-mandibular joint, to measure displacement or damage, and to assess the presence of effusions. This may well have important implications for future treatment of injuries of the craniomandibular articulation.

Fractures of the mid-face

The imaging required to obtain a detailed picture of a mid-facial fracture needs to be balanced against the benefits to actual treatment. In the tooth-bearing part of the maxillae separation at the Le Fort I level is often a clinical diagnosis. Intraoral films may, however, be most valuable in localizing alveolar fractures or a midline split of the palate, injuries which materially influence a treatment plan.

For higher level Le Fort II and III fractures, it is important to determine the overall fracture pattern and particularly the degree of cranial involvement. When there is comminution and displacement in the naso-ethmoid region or extensive damage to the orbital integrity, the clinician needs the detailed information provided by CT in order to plan the reconstruction. It is very important to obtain accurate reduction and fixation of these fractures at the acute stage when optimal results can be achieved.

Le Fort pattern fractures *True lateral projection*

Le Fort fractures at each level can be detected on this view where the fracture line passes across the pterygoid plates. It is often the only plain film which clearly demonstrates a Le Fort I

fracture. It also aids recognition and assessment of any extension of fractures into the boundaries of the frontal sinus.

Occipitomenal projection

Two occipitomenal projections are desirable, one with the tube angled at 10° and one at 30°. These projections demonstrate most mid-facial fractures (both central and lateral) with sufficient detail to determine a treatment plan. Fractures are only clearly visible where bone is thick, or where thin bone plates lie at a tangent to the X-ray beam. The films need to be examined systematically along lines where bone dys-junction can be expected to be seen. The four search lines are well described by McGrigor and Campbell (1950) and Campbell (1977), and are frequently referred to as Campbell's lines (Fig. 79a,b). A fifth line, which follows the lower border of the mandible.

Preoperative diagnosis of these types of injuries can only be made with confidence from CT scans (Rowe *et al*, 1981). In this important area modern imaging technology has replaced a 'look and see' approach founded largely on clinical judgement and experience.

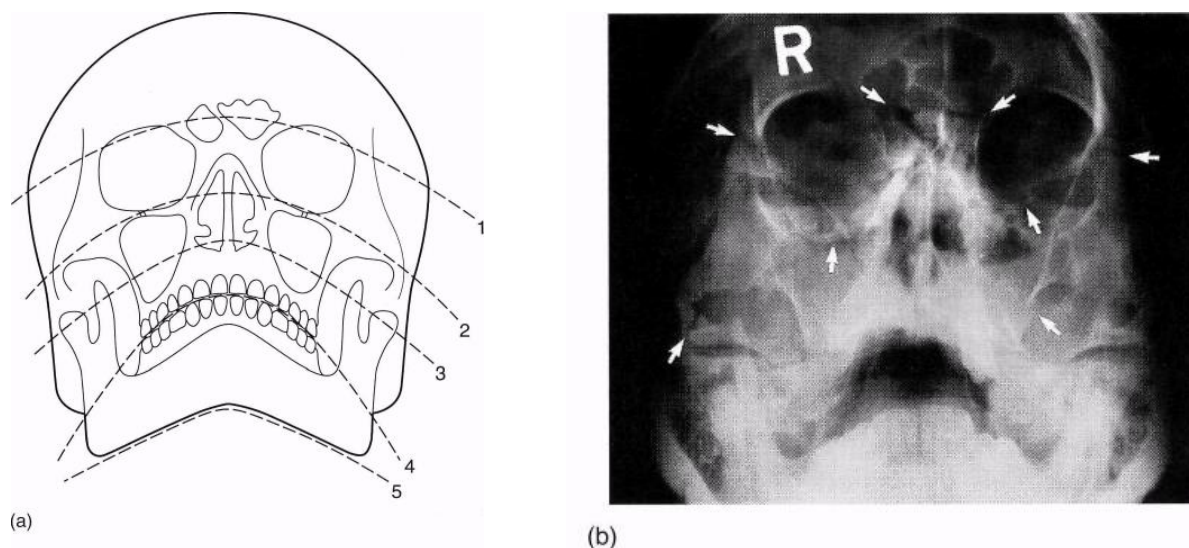


Figure 79. (a) Diagram to show the 'search lines' known as Campbell's lines (1 to 4). Line 5 was described separately by Trapnell. (b) An occipitomenal radiograph of a patient who had sustained fractures of the mid-face at both Le Fort III and Le Fort II level. Fracture sites which lie on Campbell's lines are arrowed. Note that the fracture of the left zygomatic arch is not shown on this particular film.

TREATMENT OF DENTO-ALVEOLAR INJURIES

INTRODUCTION AND CLASSIFICATION

The term 'dento-alveolar injury' describes an injury which is limited to the teeth and supporting structures of the alveolus. As has been mentioned in the section on clinical findings such injuries can occur in isolation or as part of a more serious maxillofacial injury. Isolated dento-alveolar injuries usually follow relatively minor accidents such as falls, or collisions during sport or play. Cycling accidents and minor road traffic accidents are another common cause. Injury to the teeth can sometimes occur during epileptic seizures, and iatrogenic damage may take place during extraction of ankylosed teeth, endoscopy procedures or endotracheal intubation. In addition, the possibility of non-accidental injury should always be considered in younger children.

The majority of patients presenting with isolated dento-alveolar injuries are children or adolescents and, as might be expected, boys are approximately three times more at risk than girls (Hunter *et al.*, 1990; Andreasen and Andreasen, 1994). There is evidence that injury to the teeth is increasingly common despite the emphasis on the use of mouthguards in many sporting activities (Todd and Dodd, 1985; Dewhurst *et al.*, 1998). A significant proportion of dento-alveolar injuries can be treated in the primary dental care setting under local analgesia, particularly where damage is limited to the teeth without alveolar fracture. Unfortunately surveys have found that an adequate level of knowledge and expertise in dental practice is often lacking, and even in the hospital setting the management of the dental injury is all too often less than ideal.

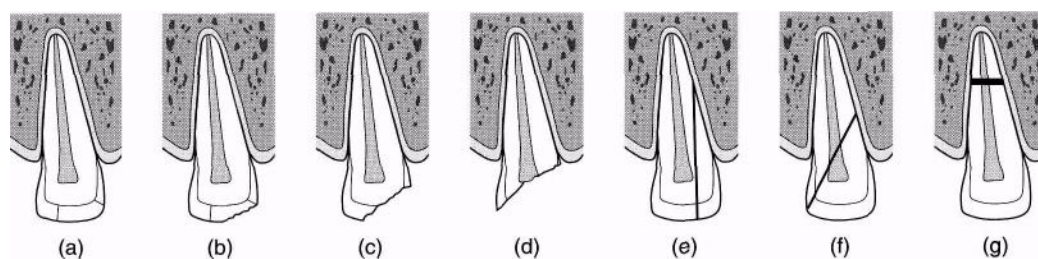


Figure 80. Diagram of injuries to the hard dental tissues and pulp, (a) Crown infraction, (b) Enamel fracture, (c) Enamel + dentine fracture, (d) Enamel + dentine + pulp fracture, (e) Vertical crown-root fracture, (f) Oblique crown-root fracture, (g) Root fracture

Table 1. Classification of dento-alveolar injuries. (Modified from Andreasen and Andreasen, 1994; Sowray, 1994 and Dimitroulis and Avery, 1994)

1. *Dental hard tissue injury* (Fig. 80)

- (a) Crown infraction (crack of enamel or incomplete fracture)
- (b) Crown fracture - enamel only
- (c) Crown fracture - enamel + dentine
- (d) Crown fracture - enamel + dentine + pulp
- (e) Crown-root fracture (vertical fracture)
- (f) Crown-root fracture (oblique fracture)

(g) Root fracture

2. Periodontal injury (Fig. 81)

(a) Concussion (no displacement of tooth but tender to percussion)

(b) Subluxation (loosening of tooth without displacement)

(c) Intrusion

(d) Extrusion

(e) Lateral luxation (loosening of tooth with displacement)

(f) Avulsion

3. Alveolar bone injury (Fig. 82)

(a) Intrusion of tooth with comminution of socket

(b) Fracture of single wall of socket or alveolus

(c) Fracture of both walls of socket or alveolus

(d) Fracture of mandible or maxilla involving the alveolus and/or tooth socket

4. Gingival injury

(a) Contusion

(b) Abrasion

(c) Laceration

5. Combinations of the above

A comprehensive classification of dento-alveolar injuries and full details of the management of damaged teeth are outside the scope of this book. Specialist texts on the subject should be consulted for further information (Andreasen and Andreasen, 1994; Roberts and Longhurst, 1996). Table 1 lists the possible components and complexity of a dento-alveolar injury.

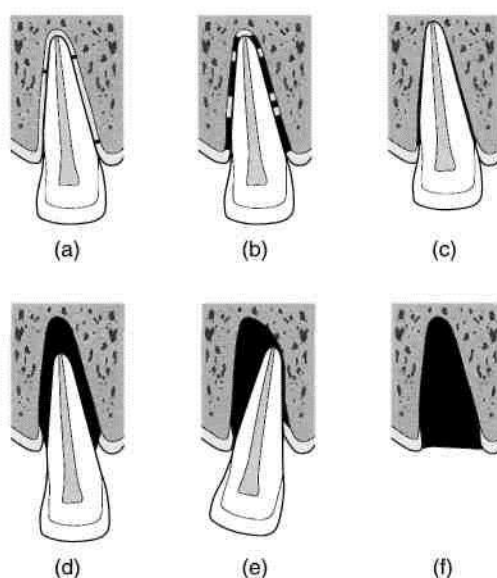


Figure 81. Diagram of injuries involving the periodontal tissues, (a) Concussion, (b) Subluxation, (c) Intrusion, (d) Extrusion, (e) Lateral luxation, (f) Avulsion.

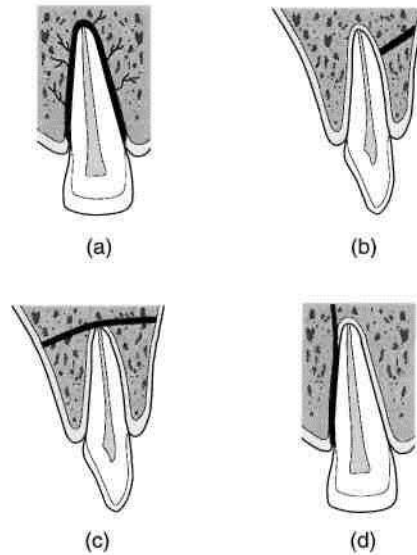


Figure 82. Diagram of injuries involving the alveolar bone, (a) Comminution of the socket, (b) Fracture of single socket wall, (c) Fracture of both socket walls or alveolus, (d) Fracture of jaw involving socket.

Table 2. Clinical findings following different types of dento-alveolar injury.

<i>Type of injury</i>	<i>Pattern of injury</i>
(a) Force distributed over several teeth, or impact cushioned by overlying soft tissues	Concussion Subluxation Lateral luxation Intrusion Alveolar segmental fracture
(b) Direct force to teeth	Crown fracture Root fracture Displacement of teeth or avulsion Penetrating lip wounds
(c) Indirect force to teeth (e.g. axial blow to chin)	Crown - root fracture (vertical split) Possible associated jaw fracture (including split maxilla)

The pattern and complexity of a dento-alveolar injury depend on a number of factors. These include the site and energy of impact, the strength of the teeth, the resilience of the periodontal structures and the elasticity of the alveolar bone. The latter two factors in particular are also related to the age of the patient. Single or multiple teeth can be damaged individually, or a complete segment of alveolar bone can be fractured with relatively little.

CLINICAL ASSESSMENT

An important point to reiterate is that urgent treatment is necessary if a tooth is to be saved following partial or complete avulsion. Similarly, any obvious or suspected exposure of the dental

pulp will require early treatment for relief of pain and the best prognosis. Dento-alveolar injuries are among the very few fractures of the facial skeleton where immediate treatment is important. Not only does delay affect the ultimate prognosis of individual teeth, it may also prolong the patient's pain and discomfort after injury. Whereas simple jaw fractures are rarely very painful, injuries to vital teeth can cause severe pain and alveolar fractures may often result in painful interference with the occlusion.

When a dento-alveolar fracture occurs in isolation the injury is easily recognized and effective treatment is usually offered. However, when damage to individual teeth is part of a more extensive facial injury the importance of early intervention may be forgotten, even when it could easily be accomplished under local analgesia. The treatment of dento-alveolar injuries should have the same priority as the treatment of facial lacerations. Simple measures such as repositioning of displaced teeth and protection of the pulp are sometimes overlooked in the initial management of a complex facial injury. In an unconscious multiply injured patient requiring endotracheal intubation the dental injuries may seem a trivial problem, and even go unrecognized, but stabilization of any loose teeth or alveolar segments will minimize difficulties in positioning the tube and prevent further dental damage. Similarly, covering or extirpating the exposed dental pulp will reduce the painful stimuli which can contribute to restlessness in the unconscious patient.

A thorough clinical assessment of the dentition requires a good inspection light, adequate retraction of the lips and cheeks, a fine-tipped sucker, the use of a dental mirror and probe, and a co-operative patient. These conditions are normally achievable with a conscious adult but in the case of a distressed young child full assessment may have to await the administration of a general anaesthetic. The most difficult injuries to diagnose clinically are stable root fractures and vertical crack fractures of the crowns of posterior teeth. In this situation the examination should include percussion of the teeth, careful probing of the crown and asking the patient to bite gently on a wooden spatula.

The radiographic examination of dento-alveolar injuries must include occlusal or peri-apical dental radiographs. With the advent of panoramic tomography these views are less used than they should be in the diagnosis of maxillo-facial trauma but full assessment of injuries to the teeth is impossible without them.

TREATMENT

Several factors have to be taken into consideration in the treatment of dento-alveolar injuries. The relative importance of preserving damaged teeth will vary according to the complexity of the maxillofacial injury, the age of the patient, the general dental condition including crowding, the site of the dento-alveolar injury and the wishes of the patient. The prognosis of traumatized teeth and the healing of alveolar fractures are generally better in younger patients. Open root apices,

intact gingival tissues, absence of root fractures and good periodontal bone support are all clinical conditions which are indicative of a good outcome.

In the deciduous dentition the pattern of injury differs from adolescents and adults because the elasticity and thinness of the alveolar bone usually protects against fracture of the tooth. Segmental fractures of the alveolus are extremely rare for the same reason. The more complex dento-alveolar injuries normally affect the permanent dentition and in planning treatment it is convenient to consider each component in turn (see classification in Table 5.1). These range from a small chip of a cusp or incisal edge to multiple broken and displaced teeth with an associated fracture of the supporting alveolus.

Injuries to the primary dentition

Seventy per cent of injuries to the primary dentition involve the maxillary central incisors (Galea, 1984). Intrusion and lateral luxation are the commonest injury (Mackie and Warren, 1988) with avulsion occurring in approximately 10 per cent of cases (Fountain and Camp, 1991). Generally speaking fractured, extruded or grossly displaced teeth should be extracted. Less displaced teeth that do not cause occlusal interference can be left and monitored. Damage to the underlying developing permanent tooth by displaced teeth is a recognized problem, particularly with intrusion injuries. This has been shown to occur in 25-70 per cent of cases (Von Arx, 1997). Intruded primary teeth will normally erupt spontaneously and extraction simply increases the risk of further damage to underlying teeth.

Injuries affecting the permanent dentition

Injuries to the dental hard tissue Crown fracture

A simple fracture of only the enamel does not require emergency treatment but exposure of the underlying dentine should be covered as soon as possible, particularly in young people where bacterial penetration of the open dentinal tubules can be rapid (Lundy and Stanley, 1969). Protection with a calcium hydroxide cement held in place with a temporary acid-etch composite dressing is ideal until a definitive restoration can be undertaken. Providing it is large enough, consideration can be given to restoring the fractured crown by cementing the fragment with composite resin. Pulp testing immediately after injury is of no clinical value, but the tooth must be carefully followed up and root-treated later if necessary.

If the pulp is exposed it is not only exquisitely painful to touch and thermal stimuli but will also eventually necrose. Small exposures treated early can be managed as above and monitored, but larger exposures or delays in treatment will require a minimal pulpolomy and calcium hydroxide dressing if the apex is still open, or pulp extirpation if the apex is closed.

Root fracture

An oblique fracture of the crown may extend subgingivally (crown-root fracture). In this situation a decision has to be taken about the possibility of saving the tooth following the same emergency methods described above. If the fracture extends a considerable way down the root, or if there is a vertical split, extraction is inevitable.

Transverse fractures of the root usually affect the incisor teeth and the prognosis depends to a large extent on the level of fracture. A calcified or fibrous bridge occasionally results in 'healing' of the root, particularly if the fracture is in the apical third, but fractures that lie near the gingival level have a poorer prognosis. If the tooth is to be conserved it should be held in a rigid splint for at least 8 weeks. The teeth can be immobilized by bonding to adjacent teeth with acid-etch composite, or a wire and acid-etch composite splint can be applied.

Pulp necrosis, root resorption and obliteration of the pulp canal are common consequences of root fracture, occurring in up to 60 per cent of cases.

In fractures that lie close to the gingival margin the tooth can still be restored. The loose coronal fragment should be removed and the root devitalized. Following endodontic treatment the root can be orthodontically extruded or a crown-lengthening procedure carried out according to circumstances. This will allow a definitive restoration with a post crown.

Injuries to the periodontal tissues

Luxation

Pulpal haemorrhage can occur following simple concussion of a tooth (Fig. 83) and any loosening or displacement carries a high risk of subsequent pulp necrosis, particularly following intrusion injuries (Fig. 84). As with root fractures additional late complications include root resorption, pulp canal obliteration, ankylosis and loss of marginal bone support.

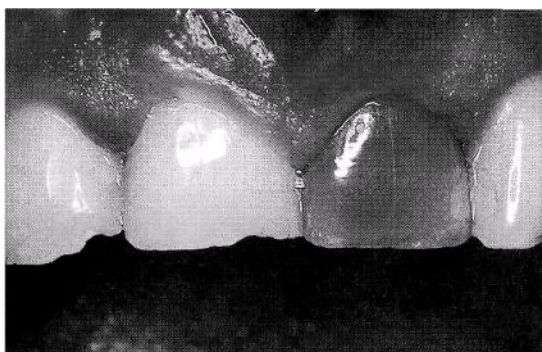


Figure 83. Acute pulpal haemorrhage causing discoloration of concussed upper left central incisor.

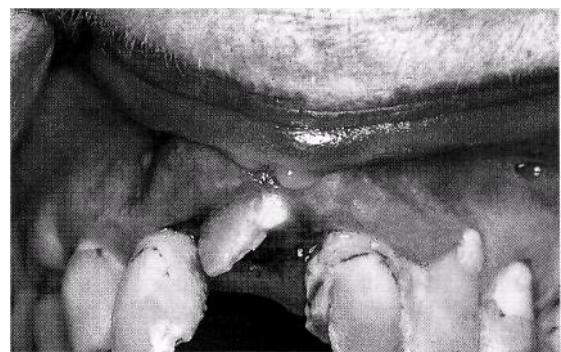


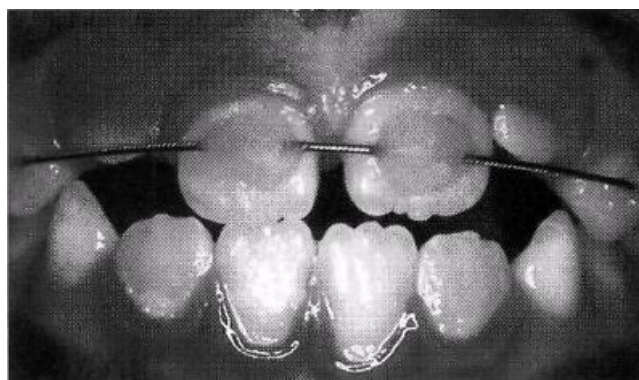
Figure 84. Severely intruded upper right central incisor. This injury carries a poor prognosis and almost invariably leads to pulp necrosis.

Teeth that have been loosened, laterally luxated, or extruded should be manipulated back into position and splinted for 7-21 days (see Table 3). The older methods of fixation such as

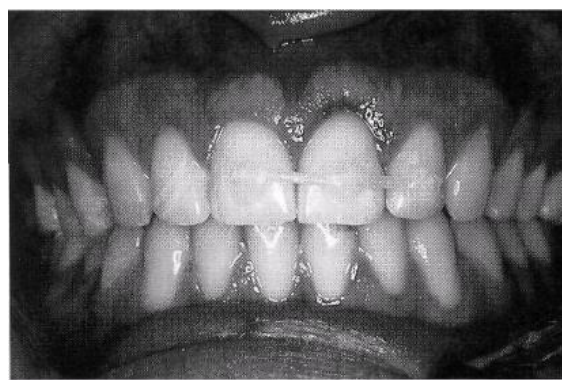temporary foil splints or cast cap splints have been replaced by acid-etch composite techniques in which a piece of heavy wire or light arch bar is bonded to the damaged tooth and adjacent sound teeth (Fig. 85a). Lighter or flexible orthodontic wire, or even a length of heavy nylon suture, can be used if a semirigid splint is needed (Fig. 85b).

Table 3. Types of splint and duration of treatment in dento-alveolar injuries.

<i>Injury</i>	<i>Splint</i>	<i>Duration of splinting</i>
Root fracture	Rigid	8 weeks minimum 7-
Extrusion	Semi-rigid	10 days 2-3 weeks 7-
Lateral luxation	Semi-rigid	10 days
Avulsion	Semi-rigid	4-6 weeks 4-6 weeks
Alveolar fracture Block segment of teeth Fracture of labial/lingual plate	Rigid Semi- rigid	



(a)



(b)

Figure 85. (a) Wire-reinforced composite splint used to immobilize previously luxated upper central incisor, (b) Use of a reinforced semi-rigid material as an alternative to wire, again used to splint a previously subluxed upper central incisor.

Soft stainless-steel wire can be used to construct a splint without the help of composite material. A loop of wire is passed around a group of teeth, incorporating one or two teeth either side of the subluxed teeth. Individual tie wires are then passed interdentally and tightened to take up the slack in the loop and immobilize the loose teeth (Fig. 86).

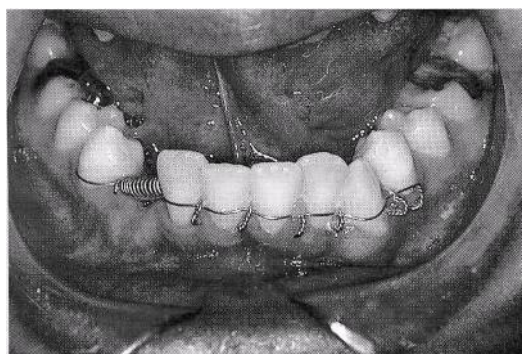

Figure 86. Subluxed lower central incisors treated by a simple soft wire loop splint and interdental tie wires. The splint has been reinforced in the edentulous space by winding wire round the buccal and lingual aspects of the loop wire.

Simple splints for subluxed teeth or alveolar fractures can be rapidly constructed from vacuum-formed plastic (extruded butyrate sheet, May & Baker Ltd.). An impression is taken following repositioning of the tooth or alveolar fragment. If necessary the affected teeth are relieved on the model, and the thin plastic veneer vacuum-formed on the press in the laboratory (Fig. 87). The splint is usually fixed with a zinc oxide-based cement or self-cure acrylic resin, although individually chipped or fractured teeth should be covered with calcium hydroxide as described above. The whole procedure can be completed on an outpatient basis within 1 hour if the laboratory is on site, and with a minimum of discomfort to the patient. A criticism of this type of splint, as well as for interdental wiring techniques, is that oral hygiene may be compromised leading to gingival inflammation and interference with healing of the traumatized tissues.

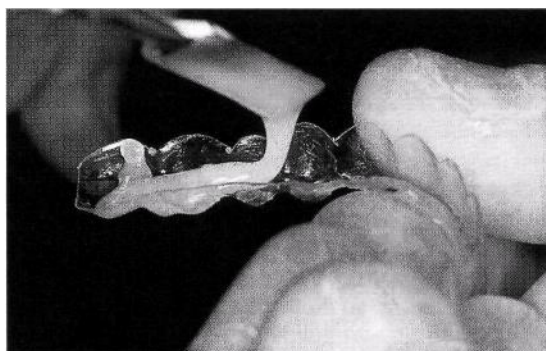


Figure 87. Thin vacuum-formed plastic splint being filled with cold-cure acrylic resin prior to cementation for stabilization of loose or avulsed teeth.

Avulsion

A number of factors will influence the chance of success following replantation of an avulsed tooth. These include the stage of root development, the length of time the tooth is allowed to dry, the length of wet storage and the medium used, and correct handling and splinting (Andreasen *et al.*, 1995). Immediate replacement is still the ideal treatment. The root should not be handled, to avoid damage to the periodontal ligament cells, but this is a counsel of perfection in the acute situation where the tooth may have to be retrieved from a playground or sports field! Debris should be removed by gentle rinsing for a few seconds under running cold water. Once the tooth is replaced the patient should bite gently on a handkerchief or gauze and an emergency appointment should be made with a dental surgeon for semi-rigid splinting.

If the tooth cannot be replanted immediately it is important to ensure that the cells of the periodontal ligament do not dry out. Survival out of the mouth is possible for up to 30 minutes but few cells will retain any vitality after 60 minutes. Blomhof (1981) has shown that periodontal cells will retain their vitality for 2 hours in the patient's saliva and 6 hours in fresh milk. Water is a harmful storage medium due to osmotic lysis of the cells. As soon as possible the socket should be irrigated with warm saline to clear any clot or debris. Curettage of the socket should be avoided because it is associated with increased resorption. The tooth is held by the crown and the root gently

irrigated to wash off the storage medium. It is then firmly replanted in the socket. The alveolus should be compressed to reduce any fracture of the socket wall. A semi-rigid splint is applied for 7-14 days and a course of antibiotics prescribed. Even if the eventual outlook is poor it is still worth attempting to save a tooth in the short term since this will help alveolar healing and will retain alveolar bone in the area, an important factor if an implant is to be considered at a later date.

Injuries to the alveolar bone

Alveolar fractures involving a block of alveolar bone, or sometimes the labial and lingual socket walls, usually occur in the anterior or premolar region. The commonest posterior fracture is an iatrogenic fracture of the maxillary tuberosity, which may complicate the extraction of upper molar teeth. As with other facial fractures the treatment of displaced alveolar fractures involves reduction and fixation. Closed reduction of the alveolar segment is usually achieved by finger manipulation and a suitable splint is then applied. Care needs to be taken to avoid displacing loose teeth during the reduction, and any splint used must extend to enough sound teeth to achieve satisfactory immobilization. Open reduction is rarely performed in alveolar fractures unless access is possible as part of the treatment of an underlying jaw fracture.

A rigid wire and composite splint is effective in the anterior region but is more difficult to apply in the posterior maxillary arch. Arch bars and interdental wiring have the drawback of being more traumatic to the gingival tissues and there is a real risk of avulsing loose teeth as the wires are tightened. The individual teeth in the alveolar fragment need to be examined carefully and treated appropriately if damaged. A minor problem with isolated displaced alveolar fractures is that it is sometimes difficult to avoid leaving the teeth slightly 'high' after reduction. This results in premature contact and continuing trauma to the teeth. The occlusion needs to be checked carefully and the bite adjusted if necessary. Occasionally a short period of intermaxillary fixation is a sensible precaution, particularly if the fragment is very mobile.

Comminuted fractures of the alveolus in the incisor area, with or without comminution of associated teeth, usually necessitate the removal of the portions of teeth and alveolus and careful soft-tissue repair of the resulting alveolar defect. The operator should preserve any portions of alveolus which appear to have a chance of survival. Lacerated wounds in the lip should be carefully explored, and any fragments of teeth removed. The edges of the wound are then trimmed if necessary and closure carried out.

Extraction of damaged teeth from a block of fractured alveolus should be avoided if at all possible. Unless a careful surgical technique is used there is a significant risk of tearing the mucosal attachment and avulsing the whole segment. Ideally any extractions of teeth or roots should be delayed for 6-8 weeks when bone healing will be advanced and the mucoperiosteal tissues healthy.

This principle extends to fractures of the tuberosity. This complication occurs because of ankylosis or root bulbosity affecting the maxillary molar teeth. The thin supporting alveolar bone and antral floor fractures on attempted forceps extraction. The operator becomes aware that a whole dento-alveolar block extending to the tuberosity is mobile on moving the tooth. On occasion the palatal mucoperiosteum tears longitudinally as a result of the forcible buccal movement with the extraction forceps. If the tuberosity is completely detached from the periosteum it should be carefully dissected out and the resulting soft-tissue defect sutured to prevent any residual opening into the maxillary sinus.

If the tuberosity, with or without associated teeth, appears to be well attached to the periosteum, it can be left alone with or without splinting. Splinting of a tooth left attached to the fragment and immobilizing it to other standing teeth in the maxilla for 1 month usually results in union. This can be achieved sometimes with a wire and composite splint, but an alternative is to take an impression for a full-coverage palatal acrylic plate extending around the palatal surfaces of the affected teeth. This can be retained by Adams cribs, including one or more on the mobile segment.

If the tooth in the tuberosity fragment requires extraction it should be removed surgically by drilling away the surrounding bone after the tuberosity is firm. If the tooth is painful, this surgical extraction must be carried out earlier, but the chance of saving the tuberosity in such circumstances is greatly reduced.

Fractures extending to the alveolar floor of the maxillary sinus are treated in the same way, depending upon whether the alveolar fragment, together with any associated teeth, is completely detached from the periosteum.

If the alveolus and floor of the antrum are inadvertently removed during the extraction of a tooth a very careful soft-tissue repair of the defect must be carried out immediately, if necessary by advancing a buccal flap. The patient should be given nasal drops of ephedrine 0.5 per cent to help antral drainage and an antibiotic for 5 days to prevent infection leading to breakdown and development of an oro-antral fistula.

Injuries to the gingival tissues

Gingival damage is obviously associated with most dento-alveolar injuries. The maintenance of good gingival health is important for uncomplicated healing, and will improve the outcome for replanted or replaced teeth. Chlorhexidine mouthwash should be prescribed in the postoperative period.

Displacement of teeth or a block of alveolar bone commonly results in small vertical gingival lacerations. These usually heal well following reduction of the fracture and rarely need suturing. If a piece of bone becomes denuded because of stripping of the gingival mucoperiosteum a

decision has to be taken regarding the advisability of retaining the bone and risking infection or removing it with a loss of alveolar support.

A common gingival injury which may be associated with injuries to the lower anterior teeth is a laceration in the lower buccal sulcus with 'degloving' of the mental region of the mandible. This results from a sliding fall. The separation occurs at a suprapariosteal level and the mental nerves may even be exposed by the injury in severe cases. It is not unusual to find debris or road dirt in the depths of the wound and in this situation copious lavage with warm saline should be performed.

TREATMENT OF FRACTURES OF THE MANDIBLE

FRACTURES OF THE TOOTH-BEARING SECTION OF THE MANDIBLE

Reduction

Reduction of a fracture means the restoration of a functional alignment of the bone fragments. In certain situations, for example a fracture of the clavicle, this does not necessarily imply exact anatomical alignment. However, in the dentate mandible reduction must be anatomically precise when teeth, which were previously in good occlusion, are involved. Less precise reduction may be acceptable if part of the body of the mandible is edentulous or there are no opposing teeth.

The presence of teeth provides an accurate guide in most cases by which the related bony fragments can be aligned. The teeth are used to assist the reduction, check alignment of the fragments and assist in the immobilization.

Whenever the occlusion is used as an index of accurate reduction it is important to recognize any pre-existing occlusal abnormalities such as an anterior or lateral open bite. Wear facets on individual teeth can provide valuable clues to previous contact areas. Teeth may on occasions be brought into contact during reduction and yet be occluding incorrectly owing to lingual inclination of the fracture segment.

Widely displaced, multiple or extensively comminuted fractures may be impossible to reduce by means of manipulation of the teeth alone, in which case open operative exploration becomes necessary.

In general, reduction and later immobilization is best effected under general anaesthetic, but occasionally it is possible to employ local analgesia supplemented if necessary by sedation. If there is minimal displacement the reduction can sometimes be effected without an anaesthetic.

If the patient's general medical condition precludes the administration of a general anaesthetic, gradual reduction of fractures can sometimes be carried out by elastic traction. Small elastic bands are applied to cap splints or wires fitted to teeth on the individual mandibular fragments and attached in turn to the intact maxilla. More often nowadays, modified orthodontic brackets are

cemented to selected teeth to which elastic bands can in turn be attached. A satisfactory temporary reduction can usually be achieved pending an improvement in the patient's general condition.

Teeth in the fracture line

Teeth in the fracture line are a potential impediment to healing for the following reasons:

1. The fracture is compound into the mouth via the opened periodontal membrane.
2. The tooth may be damaged structurally or lose its blood supply as a result of the trauma so that the pulp subsequently becomes necrotic.
3. The tooth may be affected by some preexisting pathological process, such as an apical granuloma.

The fracture line can become infected as a result of any of the above - either from the oral cavity via the disrupted periodontium or directly from an infected pulp or apical granuloma. Infection of the fracture line will result in greatly protracted healing of the fracture or even nonunion.

For these reasons in pre-antibiotic days all teeth in the line of the fracture were extracted. This practice was, however, continued into the antibiotic era with unnecessary detriment to the patient. A tooth in the line of fracture which is structurally undamaged, potentially functional, and not subluxed should be retained and antibiotics administered. Its retention will tend to delay clinical union of the fracture by a short period, but this is acceptable in order to preserve the integrity of the dentition. Obviously teeth in an intact dentition are more important than those in a partially edentulous jaw.

Without antibiotic therapy teeth in the line of fracture constitute a real risk of infection. As recently as 1978 Neal and co-workers reported a complication rate of 30 per cent in a retrospective study of 207 mandibular fractures, where the average delay in treatment was 3-4 days, and the patients were generally from deprived social backgrounds and uncooperative (Neal *et al.*, 1978). Thirty-six infections of the fracture site occurred, the incidence interestingly being unrelated to whether the involved tooth was removed at the time of treatment or after the complications had ensued. The subsequent literature supports the observation that infection is almost invariably associated with teeth in the fracture line but the incidence is not affected by early removal (Anderson and Alpert 1992; Ellis and Sinn 1993).

In general the infection rate of mandibular fractures which involve teeth is much lower - around 5 per cent (James *et al.*, 1981). Kahnberg (1979) and Kahnberg and Ridell (1979), in a study of 185 teeth involved in the line of mandibular fractures, have shown that the prognosis of the teeth they elected to conserve was good. Complete clinical and radiographic recovery was found in 59 per cent, a figure similar to other studies. Careful follow-up of the retained teeth was necessary so that endodontic therapy could be instituted as soon as there were clinical indications. In Kahnberg and Ridell's study 32 of the 185 involved teeth were extracted, 20 of which became necessary after

initial fixation of the fracture because of loosening of the teeth or infection of the fracture site. Kamboozia and Punnia-Moorthy (1993) found that there were significantly more devitalized teeth in the line of mandibular fractures treated by plated osteosynthesis.

Fractures at the angle of the mandible with teeth in the fracture line are more likely to become infected than at other sites (Ellis, 1999). Considerable controversy therefore exists with regard to functionless third molars involved in mandibular fractures. These teeth are a potential source of infection and, if left, will eventually need to be removed. They have little value in stabilizing the fracture which, if undisplaced, is retained in line by the attached periosteum. Furthermore, such a tooth will never be more easy to remove, because the fracture effectively disimpacts it and as a result it can be elevated with minimal disturbance of bone and periosteum. On balance it would seem more sensible to remove a functionless, potentially troublesome tooth when an operative intervention has become necessary by virtue of the fracture.

Summary

Absolute indications for removal of a tooth from a mandibular fracture line:

1. Longitudinal fracture involving the root.
2. Dislocation or subluxation of the tooth from its socket.
3. Presence of periapical infection.
4. Infected fracture line.
5. Acute pericoronitis.

Relative indications for removal of a tooth from the fracture line:

1. Functionless tooth which would eventually be removed.
2. Advanced caries.
3. Advanced periodontal disease.
4. Doubtful teeth which could be added to existing dentures.
5. Teeth involved in untreated fractures presenting more than 3 days after injury. It is desirable that all teeth not covered by these conditions should be retained.

Management of teeth retained in fracture line:

1. Good-quality intra-oral periapical radiograph.
2. Institution of appropriate systemic antibiotic therapy.
3. Splinting of tooth if mobile.
4. Endodontic therapy if pulp is exposed.
5. Immediate extraction if fracture becomes infected/
6. Follow-up for 1 year and endodontic therapy if there is demonstrable loss of vitality.

Immobilization

Following accurate reduction of the fragments, the fracture site must be immobilized to allow bone healing to occur. Orthopaedic surgeons have been concerned for some time with the process of fracture healing when either rigid or semi-rigid fixation is employed. The speed of repair of the weight-bearing skeleton is of paramount importance in the eventual rehabilitation of an injured patient. When semi-rigid fixation is used a fracture heals by secondary intention, which involves the formation and subsequent organization of callus. This is a relatively slow process and weight-bearing must be delayed until full bone replacement has occurred. Even apparently rigid fixation by means of non-compression plating or pinning leaves a gap between the bone ends and bony union requires organization of a primary callus. Key (1932) noted that healing of the arthrodesed knee was accelerated when the opposing bony surfaces were compressed. Later experimental work (Perren *et al.*, 1969) has confirmed that compression osteosynthesis of both experimental osteotomies and clinical fractures results in primary bone healing without the formation of intermediate callus. This results in more rapid stabilization of the fracture site and much earlier restoration of the mechanical strength of the bone. Reitzik and Schoorl (1983) compared non-compression screw and plate osteosynthesis and wired osteosynthesis on either side of the same mandible. Although non-compression plated osteotomies resulted in gap healing with the formation of a small amount of intermediate callus, this was still superior to the less rigid wired osteosynthesis with demonstrably increased mechanical strength on the plated side 6 weeks after surgery. The question arises as to how relevant are these findings to the treatment of mandibular fractures. Unlike a weight-bearing bone, it is only necessary to immobilize the mandible until a stable relationship between the fragments has been achieved. This period is considerably less than would be required for full bony consolidation to take place. Some simple mandibular fractures need no immobilization at all, particularly if a lack of teeth means that precise restoration of the occlusion is not at a premium. Such fractures remain mobile for some time if they are forcibly manipulated but eventually proceed to full bony union. It is indeed difficult to prevent the fractured mandible uniting, and malunion is a more frequent complication than non-union.

Infection of a fracture line prior to definitive treatment has traditionally been regarded as a contraindication to any form of direct skeletal fixation. Indeed at one time it was considered inadvisable to insert a transosseous wire if the fracture was compound into the mouth, because of the risk of subsequent infection. However, with the routine employment of prophylactic antibiotic cover, this risk is very considerably reduced. James *et al.* (1981), in a prospective study of 422 mandibular fractures, concluded that the postoperative infection rate of the fracture line was no different whether closed or open techniques were employed. Awty and Banks (1971) and Banks (1985) showed that trans-osseous wiring could be regularly and safely employed in heavily

contaminated gunshot wounds. There is some evidence that rigid fixation of previously infected fractures by plates produces better results in terms of uncomplicated healing than traditional methods (Kai Tu and Tenbulzen, 1985).

The overwhelming advantage of plating techniques is that they are all sufficiently rigid to obviate the need for intermaxillary fixation. However, in view of the fact that clinical union of mandibular fractures is much quicker than most other bones, compression osteosynthesis must have a very dubious place in any treatment plan.

Period of immobilization

Whenever IMF is used as the main or adjunctive means of immobilizing a fractured mandible, the clinician needs some guide to the length of time it must be kept in place. The period of stable fixation required to ensure full restoration of function varies according to the site of fracture, the presence or otherwise of retained teeth in the line of fracture, the age of the patient and the presence or absence of infection. Juniper and Awty (1973) have shown that in favourable circumstances stable clinical union can on average regularly be achieved after 3 weeks, at which time fixation can be released.

In fractures of the body of the mandible the blood supply to the fracture site is important to the healing process. Where endosteal vascularity is relatively poor, as in the ageing jaw, and particularly in the symphysis region, healing tends to be prolonged. In contrast, the rich blood supply and exuberant osteoblastic activity of the child's growing mandible ensures extremely rapid union.

A simple guide to the time of immobilization for fractures of the tooth-bearing area of the lower jaw is as follows (3 weeks):

1. Tooth retained in fracture line: add 1 week.
2. Fracture at the symphysis: add 1 week.
3. Age 40 years and over: add 1 or 2 weeks.
4. Children and adolescents: subtract 1 week.

Applying this guide it follows that a fracture of the symphysis in a 40-year-old patient where the tooth in the fracture line is retained requires 6 weeks of immobilization (basic 3 weeks + 1 week for less favourable site + 1 week allowed for age + 1 week for tooth retained in the line of fracture).

Rules such as these are designed for guidance only, and it must be emphasized that the fracture must always be tested clinically before the mandible is finally released. The temporary attachments to the dentition should be retained for a further period so that re-immobilization can be carried out if the union of the fracture is found to be inadequate after function has been restored.

Methods of immobilization

The methods of immobilization can be summarized as follows:

1. Osteosynthesis without intermaxillary fixation:

- a) non-compression small plates;
- b) compression plates;
- c) miniplates;
- d) lag screws;
- e) resorbable plates and screws.

2. Intermaxillary fixation:

- a) bonded brackets;
- b) dental wiring: direct, eyelet;
- c) arch bars;
- d) cap splints.

3. Intermaxillary fixation with osteosynthesis:

- a) transosseous wiring;
- b) circumferential wiring;
- c) external pin fixation;
- d) bone clamps;
- e) transfixation with Kirschner wires.

Osteosynthesis without intermaxillary fixation

This can only regularly be achieved by some form of bone plate although some oblique fractures can be fixed by the application of suitably positioned lag screws. Currently, three main systems of bone plating are used for fixation of mandibular fractures. Small bone plates based on the Swiss AO system (Arbeitsgemeinschaft für Osteosynthese) and the ASIF technique (Association for the Study of Internal Fixation) are designed for compression (Raveh *et al.*, 1987). An example of a small compression plate is shown in Fig. 88, but plates of similar dimensions can equally be of simple non-compression design. The main alternative which has found favour has been the use of miniaturized plates such as those originally used for injuries to the fingers (Hayter and Cawood, 1993) (Fig. 89). All forms of bone plating provide rigid fixation. However, a distinction should be made between semi-rigid plates and compression plates. In the former group a small gap between the bone ends exists which means that a limited amount of primary callus forms, whereas, when compression plates are used, experimental evidence suggests that primary bone healing takes place without the formation of any intermediate callus. It is claimed that the full strength of the bone is thereby restored more rapidly. Each system ensures sufficient rigidity across the fracture site to obviate the need for intermaxillary fixation. This enables the patient to enjoy a

relatively normal diet and to maintain oral hygiene more easily. These conditions are desirable for all mandibular fractures but there are particular clinical indications in certain cases. For example, a fracture of the body of the mandible with a coexistent intracapsular fracture of the condyle may make early mobilization especially important to order to ensure recovery of function of the temporo-mandibular joint. Again, intermaxillary fixation is not well tolerated in some elderly patients and is particularly difficult to maintain in mentally disturbed or subnormal individuals.



Figure 88. A compression bone plate. In this design both of the 'pear'-shaped compression holes are to the left of the fracture line. (Case treated by Mr P. T. Blenkinsopp and reproduced with his kind permission).




Figure 89. (a) A miniaturized plating system based on the original design by Professor M. Champy. The 2 mm and 1.5 mm systems are shown, (b) Individual plate design from the AO miniaturized plating system showing, from above down, pairs of 1 mm microplates, 1.5 mm compact plates, 2.0 mm compact plates and stronger 2 mm mandibular plates.

However, the application of bone plates to the mandible is an exacting technique requiring a fairly long period of general anaesthesia and a considerable degree of surgical skill. Many surgeons routinely still use an extra-oral approach which leaves a scar on the face at the conclusion of treatment. Plating is increasingly carried out from an intra-oral approach but the technique requires special surgical instruments in order to gain access to all areas of the body of the mandible.

Becker (1974) has pointed out that any treatment method which does not rely on intermaxillary fixation must ensure the restoration and maintenance of correct occlusion. In spite of numerous claims to the contrary, bone plates because of their very precision do not always achieve this fundamental objective. The occlusal problem can be overcome in skilled hands. Raveh *et al.* (1987) have reported results in 531 mandibular fractures treated with AO plates followed by immediate mobilization. All cases were operated on via an intra-oral approach and only two cases exhibited mal-occlusion. This group employed a special localization device across the fracture line, which was inserted and adjusted prior to the placement of the plate. In other series, however, up to 25 per cent of cases treated required some adjustment by occlusal grinding, and to avoid this patients treated by plating techniques may need to be placed into intermaxillary fixation for a significant period (Pogrel, 1986). Plates are particularly useful in patients who are either partially or completely edentulous.

The incidence of postoperative infection of bone plates seems to be decreasing and compares favourably with other methods of fixation. Plating may indeed be employed for the elective treatment of infected fractures (Koury *et al.*, 1994) although the incidence of persistent infection postoperatively is higher than in non-infected cases. Some of these improved results can be attributed to greater surgical skill and some to the use of more biocompatible materials. Titanium has now replaced stainless steel and chrome-cobalt alloys for the manufacture of all types of plates. There is no convincing evidence to challenge the biocompatibility of titanium bone plates, nor is there a need for them to be removed electively. Most surgeons throughout the world leave asymptomatic plates in situ (Haug, 1996). Nevertheless, a few plates have to be removed due to later infection (Souyris *et al.*, 1980), and in a number of centres patients are routinely readmitted for elective removal (Alpert and Seligson, 1996).

There are certainly theoretical reasons for removal of metal plates on the grounds that they protect the underlying bone from normal stress and therefore lead to atrophic changes. Metal will also cause artefacts on postoperative computed tomography (CT) and magnetic resonance imaging (MRI).

There is now evidence that titanium is not quite as biologically inert as was originally supposed. Limited corrosion takes place with detectable particles in both local tissue and regional lymph nodes. These findings have reinforced the arguments for routine removal of all metal plates.

This in turn begs the question that if all plates are to be removed why use an expensive material like titanium rather than stainless steel?

For all of these reasons maxillofacial surgeons as well as orthopaedic surgeons have looked for a biodegradable material which could be used for the construction of bone plates of sufficient strength and acceptable bulk to satisfy the mechanical requirements of both craniofacial reconstruction and the management of facial fractures. The most obvious available material is bone itself, either autogenous or bank. Records of individual patients from World War I describe the use of screws and dowels fashioned from bone which were used to fix mandibular fractures and bone grafts in an effort to avoid the ever-present risk of infection. More recently, Obwegeser (1997) has described a bioconvertible osteosynthesis system utilizing plates and screws made from autogenic or allo-genic cortical bone and which has been in clinical use since 1992.

There is a distinction between materials that are biodegradable, i.e. are broken down within the body, and those which are bioabsorbable, i.e. are completely eliminated. Lindqvist and his co-workers in Helsinki have extensively investigated bioabsorption and the use of bioabsorbable materials in maxillofacial surgery (Lindqvist, personal communication; Suuronen *et al.*, 1999). Research has concentrated latterly on a group of high molecular weight poly-alpha-hydroxy acids and their copolymers -specifically polylactic acid (PLA), polyglycolic acid (PGA) and polydioxanone (PDS). Initially the laevo form of polylactic acid showed most promise. The mechanical properties were substantially improved by two further developments. It was found that copolymers of laevo-and dextro-lactic acid in certain proportions could be formed into small plates which were heat-malleable, resorbed within 2 years and were strong enough for craniofacial reconstruction. The material was still not sufficiently robust to be used for most mandibular fractures. A second important development took place when it was discovered that the polymer elements could be orientated during manufacture to strengthen the final product even more - a process of self-reinforcement. Self-reinforced copolymer can be bent and adapted at room temperature using suitable pliers, and can be sterilized by gamma radiation. The most promising present material is, accordingly, a self-reinforced copolymer of L- and DL-lactide which can be fashioned into miniplates. They are already widely used for craniofacial and orthognathic surgery but whether they have sufficient strength for the routine treatment of fractures of the mandible is less certain (Tarns *et al*, 1999). At their present stage of development bioabsorbable plates and lag screws appear to have a place in the fixation of fractures of the mandibular symphysis where there is good bony contact .

Non-compression small plates

Small conventional orthopaedic plates have been used in the past for the treatment of mandibular fractures. These plates are, however, larger than the presently designed miniplates and offer

no advantages (Fig. 90). The only reason for using a plate of larger dimension than the miniplates is to incorporate compression across the fracture.



Figure 90. A standard non-compression orthopaedic plate which was removed from a treated fracture of the angle of the mandible. Insertion and removal required a large extra-oral submandibular incision.

Compression plates

Compression osteosynthesis of mandibular fractures is based on the firm biological principles established for the treatment of fractures of weight-bearing long bones. However, as has been previously pointed out, non-union or delayed union is rarely a problem in fractures of the mandible or other facial bones. On the other hand, precise reduction is essential in the dentate mandible and precise reduction is difficult to achieve with compression plating techniques. It is probably true to say that compression plates have now been abandoned by the majority of maxillofacial treatment centres. For the student it is instructive to examine why this has occurred.

Mandibular compression plates are either AO dynamic compression plates or plates based on the same design principle. For anatomical reasons it is necessary to apply these plates to the convex surface of the mandible at its lower border. However skilfully the plate is adapted there is a tendency for the upper border and the lingual plate to open with the final tightening of the screws. This leads both to distortion of the occlusion and, in a bilateral fracture, to opening of the fracture line on the other side (Spiessl, 1972).

In order to overcome these problems various designs of compression plate were devised (Prein and Kellman, 1987). Unlike miniplates (see below) these are often applied to the bone surface using screws which engage the inner cortical plate and must therefore be sited below the inferior dental canal. All compression plates include at least two pear-shaped holes. The widest diameter of the hole lies nearest the fracture line. The screw is inserted in the narrow part of the hole and at the final moment of tightening its head slides forcibly into the wider diameter section, which is countersunk to receive it (Fig. 91).

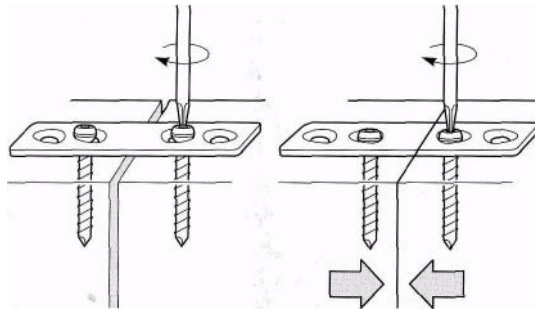


Figure 91. Diagrammatic representation of a small compression plate to illustrate the principle by which compression of the bone interface is achieved. The eccentric pear-shaped holes in the plate cause inward movement of the screw at the final stage of tightening when the head of the screw localizes in the wider part of the pear-shaped hole.

The compression holes in the plate may be positioned one on each side of the fracture (Spiessl, 1972) or both on the same side (Becker, 1974). Because of the tendency for the upper border to open when compression is applied across the fracture at the lower border, it is necessary to apply a tension band at the level of the alveolus before tightening the screws (Figs. 92 and 93). This can be in the form of an arch bar ligatured to the teeth or as a separate plate with screws penetrating the outer cortex only. Schilli (1977) designed a plate with oblique lateral holes which ensured that the compressing force was in part directed towards the upper border so that when the plate was tightened into place there was less tendency for the fracture line to gape. Raveh *et al.* (1987) employed a special adjustable temporary plate at the upper border which enabled them to achieve precise reduction of the fracture prior to application of the definitive lower border dynamic compression plate. They found no application for the eccentric dynamic compression plate in their large series of cases and reported malocclusion post-reduction in only 0.5 per cent of patients. Other workers have either placed the patient in temporary intermaxillary fixation or employed special adjustable bone-holding forceps to ensure accurate fracture reduction prior to application of the compression plate.

It has become increasingly apparent that compression plates offer no material advantage to the patient in the treatment of facial bone fractures. The operative approach tends to be lengthy and requires considerable expertise to produce consistent results. This is especially so if an intra-oral approach is used or if preliminary intermaxillary fixation is applied. Compression plating becomes more difficult when there is any obliquity of the fracture because of the depth of penetration of the screws. Problems also arise when there is comminution at the lower border, which is not always apparent from conventional radiographs. Perhaps the chief disadvantage, however, is the actual bulk volume of the fixation plate, which necessitates later removal in a high proportion of patients. This, of course, means subjecting the patient to a further general anaesthetic not otherwise indicated. For all of these reasons the majority of surgeons now use non-compression miniplates exclusively.

Miniplates

Roberts (1964) used cobalt-chrome alloy meta-carpal plates up to 1 inch (2.5 cm) in length to treat a series of mandibular fractures. These were applied to the outer cortical plate after reduction of the fracture, by means of 7 mm long screws 1.5 mm in diameter. Roberts later designed plates specifically for mandibular plating. Battersby (1966) subsequently reviewed a series of 350 cases treated in this way over a 12-year period and demonstrated satisfactory fixation. The plates were, however, employed as an alternative to transosseous wiring and most patients needed to be placed into intermaxillary fixation as well. Michelet and Moll (1971) described the use of similar small cobalt-chrome alloy plates of various lengths, and subsequently Michelet *et al.* (1973) reported results in 300 cases. These chrome-cobalt alloy plates were difficult to adapt and were not widely adopted. Champy *et al.* (1978) introduced a miniplate system customized for use in mandibular fractures. Originally fashioned in stainless steel, similar plates have now become widely available made from titanium (Figs. 89 and 94).

Champy and his co-workers argued that compression plates were unnecessary because there was a natural line of compression along the lower border of the mandible. They further claimed that compression exerted a stress-shielding effect which was detrimental to ultimate mandibular strength. Non-compression miniplates with screw fixation confined to the outer cortex allow the operator to place plates both immediately sub-apically as well as at the lower border. The stress distribution after fracture of the body of the mandible has been investigated using stressed bars of epoxy resin to simulate the fractured mandible. On the basis of these studies it is suggested that fractures at the angle can be secured with a single plate as near to the upper border as the dental anatomy permits. In the canine region two plates are ideally required, one juxta-alveolar and one at the lower border. All plates can be inserted by an intra-oral approach without the need for intermaxillary fixation (Fig. 94).

Miniplates of this design are now widely used and reported results are encouraging.

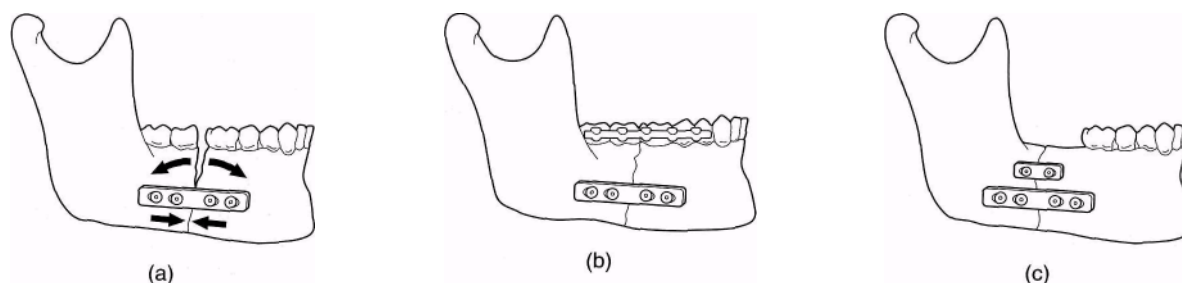


Figure 92. Diagram illustrating the chief problem with a compression plate, (a) Compression near the lower border opens up the fracture at the alveolar margin, (b) A tension band previously applied to the teeth prevents the distorting effect of the lower border compression plate, (c) A similar effect is achieved by prior application of a small cortical non-compression plate above the level of the inferior.

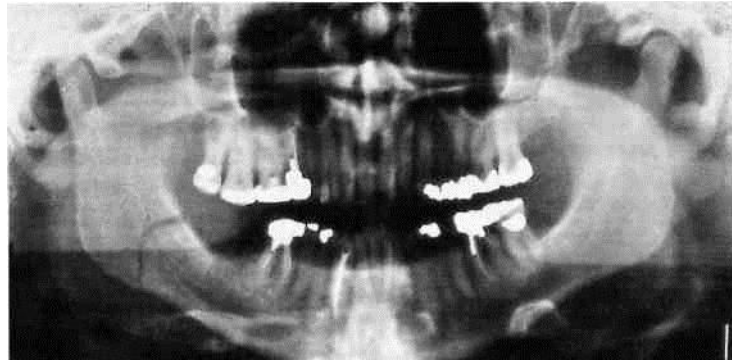


Figure 93. Radiographs showing the use of a compression plate at the lower border in conjunction with a non-compression cortical plate above the level of the inferior dental canal. (Case treated by Professor J. Prein and reproduced with his kind permission).

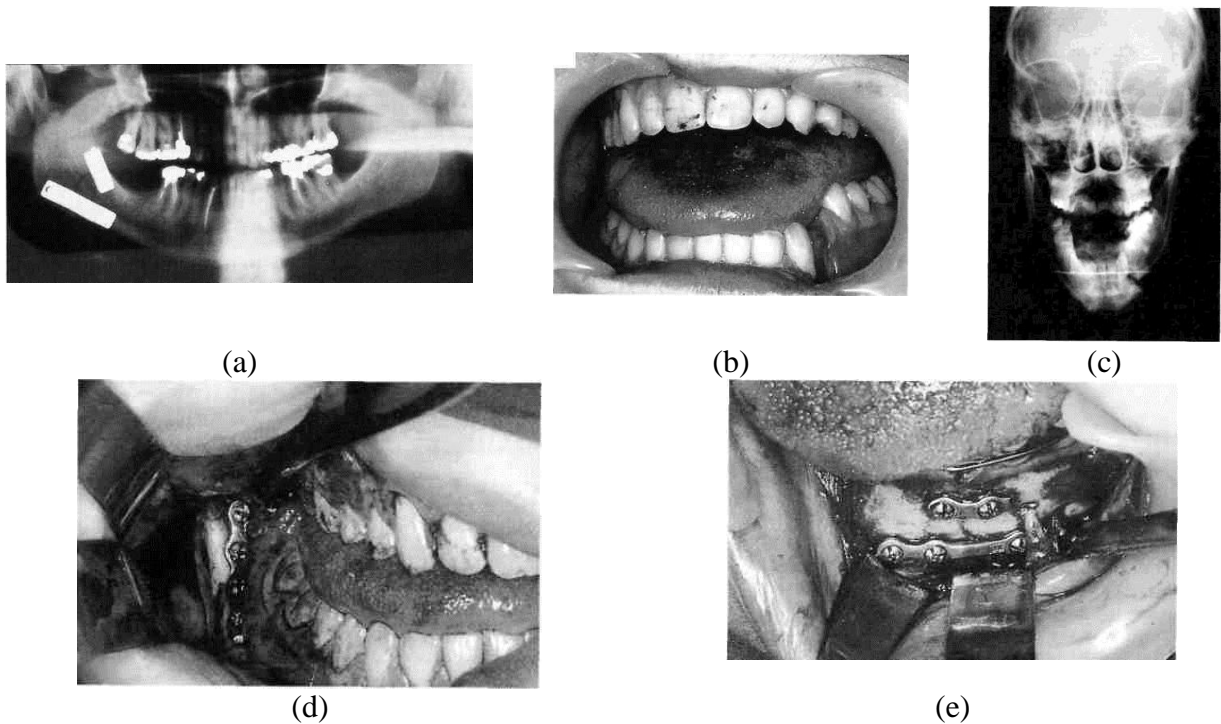
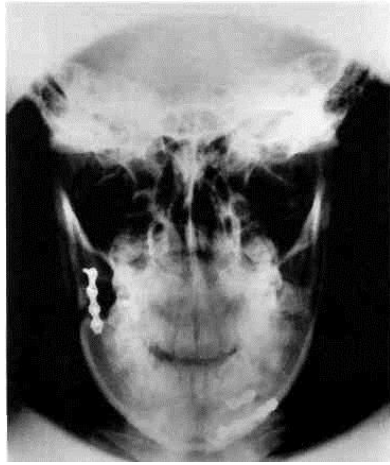
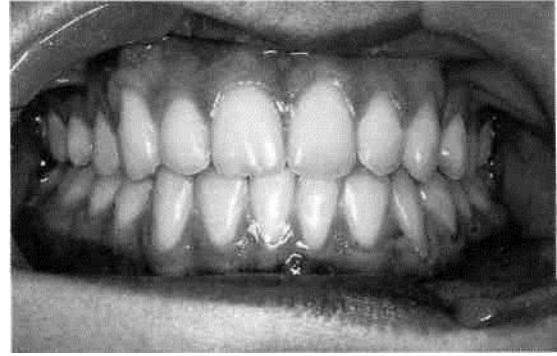


Figure 94. (a) The post-traumatic occlusion of a patient with a bilateral fracture of the body of the mandible. The 'step' deformity in the left mandible is clearly illustrated, (b) Postero-anterior radiograph showing fractures in the right molar and left canine regions of the mandible, (c) Operative photograph showing a non-compression miniplate applied across the fracture in the right retromolar region, (d) Operative view of the left canine region. The fracture was reduced with the aid of a temporary wire around the teeth. Two cortical miniplates have been inserted taking care to avoid damage to the mental nerve, which is shown emerging from the mental foramen.



(a)



(b)

Figure 94. (*continued*) (e) Postoperative radiograph. The fractures have been satisfactorily reduced and immobilized by non-compression miniplates. (f) Immediate postoperative photograph of the occlusion. The temporary wire ligature around the teeth on each side of the left mandibular body fracture has not yet been removed.

The operative time involved is no more than that required for transosseous wiring. Cawood (1985) compared 50 cases treated by conventional intermaxillary fixation with 50 cases treated by miniplates. The plated series had a higher incidence of residual malocclusion (8%) but there were no cases of delayed union compared with 6 per cent in the control group. Of the plated cases 6 per cent became infected compared with 4 per cent of the controls and 3.8 per cent in a comparable group treated in an independent hospital department.

Postoperative infection of miniplates appears to vary considerably from unit to unit. Wald *et al.* (1988) have reviewed the literature and report complications as high as 30 per cent in some series. The risk of infection from various plating systems has been reviewed by Ellis (1999).

Miniplate osteosynthesis can be used in virtually all types of mandibular body fracture.

Plates can be inserted via an intra-oral approach using special cheek retractors and protective sleeves passed through the soft tissues of the cheek. It is only necessary to reflect periosteum from the outer plate of bone, which is an advantage when compared with transosseous wiring. A few surgeons favour the use of simultaneous intermaxillary fixation when using miniplates (Mommaerts and Engelke, 1986). The plates can usually be left in permanently without causing trouble (Haug, 1996), but on theoretical grounds Cawood (1985) recommends removal because of the continuing effect on the functional forces within the bones. There is also now firm evidence that corrosion and local dispersal of titanium does take place but this is only detectable by ultramicroscopic techniques (Kim *et al.*, 1997). The significance in the long term cannot yet be evaluated, which is regarded by some as an indication for removal of all plates (Haers *et al.*, 1999).

Lag screws

A few oblique fractures of the mandible can be rigidly immobilized by inserting two or more screws whose thread engages only the inner plate of bone. The hole drilled in the outer cortex

is made to a slightly larger diameter than the threaded part of the screw. When tightened the head of the screw engages in the outer plate and the oblique fracture is compressed. At least two such lag screws are necessary to achieve rigid immobilization (Fig. 95). The technique has been well reviewed by Leonard (1987).

Resorbable plates and screws

The advantage of a small bone plate fashioned in a biocompatible resorbable material has been clear for some time and a number of materials have been investigated. In order to be useful for mandibular fractures these plates need to be both adaptable to the complex surface of the bone and strong enough to stabilize the reduced fracture until bone healing has advanced to the stage of stable union. The mechanical requirements for the fixation of fractures of the upper and mid-facial skeleton are less but the plates need to be smaller than those which can be applied to the mandible. So far the most promising materials appear to be polylactides, or more specifically self-reinforced poly (L-lactide) homopolymer (PLLA) and poly (L/D-lactide) stereocopolymers with an L/D molar ratio of up to 85:15 (Haers *et al.*, 1999).

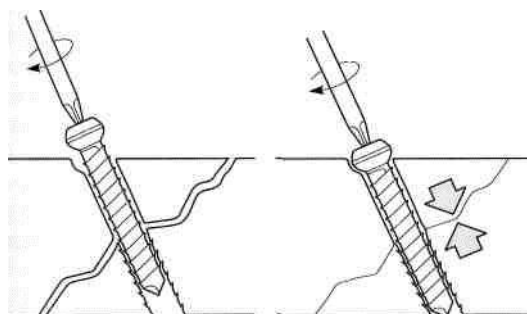


Figure 95. Diagram to illustrate the principle of the lag screw in an oblique fracture. The deeper section of the screw hole is accurately tapped whereas the superficial section allows free movement of the screw. As the screw is tightened the fracture is reduced and compressed.

Plates fashioned in this material have been used successfully in orthognathic surgery and cranio-facial surgery and have had limited clinical evaluation for mandibular fractures (Bessho *et al.*, 1997). The material is biocompatible with a somewhat lengthy period of degradation which may not end in total absorption but which does not appear to be a problem clinically (Suuronen *et al.*, 1998). Sufficiently strong plates for the management of mandibular fractures with good overall bone contact can now be constructed in sizes which compare favourably with titanium. They can be bent without heating and after bending the plate will retain its shape. It is fair to say that full clinical evaluation is not yet complete but intermediate-term results are encouraging (Fig. 96).

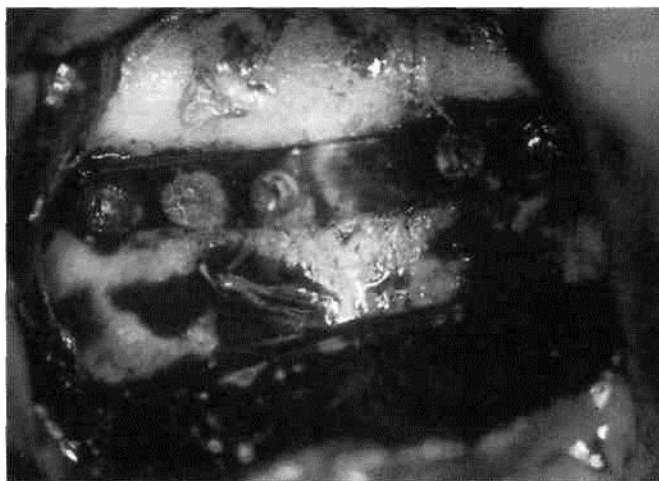

Figure 96. Clinical photograph of a self-reinforced PDLLA resorbable miniplate used for the fixation of a mandibular fracture. (Case treated by Professor C. Lindqvist and reproduced with his kind permission).

Indications for application of miniplates

Although there are some who would advocate plate osteosynthesis in all cases of mandibular fracture, there are some fractures which benefit particularly. These are:

1. Fractures in an edentulous part of the body of the mandible.
2. Concomitant fractures of the body and condyle when early mobilization is indicated.
3. When there are associated fractures of the other parts of the facial skeleton.
4. Patients in whom intermaxillary fixation is contraindicated.
5. Fractures associated with closed head injury.
1. 6. Fractures in which there are continuity defects.
6. Fractures in which non-union or malunion has occurred.

Intermaxillary fixation (IMF)

In the presence of sufficient numbers of teeth, simple fractures of the tooth-bearing part of the mandible may be adequately immobilized by intermaxillary fixation alone. Clinical union can be expected within 4 weeks in nearly all cases, and the fixation can often be established without resorting to general anaesthesia. Intermaxillary fixation is most frequently now used to maintain the correct occlusion temporarily while some form of direct osteosynthesis is applied. A number of methods are available,

Bonded modified orthodontic brackets

Fractures with minimal displacement in patients with good oral hygiene can be immobilized by bonding a number of modified orthodontic brackets onto the teeth and applying intermaxillary elastic bands. The orthodontic brackets can be suitably prepared in the maxillofacial laboratory by welding small hooks onto each of them. Selected teeth in each jaw are then carefully dried, etched, and the brackets bonded to the teeth with composite resin. Because this technique demands complete elimination of moisture, it is not applicable in cases where there is other than minimal intraoral bleeding.

Dental wiring

Dental wiring is used when the patient has a complete or almost complete set of suitably shaped teeth. Opinions differ as to the type and gauge of wire used, but 0.45 mm soft stainless wire has been found effective. This wire requires stretching before use and should be stretched by about 10 per cent. If this is not done the wires become slack after being in position for a few days. Care should be taken not to over-stretch the wire as it will become work hardened and brittle.

Numerous techniques have been described for dental wiring, but two have been found very satisfactory. The most simple is direct wiring.

Direct wiring

The middle portion of a 15 cm length of wire is twisted round a suitable tooth and then the free ends are twisted together to produce a 7.5-10 cm length of 'plaited' wire. Similar wires are attached to other teeth elsewhere in the upper and lower jaws and then after reduction of the fracture the plaited ends of wires in the upper and lower jaws are in turn twisted together. For greater stability the wire surrounding each tooth can be applied in the form of a clove hitch. Thus suitable teeth in the upper and lower jaws are joined together by direct wires. This is a simple method of immobilizing the jaws, which provides rapid temporary IMF during the application of transosseous wires or plates. The disadvantage as a definitive form of fixation arises from the fact that the intermaxillary wires are connected to the teeth themselves. It is therefore difficult to release the intermaxillary connection without stripping off all the fixation. This disadvantage is overcome by using interdental eyelet wiring.

Interdental eyelet wiring

Eyelets are constructed by holding a 15 cm length of wire by a pair of artery forceps at either end and giving the middle of the wire two turns around a piece of round bar 3 mm in diameter which is fixed in an upright position.

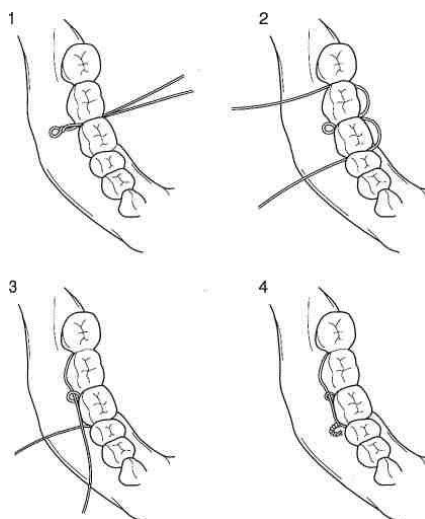


Figure 98. Diagram of the stages involved during the insertion of an eyelet wire

These eyelets are fitted between two teeth in the manner shown in Fig. 98 and twisted tight. Care must be taken to push the wire well down on the lingual and palatal aspect of the teeth before twisting the free ends tight, as the eyelet will tend to be displaced up the tooth and become loose. This can be done by pushing the wire down on the lingual and palatal aspects with a suitably rounded instrument.

About five eyelets are applied in the upper and five in the lower jaw and then the eyelets are connected with tie wires passing through the eyelets from the upper to the lower jaw. To test whether a fracture is soundly united it is then possible to remove only the tie wires, and if a further period of immobilization is indicated new tie wires can be attached.

The eyelets should be so positioned in the upper and the lower jaw that when the tie wires are threaded through them a cross-bracing effect is achieved (Fig. 99). If the eyelets are placed immediately above each other some mobility of the mandible is possible. It should be remembered when working with wire that the wire is sharp and resilient and precautions must be taken to protect the patient's eyes at all times. Every free end of wire should have a pair of heavy artery forceps attached to it when it is not actually being manipulated. When working under general anaesthesia the eyes should be closed and carefully protected. After the eyelet wires have been applied the tie wires should be loosely threaded through the eyelets in the opposing jaws. Irrevocably damaged teeth are extracted at this stage and the throat pack is removed, after which the fracture is reduced and the tie wire fixation is tightened (Fig. 100).

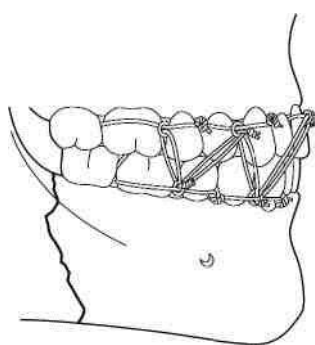


Figure 99. A completed eyelet wiring showing how the eyelets are connected by the wires, which are twisted in the manner shown in Fig. 100.

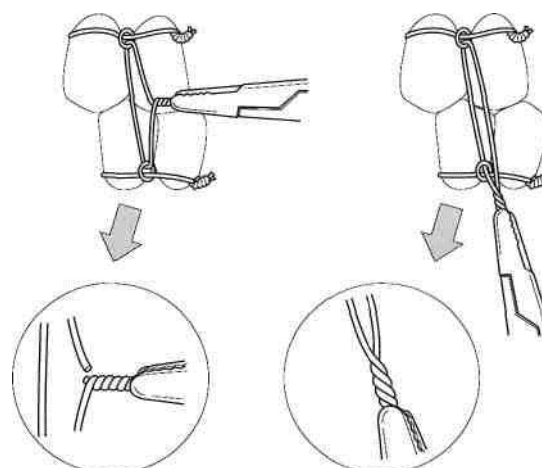


Figure 100. The incorrect (a) and correct (b) methods of twisting the tie wires together. If the twisted portion is at right angles to the wire loop as shown in (a) it cannot be twisted tightly without risk of breakage.

It is important that the patient's normal pre-fracture occlusion is understood by the operator. Many patients have some abnormality of their occlusion and a mistaken attempt to achieve a theoretically correct occlusion in such cases may result in gross derangement of the bony fragments.

Much information about the previous occlusion can be inferred from such evidence as wear facets on the teeth, examination of study models, and particularly information from the patient.

In order best to re-establish the occlusion and avoid a cross-bite, the tie wires should initially be tightened in the molar area, first on one side and then on the other, working round to the incisor teeth. Wires may be twisted quite tightly on multirouted teeth, but some caution should be exercised with single-rooted teeth to avoid subluxation. It is best to twist the tie wires loosely together first and carry out the final tightening after the occlusion has been checked. Care must be taken to ensure that the tongue is not trapped between the cusps of the teeth. After the interdental eyelet wiring is completed a finger should be run round the patient's mouth to ensure that no loose ends of wire have been left projecting which may ulcerate the soft tissue.

Interdental eyelet wiring is simple to apply and very effective in operation. Excellent reduction and immobilization are effected as the operator can see that the occlusion is perfectly restored. In practice a majority of dentate mandibular fractures can be treated in this fashion.

Arch bars

Arch bars are perhaps the most versatile form of mandibular fixation. They are particularly useful when the patient has an insufficient number of suitably shaped teeth to enable effective interdental eyelet wiring to be carried out or when, in an otherwise intact arch, a direct link across the fracture is required. The method is very simple. The fracture is reduced and then the teeth on the main fragments are tied to a metal bar which has been bent to conform to the dental arch. Many varieties of prefabricated arch bar are available and the Winter, Jelenko and Erich type bars have all proved effective. These bars are supplied in suitable lengths and have hooks or other devices to assist in the maintenance of intermaxillary fixation (Fig. 101). In the absence of such specialized bars a very effective arch bar can be constructed from 3 mm half-round German silver bar. Notches are cut on the bar with the edge of a file to prevent the intermaxillary tie wires from slipping.

Arch bars should be cut to the required length and bent to the correct shape before starting the operation. If the mandibular fragments are displaced owing to the fracture, the bar can be bent so that it conforms initially to the intact upper arch, although in practice direct application to the lower arch is usually quite satisfactory as extreme accuracy is not required. When it proves difficult to adapt the arch bar directly to the patient's own teeth any lower plaster

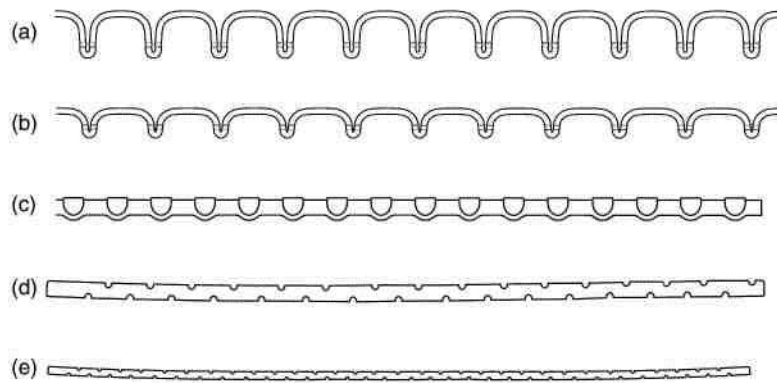


Figure 101. Various forms of arch bar in common use. (a, b) Two sizes of Jelenko arch bar. (c) Erich pattern arch bar. (d, e) Two German silver bars suitably notched to prevent the ligature wires from slipping.

model of approximately the correct size can be used. To facilitate the bending of the German silver bar, it should be annealed by heating to red heat and then allowing it to cool.

Faced for the first time with the problem of attaching an arch bar to a number of teeth by twisting lengths of 0.45 mm soft stainless-steel wire around the teeth and over the bar, any operator would rapidly develop a satisfactory routine. In fact, every operator has his own preferred method of achieving the required result.

It is helpful after the arch bar has been formed to commence wiring on adjacent teeth, preferably in the midline. The arch bar is wired to successive teeth on each side working backwards to each third molar area. In this way minor discrepancies in the arch bar are ironed out as wiring proceeds, which produces close adaptation of the bar to the dental arch. Short, approximately 15 cm lengths of either 0.45 mm or 0.35 mm wire are used for each ligature and some regular pattern is desirable. For instance, each wire may pass over the bar mesially, around the tooth, and under the bar distally, before the ends are twisted together. Whenever contact points between the teeth are tight 0.35 mm wire is used. After all the wires have

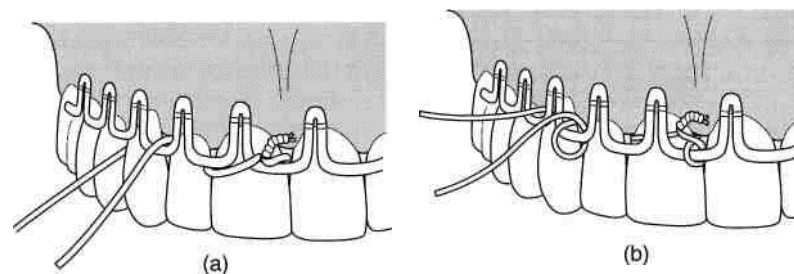


Figure 102. Two methods of ligaturing an arch bar to the teeth, (a) Simple method used in most cases, (b) Method used for unfavourably shaped teeth allowing the ligature wire to be closely adapted at the cervical margin.

been placed it will be found that some have become loose and it is therefore important to re-tighten each wire before the twisted portion is cut and tucked into a position where it will not

irritate the tissues (Fig. 102). Most fractures of the mandible can be effectively treated in this fashion if teeth are present on the main fragments (Fig. 103).

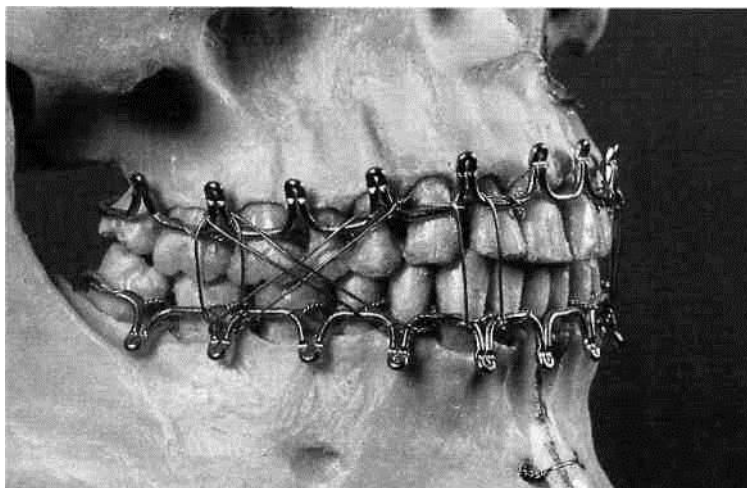


Figure 103. Model used to demonstrate a Jelenko arch bar wired to the standing teeth. Intermaxillary wire ligatures can be placed in any suitable pattern.

Cap splints

Silver cap splints were for many years the method of choice for the immobilization of all jaw fractures. Their present-day use in fracture treatment is confined to a small minority of cases. The technique is time consuming both clinically and in the laboratory and the results achieved are accomplished better and faster by other methods. As far as mandibular fractures are concerned, the possible remaining indications for the use of cap splints are as follows:

1. Patients with extensive and advanced periodontal disease when a temporary retention of the dentition is required during the period of fracture healing. A cap splint in this situation will splint all the loose teeth together and allow the application of intermaxillary fixation. Most surgeons would, however, prefer to extract the teeth and apply bone plates to the underlying fracture if the patient was fit for the operative procedure.
2. To provide prolonged fixation on the mandibular teeth in a patient with fractures of the tooth-bearing segment and bilateral displaced fractures of the condylar neck. In such a case the cap splint will immobilize the body fracture and allow mobilization and, if necessary, intermittent elastic traction for the condylar fractures. The cap splint may be built up in the molar region to provide condylar distraction. Again there are better ways of dealing with this difficult problem (see below).
3. Where a portion of the body of the mandible is missing together with substantial soft-tissue loss. A cap splint will allow the remaining tooth-bearing segments to be maintained in their correct relationship pending soft-tissue reconstruction and bone grafting.

In modern maxillofacial surgery, cap splints should be considered to be only of historical interest. They are apparently still used by some surgeons in orthognathic surgery and some operators still employ extra-oral fixation in complicated mid-facial fractures. The method of construction should therefore be understood in principle.

Impressions of the teeth of a patient with a fractured mandible are occasionally needed to facilitate the construction of arch bars as well as for cap splints. The impression technique has to be modified in the injured jaw to take account of limited opening and the presence of blood and excess saliva. The impression need only record the teeth themselves and a small amount of the alveolar margin and it is therefore easier to use a cut-back lower impression tray for both jaws.

Cap splints are subsequently constructed in the maxillofacial laboratory and finally cemented to the teeth. They are constructed with small hooks or cleats on the sides to which intermaxillary elastic bands are easily attached. Intermaxillary elastic traction will produce a degree of reduction which may be acceptable in rare circumstances when other injuries discourage prolonged operative treatment of the maxillofacial injury. Operative reduction is to be preferred in all other circumstances. After reduction, segmental splints need to be localized together to produce continuity of the splint round the whole mandibular arch. Locking bars have to be made which are soldered to individual plates, which in turn can be screwed to matching plates on the splint segments.

Intermaxillary fixation and osteosynthesis using wire

Although some simple fractures of the tooth-bearing portion of the mandible can be accurately and adequately treated by intermaxillary fixation alone, in practice that fixation is frequently reinforced by open reduction of the fracture and some type of non-rigid osteosynthesis. Osteosynthesis by wiring has the advantage that a minimum of specialized equipment is required, and the method can be used to treat most mandibular fractures which cannot satisfactorily be managed by eyelet or arch wiring alone. There are numerous refinements of these techniques but all have stood the test of time and produce reliable results for the injured patient.

Transosseous wiring

Direct wiring across the fracture line is an effective method of immobilizing fractures of the body of the mandible including the angle. In principle, holes are drilled in the bone ends either side of the fracture line after which a length of 0.45 mm soft stainless-steel wire is passed through the holes and across the fracture.

After accurate reduction of the fracture the free ends of the wire are twisted tightly, cut off short and the twisted ends tucked into the nearest drill hole. It is most important not to attempt to reduce the fracture by tension on the wire. The fracture must be reduced independently *with the teeth in occlusion* before the wire is tightened (Fig. 104). In practice some ingenuity is required in the placement of transosseous wires in order to ensure that the fracture is stable, particularly when it is comminuted to any degree.

Upper border wires are applied via an intraoral approach and are particularly useful in aligning an edentulous posterior fragment or for stabilizing a fracture at the angle (Fig. 104a). It is often sufficient for an upper border wire to pass through the outer cortical plate alone as the fixation is always combined with some form of intermaxillary fixation.

Lower border wires are usually inserted via a skin incision placed well below the line of the lower border of the mandible. They are particularly useful for the control of grossly displaced fractures of the body or angle, particularly when the upper alveolar border is comminuted (Fig. 104b). In the symphysis region a lower border wire can be inserted quite easily via an intra-oral incision in the anterior buccal sulcus. Fractures in this area tend to gape at the lower border under the influence of the mylohyoid diaphragm and a transosseous wire placed near the lower border exerts excellent control even when passed through the outer cortex alone.

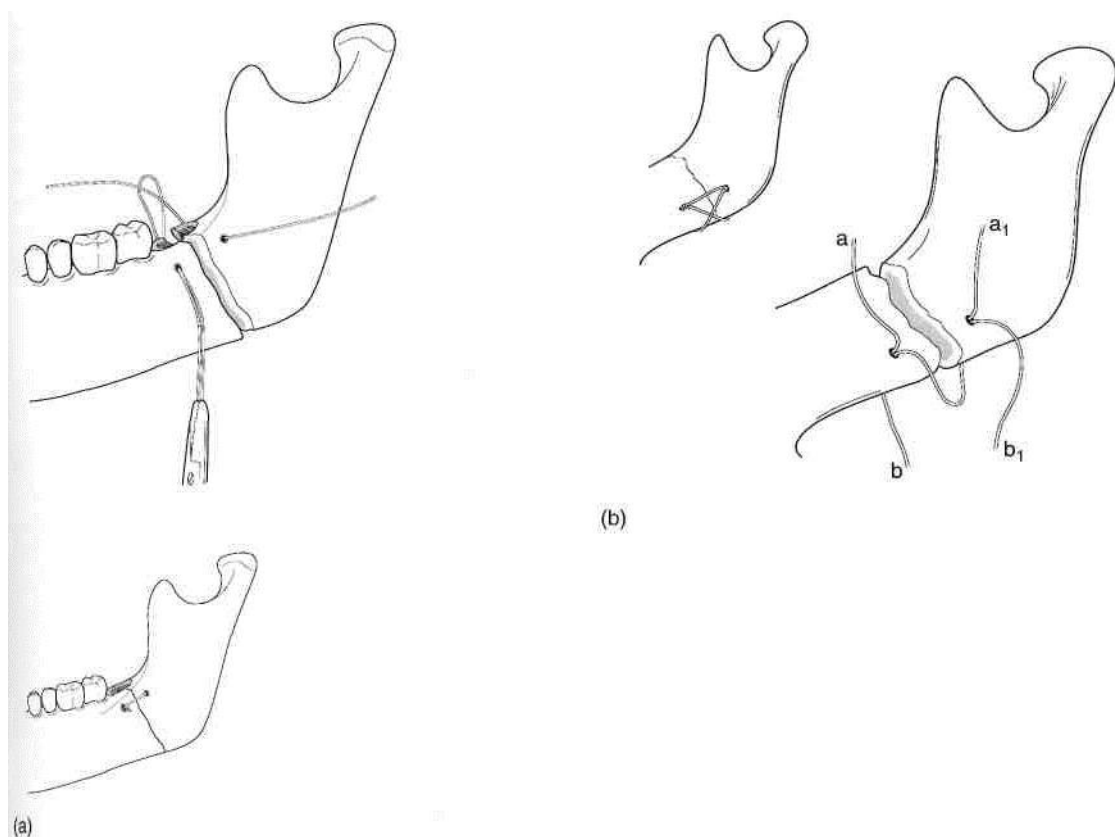


Figure 104. (a) Diagram of mandible showing an upper border wire used to control a horizontally unfavorable fracture of the angle after removal of the third molar involved in the line of the fracture, (b) Diagram of mandible showing the application of a combination of standard and figure-of-eight lower border wires.

Multiple fractures at the symphysis create a particularly difficult problem especially when the lower anterior teeth are damaged beyond repair. In such cases the only reasonably large fragments may be those which previously constituted the lower border. Careful multiple transosseous wiring through a submental incision will allow the lower border to be reconstituted accurately, and provide a firm base for restoration of the mandibular arch. In practice it is usually easier to adapt a long plate to achieve the same result.

When a single lower border wire is applied to a fracture site it may on its own be insufficient to stabilize the fracture owing to the tendency of the fragments to over-ride, particularly if the fracture line is oblique. This can be corrected to some extent by combining a conventional wire with a second figure-of-eight wire (Fig. 104b). Alternatively, the transosseous wire can be reinforced by passing it through a length of stainless-steel orthodontic tubing let into a groove in the outer cortical plate.

When the line of the fracture is very oblique in the vertical plane it is often possible to hold the fracture in a reduced position and pass two wires separately directly through the outer and inner cortical plate and twist the ends together under the lower border, a technique which provides firm fixation (Fig. 105).

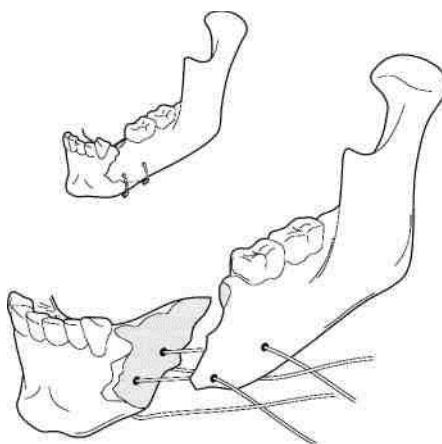


Figure 105. Method of immobilizing an oblique fracture by two transosseous wires passed from buccal to lingual and twisted together under the lower border.

Circumferential wiring

A few oblique fractures of the body of the mandible can be reinforced by passing a length of 0.45 mm soft stainless-steel wire circumferentially, utilizing the same technique as that employed for wiring modified Gunning-type splints to the edentulous jaw. A useful variation of this technique is frequently applicable to oblique fractures of the angle after removal of an involved third molar. The wire is passed through the upper border of the proximal fragment and then around the lower border of the mandible which, in an oblique fracture of this nature, controls the distal fragment.

External pin fixation

There are occasions when extensive comminution of the whole or a large part of the body of the mandible occurs. In order to maintain the relationship of the major fragments some form of external pin fixation can often usefully be applied. The technique consists of inserting into each major bone fragment a pair of 3 mm titanium or stainless-steel pins, which diverge from each other but are connected by a crossbar which is attached to each pin by means of universal joints. Self-tapping pins such as Moule or Toller type are used, these being screwed into prepared holes in the bone of slightly smaller diameter. After reduction of the fracture the pairs of pins are linked by attaching a connecting rod or rods to the centre of the cross-bar by means of universal joints. Alternatively, one end of the linkage may be attached to a lower cap splint by a suitably designed locking plate and connecting bar (Fig. 106a,b).

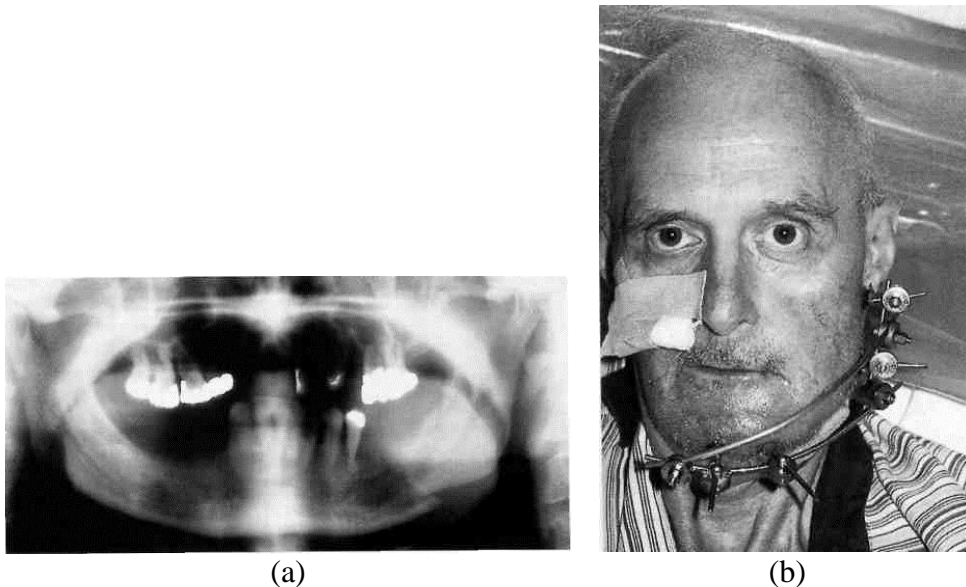


Figure 106. (a) A displaced pathological fracture at the site of a lymphoma within the mandible. Extra-oral fixation was applied while the lesion was treated non-surgically. (b) Extra-oral fixation using titanium pins inserted proximally and distally to the lesion and connected by rods and universal joints.

Pin fixation of this nature is not particularly rigid and supplementary intermaxillary fixation is usually required. The extra-oral fixation can be reinforced by self-curing acrylic resin as a biphasic appliance. This form of fixation has been widely favoured for the management of missile injuries of the mandible.

The main indications for the use of pin fixation for mandibular fractures may be summarized as follows:

1. To provide fixation across an infected fracture line.

2. To maintain the relative position of major fragments in extensively comminuted fractures.
3. To stabilize a pathological fracture where there is a large amount of bone loss.
4. In the treatment of bimaxillary fractures when a 'box frame' form of fixation is employed.

Bone clamps

Bone clamps are of historical interest only and are no longer used in clinical practice. They were introduced to overcome some of the problems associated with the stainless-steel bone pins in use at the time which resulted from electrolytic activity of biologically incompatible alloys. Since the introduction of titanium these problems no longer exist and as a result bone clamps are obsolete. The Brenthurst splint, invented in South Africa and used in the Second World War, was the best known example of this system. Instead of pins screwed into the bone, the fragments each side of the fracture were secured by clamps attached to the lower border of the mandible. Pins which projected from the clamps were then connected by a system of external rods and universal joints in a similar manner to that employed with external pin fixation.

Transfixation with Kirschner wires

Kirschner wires (K-wires) are widely used in orthopaedic practice and are therefore usually available in most hospitals. In rare emergency situations these wires can be used to provide temporary stabilization of a fractured mandible. The fracture is held in a reduced position and one or more wires drilled through the fragments so that part of the wire passes through undamaged bone each side of the fracture. The method is versatile and can be applied with appropriate ingenuity to fractures in any part of the mandible whether there be teeth present or not (Vero, 1968). In the context of fractures of the tooth-bearing area it is of little use when more conventional methods are available.

Shuker (1985) described an ingenious use of a single K-wire for the rapid immobilization of a comminuted fracture of the body of the mandible such as might occur after a missile injury. A horseshoe-shaped 2 mm K-wire is adapted to the mandibular arch and then each end is inserted into two holes drilled from an intra-oral approach into the anterior border of each ramus. The horseshoe-shaped wire lies on the buccal side of the displaced mandibular arch and the individual segments with their contained teeth are ligatured to this semi-rigid frame.

Fractures of the tooth-bearing section of the mandible: synopsis

1. Accurate reduction is essential in the presence of a good functional occlusion.

2. All of these fractures are compound into the mouth.
3. Teeth in the line of fracture are a potential source of infection and delayed healing.
4. Mandible can be immobilized by direct osteosynthesis, IMF or a combination of both.
5. Compression plating is based on sound general orthopaedic principles which are less relevant to the dentate mandible than to the skeleton as a whole.
6. Non-compression miniplate fixation is currently the preferred method wherever the necessary resources are available.
7. Malunion is much more likely than nonunion.
8. Other well-proven methods of fixation continue to be employed, apart from cap splints which are now obsolete.

Interference with growth potential

The normal growth of the mandible will be disturbed if unerupted permanent teeth or teeth germs are lost, because the alveolus will not develop normally in the areas affected. Damage to the growth potential will be more severe in the event of infection of the fracture site.

McGuirt and Salisbury (1987) carried out a careful cephalometric analysis of 28 children who had experienced mandibular fractures at sites other than the condyle and found the mandibular unit length to be less than expected in 67 per cent of cases. One-third of the patients with fractures in the tooth-bearing portion of the mandible had specific dental complications.

The capacity for preferential growth in the subcondylar region may be seriously compromised by high condylar fractures, particularly if function is restricted as a result of fibrous or bony ankylosis of the temporo-mandibular joint. The treatment of these injuries is discussed in more detail below.

Fixation in the deciduous and mixed dentition period

If the severity and displacement of the fracture are of sufficient degree to warrant immobilization of the mandible, some modification of technique is required because of the presence of unerupted or partially erupted teeth of the permanent dentition and deciduous teeth of variable mobility.

Fixation independent of the teeth

1. In the very young with unerupted or very few deciduous teeth MacLennan (1956) recommends the use of an overall Gunning-type splint for the lower jaw alone. This is con-

structed as a trough lined with black gutta percha and retained by two circumferential wires.

2. Where some occlusion is present but there is widespread caries or loose deciduous teeth the mandible may be suspended by circumferential wires on each side linked to circumzygomatic wires from above.
3. Rarely when there is significant displacement of fragments open reduction may be necessary. Providing plate or wire fixation is confined to the lower border no damage to developing teeth should occur.
4. A simple elasticated bandage chin support may be used in cases with minimal displacement where jaw movement is nevertheless painful.

Fixation utilizing the teeth

1. Where there are sufficient firm erupted deciduous and permanent teeth, eyelet wires or arch bars can be used. It is often difficult to fix wires firmly to deciduous molars and canines but this task is made easier by using thinner, more flexible, soft stainless-steel wires of 0.35 mm diameter. Similarly, a light arch bar of German silver without hooks is more easily adapted to the irregular dentition, and this should be attached to the teeth by similar 0.35 mm diameter wire ligatures. Orthodontic brackets bonded directly to the teeth may be used in simple fractures (Fig. 107).
2. Cap splints can be constructed for the mixed dentition but retention tends to be inadequate, particularly if partially erupted teeth are present. It is necessary to reinforce the cement bond with circumferential wires tied over the splint on each side.

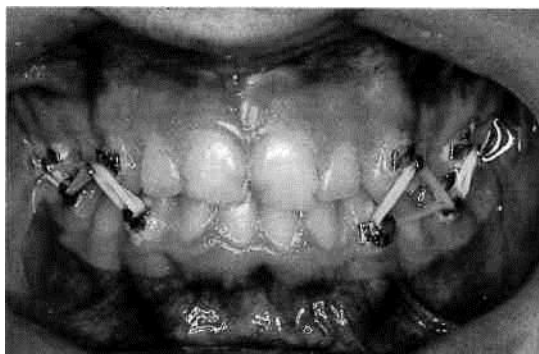

Figure 107. Modified orthodontic brackets fixed to the teeth of a young patient by acid-etching and composite bonding. Intermaxillary elastics have been used to immobilize the mandible, which had a relatively undisplaced fracture of the left angle.

Fractures of the mandible in children: synopsis

1. Modification of the principles of treatment is necessary to take account of:
 - (a) capacity for rapid bony union - fractures are stable at between 1 and 3 weeks;
 - (b) the mixed dentition and multiple buried developing teeth;

- (c) potential interference with subsequent growth.
2. Accurate reduction is less important as further growth will often compensate for occlusal discrepancies.
 3. Direct osteosynthesis should be avoided. Wiring or plating the lower border may occasionally be indicated.
 4. IMF can be applied to deciduous teeth but finer diameter wire should be used.
 5. Fractures of the condyle require special consideration.
 6. Prolonged period of follow-up is important.

FRACTURES OF THE CONDYLAR REGION

Fractures involving the mandibular condyle are the only facial bone fractures which involve a synovial joint. Injury to the joint can occur in the absence of any fracture of the articular surfaces. Trauma to this region may therefore be divided into three main types:

1. Contusion: apart from damage to the capsular ligaments such an injury may be accompanied by a synovial effusion, haemarthrosis or tearing of the meniscus. Such injuries are difficult to diagnose without special imaging techniques but they may predispose to later degenerative changes in some cases.
2. Dislocation: irreducible displacement of the condyle from the glenoid fossa is usually anterior or medial. Lateral, posterior or central dislocations rarely occur. A coexisting fracture of the condylar neck is common.
3. Fracture: includes any fracture above the level of the sigmoid notch. Fractures, fracture/dislocations and dislocations of the condyle are all accompanied by varying degrees of contusion. If the fracture extends into the joint space, haemarthrosis and rupture of the meniscus is more likely to occur and such injuries may predispose to later disturbance of function.

The incidence of condylar process fractures as a proportion of all fractures of the mandible is high, and almost 50 per cent of these condylar fractures are associated with other coexistent fractures of the mandible.

It is unfortunate that there are still no clear guidelines for the treatment of fractures of the mandibular condyle. Gerry (1965) observed that 'a patient who has had a condylar fracture cannot be considered to be cured until he is able to masticate easily with the contra lateral side of the dentition, which implies the recovery of the condylar excursion'. Clinical experience suggests that many 'successfully' treated cases do not fulfil these criteria.

Conservative management

Unlike other fractures of the mandible, anatomical reduction and subsequent fixation of condylar fractures is difficult to achieve.

The majority of surgeons have traditionally favoured a conservative approach, avoiding direct disturbance of the fracture site and concentrating on early restoration of function. MacLennan and Simpson (1965), after reviewing several large series of condylar fractures treated in a number of centres, concluded that a good result was achieved by closed conservative management in 93 per cent of cases. A good early functional result does not, however, necessarily mean full recovery of condylar excursion and there is increasing evidence that subsequent joint dysfunction and osteoarthritis can occur.

A careful prospective study of 76 condylar fractures by Lindahl and Hollender (1977) and Lindahl (1977) resulted in a number of interesting observations. In the majority of young patients, following fracture of the condyle with displacement, there was a complete anatomical restitution of the temporo-mandibular articulation within a 2-year period. Amongst teenagers the joint did not return to normality to the same extent, and in adults only minor remodelling was observed. Asymmetry of mandibular movement and altered function at the fracture site usually disappeared in children, while it persisted or became aggravated in adults. Late symptoms such as clicking and tenderness were rare in children and frequent amongst adults. These authors concluded that remodelling following fractures could be regarded as restitutive in children and adjusting or functional in adults.

The important animal experiments of Walker (1960), Boyne (1967) and Choukas *et al.* (1970) were conducted on young monkeys and all demonstrated satisfactory remodelling and healing of experimental condylar fractures, whether surgically reduced or not. More recently Zhang and Obeid (1991) have demonstrated better outcome after open reduction of experimental condylar fractures in adult rabbits. It is, however, unwise to extrapolate these results to the adult human as a valid guide to treatment.

Dahlstrom *et al.* (1989) completed a 15-year follow-up of a small number of conservatively treated condylar fractures which occurred during growth. They concluded that the older the child the less the capacity for functional remodelling due to reduced bone resorptive capacity. Frequent joint dysfunction was noted in these now young adults but in none was this considered serious. Feifel *et al.* (1992) have reported similar results in another 15-year follow-up. Only half of these patients showed restitutive remodelling but the functional result appeared satisfactory in all cases. Norman (1982) claimed that many cases of osteoarthritis and recurrent dislocation of the temporo-mandibular joint were associated with previous trauma, while over 60 per cent of cases of ankylosis were the result of previous injury.

Open reduction

Grossly displaced fracture/dislocations of the condyle, particularly bilateral fractures, are inevitably accompanied by malocclusion in the dentate patient. Simple immobilization by means of intermaxillary fixation does not always achieve a satisfactory reduction of the fracture and malocclusion persists after healing is complete. Functional distraction of the condyle by applying intermaxillary fixation with the bite gagged posteriorly has been recommended in the past but this is not a reliable method. Open surgical reduction and fixation of displaced condylar neck fractures would appear to be a sensible option in such cases. There is certainly firm evidence from postoperative **MRI** studies that open reduction leads to better anatomical restoration of both the condyle and the articular disc. Zide and Kent (1983) have outlined the indications for open reduction as follows:

1. Absolute indications:
 - (a) displacement of condyle into middle cranial fossa;
 - (b) impossibility of restoring occlusion;
 - (c) ateral extracapsular displacement;
 - (d) invasion by foreign body, e.g. missile.
2. Relative indications:
 - (a) when intermaxillary fixation is contra-indicated for medical reasons;
 - (b) bilateral fracture with associated mid-face fracture;
 - (c) bilateral fracture with severe open bite deformity.

Open reduction of a condylar neck fracture has in the past been regarded as technically difficult although various authors have reported consistent results using transosseous wiring or mini-plates. The operative reduction and subsequent osteo-synthesis is considerably facilitated by a retro-mandibular approach. Consistently good functional and anatomical reconstruction is possible by this approach (Figs. 108), and there is increasing evidence that selective open reduction improves outcome particularly in bilateral condylar fractures. The less satisfactory access to the fracture site from a submandibular approach has led to the development of special methods of fixation from which equally good results can be obtained.

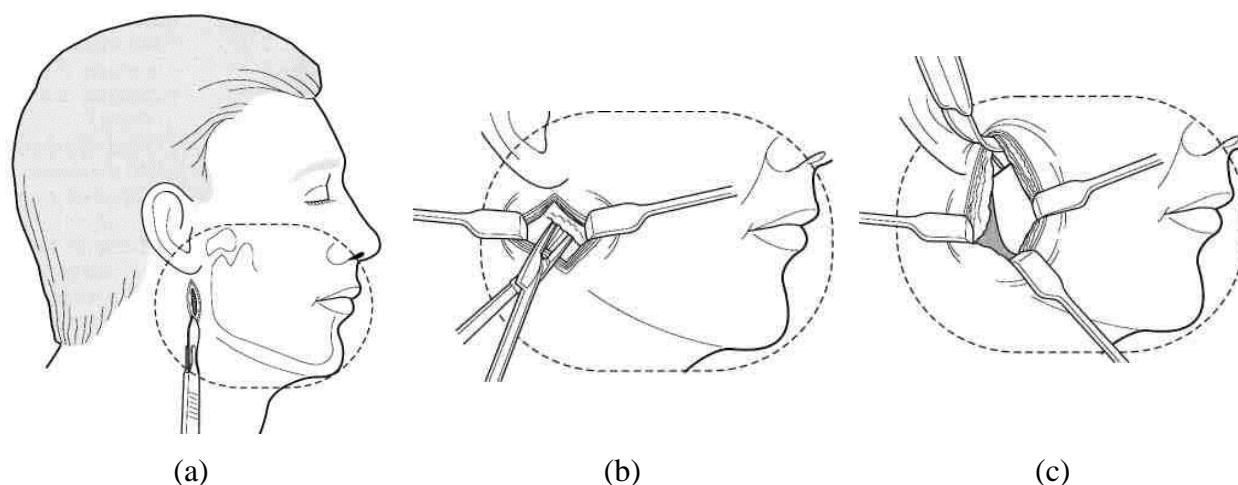


Figure 108. Diagram illustrating the retromandibular approach to the mandibular condyle. The vertical incision lies parallel to the branches of the facial nerve and blunt dissection avoids any damage to this structure.

Major complications

Ankylosis of temporo-mandibular joint

It has long been recognized that ankylosis of the temporo-mandibular joint can occur following trauma. Equally it is now clear that this is a rare complication occurring in only 0.4 per cent of condylar fractures. The fact that ankylosis appears to be commoner in some parts of the world than in others has led to speculation that there may be a genetic predisposition among some racial groups. Fractures which involve the joint space, particularly in young patients, seem most prone to result in this severe complication although attempts to produce experimental ankylosis in primates have been notably unsuccessful.

Laskin (1978) has identified predisposing factors as follows:

1. Age: the major incidence is below the age of 10 years.
2. Type of injury: intracapsular crushing of the condyle.
3. Damage to the meniscus: experimental work on large primates has shown that more restriction of movement occurs when an intracapsular fracture is accompanied by excision of the meniscus. Furthermore, remnants of the meniscus can be found in the medial displaced mass of bone, a finding which is common in human cases of bony ankylosis. Disruption of the meniscus is likely to occur in two types of fracture - a severe intracapsular compression injury or a fracture/dislocation. Yaillen *et al.* (1979) observed marked degenerative changes in the fossa and condylar head after experimental meniscectomy in macaque monkeys.

There is no evidence that prolonged immobilization predisposes to either fibrous or bony ankylosis or indeed to restriction of subsequent movement.

Disturbance of growth

A small proportion of children in which the fracture involves the condylar cartilage and the articular surface exhibit subsequent disturbance of growth. In some cases fibrous or bony ankylosis of the temporo-mandibular joint is an additional complication. This reduces the normal functional movement of the jaw which further inhibits growth. Walker (1957) investigated 50 cases of post-traumatic arrested development of the condyle and found coincident ankylosis in a high proportion. There is an ongoing debate as to whether or not the sub-condylar region is a primary growth centre. In practical terms it does not matter whether this part of the mandible is a hormone-dependent primary centre for growth or an area where secondary preferential bone formation takes place as the mandible develops within a functional matrix. The important concept is that it is an area of preferential growth and therefore the effect of damage is the same - failure of development of the condylar process and a smaller mandible on the affected side.

Treatment of condylar fractures

The methods of treatment of condylar fractures should be based on the clinical and experimental evidence outlined above.

Treatment should be designed to minimize subsequent functional disturbance of the articulation. The difficulties of open reduction and fixation need to be appreciated and where possible a conservative approach preferred.

There are three treatment options:

1. Functional.
2. Indirect immobilization.
3. Osteosynthesis.

Condylar fractures should be classified according to:

1. Age:
 - (a) under 10 years;
 - (b) 10-17 years;
 - (c) adults.
2. Surgical anatomy:
 - (a) involving joint surface - intracapsular;
 - (b) not involving joint surface - extra-capsular;
 - (c) high condylar neck;
 - (d) low condylar neck.
3. Site:

(a) unilateral;

(b) bilateral.

4. Occlusion:

(a) undisturbed;

(b) malocclusion.

Adults

Unilateral intracapsular fractures

The occlusion is usually undisturbed and the fracture should be treated conservatively without immobilization of the mandible.

Occasionally slight malocclusion is noted, particularly when there is an associated effusion in the joint, in which case simple intermaxillary fixation with eyelet wires should be applied for 2-3 weeks.

Unilateral condylar neck fractures

If the fracture is undisplaced the occlusion will generally be undisturbed and no active treatment is necessary. A fracture/dislocation will often induce significant malocclusion due to shortening of the ramus height and premature contact of the molar teeth on that side. A low condylar neck fracture is probably best treated by open reduction in these circumstances.

In the case of a high condylar neck fracture with extensive displacement and malocclusion, intermaxillary fixation is applied and maintained until stable bony union has occurred, i.e. for 31 weeks. In spite of maintaining the occlusion by intermaxillary fixation relapse may take place when the fixation is removed. As this is usually slight it can be corrected by a combination of occlusal grinding and spontaneous adaptation. Extensive occlusal grinding or residual temporomandibular joint (TMJ) dysfunction is certainly not desirable and for this reason there is an increasing body of opinion in favour of ORIF (Fig. 109).

Bilateral intracapsular fractures

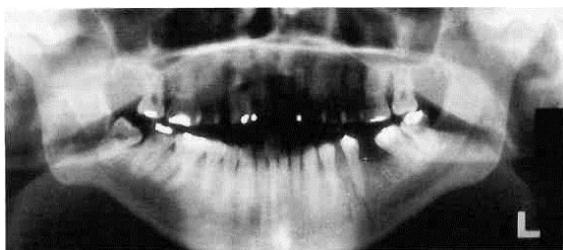
The occlusion is usually slightly deranged in these cases. The degree of displacement of the two condyles may not be the same and it is best to immobilize the mandible for the 3-4 weeks required for stable union. It used to be thought that this would predispose to chronic limitation of movement but post-reduction physiotherapy in the form of simple jaw exercises is effective in preventing this.

Bilateral condylar neck fractures

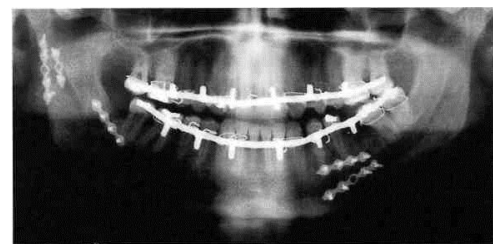
These fractures present the major problem in treatment. There is usually considerable displacement of one side or the other. Even if displacement is not evident when first seen, the fractures are inherently unstable and functional treatment is contraindicated. Although the application of intermaxillary fixation will re-establish the occlusion, it will not reliably reduce the fracture on both sides. Operative reduction of at least one of the fractures to restore the ramus height is desirable. In the case of bilateral high condylar neck fractures where operative reduction is likely to be difficult, intermaxillary fixation should be applied for up to 6 weeks. If strong arch bars or even cap splints are applied this will allow the use of intermittent intermaxillary elastics at night for several weeks after fixation is removed. This technique may encourage better functional remodelling.

Although ankylosis of the temporomandibular joint itself does not occur with condylar neck fractures, exuberant callus formation around grossly displaced fragments may cause extra-articular interference with joint excursion.

When a bilateral fracture of this nature is associated with a major mid-facial fracture, operative reduction of both sides is desirable. It should be appreciated that this represents a considerable amount of operating time even in skilled hands. Nevertheless, modern materials and the use of a retromandibular operative approach make the procedure perfectly practicable. It should be appreciated that ORIF of a condylar neck fracture requires the fixation to be of adequate strength. Application of a single standard miniplate is not sufficient nor are the smaller miniplates and microplates used for fixation of periorbital and naso-ethmoid fractures. If these are used in the subcondylar region they will frequently fracture within a few days. Two standard size miniplates should always be inserted (Figs. 109).



(a)



(b)

Figure 109. (a) Radiograph of a patient with mandibular fractures resulting from direct violence to the parasymphysis. Fractures have occurred in the left premolar region, the right angle and the right subcondylar region. There is considerable shortening of the right ramus and obvious malocclusion. (b) Immediate postoperative radiograph. The condylar fracture has been reduced through a retromandibular incision and two miniplates applied. The lower right third molar involved in the fracture line has been removed and a plate applied via an intra-oral approach. The functioning teeth in the fracture line on the left have been retained and two plates inserted. Upper and lower arch bars were applied to secure a short period of IMF immediately postoperatively.

Fractures of the condylar region: synopsis

1. Fractures of the condylar region involve the temporo-mandibular joint (TMJ) either directly or indirectly.
2. Permanent disturbance of function of the TMJ is common but usually not significant. Fractures which involve the subcondylar area in children can occasionally lead to significant disturbance of growth. Fractures into the joint space can result in fibrous or bony ankylosis, which is more common in some races than others.
3. All intracapsular fractures and all fractures
4. in growing children should be treated conservatively. If the occlusion is disturbed intermaxillary fixation (IMF) is applied and maintained until stable union is expected. Otherwise immediate or early mobilization should be permitted.
5. Displaced subcondylar fractures in adults, particularly when there are bilateral fractures, should be treated by open reduction and fixation.
6. The retromandibular surgical approach to the subcondylar region gives rapid and sufficient access for the application of bone plates, which must be of adequate strength.
7. Treatment of fractures of the condylar region in all age groups is still less than ideal and remains to be evaluated fully.

FRACTURES OF THE EDENTULOUS MANDIBLE

The physical characteristics of the body of the mandible are altered considerably following the loss of the teeth. In effect from the point of view of treatment, the edentulous mandible becomes a different bone. Following resorption of the alveolar process, the vertical depth of the subsequent denture-bearing area is reduced by approximately one-half and in some cases by considerably more. The resistance of the bone to trauma is further reduced by changes in the structure of the bone associated with the process of ageing.

The ageing process is also associated with significant changes in the functional vascular architecture. The endosteal blood supply from the inferior dental vessels begins to disappear and the bone becomes increasingly dependent on the peri-osteal network of vessels. The denture-bearing area of the edentulous mandible is therefore not only more easily fractured, but also less well disposed to rapid and uneventful healing.

In addition, the smaller cross-sectional area of bone at the fracture site and the absence of the stabilizing influence of teeth means that the bone ends are more easily displaced, and even after reduction the area of contact between them may be insufficient for healing to occur easily. The more atrophic the mandible the more significant these factors become. Bruce and Strachen

(1976), in a study of 146 fractures occurring in thin mandibles treated by a variety of methods, reported a 20 per cent incidence of non-union.

The edentulous state confers a few advantages. Fractures are, for instance, much less frequently compound into the mouth than when teeth are present. As a result whenever closed reduction is possible the risk of subsequent infection of the fracture is negligible. Again, the absence of teeth means that precise reduction, such as would be required to restore the occlusion of natural teeth, is not necessary as any inaccuracy is easily compensated by adjustment of dentures. For these reasons many fractures in edentulous

patients require no treatment at all. If the fracture is simple with little or no displacement it will heal satisfactorily if the patient refrains from unnecessary active movements and adjusts to a temporary soft diet. Any subsequent discrepancy in the denture occlusion can be corrected in most cases by relining with or without occlusal adjustment.

In very elderly and infirm patients, the clinician should aim first and foremost for a stable pain-free fracture site, achieved at minimal risk to the patient. Fibrous union alone may provide this result but it may, in turn, condemn the patient to a long, or even permanent period when they are unable to wear dentures. A fibrous union in the body of the mandible will often calcify slowly over a period of up to 12 months. Gross distortion of the alveolus resulting from malunion is less of a problem than it used to be, as the patient may be able to have osseointegrated implants inserted and as a result be able to retain good functioning dentures.

Methods of immobilization

The fact that there is no uniformly accepted method of immobilizing edentulous fractures is indicative of the fact that no completely satisfactory method has yet been devised. There is no doubt, however, that the traditional treatment by means of Gunning-type splints has been largely superseded in recent years by methods which employ some form of direct or indirect skeletal fixation. In older patients intermaxillary fixation is even less desirable than in younger age groups. Nutritional requirements become difficult to maintain and oral candidiasis commonly affects the oral mucosa causing considerable discomfort during the active treatment period. The methods of treatment currently available are listed below:

1. Direct osteosynthesis:

- (a) bone plates;
- (b) transosseous wiring;
- (c) circumferential wiring or straps;
- (d) transfixation with Kirschner wires;
- (e) fixation using cortico-cancellous bone graft.

2. Indirect skeletal fixation:
 - (a) pin fixation;
 - (b) bone clamps.
3. Intermaxillary fixation using Gunning-type splints:
 - (a) used alone;
 - (b) combined with other methods.

Direct osteosynthesis

Bone plates

Bone plates are particularly useful for displaced fractures of the edentulous mandible, particularly those at the angle. They allow the fracture to be stabilized without immobilization of the jaw as a whole. The patient is, as a result, more comfortable during the period of healing of the fracture. The main mandibular plating systems described earlier in the chapter are in general applicable to edentulous fractures. Unlike the dentate mandible there is a significant risk of non-union in the edentulous state and it could be argued that compression plates might have a theoretical advantage. However, the reduced depth of bone in the edentulous mandible favours the use of non-compression miniplates rather than the bulkier compression plates in that the former are less likely to interfere with the edge of a future denture. Bone plates are easier to apply in the edentulous state than when teeth are present as there is no need to achieve the same degree of precision in the reduction of the fracture. Any discrepancy in the eventual occlusion of the pre-existing dentures is more easily corrected than when natural teeth are involved (Fig. 110).

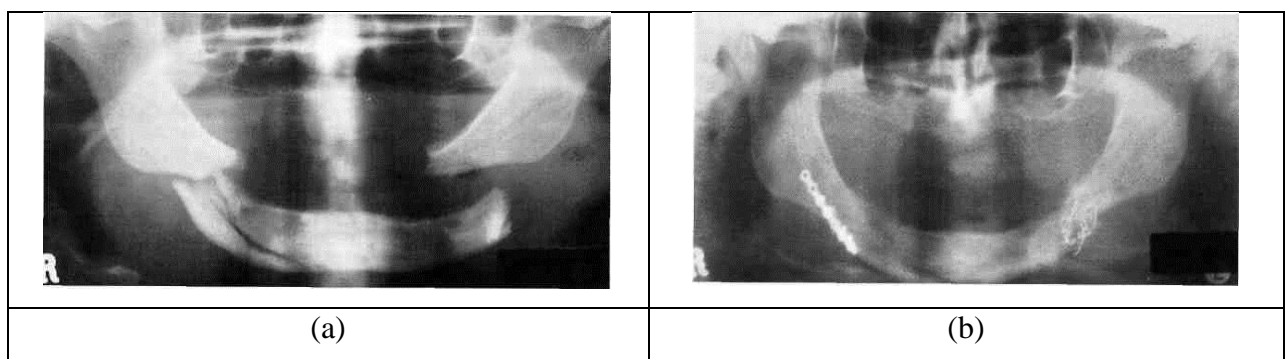


Figure 110. (a) Panoramic tomogram of a bilateral fracture of an edentulous mandible with considerable displacement of the fragments, (b) The situation 6 months after treatment. A miniplate was used for fixation on the right and transosseous wiring on the left. No IMF was employed and the healing on each side is comparable.

It is easier to apply bone plates to the edentulous mandible than it is to insert transosseous wires. There must be fairly liberal exposure of the fracture site with extensive elevation of the periosteum, but that exposure can be confined to one surface of the bone and the overall peri-

osteal attachment is often disturbed less than when inserting a number of transosseous wires. Both compression and non-compression systems require an adequate blood supply to achieve uncomplicated bony union and elevation of periosteum in the thinner mandible seriously compromises the blood supply to the fracture site. It has been suggested that in these circumstances plates should be applied with an intervening layer of attached periosteum, but in practice this is difficult to accomplish.

Plates related to the denture-bearing part of the mandible are much more likely to require removal at a later date than those used in the ramus or in dentate fracture sites. Nevertheless some form of plating is currently the preferred method of fixation for the majority of edentulous mandibular body fractures. Resorbable plates would appear to have an advantage but, at their present stage of development, degradation takes place over a period of 2 years or more during which new dentures are likely to be needed. A metal plate removed electively is a better option.

Transosseous wiring

Many simple edentulous fractures can be satisfactorily immobilized by direct transosseous wires but, in general, when a surgical exposure has been made it is just as easy to apply a mini-plate if available. Transosseous wires do not provide rigid osteosynthesis, and supplementary fixation may be necessary. At the upper border they may be somewhat easier to apply from an intra-oral approach, and in this position are less likely than plates to impinge on denture flanges at a later date. Lower border wiring in the molar region and angle of the mandible will usually require an extra-oral approach. When the neurovascular bundle crosses the fracture site it is easier to avoid damage with a trans-osseous wire than a screwed plate.

The special instrumentation required for the application of miniaturized plates is not available in all parts of the world where fractures require treatment, and wiring techniques continue to provide a simple and reliable alternative.

Circumferential wiring or straps

Oblique fractures of the edentulous mandible can be most effectively and simply immobilized by circumferential wires. A modification of the method is recommended in order to avoid placing the upper part of the wire immediately below the oral mucosa. Williams (1985) has described the use of miniaturized circumferential nylon straps as a useful alternative to wire. The only conceivable advantage these methods have over plating techniques is that they are less likely to impinge on a future prosthesis.

Transfixation with Kirschner wires

This method of fixation employs a 2 mm Kirschner wire inserted within the medullary cavity across the fracture site. When the edentulous mandible is reasonably thick the wire can be introduced through a stab incision in the overlying skin and a suitable point of insertion located on the cortex of the distal fragment. A hole is drilled through the cortex at this point and the wire directed into the medullary cavity and onwards across the reduced fracture site. The wire is cut off at the skin entry point from where it can be withdrawn when the fracture has healed.

In practice it is extremely difficult to insert a wire in this way without damaging the inferior dental vessels and nerve. The most satisfactory method of placing such a wire is to expose the fracture site by an external skin incision. The transfixing wire is passed first into the proximal or distal segment and drilled down the centre of the mandible to emerge through the cortex and skin at a point where the curvature of the jaw prevents further passage. The wire end attached to the drill will eventually come to lie opposite the fracture site, at which point the inserting drill is detached and the direction of the wire reversed so that it is made to pass back down the other fragment transfixing the fracture.

When the wire is inserted under direct vision, as in this latter technique, it can be usefully employed to immobilize fractures of the body of thin edentulous mandibles where a plate would be too bulky. It is not possible, however, to employ the technique in the ultra-thin mandible because of the risk of damage to the inferior dental nerve.

Kirschner wires and tools for their insertion are commonly available in any hospital with an orthopaedic department. It is useful for a maxillofacial surgeon to be aware of these techniques, which may be employed in a situation where more specialized instrumentation is not available.

Primary bone grafting

The ultra-thin mandible

Extreme atrophy of the edentulous mandible can occur to such an extent that the mandibular neurovascular bundle may come to lie above the bone covered only by soft tissue. While this is relatively uncommon and usually associated with old age, this is not always the case. Some female patients, particularly those suffering from premature osteoporosis and who have been edentulous from an early age, may have ultra-thin mandibles by the fifth decade. Fracture of the body of the mandible can result from minimal trauma and may indeed occur spontaneously. The fracture is usually displaced and may assume a 'bucket handle' deformity. Treatment of such a fracture by open reduction and internal fixation is often disastrous. The bone ends are difficult to reduce; further fragmentation may occur as the result of manipulation; and

eventual bone contact is minimal, which together with the interference of the local blood supply leads inevitably to non-union.

The panoramic tomogram provides a rough but useful classification. If the depth of the radio-graphic image of the thinnest part of the body of the mandible is less than 1 cm it should be classified as ultra-thin and therefore demanding special treatment.

Obwegeser and Sailer (1973) suggested primary bone grafting as a method of stabilizing and augmenting a fracture of the body of the *ultra-thin edentulous mandible*. Wood *et al.* (1979) successfully treated nine such fractures using autogenous rib grafts. A 5 cm length of rib is obtained as an autogenous graft. The rib is split and the two pieces are placed one on each side of the fracture site in the manner of a first-aid splint applied to a limb. The rib halves may be lashed together by a series of circumferential wires sandwiching the fractured bone ends between them. Iliac bone can be employed in a similar fashion (James, 1976). Alternatively and much more neatly the bone graft can be secured directly by means of self-tapping or lagged titanium screws 11 to 13mm in length.

Indirect skeletal fixation

A system of bone pins joined together by rods and universal joints can be used in edentulous mandibular fractures in the same manner as when teeth are present. The method is occasionally of practical use when there has been extensive comminution of a long segment particularly if this involves the symphysis.

Bone clamps such as the Brenthurst splint are theoretically of use to immobilize a fracture in a thin edentulous mandible avoiding direct surgical exposure of the fracture site. These systems are mainly of historical importance, in that they were developed in order to avoid operative exposure of either infected fracture sites, or fracture sites where the blood supply was known to be compromised.

Intermaxillary fixation using Gunning-type splints

The dental splint described originally by Gunning (1866) was a vulcanite overlay of the natural teeth which he used as a splint for the fractured dentate mandible. A similar splint for the edentulous mandible consisted of a type of removable monobloc resembling two bite blocks joined together. The modern Gunning splint is therefore more correctly described as a Gunning-type splint. These splints take the form of modified dentures with bite blocks in place of the molar teeth and a space in the incisor area to facilitate feeding. They can be used when the patient is edentulous in one or both jaws. If the patient is completely edentulous immobilization is carried out by attaching the upper splint to the maxilla by peralveolar wires and the lower

splint to the mandibular body by circumferential wires. Intermaxillary fixation can then be effected by connecting the two splints with wire loops or elastic bands (Figs 111 and 112). When the patient is edentulous in one jaw intermaxillary fixation is achieved by attaching the Gunning splint to whatever type of splint is present in the opposing jaw.

Properly constructed Gunning-type splints should hold the jaws in a slightly over-closed relationship, as in this position fractures of the body of the mandible are more effectively reduced. The edges of the splints should be slightly over-extended around the sulcus in order to minimize food entry under the fitting surface. When the jaws are immobilized over-extension does not lead to ulceration of the mucosa as it would in a functioning denture.

When treatment is completed, the peralveolar and circumferential wires are removed by cutting each wire close to the buccal sulcus and pulling firmly and rapidly. An anaesthetic is not required and if the wire is cut close to the point of mucosal entry this avoids a length of contaminated wire passing through the tissues. In spite of these precautions the passage of the wire during removal occasionally causes infection and it is wise to prescribe antibiotic cover for the procedure.

Gunning-type splints are still occasionally used as fixation for fractures of the edentulous mandible, which justifies describing the technique in some detail. The method is useful for simple fractures treated by surgeons of limited experience. It is, however, a technique which is far from ideal. The splints become exceedingly foul during 4-6 weeks' fixation as a result of food stagnation between the poorly fitting surface of the splint and the mucosa. Apart from the *Candida-induced* stomatitis which results, there is a significant incidence of more serious infection of the wire track within the tissues. These splints are inefficient as a method of immobilization and provide poor control of mobile fractures, particularly when the mandible is very thin. They are unfortunately least efficient in those cases where closed reduction is most desirable.

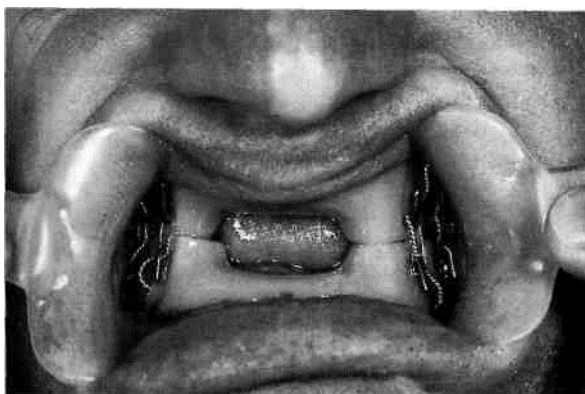

Figure 111. Gunning-type splints wired in position by circumferential and peralveolar wires. Intermaxillary fixation is effected with 0.45 mm soft stainless-steel wire between the upper and lower hooks.

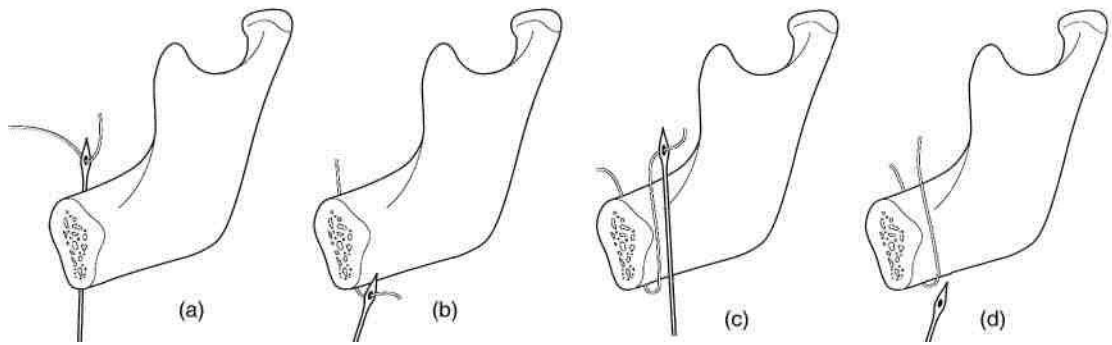


Figure 112. Method of passing a circumferential wire around the body of the mandible, (a) An awl is pushed through the skin beneath the chin and up into the mouth on the lingual side of the mandible. A length of 0.45 mm soft stainless-steel wire is threaded into its tip. (b) The awl is withdrawn to the lower border of the mandible, (c) Keeping the awl close to the bone it is passed around the lower border and then pushed up into the buccal.

Fractures of the edentulous mandible: synopsis

1. In the edentulous mandible reduction and fixation is mainly required for fractures of the angle and body with a view to restoring an adequate denture-bearing area and avoiding facial deformity.
2. Because of the risk of non-union resulting from interference with the periosteal blood supply, reduction should be accomplished with minimal exposure. Many undisplaced fractures require no active treatment.
3. Although Gunning-type splints can be used to achieve fixation after closed reduction, their inherent disadvantages make other methods preferable in all cases requiring active treatment.
4. In otherwise fit patients, open reduction and direct osteosynthesis is the method of choice. Intermaxillary fixation should be avoided wherever possible.
5. The most effective form of osteosynthesis is by non-compression miniplates. Compression plates offer theoretical advantages which are outweighed by their size in relation to the edentulous bone.
6. When the mandibular body is less than 10 mm in depth, fracture treatment becomes difficult and non-union is more likely. It must be remembered that stable fibrous union may be an acceptable result in the very old or infirm patient. Although transfixation procedures utilizing Kirschner wires have their protagonists, the method is only occasionally used, and the same may be said of systems employing bone clamps and pins. However, when there is extensive comminution these methods should be considered.

7. The ultra-thin mandible will not usually unite satisfactorily with conventional methods of reduction and fixation and in these cases autogenous bone grafting as a primary procedure should be the method of choice where the patient's general condition permits.

GENERAL PRINCIPLES OF TREATMENT OF MANDIBULAR FRACTURES

A number of interrelated factors determine the choice of a method of treatment. Some of these may be enumerated as follows:

1. The fracture pattern.
2. The skill of the operator.
3. The resources available.
4. The general medical condition of the patient.
5. The presence of other injuries.
6. The degree of local contamination and infection.
7. Associated soft-tissue injury or loss.

The simplest method of treatment is not necessarily synonymous with the best, and maxillofacial surgeons need to be trained in all available skills to best serve the patient under their care. Increasingly direct skeletal fixation without the need for total immobilization of the jaw is being shown to produce consistently good results. Such methods demand special skills and resources to match. Even with special skills the necessary surgical instrumentation may not be available. The most complicated of fractures of the mandible can be successfully treated with a suitable selection of arch bars and 0.45 mm soft stainless-steel wire, and these traditional techniques should not be lightly discarded. It should be remembered that in fractures of the tooth-bearing portion of the mandible the restoration of the occlusion is of prime concern and methods which rely at least in part on intermaxillary fixation consistently achieve this end.

Severely displaced or comminuted fractures of the mandible, many fractures of the condyle and fractures of the thin edentulous mandible are all injuries of considerable complexity which tax the skills of even the most experienced maxillofacial surgeons. In any type of mandibular fracture more than one method of treatment may well be suitable, and the eventual choice may depend on such factors as the general condition of the patient, the timing of the treatment of other injuries, the presence of infection and even the availability of an operating theatre.

TREATMENT OF FRACTURES OF THE MID-FACE AND UPPER FACE

GENERAL PRINCIPLES

The definitive treatment of fractures of the mid-facial skeleton must, of necessity, vary according to the pattern of injury. Basically, in common with other fractures, treatment consists of reduction and alignment, with immobilization of the fragments until union has occurred. Not all mid-face fractures need active fixation following reduction, however. For example, most simple nasal fractures and a number of zygomatic complex fractures will be stable without further surgical intervention.

There have been continuing developments in the methods of fixation used in mid-face fractures. The older methods of internal packing or external pin fixation of unstable nasal and zygomatic fractures have now largely been replaced by bone plates. Similar changes have also taken place in the treatment of maxillary fractures. Prior to the development of miniature bone plates it was common to treat Le Fort type fractures using either internal wire suspension within the tissues, or external fixation with a system of metal rods fixed to the cranium. These methods are now considered virtually obsolete and, in common with mandibular fractures, the preferred method of treatment for most maxillary fractures involves open reduction and internal fixation. Transosseous wiring can still be effective in certain situations but the versatility of the many semi-rigid plating systems available makes this technique the method of choice.

The differences in the surgical anatomy of the mid-face and mandible have already been considered. Due to the comminution which is common in fractures of the mid-face there has, in the past, been some controversy as to whether bony union actually occurs following these injuries or whether the end result is often fibrous union. Bony union will depend largely on whether there is intimate contact of the fragments following reduction. This is best achieved by open reduction and internal fixation although closed reduction methods will normally ensure apposition of the main bony struts of the mid-face. The greater part of the union will therefore be bony. This is less predictable, however, when there is gross comminution of thin cortical bone, such as may occur in the lateral antral wall or naso-ethmoidal complex. In this situation it is conceivable that fibrous union, or even resorption, may take place. Indeed, the periosteal stripping required if internal fixation is to be applied to these small fragments may actually contribute to the process.

Since many mid-face fractures are best treated by open reduction the surgical approaches in common use will be described first before discussing treatment. Appropriate exposure of the mid-face can be achieved using a variety of incisions, all of which should have minimal cosmetic

morbidity. Depending on the pattern of fracture, these incisions can be used singly or in combination. In practical terms exposure of the inferior, middle or superior aspects of the mid-face may be required. This in turn corresponds to access to the maxilla, the orbito-zygomatic complex, or the naso-frontal region (Table 4).

Table 4. Surgical approaches to mid-face and upper face fractures

1. Incisions for surgical exposure of the maxilla

- I. Vestibular*
- II. Palatal*
- III. Mid-face degloving procedure*

2. Incisions for surgical exposure of the orbito-zygomatic complex

- I. Supero-lateral orbital rim*
 - (a) Lateral eyebrow
 - (b) Supratarsal fold ('upper blepharoplasty')
 - (c) Extended preauricular
 - (d) Coronal
- II. Lateral orbital rim and body of zygoma*
 - (a) Lateral canthus ('crow's foot crease')
 - (b) Extended preauricular
 - (c) Coronal
- III. Inferior orbital rim and orbital floor*
 - (a) Midtarsal
 - (b) Subciliary ('lower blepharoplasty')
 - (c) Transconjunctival

3. Incisions for surgical exposure of the medial orbital wall, naso-ethmoidal complex and frontal bone

- I. Local (forehead and nasal bridge)*
- II. Coronal (scalp)*

SURGICAL APPROACHES TO FRACTURES OF THE MID-FACE AND UPPER FACE

An existing overlying facial laceration may sometimes give entirely suitable access. However, caution should be exercised in further extending a laceration to any extent, especially if treatment of the fracture is delayed, since an elective surgical incision usually gives better exposure and a better cosmetic result. The timing of the repair of mid-face fractures has already been discussed. Gross swelling is common within a few hours of injury and surgery is often delayed until this settles. Approaches to the periorbital and nasoethmoidal regions in particular are very difficult in the presence of gross oedema due to the turgor of the tissues and loss of the normal surgical planes.

Incisions for surgical exposure of the maxilla

Vestibular

A vestibular incision through the non-keratinized mucosa overlying the alveolar process, followed by subperiosteal elevation, gives excellent access to most of the antero-lateral aspect of the maxilla. A relatively limited unilateral incision is all that is required to expose the base of the zygomatic buttress, whilst a molar to molar incision gives access to the whole maxilla from the Le Fort I level to the inferior orbital rims. The subperiosteal dissection is often slightly more difficult than normal due to oedema and displacement of the bone segments. Comminution of the antral wall and base of the zygomatic buttress is common in zygomatic and Le Fort fractures, and small bone fragments may be lost as a result of periosteal detachment. This needs to be allowed for when placing miniplates.

Palatal

In severe facial injuries there may be a midline split of the maxilla. It is important to recognize this if the occlusion is to be restored correctly. If necessary a short miniplate can be placed across the fracture through a small sagittal palatal incision. Ideally this incision should be to one side of the fracture to minimize the chance of an oro-nasal fistula developing, but this is a counsel of perfection. Indeed, there may already be a laceration of the palate due to the fracture. It is advisable to avoid raising a full mucogingival palatal flap since this, in combination with a vestibular incision, will put the blood supply to the mobile maxillary segments at risk.

Mid-face degloving procedure

This is very rarely indicated but may have a use in the exposure of some Le Fort II fractures. The technique was first described by Casson *et al.* (1974) and essentially combines an intraoral vestibular approach with a degloving of the lower half of the nose to allow wide exposure of the whole maxilla including the nasal skeleton. Bilateral intercartilaginous incisions between the alar and lateral cartilages are made as for a rhinoplasty. The skin is elevated over the lateral cartilages and nasal bones and a transfixion incision extended along the dorsal and caudal aspects of the septal cartilage to detach the columella. The intraoral vestibular incision is then used to expose the nasal spine and piriform aperture. The nasal mucosal attachment to these structures is divided to allow the premaxillary dissection to join the transfixion incision. Retraction of the soft tissues with further wide subperiosteal dissection to the inferior orbital rim will allow complete exposure of the central mid-face skeleton. At the end of the procedure careful re-draping and suturing of the intranasal incisions is carried out and a nasal splint applied to minimize haematoma formation.

FRACTURES OF THE NASAL BONES

These are the most frequent fractures of the facial skeleton in clinical practice. The vast majority of nasal fractures can be treated by closed manipulation and simple splinting. It is advisable to wait 5-10 days before reduction for the swelling to subside since this allows a clearer assessment of the injury.

More severe injuries, normally due to high-energy frontal impact, may need open reduction. These grossly displaced fractures of the naso-ethmoid complex, which are often associated with other facial injuries, will be considered later.

Reduction

Simple nasal complex fractures with minimal displacement can be reduced under local analgesia. General anaesthesia with an oral endotracheal tube is still preferred by most surgeons and is definitely indicated when there is significant deviation or septal fracture. An adequate throat pack is essential because haemorrhage may be profuse.

Walsham's and Asche's forceps are used for manipulating the fragments. The unpadded blade of the Walsham's forceps is passed up the nostril and the nasal bone and associated fragment of the frontal process of the maxilla are secured between it and the padded blade externally (Fig. 113). The fragments are manipulated into their correct position and then the manoeuvre is repeated on the opposite side.

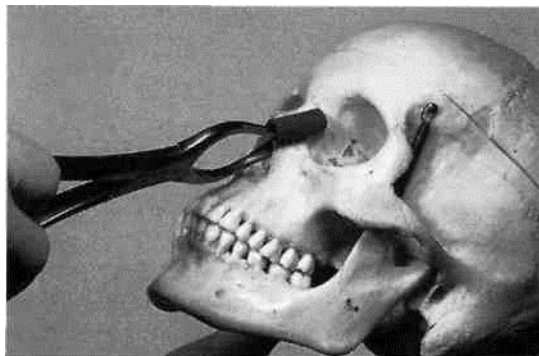


Figure 113. Position of Walsham's forceps when reducing fractures of the nasal complex.

Next, the vomer and the perpendicular plate of the ethmoid are 'ironed out' with the Asche's septal forceps, using one blade each side of the septum and then, if possible, the septal cartilage is grasped and brought forwards and repositioned in its groove in the vomer. Murray *et al.* (1984) maintain that consideration should be given to a limited submucous resection of the septum in many nasal fractures. They showed that a C-shaped fracture involving the perpendicular plate of the ethmoid and the vomer is common when significant deviation of the nasal bones is present. Resection of the cartilage and bone adjacent to this fracture is advocated

to prevent later collapse and poor nasal airway function. Despite their findings it has to be said that this procedure is not commonly carried out in clinical practice.

When the septum has been realigned the finger and thumb of one hand are used to compress the lacrimal bones and medial walls of the orbit on each side to achieve a narrow bridge to the nose. Finally, a fine sucker should be passed down each of the nares to ensure that they are clear and that the patient has a patent nasal airway.

If the nasal bones are severely comminuted it is often sufficient to mould the nose into shape between the thumb and forefinger, or by applying a thumb along each side of the nose and squeezing. Such fractures tend to be less stable after reduction.

Fixation

When the fracture is minimally displaced, it may be unnecessary to splint the nose following reduction. Usually, however, some sort of splint fixation is advisable.

There are a number of custom-made malleable or thermoplastic splints available but many surgeons still prefer a plaster-of-Paris splint. This consists of eight layers of plaster-of-Paris bandage cut so as to produce a strip of plaster across the bridge and covering either side of the nose, with an extension up to the forehead.

The splint is moulded into place while soft and held while it sets. It is then fixed into position with strips of adhesive tape across the forehead and across the nasal bridge (Fig. 114). A *light* nasal pack can be placed for 24 hours to help haemostasis but care must be taken to prevent over-packing and displacement of the nasal bones.

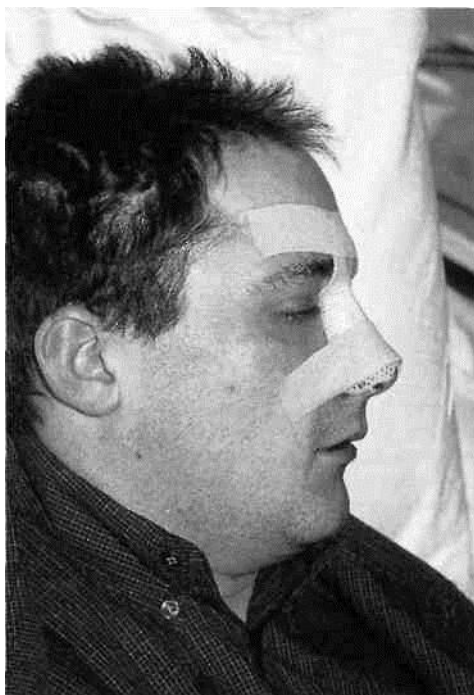

Figure 114. Thermoplastic material used to form an external nasal splint. The splint should extend and be carefully moulded into the medial canthal area.

Ideally a fresh, accurately fitting splint should be applied a few days later when the post-operative oedema over the nasal region has subsided. A nasal splint should be left in situ for about 10-14 days in total. The aim of a splint is to help maintain an already adequately reduced and stabilized fracture. It is also protective and reminds the patient to avoid unnecessary contact.

Simple external splints are not effective in maintaining unstable reductions in the hope that they will heal properly. If the nasal fracture is too mobile to be efficiently stabilized with an external splint a lead-plate splint, or Silastic button splint, is used either side of the nose. These plates, each with an upper and lower hole through the centre, are shaped and fitted either side of the nose with the edges carefully moulded to prevent chafing of the skin. They are held in position by a mattress suture of tantalum or 0.35 mm soft stainless-steel wire, which is passed through the holes in the plates with a fine awl, the wires transfixing the tissues and passing beneath the nasal bones (Fig. 115). This splint is left in situ for about 3 weeks.

Occasionally, if the nasal complex region is particularly flat, it is impossible to achieve a satisfactory result with closed reduction methods. Open reduction, as described in the section on naso-ethmoid fractures, may be a better but more demanding alternative.

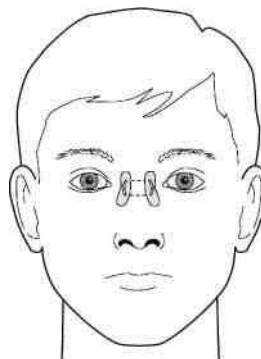


Figure 115. Diagrammatic representation of a fracture of the nasal complex splinted between two plates which are held in position by a mattress suture of fine stainless-steel or tantalum wire. The plates are shaped to fit into the medial canthal area with everted edges to avoid chafing the skin.

FRACTURES OF THE ZYGOMATIC COMPLEX

Zygomatic complex fractures with minimal displacement that are not causing symptoms do not necessarily require treatment. According to most reported series of fractures of the zygoma, around 20 per cent will not need surgical intervention. The indications for treatment are as follows:

- (a) To restore the normal contour of the face both for cosmetic reasons and to re-establish skeletal protection for the globe of the eye.

- (b) To correct diplopia.
- (c) To remove any interference with the range of movement of the mandible.

An assessment of the significance of the displacement is important. The cosmetic expectations of the patient are relevant and sometimes an obviously displaced zygoma is left if the patient is elderly and a poor operative risk. At the other end of the scale, in a young, fit patient, even a minimally displaced fracture should be elevated to restore contour, minimize the problems of late collapse and relieve pressure on the infra-orbital nerve (De Man and Bax, 1988). In general, cases with diplopia always require operation.

Reduction

Surgical reduction of the displaced zygomatic complex becomes increasingly difficult with the passage of time. If necessary the operation can be delayed for up to 10 days to allow the swelling to settle. After 2 weeks the displaced bones start to become bound down by organizing scar tissue but it is still better to attempt primary correction rather than to settle for secondary reconstruction. In practice, reduction can usually be achieved up to 6 weeks after injury and sometimes even longer.

Many zygomatic complex fractures are stable after reduction without any form of fixation, particularly where the displacement is essentially a medial or lateral rotation around the vertical axis without separation of the frontozygomatic suture (Rowe, 1994). Recent fractures tend to be more stable than those which are more than 2 weeks old. Fractures in which there is disruption of the frontozygomatic suture and those which are extensively comminuted are usually unstable.

Indirect reduction of a zygomatic fracture can be carried out by a temporal, percutaneous or intraoral approach.

Temporal approach

The Gillies temporal approach is popular and straightforward. The operation depends on the fact that the deep temporal fascia is attached along the superior surface of the zygomatic arch, whilst the temporalis muscle passes beneath the arch to be attached to the coronoid process and down the ramus as far as the retromolar fossa. Therefore, if an incision is made in the hairline in the temporal region and the temporal fascia is incised, it is possible to pass an instrument down on the surface of the temporalis muscle beneath the zygomatic arch. The zygomatic bone or its arch can then be elevated into its correct position.

A oblique 2 cm incision is made within the hairline between the bifurcation of the superficial temporal vessels. The temporalis fascia is exposed and incised and a Rowe's or Bristow's elevator passed down beneath the zygomatic bone, which is then elevated back into position (Fig. 116). The position of the bone is confirmed by palpation of the infra-orbital rim and the cheek prominence using the uninjured side is for comparison. One advantage of the Bristow's elevator is the ability to palpate the infra-orbital rim with one hand while manipulating the bone with the other. When palpating the reduced position it is important to relate the prominence of each zygomatic body to a common point distant from the bone, such as the glabellar region, since periorbital soft tissue swelling on the fractured side can give a false impression. When a satisfactory stable reduction has been obtained the temporal fascia and skin are sutured.

The Gillies approach is undoubtedly the most versatile method of indirect reduction. It is simple to perform and gives excellent control of the fractured zygomatic complex during all stages of reduction.

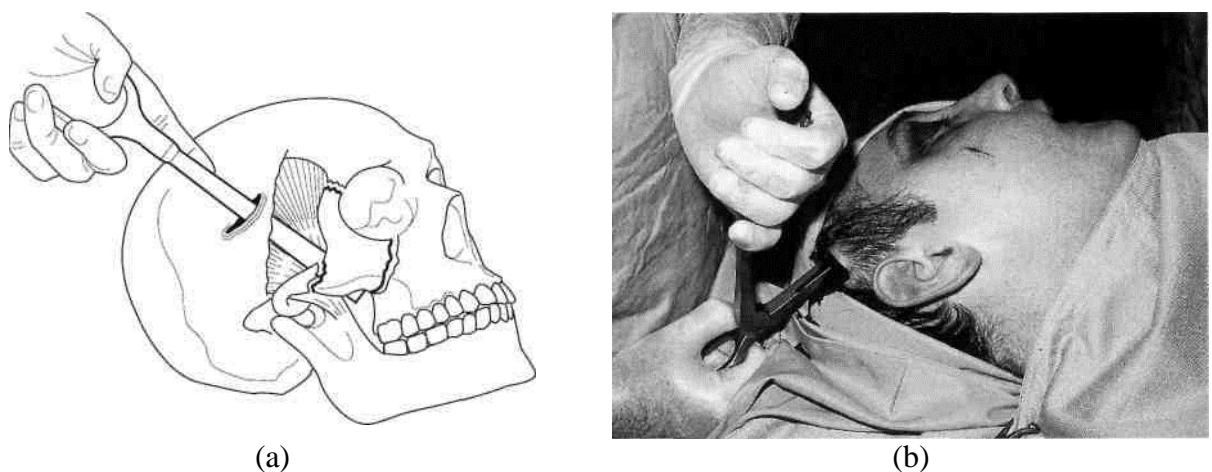


Figure 116. (a) Position of Bristow's elevator during the elevation of a fractured zygomatic bone. The instrument is passed through an incision in the temporalis fascia and down on the surface of the temporalis muscle beneath the zygomatic bone, (b) The same technique being performed using a Rowe's elevator.

Percutaneous approach

This rapid method is most useful in non-comminuted fractures with medial displacement and no distraction of the frontozygomatic suture. A number of hook-ended instruments have been designed for this purpose. The location of the stab incision for insertion of the hook elevator is found at the intersection of a perpendicular line dropped from the outer canthus of the eye and a horizontal line extending laterally from the alar rim of the nostril. The point of the instrument is kept in close contact with the undersurface of the body of the zygoma and traction is applied to reduce the fracture. A single fine suture is all that is required to close the wound, which is virtually invisible when healed.

Intraoral approach

Some surgeons prefer to elevate the zygomatic bone from an intraoral approach. However, although this technique has a long history, it is not widely practised. An incision is made in the upper buccal sulcus immediately behind the zygomatic buttress and a curved elevator is passed supraperiosteally to engage the deep surface of the zygomatic bone. Forward and outward pressure is exerted to reduce the fracture.

Fixation

Temporary support

If the reduced zygomatic complex is unstable as a result of comminution or delayed reduction some form of temporary support can be considered as an alternative to open reduction. Antral packs were advocated for this in the past but the indications for their use have waned considerably with the advent of miniature bone plates. Nevertheless, antral packing is still an effective way of managing the grossly comminuted fracture, and can have a useful part to play in the support of orbital floor fractures where there is no bone loss. For comminuted zygomatic fractures the pack should be directed chiefly to the outer aspect of the antrum beneath the body of the zygoma, whilst for support of the orbital contents it should be applied much more gently in the space between the undersurface of the orbital floor and the antral floor (i.e. the antral surface of the maxillary alveolus).

The sinus is approached through a buccal sulcus incision. An opening is usually present as a result of the fracture; otherwise a window into the sinus is made through the canine fossa. The opening is enlarged, and any blood clot and fragments of bone within the sinuses are evacuated. The operator gently repositions any fragments of the orbital floor with a finger and the antrum is then packed in a concertina pattern. The pack should be composed of 5 cm ribbon gauze soaked in Whitehead's varnish (Pigmentum Iodoform Compound: B.P.C.). This will remain uninfected during the period needed for stabilization of the fracture. White-head's varnish contains a number of aromatic resins, which are very slowly broken down to produce benzoic acid. It is this slow release of a potent antiseptic, together with the waterproofing property of the compound, which makes it superior to other media. Antral packs are best left completely enclosed within the sinus, beneath the suture line in the buccal sulcus, by which route they are easily removed. The presence of a pack must be recorded prominently in the patient's operation notes.

An antral pack should be retained until the bone it is supporting is stable, which will normally be about 3 weeks. However, in some grossly comminuted fractures it may be necessary

to retain the pack for much longer, and indeed to replace a pack by another if the fragments are still mobile after the initial removal. If support is not maintained in this way, late contracture and flattening of the profile may occur.

When packing the antrum great care must be taken not to displace any bony spicules of the orbital floor against the optic nerve and ophthalmic artery. For this reason any pack used to support the orbital floor must be very carefully applied, and in most cases it is advisable to expose the orbital floor from above to ensure controlled application of the support. For the same reason when there is an associated Le Fort I, II or III fracture, this should be reduced and immobilized before packing the antrum. If the antrum is packed and the mid-face is then manipulated, the antral pack will be forced against the orbital floor with the risk of damage to the orbital contents.

Balloon catheters in the antrum have been advocated instead of a pack but they have the disadvantage of expanding uniformly in all directions so that pressure cannot be exerted to the correct sites with any degree of accuracy.

Direct fixation

Although antral packs have been used in the past for unstable and comminuted fractures, these are best treated by open reduction and internal fixation. This is also the method of choice where there is significant separation at the frontozygomatic suture, and can be achieved by transosseous wiring or bone plating.

Transosseous wiring

Wiring of the frontozygomatic suture is a time-honoured method but there is experimental and clinical evidence to suggest that it is not enough on its own to resist late contraction forces. Even if frontozygomatic wires are supplemented by infra-orbital wiring the fracture may not be stable in the long term. Larsen and Thomsen (1978) found 30 per cent of patients had residual deformity at late follow-up. Altonen *et al.* (1976), in a comparative study of wiring, antral packs or no fixation, demonstrated a 13 per cent incidence of late flattening of the zygomatic prominence in the wired group. Furthermore, wiring at the infra-orbital margin is technically difficult if there is comminution of the rim, with the risk of avulsion of small fragments.

Despite concerns about the true effectiveness of the technique, transosseous wiring at the frontozygomatic suture is still the best option if plates are not available. It is also useful as a temporary means of fixation whilst the other fracture sites, namely infra-orbital and zygomatic buttress, are inspected to confirm alignment and fixed with plates as necessary.

Small holes are drilled in the zygomatic process of the frontal bone and the frontal process of the zygomatic bone and, after the fracture has been reduced, the zygomatic bone is fixed in position by a piece of 0.45 mm soft stainless-steel wire passed through the two holes and twisted up. Greater stability may be achieved by passing a figure-of-eight wire.

Bone plates

These constitute the most secure method of fixation for an unstable fracture of the zygomatic complex. Following the early reports of Vitallium miniplates by Michelet *et al.* (1973),

Champy and Lodde (1976) designed a stainless-steel plate for orbital trauma. The original designs have been copied and modified by various suppliers and there are now a large number of maxillofacial plating sets available for use. Titanium has replaced stainless-steel in view of its relatively bio-inert properties, but some surgeons still advise removal in view of possible long-term effects, although this is not common practice in the UK.

In addition to the standard miniplate there are low-profile versions which are easier to adapt and less palpable beneath the soft tissues. For very small, thin fragments, such as the inferior orbital rim, an even smaller microplate is available. A number of different lengths and shapes are provided in most plating sets, and there are also mesh and special grid-design plates for use in orbital floor or cranial repair.

Resorbable plates and screws for use in the maxillofacial region have been a more recent development. Some of the early papers describe the use of poly-L-lactic acid (PLLA) plates in the fixation of zygomatic fractures. Early and late cellular reactions to the crystalline degradation products, particularly evident when the plates were placed beneath the thin, soft tissues overlying the frontozygomatic suture, led to the development of modified materials such as copolymers of L-lactic acid and D-lactic acid, or copolymers of L-lactic acid and polyglycolic acid. Initial results using these more biocompatible materials in zygomatic fractures seem promising, although the thickness of the plates and the size of the screws preclude their use at the infra-orbital rim. The theoretical advantages of resorbable plates may be obvious but the true benefits of these materials compared with titanium have yet to be proven in a controlled randomized study.

Whether metal or resorbable plates are used the question still arises as to how many fracture sites need to be plated to be sure of an initial stable result. Davidson *et al.* (1990) have considered this in an experiment using human dried skulls. Various combinations of plates and wires were used at the frontozygomatic suture, infra-orbital rim and zygomatic buttress. Forces were then applied to the zygoma to simulate the muscle pull of the masseter. Not surprisingly they found the more sites plated, the more stable the result. Even wires were very effective if

applied well to all three sites. They found a single standard miniplate at the frontozygomatic suture to be unsatisfactory in many instances, and consequently recommend that a minimum of two sites should be plated for optimum results. This is essential if less robust low-profile plates are used. A thicker compression plate at the frontozygomatic suture has been advocated as a means of achieving stability with a single plate but the technique is less forgiving and the plate has to be removed later. Experience shows that semi-rigid non-compression plates are quite satisfactory for mid-face fractures, where the displacing forces are much less than in the mandible.

The decision about which sites to plate depends to some extent on the type of displacement. The orbital floor is always involved in zygomatic fractures and, if there is evidence of herniation into the antrum or significant displacement of the orbital rim, surgical exploration is advised. A plate at the orbital rim in addition to the frontozygomatic suture is then the obvious treatment, although comminution of the rim may compromise its effectiveness.

If there is no strong indication to explore the orbital floor a buttress plate may be a better alternative. This allows inspection of the accuracy of reduction in this critical area. It is possible to obtain good reduction at the lateral and inferior orbital margins and still to have a poor result because of rotation around the vertical axis or medial displacement at the base of the zygomatic buttress. This in turn will mean that the postero-lateral orbital wall is poorly reduced with a failure to restore orbital shape and volume. Some unexpected late enophthalmos may be due in part to this mechanism.

If open reduction is planned from the outset it is usually possible to reduce the fracture through the incision used to expose the frontozygomatic suture. If this proves difficult a Gillies temporal approach should be used to get maximum control. As mentioned above, it may be advisable to place a temporary wire at the frontozygomatic suture until the other sites are explored and reduced. As with all fractures, zygomatic complex fractures need to be considered in three dimensions, and a mistake at the first fixation site will be compounded at the others.

Indirect fixation

The reduced zygomatic bone can be fixed indirectly to other parts of the facial skeleton while healing takes place. For example, extra-oral fixation can be applied using a rigid rod connected by universal joints to a threaded bone pin in the supra-orbital ridge and another in the body of the zygoma. Another method which has been popular in the past as a means of rapid stabilization is transantral internal pin fixation with a Kirschner wire. Similarly, Brown and Barnard (1983) described a transnasal approach in which the pin is inserted through the frontal

process of the contralateral maxilla across the nasal cavity to engage the antral surface of the fractured zygoma.

These methods may have limited usefulness in stabilizing an excessively mobile zygoma, or in reinforcing wire fixation, but the development of plating techniques has probably made them virtually redundant.

Fractures of the zygomatic arch

Fractures of the zygomatic arch associated with fractures of the zygomatic bone and other elements of the zygomatic complex usually become repositioned when the main zygomatic bone fragment is surgically elevated into its correct position. Open reduction and internal fixation is only required if there is gross displacement, or as part of the repair of complex multiple mid-face fractures.

Isolated fractures of the zygomatic arch are not uncommon following direct injury to the area. Classically a V-shaped depressed fracture occurs and may interfere with mouth opening. In this situation the fragments should be reduced via a Gillies approach. A light instrument, such as a Howarth's elevator, is usually sufficient to reduce the fracture, which clicks back in place easily if treated early enough. Fixation is normally unnecessary as the temporalis fascia attached along the superior aspect of the arch will provide the necessary immobilization. Fragments of the zygomatic arch will only be displaced downwards if their attachment to the temporalis fascia is stripped away. For this reason care should be taken to ensure that the elevator is passed deep to the arch on insertion. In the very rare event that temporary support of very mobile fragments is needed, a balloon catheter can be passed beneath the arch through the Gillies incision and inflated with normal saline. Alternatively a wooden spatula can be placed externally over the arch and held in place with circumferential wires or heavy suture material. Open reduction and fixation is probably a better option.

LE FORT I, II AND III FRACTURES

General factors affecting treatment

There are a number of special anatomical problems in the mid-facial region which complicate the basic principles of reduction and fixation in Le Fort-type fractures. These are described below.

Complexity of the facial skeleton

Although the facial skeleton tends to fracture along broadly predictable lines of weakness, the resulting injury can be extremely complicated. It is very rare for the separated fragment to exist as a single block of bone. In the past the main guide for reduction of the

fracture was the restoration of the occlusion and, despite advances in internal fixation, this still remains a crucial aspect of treatment in the dentate patient. However, because the mandible is moveable, simple re-establishment of the occlusion, for example by inter-dental wiring, only corrects the relative position of mandible to maxilla. This does not give a precise register of the position of the mobile mid-face in relation to the cranial base. In addition to occlusal restoration, accurate repositioning in the vertical and transverse dimensions is needed in mid-face fractures in order to achieve the correct facial balance. This exercise becomes more difficult the more complicated the fracture.

The actual injury is often a complex of Le Fort I, II and III type fractures. Isolated Le Fort III fractures in particular are very rare. Furthermore, the nasal skeleton and the walls of the paranasal sinuses may be extensively comminuted and compressed into the main body of the skeleton of the mid-face. The restoration of facial form requires reconstruction of this complex facial shell, a task that is often hampered by the degree of comminution.

Other associated facial bone fractures

The fractured central mid-face is often only part of a complex which may include fractures of the mandible, zygoma, frontal bone and nose. Sometimes the inexperienced surgeon does not know where to start reorganizing these multiple displacements. But essentially the outer ring or framework of the face is reconstructed first by reducing the frontal bone and orbital roof above, the zygomatic complex on each side and the mandibular platform below. Once the outer frame of the face is re-formed the central block can be reduced and fixed within it, utilizing the occlusion as a locating point below and direct fixation to the reduced craniozygomatic complex as a key above. Finally, the nasal complex can be re-contoured and supported in its correct relationship to the reduced central mid-facial bone mass.

Airway management

The problems of reduction of the facial fractures are compounded by the need to maintain an airway and in most cases to administer a general anaesthetic. Under general anaesthesia it is usually difficult to re-establish the occlusion unless nasal intubation or tracheostomy is performed. Tracheostomy should only be performed when there are specific surgical indications such as head or chest injury. Occasionally a reinforced oral endotracheal tube can be inserted to emerge through the mouth laterally posterior to the dentition in the retromolar region, and techniques have also been described in which the tube is brought out through the floor of the

mouth. These measures are usually unnecessary since the majority of patients with mid-face injuries can be anaesthetized successfully utilizing a nasal endotracheal tube.

Most nasal fractures occurring in association with other fractures of the central mid-face can be treated satisfactorily with a nasal tube in place. Reduction is made easier if the tube is situated so that it drapes laterally across the cheek, in which position it causes minimal deformation of the nose and minimal interference with access incisions (Fig. 117). Oral intubation becomes necessary in the rare instance when there is extensive soft-tissue damage to the nose, in which case there may be a compromise in the accurate positioning of the tooth-bearing segment of the maxilla during surgery, even if open reduction techniques are employed.

Problems of fixation

As has been noted above, even if intermaxillary fixation is applied it is insufficient to stabilize the mid-facial skeleton because of the mobility of the lower jaw. After using the mandible as a guide to accurate reduction, the mid-face must be immobilized by attaching it to the adjacent facial bones or to some distant fixed point such as the cranium. Historically this was achieved by attaching the facial bones to the skull using a dental splint or arch bar attached to a system of rigid extraoral rods fixed to a plaster head-cap, halo frame or supra-orbital pins (craniomaxillary fixation; Banks, 1975). Alternatively, internal systems of fixation were used which depended on suspension wires within the tissues running from some fixed point on the cranium to the mandible, supporting the reduced mid-face fracture in between (cranio-mandibular fixation; Adams, 1942; Adams and Adams, 1956). These older methods may still have an occasional place as fast emergency treatment, or where plating equipment is not available, but in common with mandibular fractures semi-rigid plate fixation is now the accepted treatment of choice for most mid-face fractures. Additional intermaxillary fixation is often advisable in complex trauma because gross comminution can make it difficult to obtain complete stability of the tooth-bearing segment even if plates are used.

Surgical management

Reduction

The key to the successful reduction of maxillary fractures is thorough mobilization. This is true even when open reduction and internal fixation techniques are planned because accurate repositioning and alignment is difficult without easy manipulation of the bony fragments.

The inherent degree of mobility of Le Fort fractures following injury varies considerably. To a large extent this depends on the amount of displacement and comminution. In some situations it may be possible to reduce low-level maxillary fractures simply by finger manipulation alone. At the other extreme, with very firmly impacted Le Fort I and II fractures, it may be necessary to expose the fracture line through an incision in the buccal sulcus in order to mobilize it with an osteotome before reduction can be carried out.

The techniques described below, which were previously used for closed reduction of mid-face fractures, are now a useful preliminary to plate fixation under direct access.

Le Fort I (Gue'rin or low-level) fractures

Rowe's disimpaction forceps are invaluable in the mobilization of most maxillary fractures. The maxilla is held with two pairs of Rowe's disimpaction forceps (Fig. 117). Each unpadded blade is passed up a nostril and the padded blade enters the mouth and grips the palate. Standing at the head of the operating table, the operator grasps the handles of each of the two pairs of forceps and manipulates the fragments into place. This is done by deliberate rocking and rotating movements in the sagittal and transverse planes, rather than simply attempting vigorous shaking in a misdirected manner.

Forward traction can be applied once the fracture is mobile but significant posterior displacement is actually unusual in Le Fort I fractures. So-called lengthening of the face is a more common physical finding and special attention should be given to correcting any inferior displacement of the posterior aspect of the maxilla to relieve 'gagging' of the posterior teeth and a subsequent anterior open bite (apertognathia).

It is important to realize that some Le Fort I fractures may be in two segments with a midline split of the palate or a separate dento-alveolar fragment. Injudicious use of Rowe's forceps can easily lead to an extensive laceration of the palatal mucosa in this situation (Fig. 118).

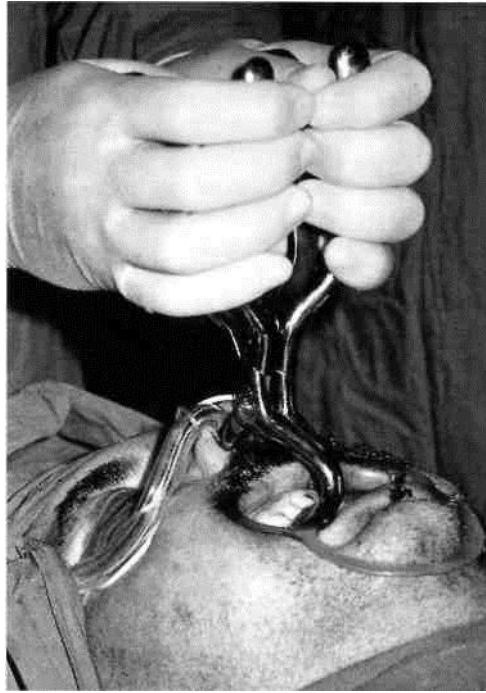


Figure 117. Rowe's disimpaction forceps in position to reduce the tooth-bearing portion of the upper jaw. Nasal intubation does not prevent application of the forceps. Note also the lateral positioning of the tube to minimize nasal distortion and facilitate surgical access to the orbital region.

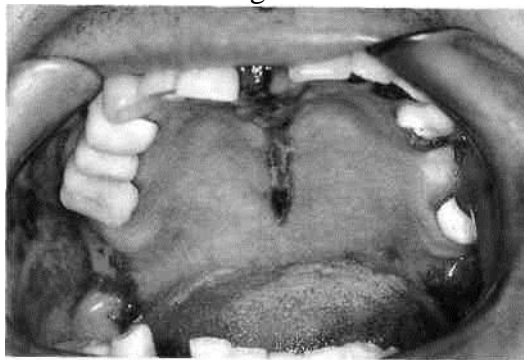


Figure 118. (a) A palatal laceration denoting underlying bony injury in a patient with a Le Fort I fracture with an associated midline split of palate, (b) Transverse axial CT scan of the same injury.

Le Fort II (pyramidal or subzygomatic) fractures

If the fracture is in one piece, it may be reduced in the same way as an impacted Le Fort I fracture employing two pairs of Rowe's disimpaction forceps. The fragment should be manipulated firmly away from the base of the skull until it is freely mobile. It should not be shaken indiscriminately because the fracture line frequently involves the anterior cranial fossa, which should not be further disturbed if possible. If, as is often the case, there is a coexisting Le Fort I fracture, manipulation with disimpaction forceps will only reduce the tooth-bearing portion. It may be difficult to mobilize the rest of the fragment but this can often be effected by grasping the nasal septum with Asche's or Walsham's septal forceps, while at the same time inserting a finger of the other hand up behind the soft palate and exerting forward pressure. Any

associated naso-ethmoidal fracture is treated after the tooth bearing portion is adequately reduced and immobilized.

Le Fort III (high-level or suprazygomatic) fractures

These severe injuries rarely occur in isolation, but when they do, displacement is usually fairly minimal and reduction is achieved after exposure of the frontozygomatic suture on each side.

Frequently there are associated Le Fort I and II fractures, often with separate zygomatic and nasal complex fractures. Extension of the fracture into the frontal bone and roof of the orbit may also occur (craniofacial fracture).

Disimpaction in this situation should be carried out in the following order:

1. Frontal and zygomatic fractures should be reduced and fixed under direct vision employing a coronal scalp flap for access (see below).
2. The upper part of the central mid-facial fracture can usually be reduced via the same approach.
3. The tooth-bearing portion is manipulated into a correct occlusal relationship by means of Rowe's disimpaction forceps.
4. After the main fragments of the central block have been reduced and fixed any remaining parts of the naso-ethmoidal complex are treated.

The structural pillars of the face are the key areas for assessment of the adequacy of reduction of complex facial fractures. It can be appreciated that the localization of the upper part of the mid-face depends on the frontal bone with its nasal and zygomatic processes, whereas the lower part depends on the zygomatic buttresses and the piriform aperture. These are also the areas most suitable for the application of bone plates. In the dentate patient occlusion with the mandibular platform is the ultimate key to localization at the Le Fort I level.

Fixation

The last two decades have seen major changes in the methods of fixation used for maxillary fractures. This has followed developments in surgical technique, shared with orthognathic and craniofacial surgery, and the refinement of semi-rigid miniature bone plating systems, which has both accompanied and driven many of these developments. In broad terms the move has been away from delayed closed reduction with internal wire suspension or external frame fixation to early open reduction and internal plate fixation (Table 5).

Table 5. Changing trends in the management of mid-face fractures

<i>Historical approach to treatment</i>	<i>Contemporary approach to treatment</i>
Common to delay surgery for 7-14 days	Earlier one stage repair advocated
Closed reduction in most instances	Emphasis on open reduction
Long periods of intermaxillary fixation	No intermaxillary fixation (or short periods only)
Small local incisions with restricted access for open reduction (if used)	Wide exposure of all fracture sites
Accuracy of reduction sometimes estimated, especially in vertical dimension	Anatomical reduction of structural pillars of the face
Wire osteosynthesis, wire suspension (craniomandibular) or external fixation (craniomaxillary)	Semi-rigid miniplate and microplate internal fixation (with primary bone grafting in some situations)

It has to be recognized that delays in treatment in the past often related to concerns about the management of a head injury, or the priority of other life-threatening injuries. As has been pointed out in Chapter 2, advances in anaesthesia have reduced the need for delay in cerebrally injured patients. It is alleged that early treatment will produce optimal facial bone repair but the reality of the situation in practice is that a delay of a few days often occurs. This is rarely a disadvantage, and it is usually beneficial as it allows the oedema to settle and the patient to be prepared for surgery.

Although direct fixation with semi-rigid plates and monocortical screws has become widespread there are still situations where older indirect methods may have a place and these will be described briefly for completeness. It is also important to realize that there are some areas of the world where relatively expensive bone plating systems are not available for routine use.

Direct fixation

Le Fort I fractures

Minimally displaced fractures of the edentulous maxilla may not need active treatment. In the dentate patient with a minimally displaced fracture 3 weeks of intermaxillary fixation is still an excellent and accurate method of treatment. The disadvantages of this time-honoured approach have to be weighed against the technical problems of bone plating. This is an unforgiving technique which depends on anatomical reduction and completely passive adaptation of the plates if occlusal discrepancies are to be avoided.

Surgical exposure is achieved through a vestibular incision. Comminution of the anterolateral antral walls is common and small fragments may become detached as the periosteum is elevated. Reduction with Rowe's forceps, either before or after the exposure, can add further to this comminution. It is better to rely on temporary intermaxillary fixation to restore the occlusal

relationship rather than simply offering up the mandible to the maxilla. Any split of the palate should be repaired with a plate or transosseous wire before applying the intermaxillary fixation, and associated dento-alveolar fractures will require stabilization with an arch bar or splint.

The maxillo-mandibular complex is positioned passively prior to plating. It is important to ensure that the mandibular condyles are seated correctly in their fossae to prevent a subsequent anterior open bite. Inspection of the piriform aperture and zygomatic buttress areas will confirm the accuracy of the reduction and the fixation plates should then be applied. Even when there is comminution at the base of the zygomatic buttress it is usually possible to find an area of bone contact between the alveolus and the buttress across which a plate can be placed. If this is truly not possible consideration should be given to bone graft reconstruction of the buttress or resorting to cranio-mandibular internal suspension and intermaxillary fixation.

At the end of the procedure the intermaxillary fixation is released and the occlusion is checked using passive movements of the mandible. Intermaxillary fixation is not necessary but may be desirable for a short period, particularly where there is comminution, a split palate, a separate dento-alveolar fracture, an associated mandibular fracture, or where there is any doubt about the accuracy of the occlusal relationship.

Le Fort II fractures

Where the fracture is in a single block it can be treated in a similar manner to Le Fort I fractures. Plates are usually applied to the zygomatic buttress and infra-orbital margin.

Occasionally exposure can be sufficient using a vestibular incision, but more commonly the vestibular approach is supplemented by a lower eyelid or transconjunctival approach to the orbital rim.

Le Fort II fractures are often associated with comminution of the nasal complex. A decision has to be taken as to whether the nasal fractures will be treated by closed reduction or whether open reduction and plating is indicated. If it is the latter and a coronal incision is used to gain access it may be possible to reach the infra-orbital rim in this manner although local incisions usually give better exposure for plating.

Le Fort III fractures

Monobloc Le Fort III fractures are exceedingly rare and are comparatively simple to treat by plating at the frontozygomatic and frontonasal sutures. More often the craniofacial dysjunction is a combination of bilateral zygomatic complex, nasal complex and Le Fort II fractures. This type of severe injury is also commonly associated with frontal bone fractures. CT scans will reveal the extent of fragmentation. Access to the whole upper and mid-face from the

cranial base to the maxillary occlusal level is obtained by using a coronal scalp flap with an intraoral vestibular incision. Bilateral lower eyelid incisions are often needed in addition to expose the infra-orbital rims and orbital floors. This combination of incisions effectively 'degloves' the mid-face so the blood supply to very small fragments is disrupted. In this situation they probably act as free bone grafts and may even resorb.

As has been pointed out already, the principle of management of these complex fractures is to reconstruct the outer facial frame first. This begins with fixation of both zygomatic complexes to the frontal bone laterally. Gruss *et al.* (1990) have stressed the importance of careful reconstruction of a comminuted zygomatic arch to act as the basis for correct positioning of the main body of the zygoma. If this is overlooked it may result in a failure to re-establish the forward projection and normal width of the bony mid-face (Figs 119). Rotation of the zygoma can also be missed and should be corrected prior to plating at the frontozygomatic suture. Direct inspection of the lateral aspect of the lateral wall of the orbit

will prevent this problem and it is possible to plate this area by elevating the anterior fibres of the temporalis muscle.

Once the lateral orbito-zygomatic frame has been reconstructed attention is directed to the central mid-face block. This will usually comprise a Le Fort II fragment with or without a separate Le Fort I component. The fractures are reduced and plates applied as necessary to the infra-orbital rim and zygomatic buttress to rebuild the facial bones. Temporary intermaxillary fixation is used to locate the tooth-bearing segment and to re-establish the occlusion with the mandible. Finally the nasal bones are manipulated and splinted or plated.

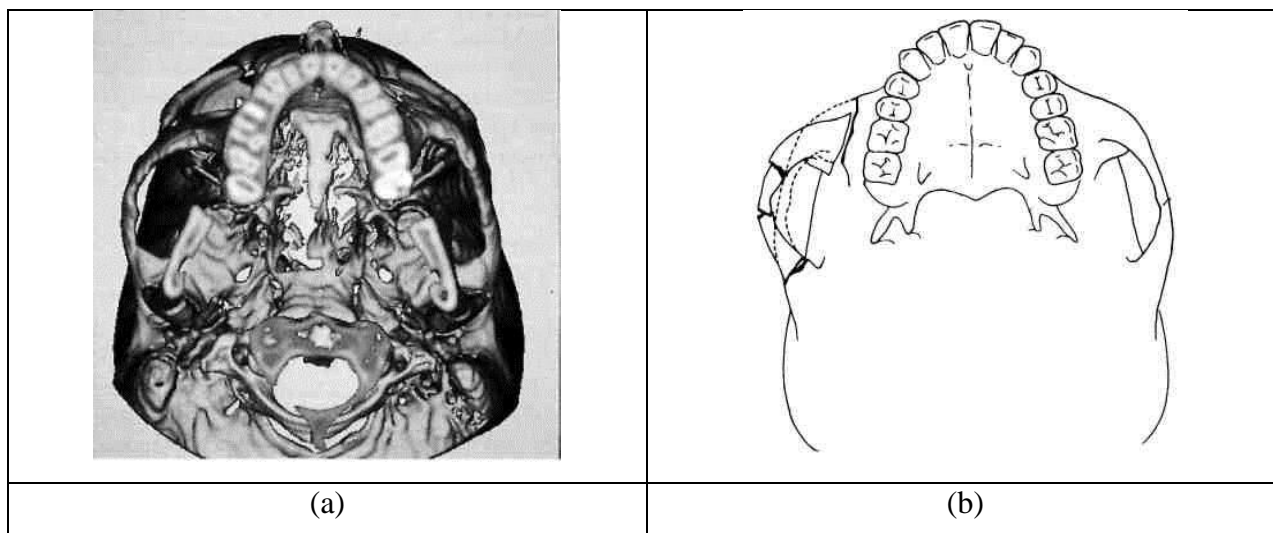


Figure 119. (a) Three-dimensional CT scan of an untreated zygomatic fracture showing how posterior displacement leads to rounding and loss of forward projection of the zygomatic arch, (b) Diagram illustrating how failure to correct this deformity will result in increased malar width and flattening of the face ('dished face').

Indirect fixation

Although indirect methods of fixation are considered less satisfactory there may still be a need for rapid immobilization in a patient who is otherwise unfit for a lengthy operation, and it has to be recognized that sophisticated plating systems may not be available in all clinical situations. In this event either internal wire suspension or external rod fixation is possible. The latter normally requires access to a maxillo-facial laboratory for the construction of modified arch bars or cast cap splints.

Internal suspension

The principle of this technique is to use some stable portion of the facial skeleton above the line of fracture as an anchorage point for the suspension wires, which are connected to circumferential wires in the lower canine region or a lower arch bar. The fractured maxilla is thus sandwiched between the mandible and the base of the skull. The wires are passed through the tissues with the aid of long curved needles, awls or cannulae (Adams, 1942; Adams and Adams, 1956).

The suspension may be:

- (a) Circumzygomatic: the wires pass over the zygomatic arch (Fig. 120).
- (b) Zygomatico-mandibular: the wire is passed through a small hole drilled in the body of the zygomatic bone, access being obtained through a small intraoral incision beneath the buttress.
- (c) Inferior orbital border-mandibular: wiring is carried out by drilling a small hole through the lower border of the orbit, access being obtained via an incision in the upper buccal sulcus.
- (d) Frontomandibular: the upper attachment is to a hole in the zygomatic process of the frontal bone, the approach being the same as for internal fixation of the frontozygomatic suture (Fig. 121). Alternatively, a central frontal bone attachment can be made to a screw inserted above the glabellar suture and suspension wires passed within the tissues each side of the nasal aperture to emerge into the mouth lateral to the piriform fossa.
- (e) Piriform fossa-mandibular wiring: the piriform fossa is approached by an incision in the buccal sulcus. A mucoperiosteal flap is raised to expose the lateral bony wall of the nasal cavity in which a hole is drilled.

None of these suspension techniques produces an absolutely rigid fixation. Some antero-posterior movements of the fragments are possible but these are controlled by combining the suspension with intermaxillary fixation, using eyelet wiring or arch bars.

Removal of the wires at the end of the period of fixation is achieved by traction on the cut end of the wire in the mouth, except for frontomandibular wires, which are removed

externally using a separate pull-out wire attached to the highest point of the loop. This is led out through a small skin perforation above the lateral aspect of the eyebrow (Fig. 121).

Most Le Fort I fractures can be treated by internal suspension using circumzygomatic wires or, if the zygomatic complex is separately fractured, frontomandibular wires. Relatively undisplaced Le Fort II fractures can be managed in a similar manner. It will be obvious that piriform fossa-mandibular wires can only be used in Le Fort I fractures. The other variations are rarely employed.

It can be appreciated that these methods, simple and useful as they are, are only indicated for relatively uncomplicated fractures. Antibiotic cover is advisable during the placement and removal of the wires.

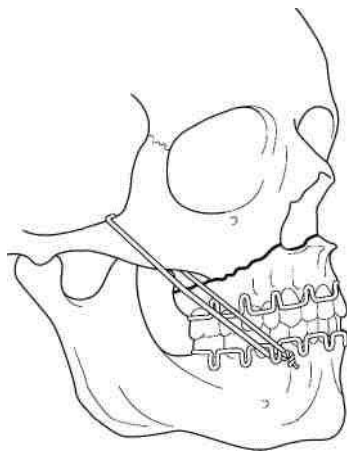


Figure 120. Diagram to show circumzygomatic-mandibular internal suspension.

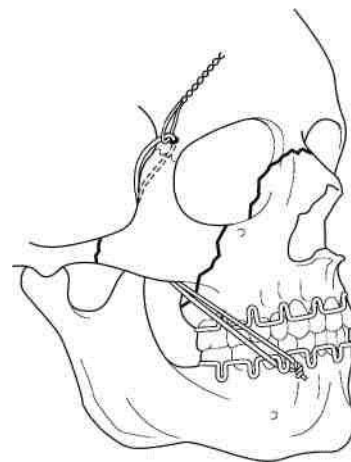


Figure 121. Diagram to show frontomandibular internal suspension with a pull-out wire at the highest point.

External fixation

This method of indirect fixation relies on a system of rigid rods and universal joints to immobilize the reduced maxilla by linking it to a fixed part of the frontal bone or cranium above. The rods are either connected to a modified skull frame (halo frame) or to a pair of bone pins inserted into the supra-orbital ridges. (Originally the rods were attached to a plaster-of-Paris head cap but complete immobility is impossible using this simple method.) All these techniques are now rarely used in clinical practice and their description here is mainly of historical interest.

Halo frame

This type of apparatus was first devised by Crawford (1943) and modified by Crewe (1966), who described a type of frame which encircles the head and is attached to the skull by four pointed screw pins which perforate the scalp to engage the outer table of the skull. The more versatile lightweight Royal Berkshire halo frame (Mackenzie and Ray, 1970) encircles three-quarters of the skull and is more comfortable when lying down since it leaves the occiput free. One midline and two laterally placed metal rods are attached to the halo frame and connected to

a projecting bar fixed to an upper arch bar, cast cap splint, or a Gunning's type splint if the patient is edentulous.

Supra-orbital pin fixation

Central mid-face fractures can be immobilized by attachment of the reduced maxilla to a pair of bone pins inserted into the supra-orbital ridges, assuming they are not also fractured. Coarse pitch screw pins (East Grinstead pattern) are most suitable for this purpose. A tapping hole is drilled via a small skin incision above the eyebrow at the junction of its medial two-thirds and lateral one-third. The hole should be placed 1 cm above the orbital margin and the drill directed towards the imagined centre of the eyeball until the hard cortical bone is just penetrated. The pin is easily screwed into place until it is firm, which usually involves little more than 5 mm penetration.

A transverse bar is connected to the two pins and by utilizing three rods, each joined to a projecting bar from the upper splint, sufficient vertical and antero-posterior support may be provided to the mid-face to allow the mandible to be freed, and the patient's fractured mid-face to be supported by craniomaxillary fixation alone.

Levant *et al.* (1969) designed a modified horizontal bar for connection to the supra-orbital pins. This carries a central U-shaped extension to allow two universal joints to be used to fix the midline connecting bar to the framework.

They maintain that this makes the system sufficiently rigid for a single rod to be used.

The 'box frame'

A system of pin fixation can easily be extended to form a rigid 'box frame' for the facial skeleton as a whole. In addition to the supra-orbital pins, two others are inserted into the mandible 1 cm above the lower border in the canine regions. These pins need to have a finer thread than those used in the softer bone of the supra-orbital ridge, but are of the same self-tapping design (Moule or Toller pins). It is necessary to drill a more accurately matched hole for mandibular pins, which should have a long enough thread to penetrate the outer cortex and just engage the inner. Upper and lower horizontal rods and two lateral vertical rods are connected to the pins to complete a rectangular 'box frame'. This constitutes a rigid form of craniomandibular fixation, sandwiching the maxilla between the mandible and the anterior cranial base. An upper splint with an anterior connecting bar is not needed in this situation but the main disadvantage of the 'box frame' arises from the need to establish it while the patient is still under an anaesthetic. Emergency release of fixation in the postoperative period is therefore difficult.

CRANIOFACIAL FRACTURES

The management of the individual types of mid-face and upper face fractures has been discussed above. It has been noted throughout that the complex nature of the facial skeleton means that facial injuries often affect more than one bone. Where fractures of the frontal bone or cranium are associated with other fractures of the mid-face the term 'craniofacial fracture' is usually applied. These more severe injuries generally require joint neurosurgical assessment and treatment.

The various components are treated in sequence following the principles already discussed. The intracranial injury and the cranial fractures are treated before treating the facial fractures. This establishes the superior aspect of the outer facial frame and acts as a guide for the mid-facial repair, beginning with the zygomatic complexes. The depressed cranial bone fragments are carefully elevated into position and wired or plated. Involvement of the frontal sinus will require attention as outlined above and any suspicion of dural laceration should be managed by craniotomy and repair. Fractures of the orbital roof may require bone grafting to prevent enophthalmos and orbital pulsation, particularly if they are comminuted. Posteriorly they can involve the optic nerves, which may require intradural microsurgical decompression.

POSTOPERATIVE CARE

Operative treatment of injuries to structures associated with the patient's airway gives rise to special postoperative problems. Those problems are compounded if the jaws have to be immobilized before the patient has fully regained conscious control of the airway. The recent trend towards treatment of facial bone fractures by direct osteosynthesis has made postoperative care simpler and safer. Intermaxillary fixation (IMF) for fractures involving the dentition has become an infrequent requirement. Operative treatment should be so designed to avoid IMF during the period of recovery from anaesthesia even if it is applied electively when the patient is fully conscious.

Postoperative care may be divided into three phases:

1. The immediate postoperative phase when the patient is recovering from the general anaesthetic.
2. The intermediate phase before clinical bony union has become established.
3. The late postoperative phase, which includes removal of fixation, bite rehabilitation, physiotherapy and long-term observation of the dentition in particular.

IMMEDIATE POSTOPERATIVE PHASE

General care

Most maxillofacial units have a special high-dependency or intensive care unit to which patients are transferred from the operating

theatre and where they are kept under skilled nursing supervision until they are fully recovered from the anaesthetic and fit to be transferred back to their ward. In the absence of such facilities an experienced nurse should remain with the patient until recovery is complete.

A minority of facial injuries are associated with general injury of a critical nature. During the postoperative period patients in the latter category will remain in a high-dependency or intensive care unit until they are conscious and systemically stable. This is essentially a period of close observation by specially trained nurses with appropriate medical staff immediately available and regularly visiting. Nursing responsibility encompasses:

- Immediate postoperative resuscitation.
- Control of the airway including tracheostomy care if needed.
- Monitoring the level of consciousness.
- Detection of circulatory failure from observations (pulse, blood pressure, urine output, central venous pressure).

- Detection of respiratory difficulties from observations (respiratory rate, oxygen saturation).
- Monitoring abdominal changes (bowel sounds, urine output, distension, tenderness).

Care of the maxillofacial injury

It is essential that good lighting is provided and that accessory lighting is available in case of a power failure. Patients should be returned from the theatre with a nasopharyngeal airway in position and this should be left in situ until the patient recovers consciousness. Patients should be nursed lying on their sides during recovery to enable any saliva or oozing blood to escape from the mouth. An efficient suction apparatus must be at the patient's bedside, to which a length of polythene tubing is attached. This enables the nurse to pass the tube down the nasopharyngeal airway or the nares to suck out the nasopharynx. The suction tube can also be passed along the buccal sulcus to keep this area free of secretions.

Although IMF can be avoided in the immediate postoperative period there are still many centres throughout the world where this traditional method of treatment is regularly employed. In such cases instruments such as scissors and wire cutters must be available at the patient's bedside so that the fixation can be removed in an emergency. Physical control of the tongue in an unconscious patient is only required if there has been extensive soft-tissue injury to the oropharynx or in a patient whose level of consciousness is expected to remain depressed after recovery. Patients in this category will normally remain on assisted ventilation via either an elective tracheostomy or prolonged endotracheal intubation.

Postoperative vomiting should not occur if it has been possible for the patient to be correctly prepared for operation. If a genuine emergency operation is required, there may be significant amounts of recently swallowed blood as well as food within the stomach. In these circumstances it will be necessary to evacuate the stomach contents before anaesthetizing the patient. Modern anaesthesia has reduced the incidence of postoperative vomiting to negligible proportions. Vomiting in the presence of IMF is unpleasant for the patient but does not represent a danger to the airway if fully-conscious.

Fractures of the mid-face often involve the orbit and it is essential that the eyes are inspected at the earliest opportunity. Vision and visual acuity must be examined and recorded as soon as the patient is conscious, and regular checks need to be made during the first few hours after surgery. Fractures of the zygomatic complex must be protected from displacement during this period, particularly when direct osteosynthesis has not been used. The occasional patient with external pin fixation needs careful nursing while restless during recovery to avoid damage to the apparatus.

Intermediate postoperative care

General supervision

Patients who have sustained a maxillofacial injury and who are in hospital will not normally require high-dependency care after the first 24 hours. They should be carefully examined at both a morning and evening ward round. The occlusion should be checked as early as possible. Direct osteosynthesis carries with it a greater risk of malalignment. Unacceptable reduction needs to be corrected at an early stage, by further surgery if necessary. Intermaxillary fixation must be inspected to ensure the postoperative reduction has been maintained and fixation has not become loose.

Reduced mid-facial fractures should be carefully examined to ensure the contour of the face has been restored. This is particularly important for zygomatic complex fractures. Eye movements must be checked and diplopia or reduced visual acuity noted. Diplopia should be tested a full arm's length in front of the patient and examination of visual acuity must take account of any eye ointment or fluid which might affect light perception.

The alignment of the nasal skeleton must be assessed clinically and any persistent or new cerebrospinal fluid (CSF) leakage noted. Nasal secretions can be troublesome for the patient and a 'bolster' dressing across the external nares is helpful in the early postoperative period.

All these clinical observations must be supported by early postoperative radiographs to confirm that satisfactory reduction and fixation has been achieved.

Adequately reduced and immobilized facial bone fractures are relatively painless and the postoperative oedema rapidly subsides. Any increase in swelling, particularly if accompanied by signs of active infection, requires immediate attention.

Posture

Patients with a fracture of the facial skeleton find it more comfortable if they are in the sitting position with the chin well forward, and providing there is no contraindication to this posture, such as a fractured vertebra, the conscious patient should be nursed in this position. The unconscious ventilated patient does not require postural assistance of this nature but will need repeated mouth toilet and suction to remove accumulated blood and secretions.

Sedation

If the fracture has been adequately reduced and effectively immobilized, the patient will experience very little pain, so that large amounts of postoperative analgesics are seldom indicated and should not be administered routinely.

Opiates are contraindicated in patients with maxillofacial injuries. These drugs depress the respiratory centre and cough reflex and for these reasons alone they are potentially dangerous if given to patients whose jaws are immobilized. The use of any powerful analgesic may mask a deteriorating level of consciousness, and morphine derivatives cause constriction of the pupil, which obscures the pupillary changes indicative of a rise in intracranial pressure. Patients with maxillofacial trauma may have sustained damage elsewhere, apart from associated head injury, and it is important that the physical signs of, for example, intra-abdominal bleeding, are not unnecessarily suppressed by potent analgesics. It should be remembered that restlessness in a recovering patient may be due to airway difficulties or a distended bladder.

Patients who are cerebrally irritated will remain in the intensive care environment with sufficient sedation to allow assisted ventilation through a secure airway and will be intensively monitored by specialist nurses during this period of care.

Prevention of infection

Facial lacerations, with the exception of animal bites and heavily contaminated wounds, do not require prophylactic antibiotics. The same can be said of all closed fractures of the facial skeleton such as the zygomatic complex and edentulous parts of the mandible or maxilla. Fractures of the tooth-bearing areas are liable to infection and prophylactic antibiotics should be given. Unless contraindicated, penicillin is the drug of choice: alone, combined with metronidazole or as co-amoxiclav (amoxicillin and clavulanic acid). If healing is proceeding well, antibiotics can be discontinued 5 days after immobilization of the fracture.

Fractures of the mid- and upper facial skeleton with actual or potential breach of the dura mater have traditionally been given prophylaxis against meningitis.

Oral hygiene

Effective oral hygiene also plays an important part in the prevention of infection of a fracture into the oral cavity. The conscious patient is given hot normal saline mouthwashes following every meal, and patients whose fractures are immobilized by any of the techniques used for intermaxillary fixation can keep the apparatus clean by using a toothbrush in the usual manner.

A 0.2 per cent chlorhexidine gluconate mouth-wash significantly reduces bacterial counts and improves plaque control in patients with intermaxillary fixation or where tooth brushing is difficult.

If the patient is too ill to co-operate in these simple measures, the mouth must be cleaned by the nursing staff after every meal using normal saline solution irrigation supplemented by chlorhexidine.

In spite of the theoretical advantages of elastic loops when intermaxillary fixation is used, there is no doubt that wire loops are more hygienic and for this reason many operators prefer them. The lips should at all times be kept lubricated with petroleum jelly to prevent them becoming dry and sticking together. If the lips are in any way excoriated and sore, as they may be after operative reduction and fixation, 1 per cent hydrocortisone ointment can be applied with benefit.

Immediately following operation the saliva tends to become thick and difficult to control. This condition may persist for the first few days after injury. It is much more difficult for a patient to cope with this if intermaxillary fixation has had to be used. The thickened saliva and congealed blood tend to block the interstices between the teeth and hinder oral respiration. The lips tend to stick together which adds to the problem. It is during this period that good nursing can do much to aid rapid recovery. The lips and mouth should be cleaned with moist saline swabs at regular intervals and the lips regularly lubricated with steroid-containing ointment or petroleum jelly. Sodium bicarbonate solution is useful to clear away viscid mucous secretions.

Feeding

The problem of providing adequate nutrition following a maxillofacial injury depends on whether the subject is conscious and cooperative or unco-operative due to a depressed level of consciousness with or without cerebral irritation.

The conscious co-operative patient

The majority of patients with facial bone fractures are nowadays managed without the need for a prolonged period of intermaxillary fixation. This simplifies their feeding requirements considerably as they are merely required to eat softer foods than normal and have no difficulty in maintaining their normal bodily needs. Even when their jaws are immobilized by intermaxillary wires, they can readily be fed by mouth with a semi-solid or a liquid diet.

An intake of 2000-2500 Calorics is adequate for most patients' nutritional requirements. However, a liquid or semi-solid diet is uninteresting and tedious to consume and for this reason patients should be encouraged to eat little and often. The balance of the diet should be decided in consultation with a dietician, who will generally encourage patients to eat as much of their normal food as can be prepared by an electric food mixer or liquidizer. Milk and milk products are encouraged for regular daily consumption. The diet usually needs to be supplemented with

vitamins, iron preparations and proprietary high-energy protein preparations. Every effort should be made to maintain the patient's interest in the diet by the use of flavouring agents, and the food should be presented in as attractive a manner as possible.

While the jaws are immobilized, feeding is helped by using a cup with a spout to which a suitable length of soft plastic tubing is attached. This enables patients to feed themselves by passing the end of the tubing through a gap in the fixation or round the back of the lower

teeth. Flexible drinking straws are also very helpful to enable a patient to drink from a vessel.

The unconscious or unco-operative patient

Fluid balance and nutrition

A fluid balance chart should be kept for all patients suffering from maxillofacial injuries until such time as the clinician in charge of the case is satisfied that an adequate fluid intake is being voluntarily ingested by the patient. The normal daily intake of fluid is about 3000 ml and the output is made up of 1500 ml of insensible loss by evaporation from the skin, sweating, etc. and 1500 ml of urine.

It should be remembered that all forms of trauma and all surgical operations provoke a complex metabolic disturbance which varies directly with the magnitude and duration of the trauma or operation. This consists essentially of a reduced ability to excrete water and salt with an increased metabolism and excretion of potassium and nitrogen. The impairment of water excretion lasts 24-36 hours and is characterized by low output of urine of high specific gravity. The impairment of excretion of sodium lasts 4-6 days and after 24 hours there is marked lowering of sodium and chlorine in the urine. There is an increased excretion of potassium, which lasts 24-48 hours due to mobilization and excretion of intracellular potassium. The increased nitrogen excretion is due to the breakdown of tissue. These changes are a normal response to trauma and in most cases the disturbances are slight and do not require any action. Most patients with maxillofacial injuries will have been on a normal diet and fluid intake up to the time of injury and are therefore in normal electrolyte balance. Usually such patients can return to an adequate fluid intake by mouth as soon as the fracture is immobilized and such cases present no fluid balance problems. In conscious patients the fluid intake can be left to the desires of the patient, as normal kidneys have enormous flexibility of function and can excrete excess salt or fluid from the body. This flexibility, as already stated, is temporarily lost following trauma and operation. Intravenous fluids override the natural control provided by the patient's thirst and therefore the amount administered has to be accurately assessed by the surgeon. In a patient unable to swallow due to the severity of the injury, considerable dehydration can occur in

24-48 hours, especially in elderly patients. If the patient is capable of taking fluid by mouth, it is unnecessary to employ any other route, but if for some reason the patient cannot swallow, enteral or parenteral fluid therapy must be instituted. Injured patients also need early and adequate nutrition, and fluid requirements have to be supplemented by a sufficient energy intake to promote healing.

Enteral fluid therapy

Enteral fluid therapy is effected by passing fluid into the stomach via a transnasal gastric tube. Considerable advances have been made in recent years in this form of feeding, mainly derived from experience with burn injuries and the management of orofacial cancer. All the patient's nutritional requirements may now be administered via a soft, very thin, flexible nasogastric tube using specially constituted food preparations injected slowly under pressure (Silk, 1980; Brown, 1981) (Fig. 122). If a nasogastric tube is passed in order to feed the patient it is essential to take a chest radiograph to ensure that it is in the stomach before any food is given. Occasionally these tubes are inadvertently passed into the trachea.

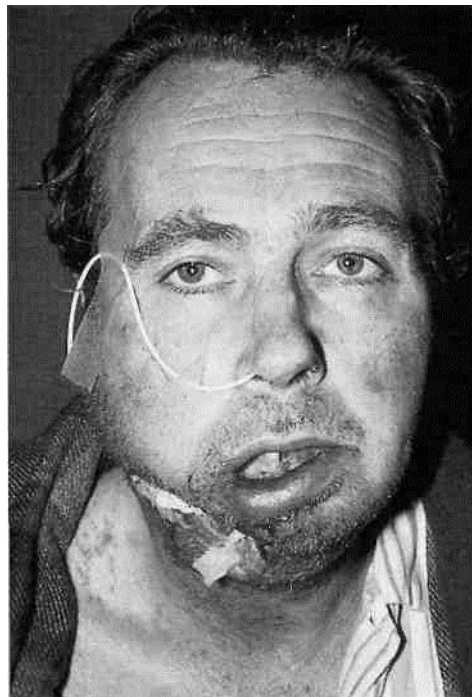

Figure 122. Postoperative photograph of a patient with a severe gunshot wound involving the right mandible. An ultra-thin flexible nasogastric tube has been passed to permit enteral feeding with minimal discomfort for the patient.

Percutaneous endoscopic gastrostomy (PEG)

The development of a simple endoscopic technique for the insertion of a feeding gastrostomy represents a major advance in enteral feeding and fluid balance for those patients who may require prolonged periods of supplemental nutrition. The technique utilizes a flexible fibroptic gastroscope to locate a site for insertion of a thin trochar through the abdominal wall

into the stomach while its wall is pressed tight against the overlying peritoneum. A guideline is in turn passed into the stomach and located by the gastroscope operator who leads it back through the mouth. The gastrostomy tube is then tied to the guideline and passed back down and out through the abdominal wall. The stomach is retained in contact with the peritoneum by a soft flange at the end of the gastrostomy tube. This technique is equally applicable for patients with severe injuries as it is for postoperative patients who require long periods of artificial feeding (Fig. 123).

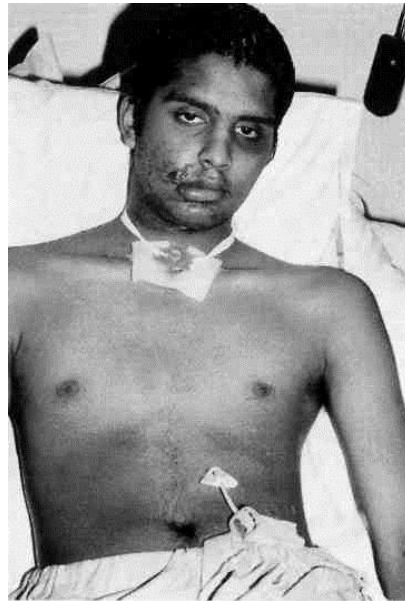

Figure 123. Postoperative photograph of a patient with a direct penetrating injury of the oropharynx, who was fed satisfactorily by means of a PEG until normal function was restored as the wound healed.

Parenteral fluid therapy

Parenteral fluid therapy is administered through an intravenous line. The greatest risk with this form of therapy is overloading the patient with water while the normal kidney flexibility of function is temporarily impaired as a result of the trauma and/or operation. It is exceptional for patients who have sustained maxillofacial injuries to require intravenous fluid in the postoperative period in the absence of some complication such as protracted unconsciousness, although intravenous blood or other fluid may need to be given immediately following the accident if the patient is shocked. As already stated, shock is rare following such fractures and, if present, is usually due to some associated injury. In all instances patients should revert to oral fluid and feeding as soon as possible.

LATE POSTOPERATIVE CARE

Testing of union and removal of fixation

Fractures of the mid- and upper face unite very rapidly and clinical testing for union is both unnecessary and impractical. Fixation is where possible achieved by multiple miniplates of the smaller size and these plates rarely need to be removed. The chief reason for removal arises if the plate is prominent or visible beneath the skin or becomes exposed intraly. It should be remembered that there is a school of thought which believes all plates should be electively removed (Alpert and Seligson, 1996). The arguments for this are outlined in Chapter 6 in relation to research related to biodegradable plates. These arguments are largely theoretical and are not so far justified by clinical experience in maxillofacial injuries. The operative extraction of metal plates can be fairly difficult, particularly if the make of plate and the design of the screws used is not known or has not been recorded. Plate-removing kits can now be purchased which contain a selection of screwdrivers designed to fit all known screw heads.

When external pin fixation has been employed or the maxilla has been stabilized by some form of internal wire suspension, this fixation has to be removed by one or other of the techniques described below in relation to mandibular fractures.

Fractures of the body and ramus of the mandible treated by rigid osteosynthesis will not normally have had intermaxillary fixation applied for other than a short period designed to minimize postoperative discomfort. Although plates produce a strong clinically stable union more rapidly than traditional forms of fixation, some care is needed in the management of the early stages. Patients should be kept on a soft diet for the first 2 weeks and carefully monitored in order that wound infection, should it occur, be recognized at an early stage. In some treatment centres plates are routinely removed after 6 months whereas in others they are left as permanent implants unless they become exposed or infected. There is evidence to suggest that routine removal of internal fixation is unnecessary. Larger plates, such as those designed for compression osteosynthesis, are more likely to become exposed. Similarly the larger interface with vital tissue is more likely, in the longer term, to become infected from blood-borne organisms. All plates and certainly all transosseous wires are probably better regarded as permanent implants unless they cause trouble. Removal is indicated because of infection, exposure to the mouth, close and prominent proximity to the skin or interference with the subsequent design of a prosthesis.

When intermaxillary fixation has been employed, it is left until sufficient time has elapsed for stable clinical union to be expected. It is then released to allow the fracture site to be tested by gentle manipulation. If the fracture is stable in normal function, intermaxillary fixation is discontinued and the fracture examined again 1 week later. Some movement across the fracture is acceptable when intermaxillary wires are removed. The amount of acceptable mobility is a matter of clinical experience which is not difficult to acquire.

All current methods used to apply intermaxillary fixation allow the wires to be removed without disturbing the fixation to the teeth. This gives the clinician the option to immobilize the mandible for a further period with minimal inconvenience to the patient. The exception to this arises when Gunning-type splints are used for edentulous fractures. It is then necessary to remove the whole splint before the fracture can be tested - an additional disadvantage of the technique.

When the fracture is satisfactorily united the fixation apparatus is removed in its entirety. Wire ligatures and eyelets should be unwound a few turns to loosen them and the wire cut in such a way that there are no residual obstructions to smooth withdrawal. Nevertheless the process is uncomfortable for the patient. Local anaesthesia over a wide area is also uncomfortable for the patient and inhalational relative analgesia can be employed with advantage.

Peralveolar and circumferential wires are removed by cutting one end close to the mucosa and pulling on the opposite end of the wire. No anaesthetic is necessary, but it is essential to cut the wire cleanly, for a jagged end of wire causes pain as it is pulled through the tissues. The mouth should be cleaned with antiseptic, such as 1 per cent chlorhexidine gluconate solution, before pulling out the wire to avoid introducing infection deep into the tissues. It is helpful as an additional safeguard against infection to administer a single dose of an appropriate antibiotic, for example 3 g amoxicillin.

Cap splints can be removed with an old pair of upper extraction forceps. One blade is placed on the edge of the splint near the gingival margin and the other blade on the occlusal surface of the splint. The handles of the forceps are approximated to squeeze the two blades together and the underlying cement is cracked. This manoeuvre is carried out all around the splint and when it is loose it is lifted off the teeth, which then have to be cleaned. Extraoral pins are removed using the special insertion tool in reverse. The skin surrounding the pins should be well cleaned with an antiseptic before removing them to avoid introducing infection.

The described procedures for removing these traditional methods of fixation are tedious and uncomfortable for the patient and a further reason why these techniques have become largely obsolete.

Adjustment of occlusion

Little adjustment of the occlusion is required when direct or eyelet wiring has been employed as the cusps are placed in their correct position under direct vision at the time of immobilization of the fracture. When open reduction and internal fixation has been used the

resulting postoperative occlusion must be acceptable without further adjustment by selective grinding.

Some slight adjustment to the occlusion is required, however, when cap splints have been employed, for no matter how accurately they have been constructed there is, of necessity, a layer of splint metal and a layer of cement over the cusp of each tooth incorporated in the splint. Slight derangement of the occlusion can often be overcome by allowing the patient to masticate normally, for usually there is sufficient elasticity in the recently healed fracture to allow the occlusion to correct itself.

More gross abnormalities of the occlusion are treated by selective grinding of the cusps. Special problems arise when only a small number of teeth are present in either jaw, for the patient tends to assume a bite of convenience. Such cases should be fitted with partial upper and lower dentures as soon as possible to stabilize the bite. Patients with fractures of the edentulous mandible can seldom wear their original lower dentures and new ones are required when the fracture is healed.

Mobilization of the temporo-mandibular joint

Patients seldom have any difficulty in moving their temporo-mandibular joints even after a protracted period of immobilization of the mandible, and usually no special treatment is required on removing the fixation beyond encouraging movement. The function of the temporo-mandibular joint may, however, be adversely affected in certain fractures of the condyle, particularly when intracapsular. Post-traumatic disorders of the temporo-mandibular joint are probably much more common than has hitherto been recognized (Norman, 1982) and indeed the overall mobility and closing force of the mandible may be significantly reduced by fractures other than those involving the condyle (Wood, 1980).

Anaesthesia and paraesthesia of peripheral nerves

If the inferior dental nerve is involved in a fracture of the mandible, or the infra-orbital nerve in a fracture of the maxilla, the damage may take the form of a neuropraxia or neurotmesis and the period for recovery of sensation will, of course, depend on the nature and degree of damage to the nerve. A neuropraxia usually recovers in about 6 weeks, but a neurotmesis may take 18 months. Following severe damage to a sensory nerve complete recovery may not occur and the patient will complain of slightly altered sensation in the area of distribution. However, some degree of sensation in the lower lip always seems to remain, as the area of skin supplied by the inferior dental nerve has an accessory sensory supply from the mylo-hyoid nerve. The lingual

nerve is seldom damaged in civilian-type mandibular fractures but if the nerve is severed sensation in the anterior two-thirds of the tongue is seldom reestablished.

Micro neural repair of both the inferior dental nerve and lingual nerve can now be carried out in specialized centres. The results are sufficiently encouraging to justify the procedure in selected cases.

Teeth and supporting tissues

Fixation methods which involve attachments to the teeth need to distribute the load so as to avoid excessive traction on individual segments of the dentition. Otherwise significant damage to the periodontal ligament will occur which may be irreversible. After removal of eyelet wires, arch bars or cap splints, vigorous attention to oral hygiene is essential and the patient should be instructed accordingly. Where teeth have been retained in the line of fracture, localized periodontal breakdown may need specific periodontal treatment to obviate further deterioration. Fortunately the periodontal ligament undergoes rapid repair after trauma and is reconstituted within a period of 2 weeks in the majority of cases (Andrcason and Andreason, 1990).

Teeth, whether directly or indirectly involved in the fracture, may have been devitalized. Indeed studies have shown that up to 50 per cent of involved teeth undergo pulp necrosis. In the lower jaw such teeth are often in a denervated section of the mandible and standard vitality tests are unreliable. Careful postoperative monitoring of the dentition is most important and unfortunately often neglected.

When teeth have been lost, replacement by fixed or removable prostheses should be part of the overall treatment plan. In many countries restorative dentistry is a Cinderella specialty in maxillofacial treatment centres. In view of the frequency of mandibular and other facial fractures and the considerable damage to the dentition which accrues, it is surprising that those responsible for healthcare provision do not more widely recognize that restoration and rehabilitation of the dentition is an integral part of the management of a maxillofacial injury.

COMPLICATIONS

Serious complications arising as a result of fractures of the facial skeleton are rare providing the fracture has been competently treated. Minor complications are, however, more common than is generally realized. Complications may be considered under three main headings:

1. Delayed treatment.
2. Complications arising during primary treatment.
3. Late complications.

DELAYED TREATMENT

Dento-alveolar fractures

Traumatized teeth may have been subluxed or otherwise devitalized. The crown, root or both may be fractured, and with the passage of time this frequently leads to the development of apical infection.

Untreated alveolar fractures either unite in an incorrect position or become infected, often with sequestration of detached fragments of bone.

Tooth fragments or foreign bodies embedded in the lip usually heal over and remain as hard lumps which may cause the patient some irritation. Although they are frequently well demonstrated on radiographs, they are not as easy to remove as they may appear to the inexperienced operator. Large or infected fragments need to be removed and are, fortunately in these circumstances, much easier to find through an intra-oral incision.

Mandibular fractures

Whenever bone-to-bone contact is maintained at a fracture site, union is likely to occur unless prevented by intercurrent infection. When treatment of such a fracture has been delayed for 2 or 3 weeks, it is relatively easy to mobilize the bone at the fracture site and apply direct fixation. Teeth in the fracture line should at this stage be removed, even in the absence of obvious infection. An infected fracture site will usually heal more readily after late manipulation if a drain is inserted for a few days. Clinically united fractures seen a month or more after injury should be treated as an established malunion (see below).

Zygomatic complex fractures

If some 2 weeks are allowed to elapse before reducing a fractured zygomatic bone, the reduced fracture will probably be unstable because the fractured ends will no longer interdigitate efficiently. This is due to osteoclastic activity rounding off the bony spicules, and some form of direct fixation will therefore be required. After about a month, it will be found almost

impossible to elevate a fractured zygomatic bone in the conventional manner. However, the resistance to elevation is largely the result of early scar tissue formation. Surgical exposure at each fracture site and extensive sub-periosteal dissection will allow adequate mobilization and reduction even up to 3 months after injury. It is well worth making the attempt at this stage, because the zygomatic complex will still retain its basic anatomical form. It is much easier, in these circumstances, to effect a satisfactory reduction than it is after full bony malunion with associated remodelling has taken place.

Nasal complex fractures

To obtain a satisfactory functional and aesthetically pleasing result it is essential that nasal fractures are treated soon after the injury. In contrast to the zygomatic complex, there is little advantage in attempting to treat a neglected nasal complex fracture after the first 3 weeks following injury. A better result will usually be obtained by formal rhinoplasty at a later date. The exception to this is traumatic telecanthus. Whereas a late septorhinoplasty can be successful in restoring the nasal profile and reestablishing the nasal airway, it is less effective for correcting established telecanthus. The earlier a canthopexy can be performed the better will be the eventual result.

Le Fort I, II and III type fractures

When the treatment has not been unduly delayed, it is usually possible to mobilize the fracture, but this may involve fairly extensive periosteal stripping from both intra-oral and extra-oral approaches. It is usually easier to reduce the tooth-bearing portion of the fracture than the naso-ethmoidal region. In some late Le Fort I and II fractures, strong and sustained traction by intermaxillary elastics or even extra-oral traction has been recommended. Newer techniques for callus distraction, using intra-oral or extra-oral appliances, may have a place in treatment but require further evaluation. If the patient is fit enough for a general anaesthetic, operative reduction is always to be preferred and is invariably successful within the first 3 weeks after injury.

If union of the fragments has occurred, a formal osteotomy can usually be designed at the Le Fort I or II level which will correct the occlusion. Such osteotomies are always more difficult in post-traumatic deformity than they are for the treatment of jaw disproportion. Operative bleeding can often be troublesome, and considerable experience is necessary before embarking on such corrective procedures.

In cases where lack of treatment has resulted in a minor degree of gagging of the bite in the molar area, grinding of the teeth or selective extraction and alveolectomy may enable an acceptable occlusion to be restored.

The treatment of severe facial fractures which have been allowed to unite in malposition presents a very difficult problem in reconstructive surgery and every effort should be made to effect reduction of such fractures before full bony union occurs.

COMPLICATIONS ARISING DURING PRIMARY TREATMENT

General

Airway

Fixation of a severe injury involving all of the bones of the face imposes further embarrassment to the airway and close postoperative monitoring is important. If postoperative airway difficulties are anticipated, an elective tracheostomy should be considered before the patient is allowed to recover from the anaesthetic.

Cerebral

All patients with fractures of the central mid-face have sustained some degree of transmitted violence to the brain. Standard head injury charts are used in all hospitals dealing with these injuries as a means of early detection of rising intracranial pressure. When cerebrospinal rhinorrhoea has occurred, there is an added risk of infection, which increases the longer the flow of cerebrospinal fluid (CSF) persists. Leopard (1971) observed the average duration of CSF leaks after high mid-facial fractures to be 4 to 5 days, and most leaks stopped spontaneously. If a CSF leak persists for more than 10 days after reduction and immobilization, elective neurosurgical repair *should be* undertaken.

Displaced teeth and foreign bodies

Teeth or portions of dentures are occasionally inhaled and, when missing, must be accounted for. If this is not possible the chest must be radiographed and if a foreign body is present it should be recovered during bronchoscopy.

Fragments of teeth or glass are not infrequently buried in the soft tissues of the lip. They may be difficult to locate in swollen tissues but may become infected if left. If an abscess does occur, the site of pus formation locates the foreign body, which is then usually removed easily when the abscess is opened and drained injury. Gingivitis is usually not a serious problem and responds to local measures. A more serious periodontal problem can result from applying too much interdental force to individual teeth from eyelet wires or arch bars. The lower incisors are most vulnerable and may be partially extruded or even lost. The complication can be avoided by

spreading the load more widely and evenly by additional eyelets or arch bar ligatures, and by avoiding the application of wires to suspect teeth. This potential complication is, of course, avoided by direct osteosynthesis utilizing mini-plates.

Drug reactions

Allergic reactions occur from time to time, usually to antibiotics. These are fortunately in the main fairly mild but the clinician must recognize the complication at an early stage, discontinue all drugs which might be incriminated and prescribe an antihistamine such as oral chlorpheniramine maleate (Piriton) 4 mg t.d.s.

Dento-alveolar

Pulpitis

Damaged teeth may develop pulpitis or apical infection in the weeks following fracture treatment. Such teeth are easy to treat in the absence of intermaxillary fixation (IMF), and relatively easy to treat if arch bars or eyelet wires have been employed. If a tooth becomes painful under a cap splint it is occasionally necessary to remove the root portion via a buccal trans-alveolar surgical approach. The tooth is sectioned at the cervical margin and the crown left within the cap splint.

Gingival and periodontal complications

Some degree of local gingivitis is inevitable when the fixation employed involves interdental wires or cap splints. The gingival reaction used to be very severe when acrylic resin was used to attach cap splints to the teeth. This should be borne in mind if acrylic resin is selected for the fixation of vacuum-formed plastic splints as a method of immobilizing a dento-alveolar

Mandible

Mandibular fractures range from the simple to some of the most complex of the facial skeleton. There is a strong correlation between fracture severity and complication rate. The literature suggests that the incidence of complications has not been reduced by the trend towards direct osteosynthesis. The increased use of bone plates, particularly in the tooth-bearing portion of the mandible, has, however, altered the pattern of complications during primary treatment.

Misapplied fixation

Compression plates demand screws of sufficient length to impinge on the inner cortex. Care is needed to avoid the inferior dental canal and to avoid damage to the roots of teeth. The risk of damage to structures within the body of the mandible is less when the screw engages only the outer cortex, as is the case with non-compression miniplates.

Rigid or semi-rigid osteosynthesis can distort the anatomical alignment of the mandible leading to significant alteration of the occlusion. Should this occur a decision must be made as to whether the malalignment can be corrected by later occlusal adjustment or whether a second corrective operation should be performed (Fig. 124).

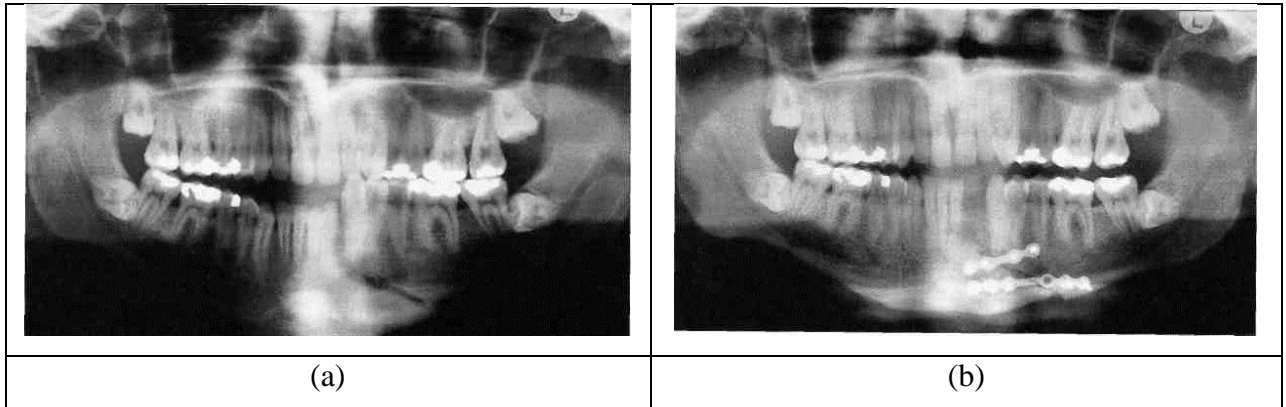


Figure 124. (a) Panoramic tomogram of the mandible. There are displaced fractures of the right condylar neck and left parasymphysis. (b) Immediate postoperative view showing incorrectly applied small non-compression miniplates. There is obvious malalignment of the fracture of the parasymphysis and persistent malocclusion.

Osteosynthesis by transosseous wires is technically easier and damage to internal structures should be avoidable. Nevertheless, ill-judged direction of drill holes can cause problems. Circumferential wires, particularly those used to retain Gunning-type splints, must be carefully located. If the circumferential wire is close to a fracture line it may inadvertently be drawn up into the fracture giving rise to displacement of the bone fragments, damage to the inferior dental bundle and inadequate retention of the splint.

The correct insertion of pins for external fixation is even more hazardous in unskilled hands. The pins have to be inserted without the advantage of direct exposure of the bone. They may impinge on nerves, blood vessels or teeth. They may split the bone fragment if inserted too near the lower border, and they may fail to penetrate sufficient bone substance to remain secure during the required period of fixation.

Infection

Infection of the fracture site resulting in necrosis or osteomyelitis of the mandible is rare. However, wound dehiscence and localized infection still happens relatively frequently, particularly in the presence of poor oral hygiene and lack of patient compliance. This is significantly

more likely in fractures at the angle of the mandible with involved teeth. When teeth are retained in the fracture and extra-oral surgical access for complicated fractures. Joos *et al.* (1999) have applied a man-dibular trauma score to assess the complexity of an injury. Their results confirm that more complications occur in the more severe injuries. They also suggest that severe fractures have fewer complications when treated with a rigid plate system whereas less severe fractures showed better results when treated with less rigid systems.

A few important facts emerge from these various studies:

1. Infection is almost invariably associated with a tooth in the line of fracture.
2. The incidence of infection is significantly higher at the angle of the mandible in the presence of involved third molars.
3. The incidence of infection is not affected by prophylactic removal of involved teeth, but in practice, prophylactic removal is carried out for the more suspect teeth. There have been no randomized prospective studies.

It is unfortunately apparent that evidence concerning the incidence of infection of mandibular fracture sites is inconclusive and further evaluation is needed, particularly in relation to retention of third molars, elective removal of plates, and the influence or otherwise of an intra-oral surgical approach.

Nerve damage

Anaesthesia of the lower lip as a result of neuro-praxia or neurotmesis of the inferior dental nerve is the most common complication of fracture of the body of the mandible. The recovery of sensation in the lower lip depends on the nature of the original damage to the nerve. While anaesthesia is present patients need to be warned of the danger of burning the lower lip. Facial nerve damage may complicate some fractures of the ramus and condyle, either as a result of a penetrating injury severing branches of the nerve, or blunt trauma causing a neuro-praxia. In the latter event recovery of the resultant nerve weakness usually takes place fairly rapidly. If the facial nerve is severed, microsurgical techniques are often successful in restoring function, but it is most important to perform the repair at the same time as the facial laceration is explored and sutured. It is much more difficult to restore continuity and function as a later secondary procedure.

Mid-facial

Nasal haemorrhage

Occasional troublesome post-reduction bleeding from the nose occurs but this is uncommon and usually managed by simple anterior nasal packing.

Ophthalmic

The rare complication of retro bulbar haemorrhage after reduction of a fractured zygomatic complex has been previously described. This complication is extremely important because it can lead to permanent loss of eyesight. Rowe (1985) has argued that a retrobulbar haemorrhage may in some circumstances lead to compression and spasm of the posterior ciliary vessels which supply blood to the head of the optic nerve (the main blood supply to the rest of the optic nerve and retina being via the central artery and vein). If this occurs it results in immediate loss of vision, which becomes irreversible within a 20-minute period. Retrobulbar haemorrhage is therefore an acute emergency, which can be treated by relatively simple decompression via a lateral or medial approach. Liu (1993) describes a technique whereby the tip of a small mosquito forceps is inserted into the orbit through an incision in the inferior medial fornix. This is passed back along the medial wall for 2 cm and then pushed down into the maxillary antrum where it is opened to enlarge the bony hole.

Abrasion of the cornea during surgery is inexcusable but can result from inadequate protection of a cornea which has become unduly exposed as a result of periorbital oedema. Protective 'shells' should routinely be inserted at the beginning of an operation. It cannot be too strongly emphasized that postoperative monitoring of the eyes must be carried out in all mid-facial fractures, especially if an antral pack has been employed.

Inaccurate reduction

If the mid-facial fracture has been insufficiently mobilized, it may end up fixed in the wrong position. It is important to ensure that the mid-line is correct, particularly when mandibular fractures coexist. A more common error occurs when intermaxillary fixation is established during anaesthesia with distraction of the mandibular condyles. If the functioning occlusion is not checked during the immediate postoperative period, the fractures may unite with the mandible distracted forwards. When fixation is eventually released, an irreducible malocclusion will exist. When the reduced mid-face fractures have been immobilized by miniplates, any occlusal disharmony is immediately evident post-operatively if, as is usual, intermaxillary fixation has not been applied. The malocclusion may in part be due to oedema and consequent shortening of the muscles of mastication. It is therefore advisable to apply intermaxillary fixation and to wait a few days before making the decision to reoperate, as in this period the occlusion may come into line.

Fractures of the zygomatic complex treated by simple closed elevation are inherently unstable. It is routine to inform the nursing staff of the risk of displacement of the reduced

fragment should any inadvertent pressure be applied, and to mark the site of the fracture. Large blue fracture symbols painted on the skin are to be deprecated, particularly when placed over the damaged bone itself. A patient has even been known to displace an underlying fracture in attempting to rub clean such a mark.

Insecure fixation

Traditional forms of indirect fixation may be misapplied during operative treatment. Internal suspension wires may be found on postoperative radiographs in unexpected disarray. It is not unknown for experienced operators, for instance, to pass a circumzygomatic wire entirely within the soft tissues and not around the zygomatic arch as intended.

Incorrectly applied halo-frames may loosen and badly positioned vertical rods may interfere with the line of vision and further discomfort the patient. Neat, accurate alignment of all external fixation apparatus is important. The biological compatibility of modern materials is such that galvanic action at the sites of bone pin penetration is virtually a thing of the past. However, early infection of plates and bone pins can occur, albeit rarely, and plates and wires left within the tissues remain a potential source of late local infection.

Nerve damage

Sensory loss over the skin of the mid-face is relatively common after facial bone fractures. This is predominantly due to neuropraxia of the infra-orbital nerve and occasionally the zygomatico-temporal and zygomatico-frontal nerves. Surgical approaches to the mid-facial skeleton need to be designed to avoid damage to the facial nerve, particularly the frontal branches. Operative treatment can result in damage to both the sensory and motor supply to the forehead after a coronal approach. Upper eyelid incisions and exploration of the orbital roof may result in persistent ptosis, which is extremely difficult to treat.

LATE COMPLICATIONS

Complications from head injuries

Most patients with facial bone fractures associated with a period of loss of consciousness suffer to a greater or lesser extent from the post-concussional syndrome, which consists of headache, dizziness, insomnia, diplopia, intolerance to noise, changes in disposition, intellectual impairment and intolerance to alcohol. Usually these distressing symptoms eventually resolve, but may become aggravated and protracted if litigation for compensation is impending.

An aerocele or a cerebral abscess may develop within a few weeks of the accident. Meningitis may occur as an early or a very late complication, and occasionally epilepsy develops.

Complications arising from the fracture

Dento-alveolar fractures Devitalization of teeth

Useful teeth in the line of a fracture should be retained but there is a significant loss of vitality particularly with mandibular fractures. Kamboozia and Punnia-Moorthy (1993) have produced convincing evidence that the incidence of loss of vitality of teeth in the line of fracture is higher after miniplate fixation (68%) than after interdental wiring (41%). In either case the devitalization rate is higher than most surgeons seem to appreciate.

Loss or damage to teeth

Teeth are frequently lost or individually fractured after facial trauma. It is interesting that teeth are usually more highly valued by patients than they often appear to be by surgeons, particularly those without dental training. Adjunctive restorative dentistry is an essential component of the management of patients who sustain facial trauma.

Mid-facial fractures

Delayed or non-union

Delayed or non-union of fractures of the mid-facial skeleton is extremely rare but is not unknown. If a patient's central mid-facial fracture is treated by intermaxillary fixation alone (as has been advocated for simple Le Fort I fractures) constant movement can delay union and in rare instances prevent it completely. Nonunion may only be detectable when the patient applies the full force of the bite. The constant pumping action will predispose to chronic infection of the maxillary antrum. Treatment is best effected by washing out the sinuses and applying small miniplates across the fracture line with or without a bone graft.

Malunion

If the fracture has been inadequately reduced, there may be bony deformity of the face. This may be entirely cosmetic resulting from change in the facial contour, or there may, in addition, be functional problems. The cosmetic and functional deformity may well be more severe if there is associated soft-tissue scarring, malalignment or loss.

Zygomatic and orbital fractures

A depressed malunion of the zygomatic complex may leave the patient with a variable degree of cosmetic deformity. It may, in addition, result in disturbance of the movement or position of the eye causing diplopia. A depressed, healed fracture of the body or arch of the zygoma can interfere with the coronoid process of the mandible and restrict opening.

If such a depressed zygomatic bone is causing diplopia or limitation of mandibular movements, a formal planned osteotomy will be necessary. Inevitably because of remodelling of the contracted orbital floor such an osteotomy will result in a considerable orbital floor bony defect. This will need to be filled with a bone or preferably cartilage graft. If the depression is merely causing a cosmetic deformity, an onlaid implant of suitable alloplastic material may suffice, but will never produce a result as satisfactory as an osteotomy. Occasionally if interference with mandibular movement is the main symptom, and the patient is not concerned about flattening of the cheek, a coronoidectomy on the affected side may be preferable to the more extensive surgery required to re-fracture and re-position the zygomatic bone.

Frequently in severe deformities resulting from malunion of these fractures there will be alteration of the orbital volume, often with tethering and shortening of the ocular muscles. Expansion of orbital volume produces enophthalmos, which is sometimes accompanied by diplopia. Diplopia or enophthalmos due to alteration of the orbital volume and scarring is difficult to treat. Bone, cartilage or alloplastic grafts placed within the orbit combined with ocular muscle surgery may be necessary to correct the defect. Computer-generated three-dimensional imaging and computer-generated models of the skeletal deformity can be of great assistance in reconstruction.

Le Fort fractures

Inadequately reduced fractures of Le Fort I, II and III types may leave the patient with an over-long face or flattening of the entire profile, the so-called 'dish-face' deformity. There will be gagging of the molar teeth with an anterior open bite. The upper arch may, in addition, be rotated to one side or the other and there may be post-traumatic defects in the palate.

Many of the inadequately reduced fractures are those of the extended variety in which the frontal bone and orbital roof are deformed. The initial severity of the head injury may have precluded effective reduction of the fracture. Apart from contour deficiencies of the forehead, the patient may present with considerable deformity of one or both orbits. Failure to correct nasoethmoidal complex fractures can result in a misshapen nose, telecanthus and obstruction of one or other airway due to deviation of the nasal septum.

Extensive damage to the cribriform plate or posterior wall of the frontal sinus can be the cause of cerebrospinal rhinorrhoea of delayed onset.

The extent of the post-traumatic deformity may therefore comprise:

1. Retrusion of upper dentition.
2. Anterior or lateral open bite.
3. Intraoral fistulae into nose or maxillary sinus.
4. Expansion or contraction of the orbital volume.
5. Orbital dystopia (alteration of the position of the orbit as a whole).
6. Tethering of ocular muscles.
7. Depression of the nasal bridge.
8. Deviation of the nasal septum.
9. Telecanthus.
10. Obstruction of drainage of the paranasal sinuses, particularly maxillary and frontal.
11. Contour deficiency of the frontal bone with distortion of the orbital roof.
12. Persistent cerebrospinal rhinorrhoea.
13. Varying degrees of soft-tissue scarring and malalignment.

It can be readily seen that the reconstruction of the more severe post-traumatic facial deformities can present a major surgical problem which often requires a craniofacial approach. The principles of reconstruction have been outlined by Gruss (1995), and can be summarized as follows:

1. Extensive facial or craniofacial exposure.
2. Bony depressions corrected by onlay grafts, rigidly fixed preferably with lag screws.
3. Segmental osteotomies and bone repositioning:
 - (a) anatomically normal bone corrected by osteotomy and repositioning;
 - (b) anatomically abnormal bone replaced by bone grafts.
4. Rigid fixation to prevent late skeletal relapse.
5. Soft-tissue distortion is the limiting factor in restoring the pre-injury appearance.

Ophthalmic complications

Residual ophthalmic problems arise from three main causes. There may, as mentioned above, be deformity of the bony orbit with or without tethering of the orbital adnexae. This produces mechanical disturbance in the movement of the eye and in many instances double vision. Late enophthalmos is a not infrequent sequel of an uncorrected expansion of the orbital volume. The function of the eye may be affected as a result of neurological damage. The oculomotor nerve is vulnerable during its long intracranial course and the abducent nerve may also be injured. If these nerves fail to recover completely the patient will suffer from strabismus, ptosis and diplopia. More rarely these nerves are damaged within the superior orbital fissure, when a superior orbital fissure syndrome is produced, consisting of ophthalmoplegia, ptosis,

proptosis and a fixed dilated pupil. There is, in addition, anaesthesia within the distribution of the ophthalmic division of the fifth cranial nerve. If the optic nerve is also damaged, partial or complete blindness results - the orbital apex syndrome.

The third cause of residual eye problems stems from damage to the globe itself and its soft-tissue adnexae and may vary from disturbances in vision to diplopia caused by direct muscle damage. Larkin *et al.* (1994) have drawn attention to the fact that a small number of patients who have had direct trauma to the globe are left with impaired perception of moving objects - the Pulfrich phenomenon. This results from delayed conduction along one optic nerve and can interfere with driving ability. Because of its importance, the authors recommend that the phenomenon is looked for in all patients who have sustained mid-facial injuries.

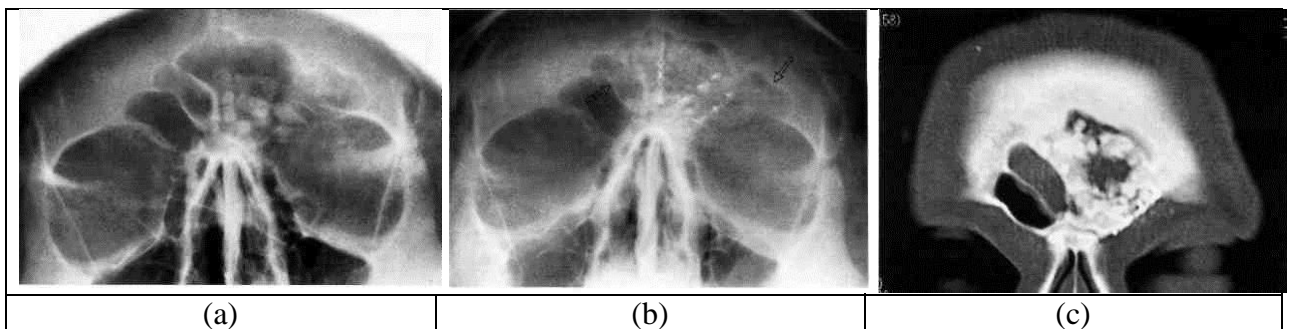


Figure 125. (a) Radiograph of a patient who had sustained a frontonasal injury. There is extensive damage to the anterior wall of the frontal sinus and contamination with fragments of glass, (b) Immediate postoperative radiograph of the same patient. Autogenous cancellous bone chips have been packed into the damaged left frontal sinus. However, the sinus has been incompletely obliterated on the left and there is an unfilled loculus on the right (both arrowed). The microplates used to secure the reconstructed anterior wall of the sinus are superimposed on the image of the bone graft, (c) Coronal CT scan taken some months later when the patient presented with symptoms consistent with infection of the frontal sinus. Particles of dead bone around a loculus which contained pus are clearly demonstrated.

Paranasal sinuses

Severe mid-facial fractures are frequently associated with comminution of the walls of the paranasal sinuses, particularly the frontal and maxillary. This may lead to obstruction of the ostium and disturbance of drainage. One or other of the frontal sinuses may be converted to an infected mucocele. In these circumstances it is almost impossible to reconstitute the ostium after surgical drainage. The sinus cavity must be obliterated by removal of the lining and particulate bone grafting. The pattern of drainage and loculation of the frontal sinuses can be confusing. One sinus may drain into the contralateral nasal cavity and total obliteration is needed to prevent further infection (Fig. 125). The maxillary sinus may become chronically infected as a result of obstruction of drainage, loss of specialized mucosa, or because of a residual oro-antral fistula. The sinus cannot be obliterated surgically so treatment has to be designed to eliminate infection

and to reestablish drainage. Reconstruction of the natural ostium by endoscopic nasal surgery is now preferred to artificial nasal antrostomy.

Lacrimal system

Partial or complete obstruction of the nasolacrimal duct is a relatively common late complication of Le Fort II and nasal complex fractures. The patient complains of epiphora and may develop an infected mucocele, a condition termed 'dacryocystitis'. If the natural pathway for tears cannot be re-established by dilation of the duct a dacryocystorhinostomy operation is done as a planned procedure by an ophthalmic surgeon.

Other neurological damage

Apart from the nerves supplying the eye, there may be permanent damage to others. Anosmia is a distressing and not infrequent sequel to those fractures which involve the cribriform plate of the ethmoid. Anaesthesia or paraesthesia within the distribution of the maxillary division of the fifth cranial nerve is less serious. Sensation in the cheek, upper lip and maxillary teeth may often be diminished or lost.

Late problems with transosseous wires and plates

Plates or transosseous wires which have been used for reconstruction of the mid-face are generally nearer the surface than in the mandible and consequently more prominent. They may simply be uncomfortable for the patient or visible as projections. Those beneath the oral mucosa are more likely to become exposed and infected than those beneath the skin. In any of these circumstances the plates have to be removed. This is not always as easy as it may sound because titanium plates in particular have often become partially osseointegrated, requiring some patience and persistence to remove. Plates on the frontal bone are inaccessible other than by reopening a large coronal flap. The alternative is to make a direct overlying skin incision, which rather negates the original cosmetically designed surgical approach.

Mandibular fractures

Malunion

Post-reduction radiographs must always be taken and should these reveal an unacceptable malposition of the fragments, this should be corrected as soon as possible, by a further operation if necessary.

After completion of treatment there should be no change in the occlusion. Minor malunion used to be fairly common when cap splints were employed, either from failure to seat

the splints evenly when originally cemented into place, or from faulty laboratory technique producing variation in the thickness of the metal casting. The use of intermaxillary fixation may mask an inadequately reduced fracture because the mandibular condyles can be inadvertently distracted. This is more likely if the occlusion is not checked at an early stage after surgery. Eventually when the intermaxillary fixation is released a degree of malunion remains. However, if fixation is removed at the stage of clinical union when the callus is still soft, minor discrepancies in the occlusion will often correct themselves as the patient starts to use the jaws again. Selective occlusal grinding may help the process of readjustment. Inaccurate reduction of a fractured mandible is always evident at an early stage when direct osteosynthesis has been used without intermaxillary fixation.

Occasionally cases may be seen where inadequate reduction has resulted in gross derangement of the occlusion and deformity of the face. This situation may also arise when a patient has had no treatment at all for the fractured mandible, either because he did not seek treatment at the time of injury, or because other more serious injuries prevented treatment or diagnosis. The mandible has an impressive capacity to heal itself and providing some bone contact is present, malunion is more likely than non-union. Gross occlusal derangement and facial deformity requires operative reconstruction, usually in the form of re-fracture. Occasionally a formal planned osteotomy or osteectomy may be required. When the jaw is re-fractured to correct malunion it is wise to pack autogenous cancellous bone chips, obtained from the iliac crest, around the newly approximated bone ends. If this is not done the diminished blood supply at the site of the original injury may predispose to further delayed union. Occasionally alloplastic onlays may be indicated particularly when there is asymmetry.

Malunion of edentulous fractures is the usual outcome of conservative treatment following closed reduction. Providing the malunion can be compensated in the subsequent dentures, it is acceptable. Operative intervention and mini-plate osteosynthesis in an elderly patient with a thin mandible carries both a risk to the patient and the possibility of non-union.

Delayed and non-union

Delayed union

If the time taken for a mandibular fracture to unite is unduly protracted it is referred to as 'delayed union'. The term is difficult to define precisely as fractures heal at different rates, but if union is delayed beyond the expected time for that particular fracture (taking the site and the patient's age into consideration) it must be assumed that the healing process has been disturbed. This may be the result of local factors such as infection, or general factors such as osteoporosis or nutritional deficiency. Providing the fracture site becomes stable so that jaw function can be resumed, no active intervention is necessary in the short term. A fracture in which fibrous union

has occurred will frequently progress to slow bony consolidation during the ensuing 12 months after injury. Fibrous union may be an acceptable result in an elderly edentulous patient. However, in a younger dentate individual, prosthetic replacement of missing teeth is impractical if any mobility at a fracture site remains, and at some point non-union has to be accepted and treated.

Non-union

Non-union means that the fracture is not only not united but will not unite on its own. Radiographs show rounding off and sclerosis of the bone ends, a condition referred to as eburnation (Fig. 126). Non-union includes the condition of fibrous union referred to previously when there is a degree of stability.

Non-union may occur in a number of circumstances, some of which are preventable. The theoretically preventable causes of non-union are as follows:

1. Infection of the fracture site.
2. Inadequate immobilization.
3. Unsatisfactory apposition of bone ends with interposition of soft tissue.

The remaining causes of non-union may be impossible or very difficult to overcome and are as follows:

1. The ultra-thin edentulous mandible in an elderly debilitated patient.
2. Loss of bone and soft tissue as a result of severe trauma, e.g. missile injury.
3. Inadequate blood supply to fracture site, e.g. after radiotherapy.
4. The presence of bone pathology, e.g. a malignant neoplasm.
5. General disease, e.g. osteoporosis, severe nutritional deficiency, disorders of calcium metabolism.

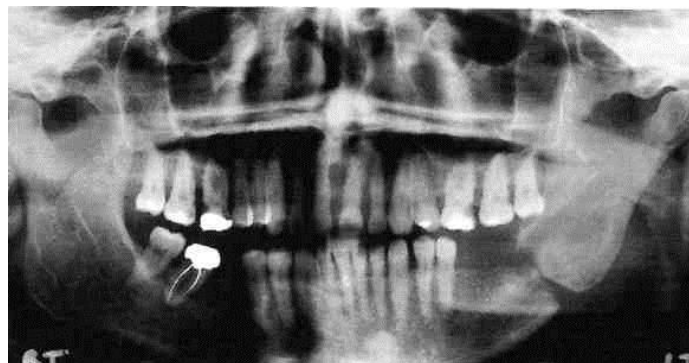


Figure 126. An unusual radiograph showing non-union of a fracture of the mandibular angle. Non-union resulted from persistent infection of the fracture site and repeated extrusion of sequestra.

Treatment

A moderate delay in union is managed by prolonging the period of immobilization. Once non-union is accepted, and if the bone ends are still approximated, the fracture line should be explored surgically and any obvious impediment to healing, such as a sequestrum or devitalized tooth, removed. The bone ends are then freshened, the wound closed and the jaw is immobilized once again. If there is any doubt concerning the health or apposition of the bone ends, autogenous cancellous bone chips should be obtained from the iliac crest and packed around the fracture site.

If radiographs of a non-union show marked eburnation of the bone ends or excessive bone loss, a formal bone graft of cortico-cancellous bone will be required. It is important to eliminate active infection from the site before employing a bone graft although if the obvious cause of the infection has been eliminated, a bone graft inserted at the same operation will usually be successful. In these circumstances intravenous metronidazole or co-amoxiclav are useful prophylactic antibiotics.

Derangement of the temporo-mandibular joint

Conservative treatment of the fractured mandibular condyle frequently leaves a state of malunion at the fracture site. Remodelling at the fracture site is less efficient in the adult than in the child and post-traumatic temporomandibular joint problems are not uncommon. The main post-traumatic complications involving the temporo-mandibular joint have been described in Chapter 6 and can be summarized as follows:

- Malocclusion.
- Limitation of range of movement.
- Displacement of the meniscus (reducible or irreducible).
- Chronic pain associated with dysfunctional movement.

Complications 183

- Chronic pain associated with osteoarthritis.
- Fibrous or bony ankylosis.
- Disturbance of further growth in children.

Late problems with transosseous wires and plates

Transosseous wires at the upper border may cause symptoms, particularly if covered by a denture. The wire is usually easily removed under local anaesthesia. Bone plates should not be placed near the oral mucosa as they will tend to become exposed.

Lower border wires sometimes give rise to pain and discomfort if the overlying skin is thin. In these circumstances they should be removed.

Bone plates, particularly the larger compression plates, may become infected some time after the fracture has healed. Surgical removal of the plate will lead to rapid resolution of the problem.

Sequestration of bone

Comminuted fractures of the mandible, particularly those caused by missile injuries, may be complicated by the formation of bone sequestra. A sequestrum may be a cause of delayed union but often the fracture consolidates satisfactorily and the sequestrum remains as an actual or potential source of infection. Sequestra may then be extruded spontaneously into the mouth with quite minimal symptoms, but sometimes a localized abscess forms and surgical removal of the dead bone becomes necessary. It is important to be sure that a sequestrum has separated completely from the healthy adjacent bone before surgical removal is contemplated. Very often an infection can be treated with antibiotics and the dead bone allowed to extrude spontaneously without surgical intervention.

Scar tissue formation

Scars

Many facial bone fractures have associated soft-tissue injuries and providing these wounds are carefully cleaned and sutured scarring will be minimal. However, it has to be accepted that some individuals have a propensity to produce unsightly scars which are occasionally hyper-trophic. Unsightly scars also result from contamination of the original wound with dirt, especially tar products. At first all scars tend to be red and feel hard to the touch but during the first year they soften and fade. Massage of the scar by the patient and the application of lanolin are very helpful in this respect.

Hypertrophic scarring or keloid produces an ugly deformity and surgical revision may be disappointing. Repeated infiltration of the scar with triamcinolone 10 mg/ml can produce dramatic improvement in some cases. Whenever surgical revision is considered, it should not be contemplated until scar maturation is complete, which takes at least 1 year. It must be emphasized that adequate wound toilet and careful suturing of the original laceration can largely prevent unsightly scars.

Limitation of opening

Prolonged immobilization of the mandible in intermaxillary fixation will result in weakening of the muscles of mastication. If there has been substantial haemorrhage within muscles a considerable amount of organizing haematoma and early scar tissue may be present

when fixation is released. All these factors combine to cause limitation of opening and a restricted mandibular excursion. In the majority of cases full movement is restored in time but as with other fractures, physiotherapy may accelerate the recovery period. Simple jaw exercises and mechanical exercisers may be employed with advantage. Occasionally manipulation of the mandible under anaesthesia may assist the breakdown of scar tissue within muscles.

Fibrodysplasia ossificans involving the main muscles of mastication is a very rare complication of facial bone fractures. It is believed that a haematoma occurs in the muscle, which organizes and eventually becomes ossified. That view is supported by the finding of trabecular bone within the muscle mass at subsequent operation. Treatment consists of excision of the ectopic bone, but the condition will often recur. The complication is extremely rare considering the frequency of mandibular injury, and systemic factors may play a part in the disorder.

TERMINAL STATES

CLINICAL, COURSE AND TREATMENT

SYNCOPE(a fainting fit, a swoon) is a sudden and short-term loss of consciousness, caused by brain hypoxia.

Fainting fits happen in people with vulnerable nervous system, more frequently: women. The reason of syncope is the nervous system dysfunction that influences the vasomotor center and the CNS vessels. Even slight pains, fright, sight of blood, etc., can cause fainting fits.

Clinical manifestations of a fainting fit are: paleness of face, sickness, ringing the ears, cold sweat, giddiness, weak pulse, dilation of pupils, shallow breathing are loss of consciousness. Fainting fits usually end quickly: in some seconds or minutes the patient recovers consciousness. A patient in the state of syncope should be laid down with his/her head lowered, his clothes should be unbuttoned at the collar and he/she should have as much fresh air as possible. To tone up the vasomotor and breathing centers it is useful to give the patient to smell ammonia and to sprinkle his face with cold water. After the recovery of consciousness it is recommended to have a drink of hot tea or coffee. The patient should remain in bed until all the symptoms of the fainting fit disappear.

COLLAPSE is a sharp and sudden lowering of arterial and venous blood pressure caused by acute vascular insufficiency. It is characterized by decrease in the blood vessel tone and diminishing of the circulating blood volume. Because of hypoxia, development as the result of the collapse, the vital functions of the organism are suppressed.

Intensive pains, bleeding, septic states, and intoxications can cause collapse. It can be cardiogenic or abdominal, etc.

Clinically collapse is similar to shock, but considering different ways the CNS is influenced, they should be distinguished.

When collapse develops, the patient's skin suddenly grows pale and cyanotic or cold and sticky sweat appears, the pulse is weak and rapid, the breathing becomes shallow and fast. The blood pressure falls sharply, the temperature lowers, the patient suffers intensive weakness. The consciousness remains.

It is important to distinguish the collapse itself from the diseases that can cause its development: brain concussion, uremia of diabetic coma, shock, sepsis, etc.

The treatment of collapse is closely connected with the liquidation of its cause (stopping the bleeding, alleviating the pain, etc.). As to medicines, the drugs that infill empty blood vessels are prescribed (strophantine, dopamine, adrenaline, mesatonum as well as blood and blood substitutes transfusions, rest, warming of the body and oxygen therapy).

SHOCK is an extremely grave disturbance of the organism functions that is manifested in the heavy suppression of the CNS functioning and progressing decrement of all physiological systems functioning.

The first specialist who had singled out shock was Le Dran (1737). He described the symptoms and introduced the term "shock" (stroke, shake and jolt) and treated the patients with rest, alcohol and opium.

At the beginning of the XIX century P. Savenko determined shock as a grave disorder of the central nervous system. N.I. Pirogov described the classical picture of shock. He considered this state a reaction of the organism as a whole to trauma. He distinguished two phases of shock - erectile and torpid. Russian physiologists I.M. Sechenov, N.S. Vedensky and I.P. Pavlov made a big contribution to the understanding of changes, happening in the organism in the state of shock.

THE THEORIES OF THE DEVELOPMENT OF SHOCK. In spite of a big number of research works on the etiology and pathogenesis of shock, there still is no generally accepted theory on the mechanism of its development. For instance, shock is not always caused by extensive tissue damage (the toxic theory) or profuse bleeding (the theory of plasma and blood loss). The changes in the endocrine functions or the decrease in the carbon dioxide blood level as the result of lung hyperventilation caused by pain, are manifestations, and not the reasons of shock. The neuro-reflex theory is the most well grounded one. It considers shock to be a violent irritation of the sense organs and CNS, especially the vasomotor centre. As the result of hyperirritation and suppression of the CNS, the peripheral blood vessels contract, and the brain vessels dilate. The metabolism is changed, as well as the functions of the endocrine, especially adrenal glands.

All the strong irritants that influence the human organism cause STRESS (pronounced tension). The results of the research carried out by G. Selie proved that resistance to shock to a great extent depends on the functional state of the adrenal glands. When shock develops, dissociation occurs between the volumetrically speed of the blood flow and the need of the tissues in oxygen and energetic substances. The blood circulation in the tissues and organs decreases because the arterio-venous shunts open. This causes cell hypoxia and metabolism disturbances, which have a decisive role in the gravity of the state and the clinical course of shock (B.I. Dmitriev).

The detoxication functions of the reticuloendothelial system (liver) are decreased. Shock causes changes in different organs, they are so called shock liver, shock kidney and shock lung. Recent investigations show important part in the development of shock belongs to the brain reticular formation and the changes in the sympathico-adrenal system. Shock should be considered a general pathological process. The main factor in the pathogenesis of traumatic and hemorrhagic shock is hypovolaemia.

The classification of shock:

1. According to the etiology of development there are: hypovolaemic shock (traumatic, burn, operation, and hemorrhagic), anaphylactic, cardiogenic and septic shock.
2. In accordance with the gravity of symptoms 4 degrees of shock are distinguished:
 - I degree - state of moderate gravity; pulse rate 80-100 per minute; arterial pressure 90/70 mm of mercury column (m.c.)
 - II degree - grave state; pulse rate 100-140 per minute; arterial pressure 90/70 mm m.c.
 - III degree - very grave state: pulse is 120-100 per minute; arterial pressure 70/50
 - IV degree - preagony: no reaction to external irrigative factors; the puis can be palpated with difficulty only on main vessels; arterial pressure 50 mm m.c. and lower.

196. According to the time of its development shock can be primary or secondary.

The primary shock develops at the time of injury or directly after it, its mechanism is neuroreflex. The secondary shock develops later and is caused by the intoxication with the tissue disintegration products.

In former times shock was subdivided into erectile and torpid forms, and at present it is generally accepted that they are not separate kinds of shock, but successive phases of one general pathologic process.

Erectile phase begins directly after the injury, it is short-termed and manifests in pronounced motor and mental excitation, high pulse rate and mobilization of the endocrine system. N.I. Pirogov's description of erectile shock is still valuable. His description of the torpid

phase is as accurate and full. This phase is characterized by suppression of the nervous system and sharp decrease of all the vital functions of the organism.

The RESULT OF TREATMENT depends on its correct tactics and speed of the therapeutical measures. All the investigations and surgical interventions are put off until the shock is coped with. Only operations of special urgency are possible when the patient is in the slate of shock - such as stopping the bleeding or tracheotomy. The therapy of shock must be pathogenetic and comprehensive. The main tasks in the treatment of shock are: to normalize the nervous system functions, to restore normal haemodynamics, gas blood levels, and water and electrolyte balance.

1. The over-excitability of the CNS can be reduced by the use of narcotic and antihista-

mine drugs and the novocaine blockade.

2. In the normalization of haemodynamics the most effective measures are transfusions

of blood, colloidal solutions, dextrans and special anti-shock solutions. The remedies that tone up the blood vessels are recommended. They are: noradrenalinum, ephedrinum, mesatonum, etc. Hormones (cortisone, hydrocortisone) are used too.

3. To cope with the factors that aggravate the course it is necessary to normalize the microcirculation, liquidate acidosis, to provide artificial lung ventilation or hyperbaric oxygenation.

TRAUMATIC SHOCK

The twentieth century, which has rapidly approached the end, except great discoveries and achievements has brought humanity much trouble and disappointment.

Two horrible world wars, a great number of local conflicts, hundreds of earthquakes, catastrophes, and natural disasters are among them. And though first the diseases of the century were called wounds and later on acquired immune deficiency syndrome (AIDS), the obstinate statistics testifies that for the majority of disabled population the main cause of mortality is trauma.

Maybe everybody knows the famous term "the war on the roads". So, only according to the data of our clinic more than a hundred of victims of traffic accidents enter our clinic every year.

History and a great clinical experience of many generations of medical workers testify that trauma as a rule is followed by shock.

What is shock, namely traumatic shock? How to define it?

It is not without reason that I put exclamation marks, thus even so far the definition of this notion evokes certain difficulties.

One of the investigators of this problem L. Delogers (1962) wrote that "It is easier to distinguish shock than to describe it and it is easier to describe shock than to give it a definition".

So, Dillon wrote: "Shock is a heavy attack on life". S.Vernon, 1970: "Shock is a general reply of organism to the stimulus which the organism admits as potentially lethal"; R.Hardueay (1966): "Shock is non corresponding perfusion of capillaries".

Here it is the definition of shock which GME (giant medical encyclopedia) gives: "Shock is a typical phase pathological process which arises in consequence of dissonance of neurohumoral regulation, which are caused by extreme influences (mechanic trauma, burn etc.) and is characterized by a sharp decrease in blood supply of tissues, which is not proportional to the level of metabolism, by hypoxia or by oppression of the functions of organism".

We consider that no doubt we can simplify this definition having remembered "Shock is the reply of organism to a serious trauma (burn, pain irritant), which is followed by hypovolemia, hypoxia and oppression of vital functions".

Etiology of traumatic shock is heavy mechanic injuries of different genesis, which are followed by bleeding.

Pathogenesis is searched about for three centuries, during that period a lot of theories have been suggested, but nowadays we have got there of them only:

- Theory of bleeding and plasma loss;
- Theory of toxemia;
- Neuvoreflex theory;

Traumatic shock belongs to hypovolemic one or the shock with the volume circulating blood deficit (VCB) (V.F.Trubnikov, 1990).

Trauma and an acute hemorrhage evoke irritation of nervous elements and a stormy impulsation, which leads to throwing into blood a great quantity of catecholamines (surrenalinum, norepinephrine, dophamine). In this consequence a general artery-spasm and increase in a general peripheral resistance. This phenomenon is defined by an uneven increase in the vascular tension with their further dystonia, which is shown in circulation of the blood centralization.

That means that circulation of the blood decreases in skin, muscles, digestion or- \ organs and in vital organs, such as heart, brain, liver, kidneys it remains.

According to centralization of the blood circulation the changes in microcirculatory flow arise. The number of functioning capillaries decreases, the blood cells are detained in post-capillary veins and the paralysis of microcirculation develops in consequence of

opening arterial-venous shunts and a lot of blood sequestrates into inter-tissue space, causing this way hypovolemia.

The viscosity of blood is increased, an aggregation of blood cell comes, and the blood flow is slowed down. That causes a spontaneous thrombogenesis in capillaries. There is a process of disseminated intra-vascular coagulation.

Thus, at a progressing shock, blood supply of the tissues drops below critical level that is necessary for a normal course of the metabolic processes. In consequence of this, cellular injuries arise with adverse consequences for life.

Heavy metabolic damages of cells, when they get in blood, start the secondary pathogenesis factor- toxemia, which provokes "an error circle" with progressing deterioration of a condition if the appropriate treatment will be not apply in time.

The degree of cellular damage and violation of their function is determinative factor of severity of traumatic shock, and it determines capability of its therapy.

To treat shock means to treat shock cell. Some organs are sensible in particular to hypovolemic shock. They are named shock - organs. First of all, kidneys, lungs and liver belong to them.

In lungs the intensity of alveolar ventilation falls sharply. Owing to decreasing the elasticity of lungs tissue atelectasis is formed, the processes of blood oxygenation are violated, that calls respiratory insufficiency. Today it is determined as "respiratory distress syndrome".

The important role in pathogenesis of post shock respiratory insufficiency may have such phenomena as overloading of the organism by fluids, colloid - crystalloid dysbalance of blood, a continuous artificial ventilation of lungs, high contents of oxygen in respiratory mixtures, which arise in consequence of no corrective intensive therapy.

In consequence of traumatic shock the liver is released from deposited glycogen and loses ability to its synthesis. The protein - synthetic and barrier functions of the liver suffer, that is connected with violations of hepatic blood flow.

Violation of kidney's function is also connected with hypovolemia, sludge - formation, which cause limitation of filtration of the primary urine in renal glomeruli. Further, renal ischemia and hypoxia conduct to necrosis of renal tubules and a sharp insufficiency of the kidney.

It is also necessary to remember the important role of acidosis in pathogenesis of shock that causes violation of contractile function of the myocardium, prof vasodilatation, decreasing excretory function of kidneys, and phenomenon of encephalopathy.

Clinic of traumatic shock and phases of its development

N.I. Pyrogov during studying and characterizing of shock clinics noticed that it has phase character. He allocated two clinic phases: erectile and torpid.

The erectile phase is accompanied by significant excitation. It is shown by increase in arterial pressure, vasospasm, dyspnea, and an intensification of metabolism. Motor and language excitation, sometimes euphoria is presented, the patient may underestimate his condition. Skin is pale. Breathing and pulse are accelerated. Reflexes are amplified. Tonus of the skeletal musculature is increased. Duration of the erectile phase is from several minutes till several hours.

The torpid phase is shown by oppression of vital functions of the organism. The classical description of this phase belongs to N.I. Pyrogov: (I quote by language of the original)"... Someone stiff with cold with alienated hand or leg lies immovable in dressing dispensary. He does not ask, does not complain, does not take participation in anything and nothing requires; his body is cold, face is pale like at a corpse, glance is immovable and is turned into a distance, pulse is like a thread and hardly noticed under the fingers, it is often inverted. Someone stiff with cold either does not has answer at all or only about himself, by whisper that audible, breathing is also hardly noticed. Wound and skin are no sensible almost at all, but if the large nerve from wound will be affected, and the patient by one easy reduction his personal muscles finds out an attribute of feeling".

Thus, traumatic shock is characteristic by preservation of consciousness, but sharply expressed depression is noticed. It is difficult to enter a contact with the patient.

Skin is pale and humid. The temperature is reduced. Superficial and deep reflexes are pressed down or completely absent. Shallow breathing is hardly appreciable.

As traumatic shock represents phase process, V.F. Trubnikov (1990), allocates three periods or stages of shock, depending on clinico-pathophysiological changes.

The first stage is stage of circulatory changes (vasoconstriction) without essential metabolic violations. There is a pale, cold, humid skin, normal or something accelerated pulse, normal or a little reduced arterial pressure, a moderate hurried breathing presences.

The second stage is shown by vasodilatation, beginning of intravascular coagulation in microcirculatory channel and by development of "shock kidney".

The third stage is of vessel atony and exchange violations. Intravascular disseminative coagulations with necrotic local injuries in lungs, liver, kidneys dominate, the metabolic acidosis progresses. Clinically: the face is sallow complexion color, limbs are cold. A thread-like pulse is presented, arterial pressure is low, breathing is accelerated I and shallow, and the patient is depressed.

According to weight of shock the most acceptable is following classification.

The first level (an easy shock): skin is pale; pulse is 100 strokes per minute. Arterial pressure is 100/60 mm. Hg, the temperature is normal, normal breathing without changes. The patient is in consciousness, it is possible some excitation.

The second level (shock of middle weight) - skin is pale. Pulse is 110-120 strokes per minute; arterial pressure 90/60, 80/50 mm. Hg; temperature is a little reduced. Breathing is accelerated. The patient is in consciousness and not depressed.

The third level (difficult shock): skin is pale covered with cold sweat. Pulse is like a thread. It is more than 120 strokes per minute.

Arterial pressure is 70/50, 60/40 mm Hg. The patient almost does not react to stimuluses.

Terminal condition (shock of 4-th level) includes preagony, agony and clinical death.

The rough imagination about weight of shock can be made by parameters of hemodynamics. Allgouer and Burri offered to use with this purpose definition of shock index.

Shock index is equaled to a pulse rate divided on systolic arterial pressure.

In norm pulse 60 per minute divided on systolic pressure 120 mm Hg - index is 0,5.

The first stage of shock: pulse 120 per minute divided on systolic pressure 100 mm Hg. The index is equaled 1,0.

The second stage of shock: pulse 120 per minute divided on systolic pressure 80 mm Hg. The index is equaled 1,5.

The third stage of shock (difficult condition): pulse 120 strokes per minute divided on systolic pressure 60 mm Hg. The index is equaled 2,0.

Definition of central venous pressure is important for shock diagnostics. It depends from circulating blood volume and from work capacity of the right ventricle of the heart. The central venous pressure is measured with the help of usual water manometer at a horizontal position of the patient.

The parameters from 30 to 120 mm of water column are normal.

TREATMENT OF SHOCK

It is expedient to allocate five directions in program of anti-shock therapy.

As the axiom it is necessary to remember the rule of "Three catheters": catheter in the central vein, catheter in the urinary bladder and a probe in stomach. It permits to watch on diuresis every hour, to conduct a continuous infusion and decompression of the stomach.

1. Treatment of dangerous for life defeats.

To such measures it is necessary to attribute:

- a) To stop bleeding, in particular profuse. It can be made by temporary methods (tourniquet, to put on clips in wound) and by final (bandaging of vessel in wound or extend,

imposing of vessel seam).

b) Imposing of occlusive dressing at opened pneumothorax, drainage of the pleural cavity at valvular pneumothorax.

c) Transport immobilization by standard or improvised splints.

d) An operative intervention concerning of dangerous for life injuries of internal organs.

2. Completeness of the above-mentioned help depends on a condition of evacuation, by

which this help is given.

3. Interruption of shock impulsion is reached by association of three methods: introduction of shock impulsion is reached by association of three methods: introduction of narcotic, analgetic and neuroleptic means, novocainic blockades of defeat centers and immobilization.

Sometimes at stages of transportation it is necessary to apply narcosis, if the appropriate instrumentation and equipment presence.

4. Replenishment of the circulating blood volume and normalization its rheological properties.

This extremely important part of anti-shock therapy should be programmed in view of cardinal links of shock pathogenesis. It is hypovolemia.

With this purpose it is necessary to replenish vascular channel with osmotic-active fluids. Among them the first place take such colloids as rheopoliglucinum.

So an infusion therapy it is desirable from these blood substitutes.

It is necessary to determinate which drug is better to use rheopoliglucinum or poliglucinum.

The main criterion in this plan is arterial pressure. If it is lower than 70mm Hg and the danger of violation renal filtration appears, it is necessary to introduce rheopoliglucinum. On difference from poliglucinum it does not assist formation of microagglutenates - sludge-complexes, which can obdurate tubuli renales. And what is more rheopoliglucinum improves rheological properties of the blood and simultaneously wonderfully executes hemodynamic functions.

If arterial pressure increases till 80-90 mm Hg, it is expedient to introduce poliglucinum.

The albumin and protein colloids wonderfully keep blood in the vascular channel. On their basis it is expedient to introduce electrolytic and detoxicative solutions.

Concerning of blood transfusion and its components, per last years the idea on expediency such transfusion is proved if the loss of blood is more than 1,5-2 liters. In this situation the correlation of blood and blood substitutes should be equal 1:1.

The speed of transfusion must be high. If arterial pressure is not determined, the speed of transfusion should be 250-500 ml per minute. Determined level of arterial pressure is 90/50 mm hg and the central venous pressure is 60-100 mm of water column it is possible to pass to slow infusion.

At closed injury of the thoracic cavity and abdomen if the capability presence, it is desirable to use auto-hemotransfusion.

The correction of metabolism should begin with liquidation of hypoxia and asphyxia. It is necessary to restore the passableness of respiratory ways and to make an artificial ventilation of lungs, when breathing stop.

The conservative therapy is directed on struggle with destructive action of superoxide radicals, which are formed owing to intensification of free radical oxidation of lipoids (FROL). With this propose antioxidants and anti-shock agents are prescribed, such as vitamins A, E, C, P, cytochrome C, lithium oxybutyrate, calcium pangamate and others. For correction of metabolic acidosis and hyperkalemia 4% sodium bicarbonate solution, acesolum, 10% glucose solution with insulin, 10% calcium chloride, Ringer -Locks solution are injected intravenously.

Prophylaxis of organic and treatment of functional violations of organs and system is used.

According to the modern representations concerning to the pathogenesis of shock, the cellular damage action is determinates by group of substances that are integrated under the name of cytokines. First of all interleikines-2, 6, 8; factor of tumor necrosis, some prostaglandies belong to them. At first cytokines injure alveolar cells, nephrocytes and heart cells.

By researches of last years is proved that the inhibitors of mentioned agents are Trental, or Pentoxiphylinum, and some nonsteroid anti-inflammatory preparations (inhibitors of cyclooxygenase 1,2) - Ibuprophenum, Movalis, Misulidum.

The preparations of essential phospholipides have extremely powerful cytotoxic effect. Essentiale and Lipostabil are the most widespread among them. The important component of complex treatment of shock is hormonal therapy by corticosteroides.

Their anti-shocks and anti-inflammation effects are widely known. In the first 2-3 days of shock treatment it is expediently to inject 1000-1500 ml of Hydrocortisone. For stabilization hemodynamics and decreasing cells need in oxygen (in particular it concerns to cardiomyocytes) it is desirable to use antagonists of calcium (Cornifar, Nifidipinum, Norvasc).

You already know, that the cascade of pathological reactions evokes significant shifts in the blood coagulating system. The infusion therapy that is not full balanced can deepen these shifts. So the correction of coagulating processes should be a necessary component of anti-shock therapy. It should be maked under the control of main parameters, such as coagulation time, coagulogram, quantity of thrombocytes and so on. Prophylactic day's dozes of anticoagulants (to

10 - 20 thousand AU [action unit] of Heparinum or 0,3 Fraxiparinum) it is desirable to prescribe at once from the beginning of infusion therapy. It is desirable to give advantage to the low molecular heparines (Fraxiparinum, Lovenox).

Further it is expedient to apply inhibitors of fibrinolysis, such as E — aminocapronic acid and inhibitors of proteases (Contrykal, Trasilol, Gordox). Thus it is necessary to remember that the results of shock treatment depend directly on time of beginning intensive therapy, on speed of renewal the circulating blood volume, restoration of microcirculation and function of kidneys.

TERMINAL STATES

The well-known anatomist and physiologist P.V. Postnikov carried out investigations on the resuscitation of the organism as long ago as the end of the XVII century. E. Muchin, M. Uspensky, and A. Filomafitsky was elaborated later this issue (the XVIII century). During the last 40 years the staff of the Research Laboratory on General Resuscitology under the leadership of Professor V.A. Negovsky worked out the theoretical bases of the terminal states problem.

Terminal states include:

1. preagonal states;
2. agony;
3. clinical death.

The shock of III^d and IVth degree also belongs to the terminal states.

PREAGONAL STATE is characterized by black-out consciousness, paleness of skin, pronounced acrocyanosis. The spasm of the peripheral vessels causes the increase of hypoxia, acidosis and metabolism disorders. Main reserves are preserved, the breathing is shallow, the pulse is thready, arterial pressure can't be measured.

AGONY is characterized by the absence of consciousness, areflexy and expressed acrocyanosis. The pulse is palpated with difficulty only on the carotids, the heart tones are very weak, bradycardic. The breathing is arrhythmic, shallow and spasmodic. The pupils begin to dilate; the maximal dilation occurs in 90 seconds after the beginning of the brain anoxia.

CLINICAL DEATH: the respiration and cardiac activity are absent. The pupils are dilated and don't react to light. The organism is in the state of minimal life activity, which lasts for 5 to 6 minutes. During this period the brain cells die, not all at the same moment. In 5 or 6 minutes clinical death turns into biological death, when the biological processes in the organism cease.

INTENSIVE THERAPY during the terminal states should be directed at restoring the vital organs functions and at decreasing the tissue hypoxia.

The comprehensive treatment of terminal states consists in:

1. heart massage (direct or indirect);
2. artificial lung ventilation;
3. intra-arterial blood transfusion;
4. heart defibrillation;
5. auxiliary artificial blood circulation.

RESUSCITATION DEPARTMENTS are organized in all big hospitals. They are situated near the operation blocks, are equipped with monitoring systems, and have express-laboratories. Only highly qualified personnel work in these departments.

The main task of the resuscitation departments and the intensive therapy wards is the mobilization of vital organs and normalization of their functions in the patients with serious injuries, acute hemorrhages or in the early post-operation period after major traumatic operations. The main disturbances in such patients are: changes in hemodynamic, respiration, metabolism and the body temperature. Therefore, special attention is focused on diagnosing blood circulation insufficiency (with the help of monitoring systems, radionuclide investigations, thermodilution, etc.); acute respiratory insufficiency (determination of changes in the function of external breathing, blood gas rates, acidic-alkaline balance), disturbances in the water-electrolyte metabolism, liver and kidneys functions, and changes in the blood coagulation and anticoagulation systems (B.I. Dmitriev).

Differentiated approach to the pathogenesis therapy of the vital organs dysfunction permits to decrease significantly the complications and mortality rates in the surgical intervention and different critical states, which occur in surgical patients.

WARDS OF INTENSIVE THERAPY are designed for treating the patients after the operation who need intensive care during some hours or days, before their state improves and permits to take them to an ordinary ward.

BURN AND FROST BITE OF MAXILLOFACIAL PART AT PEACE AND WARTIME

BURNS

Burns are the damage to tissues caused by their exposure to thermal, chemical, electrical or radiation energy.

Classification

A) Causes:

1. thermal;
2. chemical;
3. electrical;
4. radiation.

B) Dept of damage:

degree 1 – damage of the epidermis only.

degree 2 – damage of the epithelium up to the basal layer

degree 3 – damage of the dermis.

3a – epithelial necrosis with partial involvement of the basal layer, hair follicles, sweat and sebaceous glands are intact.

3 b – complete necroses of the dermis ,basal layer and part of the subcutaneous layer.

degree 4 – complete necrosis of the skin and underlying tissues.

The severity of burns depends on the area and depth of damage

Assessment of the area of burns facilitates the adequacy of the therapy. The methods currently used to calculate the area involved the are as follows:

1. A “rule of nine”.

According to this rule, the body surface regions are divided into areas that are multiples of 9% . Each of the following body regions comprises 9% of total surface burn area:

- head and neck – 9%,
- upper limb – 9% , anterior part of the trunk – 18%,
- back – 18% ,
- lower limb – 18% (thigh – 9%, leg and foot – 9%);
- external genitals – 1%.

2. A “rule of palm”.

If the damaged areas are not so extensive and scattered on different parts of the body, the rule of palm is applied to determine the areas of deep burns on the basis of superficial ones. The size of an adult palm is about 1% of the body surface area.

Special tables with graduations made according to the body surface areas (cm²) can also be used:

- the face 500cm² or 3,1%;
- scalp-the hairy part of the head – 480 cm* or 3,0%;
- chest and abdomen – 2990 cm² or 18,0%;
- the hand – 360 cm² or 2,25%;
- the back – 2560 cm² or 16,0% .

Assessment of the depth of burns.

The classification of burns into superficial and deep (degrees 3 b, 4) is primarily based on the skin's capability of regenerating through epithelization in superficial burns cap.

Within the first few hours or even days following injury, it is difficult to assess the depth of burns. The evaluation of skin sensation is used.

In superficial burns, pain sensation at the affected areas is intact or somewhat reduced.

In deep burns, unaffected areas below the affected ones become oedematous. The method of infrared thermography can also be used to determine the depth of burns (the areas with deep burns emit heat at a lesser degree than normal ones). The depth of burns can be established on 7-14 days following the injury.

Evaluation of severity of burns

In adults, the rule of 100 can be used (the age in general and burns area in %):

- 60 – good prognosis;
- 61-80 – relatively good prognosis;
- 81-100 – doubtful prognosis;
- 101 – poor prognosis.

Burn disease.

Burn disease is a constellation of clinical signs that result from superficial burns (degrees 2-3a) with a burns area of above 15% body surface and in deep burns of more than 10% body surface.

The four periods of the disease are identified:

1. burn shock;
2. acute burn toxemia;
3. septicaemia;
4. recovery.

First aid.

First aid in burns should aim at terminating of burning process and cooling the burnet area.

Cooling is achieved with cold water, ice packs, and snow is to be continued for at least 10-15 minutes. After the pain has subsided, aseptic dressing should be applied locally, and

analgesics and non – steroidal inflammatory drugs, warm tea and mineral water are given to the patient. During this period, topical treatment (i.e. therapeutic bandages) should be avoided.

Apart from analgetics, the patient is given neuroleptic and antihistamines prior to transportation that should be before an hour if the patient is to be transported for a long distance, he/she has to be given intravenous infusion of plasma substitutes and solutions of electrolytes, oxygen therapy and general anaesthesia, large amount of alkaline drinks and cardio-vascular agents.

Local treatment.

The two topical (closed and open) methods are used for burns. First, primary the wound toileting is done. The skin around the burnt areas is cleansed with swabs soaked in 0,25% ammonium, 3-4% boric acid, benzene or warm soapy water, with subsequent application of alcohol. Pieces of clothing, foreign bodies, peeling epidermis are removed from the wound; large blisters are opened to drain their contents, minor ones being left alone. Fibrin deposits are usually left intact since it is under these where regeneration takes place. Excessively dirty burnt areas are cleansed with 3% hydrogen peroxide. Sterile gauze or tissues are used to dry the burnt surface.

As a rule, the primary wound toileting is done after 1-2 ml of promedol or omnopon have been injected subcutaneously.

The **closed** method (bandaging or covering with dressing material) is the most commonly used and has a number of advantages as follows:

- isolation of the wound;
- provision of optimum conditions for the application of topical agents;
- the possibility of active movement of patients with extensive burns during transportation.

Its pitfalls are the following:

- labour intensiveness;
- the expenditure of large amounts of dressing material;
- painful change of dressing.

The **open** method avoids these disadvantages. In addition, it promotes formation of the thick eschar on the burnt surface, which is treated by free flow of air over the area, ultraviolet rays or the use of agents that dry it and coagulate protein. It is difficult, however, to implement this method when dealing with patients with deep and wide areas of burns as it requires the use of special equipment (e.g. chambers, cage with electric lamps).

Moreover, there is always a high risk of wound infection (e.g. nosocomial).

When treated by the open method, superficial (degrees 2-3a) burns tend to spontaneously healing. The open method is indicated for facial, genital or perineal burns. The open method requires the use of ointments containing antibiotics (5 and 10% synthomycin emulsions) and antiseptics (0,5% furacilin, 10% sulphacyl) three to four times a day. Suppurated wounds should be dressed. If granulation is found in the areas of deep burns treated with the open method, the closed method should be added.

Each of these methods has its specific indications. At the same time, they can be combined, whenever necessary.

In burns degree 2 it takes 7-12 days for the epithelium to form, while in 3a degree 3 to 4 weeks.

In deep burns, eschar, either as wet or dry necrosis, forms for 3-7 days.

Surgical treatment involves several operations:

- early necrectomy,
- autodermaplasty,
- amputation,
- reconstructive operations

Chemical burns

They are caused by concentrated solutions of acids and alkali (base), which leads to necrosis of the skin and mucosal membranes that may extend to deeper layers.

Acids cause- **dry** or coagulation **necrosis**, while alkali cause -**wet** or colliquative **necrosis**.

Electric burns

High-voltage electric current can cause electric burns at the entry and exit sites of the current. These kinds of burns are always deep, and here the underlying tissues are more damaged than the skin itself. All the tissues on the way of the current get necrotic, the major vessels get thrombosed in addition. In view of these the extent of burn is not established by the skin damage, which is limited to about 2-3 cm in diameter, but by the damage caused to the deep lying tissues that come into contact with the current. When major vessels are damaged there can be tissue necrosis ,gangrene of an organ.

On the sites of entry and exit of the current “current signs” form - burn wounds are the type of “sign” which differs: circular, oval, with a normal diameter of 2-3 cm with the centre drawn in; in lightning treelike type. “Current signs” consist of grey or dark brown coloured

eschars with depressed centres and oedema (edema) of the adjacent tissue. Skin sensitivity is decreased. The “figures” of lightning consist of dark grayish brown tree like forms.

After the cardiac and respiration functions have been restored, dry sterile dressing is applied to the burnt areas. All persons after rescue from an electric shock must be sent to the hospital.

In thermal burns as a result of breathing in hot air or gaseous substances or smoke there can be burns of the respiratory tract.

FROST BITE

1. Dept of damage:

- degree 1 – blood circulatory disorders and the development of reactive inflammations;
- degree 2 – damage to the epithelium up till the germinal layer which is intact;
- degree 3 – complete skin necrosis and partial necrosis of the subcutaneous layer;
- degree 4 – skin necrosis and necrosis of deep lying tissues.

2. According to the disease period (period of frost bite):

- latent (pre-reactive) period;
- reactive period.

Degrees 1 and 2 are superficial, while degrees 3 and 4 are deep.

In first degree frost bite there is blood circulation disorders without necrotic changes in the tissues. Full recovery is usually evident on days 5-7.

In second degree - the superficial layers of skin are damaged, the germinal layer is intact. Skin damage is fully healed within 1-2 weeks.

In third degree - skin regeneration is impossible, and after the eschar has fallen off a skin defect forms, which is covered by granulation tissue and unless skin grafting is done to cover the defect, the wound heals with the formation of a scar.

In fourth degree - a dry or wet gangrene of the affected organ occurs.

Patient with 1-degree complain of pain occasionally burning and unbearable during the warming period. As the patient warms, skin pallor turns into hyperaemia and becomes warm to touch, tissue oedema is minimal, limited to the damaged areas and do not progress. All types of sensation and movement are intact.

Patients with 2-degree complain of itching, burning sensation, tension in the tissues, which persist for several days. Blister formations, which commonly appears in the first days, occasionally on the second day, and rarely on the third-fifth day, is a characteristic sign. Blister are filled with transparent contents, when there are opened a red or pink papilla layer of the skin

that is occasionally covered with fibrin shows. When the bare layer at the base of the blister is touched the patient experiences severe pain. Skin oedema spreads beyond the damaged area.

In 3-degree, pain is more severe and long lasting; there is a history of staying in the cold for long. The skin in the reactive period is violet bluish and cold to touch. During the first days or even hours, all types of sensation are lost. When the blisters are opened violet-bluish surface of the blister base that is not sensitive to skin prick or irritation by gauze swabs soaked with alcohol is found. Subsequently dry or wet skin necrosis sets in; and when they peel off granulation tissue forms.

The 4-degree is unlikely to be distinguished from that of the third degree. The damaged skin looks pale or bluish. All types of sensation are lost and cold to touch. Blisters can appear in the first hours and are friable, filled with haemorrhagic dark contents. Oedema develops very fast 1-2 or a few hours after warming. Subsequently dry or wet gangrene develops. After a week, oedema subsides and the demarcation line appears (intact side and necrotic areas).

Treatment:

- first aid;
- infusion therapy;
- detoxication;
- immune stimulators;
- antibacterial therapy;
- surgical treatment (necrotomy, necrectomy, amputation of the damaged segment, plastic and reconstruction surgeries – skin transplant on the granulated wound, restoration of cosmetic defects);
- local treatment.

PHYSICAL METHODS OF TREATMENT

It is necessary to apply physical methods on the early stages of treatment of patient – from 2-3 days after the damage of jaw. It is necessary foremost to remove a pain syndrome and oedematousness of *ешыгыуы*, normalize the broken circulation of blood. For the decision of this task the electric field is appointed UHF with subsequent electroforesis of calcium of chloride, ultrasound, magnetotherapy, phonoelectroforesis (combination action of ultrasound and galvanization).

For the increase of activity of masseters from their adynamic, related to immobilization of fragments of jaws, improvement of microcirculation, utilize a direct impulsive current, amplipulsotherapy.

Investigations of V.G. Salenkov rotined that affecting area of a break of a direct electric current, by force in 25 mcA and impulsive low frequent current of rectangular form instrumental in early renewal of peripheral circulation of blood and development of arterial hyperemia in the area of break.

In the last decades at the holiatry of breaks of jaws began actively to apply a laser technique. In the beginning the utillized helium-neon lasers, which render the positive affecting microcirculatory, immunity. Affecting optimization of processes of reparative regeneration of semiconductor irasers appeared especially effective . They are distinguished from helium-neon lasers by more high penetrable ability in tissues (5-7 sm). The use of laser is «Pattern», «Milta» of combination action with the permanent magnetic field in the holiatry of victim with the breaks of lower jaw has certain advantages by comparison to the electric field UHF and subsequent electrophoresis of calcium of chloride and allows to shorten frequency of festering-inflammatory complications (S.M. Kaluzhskaya). Application IK laser «Beehive-2ê» was rotined by its expressed antibacterial action, that was instrumental in optimization of cicatrization of breaks of lower jaw, diminishing of frequency of inflammatory processes, and also to reduction of terms of temporal disability of patients (V.V. Makarenkov, 1996). Presently for the prophylaxis of inflammatory complications at the breaks of lower jaw in sew on the plasma streams of argon are successfully utillized a clinic .

Medical physical education, a gymnastics is the system of exercises for patient, conducted with a medical or prophylactic purpose. From an ordinary gymnastics it differs that its task – to affect not all of organism, but on his parts, staggered a pathological process.

Physiological essence of medical gymnastics consists in that exercises, causing (mechanically and reflexly) the acceleration of blood- and lymphokinesiss, improve a trophism, and it, in same queue, conduces to strengthening of tissues, acceleration of regeneration of the damaged organs. Medical physical education is common at the simultaneous damage of soft tissues and bones of face for the prophylaxis of formation of rough scars.

The special value is acquired by medical physical education at gunshot wounds, as they are often accompanied considerable violation of soft fabrics with formation of defects and vast scars. Scars, resulting afterwards in functional and cosmetic violations, can appear even after surgical intervention.

Medical physical education in default of inflammatory complications is used after the removal of guy-sutures on 7-8 day after a surgical roughing-out.

Depending on the damage of one or another area (mouth crack, nose, eyelids, ear) conducted exercise for the different groups of mimic muscles (opening and closing of mouth, blowing out of air). In future at all of wounds of soft tissues of person it is recommended to combine the methods of medical gymnastics with a massage of masticatory muscles.

At the breaks of jaws after their immobilization for 2-3 days begin to conduct exercises, evocative the hyposthenic breathing, causing strengthening of exchange processes. In 12-14 days after imposition of tires, I.e. in the period of primary consolidation of fragments conduct exercises for masseters (tension and weakening). After the removal of tires (in 4 weeks after a trauma) gradually and with the increasing loading appointed exercise on opening of mouth, for lateral motions of lower jaw. A massotherapy can be conducted in this period.

During 20-25 days depending on present destructions soft and by a bone tissues of person strengthening and respiratory exercises appoint, mainly, and also exercise for the mimic muscles of person. Engaged in a medical gymnastics usually conducted before a mirror. In 3-4 weeks after a wound exercises are additionally appointed for masseters during 10-20 days, after appointment a massage of masticatory muscles.

For a prophylaxis and treatment of contractures of temporo-mandibular joint a rubber cork and tubes, apparatus of swinging spoons of Limberg and other are used.

REFERENCES

1. Adams, W. M. (1942) Internal wiring fixation of facial fractures. *Surgery*, 12: 523.
2. Adams, W. M. and Adams L. H. (1956) Internal wire fixation of facial fractures: a fifteen year follow-up report. *Am. J. Surg.*, 92: 12.
3. Afzelius, L. and Rosen, C. (1980) Facial fractures: a review of 368 cases. *Int. J. Oral Surg.*, 9: 25.
4. Al-Kayat, A. and Bramley, P. A. (1979) A modified preauricular approach to the temporomandibular joint and malar arch. *Br. J. Oral Surg.*, 17: 91.
5. Alpert, B. and Seligson, D. (1996) Removal of asymptomatic bone plates used for orthognathic surgery and facial fractures. *J. Oral Maxillofac. Surg.*, 54: 618-21.
6. Altonen. M., Kohonen, A. and Dichoff, K. (1976) Treatment of zygomatic fractures: Internal wiring antral pack - repositioning without fixation. A comparative follow-up study. *J. Maxillofac. Surg.*, 4: 107.
7. Amaratunga, N. A. de S. (1988) A comparative study of the clinical aspects of edentulous and dentulous mandibular fractures. *J. Oral Maxillofac. Surg.*, 46: 3.
8. Anderson, T. and Alpert, B. (1992) Experience with rigid fixation of mandibular fractures and immediate function. *J. Oral Maxillofac. Surg.*, 50: 555-60.

9. Andreason, J. O. and Andrcason, F. M. (1990) *Essentials of Traumatic Injuries to the Teeth*. Copenhagen: Munksgaard.
10. Awty, M. D. and Banks, P. (1971) Treatment of maxillofacial casualties in the Nigerian Civil War. *Oral Surg., Oral Med., Oral Path.*, 31: 4.
11. Англо-русский медицинский словарь для стоматологов. -Москва. -2003. -с. 485.
12. Balasubramaniam, S. (1967) Intra-oral approach for reduction of malar fractures. *Br. J. Oral Surg.*, 4: 189.
13. Banks, P. (1967) Superior orbital fissure syndrome. *Oral Surg.*, 24: 455.
14. Banks, P. (1975) Fixation of facial fractures. *Br. Dent. J.*, 138: 129.
15. Banks, P. (1985) Gunshot wounds. In *Maxillofacial Injuries* (N. L. Rowe and J. LI. Williams, eds), pp. 561-603. Edinburgh: Churchill Livingstone.
16. Banks, P. (1994) Gun shot wounds. In *Fractures of the Facial Skeleton* (N. L. Rowe and J. LI. Williams, eds), pp. 561-603. Edinburgh: Churchill Livingstone.
17. Banks, P. (1998) A pragmatic approach to the management of condylar fractures. *Int. J. Oral Maxillofac. Surg.*, 27: 244-6.
18. Banks, P. and Andrew B. (2001) Fractures of the facial skeleton, p. 196. Edinburg.
19. Battersby, T. G. (1966) Plating of mandibular fractures. *Br. J. Oral Surg.*, 4: 194.
20. Battersby, T. G. (1967) Sequel to gunshot wound of face. *Br. J. Oral Surg.*, 5: 117.
21. Becker, R. (1974) Stable compression plate fixation of mandibular fractures. *Br. J. Oral Surg.*, 12: 13.
22. Bessho, K., Iizuka, T. and Murakami, K. I. (1997) A bio-absorbable poly-L-lactide miniplate and screw system for osteosynthesis in oral and maxillofacial surgery. *J. Oral Maxillofac. Surg.*, 55: 941-5.
23. Bos, R. R. M., Bocring, G., Rozema, F. R. and Leenslag, J. W. (1987) Resorbable poly(L-Lactide) plates and screws for internal fixation of zygomatic fractures. *J. Oral Maxillofac. Surg.*, 45: 751-3.
24. Bottcher, Von M., Schonberger, A. and Sumnig, W. (1988) Erfolgsbewertung konservativer und chirugischer Therapiemethoden bei Keifergelenfracturen. *Zalm- und Keiferheilk. Votr.*, 76: 283.
25. Bourquet, J. (1928) Notre traitement chirurgical des poches sous les yeux sans cicatrice. *Arch. Prov. Chir. Fr. Belg. Our.*, 31: 133-7.
26. Bowerman, J. E. (1975) The surgical approach to the naso-ethmoid complex. Paper presented to the British Association of Oral and Maxillofacial Surgeons.
27. Boyne, P. J. (1967) Osseous repair and mandibular growth after subcondylar fractures. *J. Oral Surg.*, 25: 300.

28. *Br. J. Oral Surg.*, 8: 222. Liu, D. (1993) A simplified technique of orbital decompression for severe retrobulbar haemorrhage. *Am. J. Ophthalmol.*, 116: 34-7.
29. Bradley, J. C. (1975) A radiological investigation into the age changes of the inferior dental artery. *Br. J. Oral Surg.*, 13: 82.
30. Brandt, K. E., Burrell, G. L., Hickerson, W. L. *et al.* (1991) The management of mid-face fractures with intracranial injury. *J. Trauma*, **31**: 15-19.
31. Brown, A. E. and Banks, P. (1993) Late extrusion of alloplastic orbital floor implants. *Brit. J. Oral Maxillofac. Surg.*, 31: 154-7.
32. Brown, A. E. and Obeid, G. (1984) A simplified method for internal fixation of fractures of the mandibular condyle. *Br. J. Oral Surg.*, 22: 145.
33. Brown, J. (1981) Enteral feeds and delivery systems. *Br. J. Hosp. Med.*, 26: 168.
34. Brown, J. and Barnard, D. (1983) The trans-nasal Kirschner wire as a method of fixation of the unstable fracture of the zygomatic complex. *Br. J. Oral Surg.*, 21: 208.
35. Brown, J. B., Fryer, L. and McDowell, F. (1952) Internal wire fixation for fractures of the upper face, orbit, zygoma and severe facial crushes. *Plast. Reconstr. Surg.*, 9: 276.
36. Bruce, R. A. and Strachen, D. S. (1976) Fractures of the edentulous mandible: Chalmers J. Lyons Academy study. *J. Oral Surg.*, 34: 973.
37. Casson, P. R., Bonanno, P. C. and Converse, J. M. (1974) The midface degloving procedure. *Plast. Reconstr. Surg.*, 53: 102-3.
38. Cawood, J. L. (1985) Small plate osteosynthesis of mandibular fractures. *Br. J. Oral Maxillofac. Surg.*, 23: 77.
39. Champion, H. R., Rob, C. G. and Trankey, D. D. (1997) Foreword. In *Ballistic Trauma* (J. M. Ryan, R. F. Dale, B. F. Morgans and G. J. Cooper, eds). London: Arnold.
40. Champy, M. and Lodde, J. P. (1976) Osteosynthesis of the external orbital cavity using screwed plates. Therapeutic indications and results. *Revue Oto-neuro-ophthalmologie*, 48: 243.
41. Christopher J. and Arpey M.D. (1997) *Cutaneous surgery illustrated and practical approach*. McGRAW-HILL.
42. Clark, N., Birely, B., Manson, P. N. *et al.* (1996) High-energy ballistic and avulsive facial injuries: Classification, patterns, and an algorithm for primary reconstruction. *Plast. Reconstr. Surg.*, 98: 583-601.
43. Converse, J. M. and Hogan, V. M. (1970) Open-sky approach for reduction of naso-orbital fractures. *Plast. Reconstr. Surg.*, 46: 396.
44. Converse, J. M. and Smith, B. (1966) Naso-orbital fractures and traumatic deformities of the medial canthus. *Plast. Reconstr. Surg.*, 38: 147-2.

45. Converse, J. M., Firmin, F., Wood-Smith, D. and Fried-land, J. (1973) The conjunctival approach in orbital fractures. *Plast. Reconstr. Surg.*, 52: 656-7.
46. Cook, J. A., Murrant, N. J., Evans, K. L. and Lavelle, R. J. (1992) Manipulation of the fractured nose under local anaesthesia. *Clin. Otolaryngol.*, 17, 337-40.
47. Crawford, M. J. (1943) Appliances and attachments for treatment of upper jaw fractures. *Nav. Med. Bull*, 41: 1151.
48. Crewe, T. C. (1966) A halo frame for facial injuries. *Br. J. Oral Surg.*, 4: 147.
49. Davidson, J., Nickerson, D. and Nickerson, B. (1990) Zygomatic fractures: comparison of methods of internal fixation. *Plast. Reconstr. Surg.*, 86, 25-32.
50. De Man, K. and Bax, W. A. (1988) The influence of the mode of treatment of zygomatic bone fractures on the healing process of the infraorbital nerve. *Br. J. Oral Maxillofac. Surg.*, 26: 419-25.
51. Dingman, R. O. and Natvig, P. (1964) *Surgery of Facial Fractures*. Philadelphia: W. B. Saunders.
52. Dingman, R. O., Grabb, W. C. and O'Neal, R. M. (1969) Management of injuries of the naso-orbital complex. *Arch. Surg.*, 98: 566.
53. Donald, P. J. (1979) The tenacity of the frontal sinus mucosa. *Otolaryngol. Head Neck Surg.*, 87: 557-66.
54. Dulley, B. and Fells, P. (1974) Orbital blow-out fractures. *Br. J. Orthopt.*, 31: 47.
55. Dulley, B. and Fells, P. (1975) Long term follow-up of orbital blow-out fractures with and without surgery. *Modern Problems in Ophthalmol.*, 14: 467-70.
56. Edwards, T. J., David, D. J., Simpson, D. A. and Abbott, A. H. (1994) The relationship between fracture severity and complication rate in miniplate osteosynthesis of mandibular fractures. *Br. J. Plast. Surg.*, 47: 310-11.
57. Ellis, E. (1999) Treatment methods for fractures of the mandibular angle. *Int. J. Oral Maxillofac. Surg.*, 28: 243—52.
58. Ellis, E. and Sinn, D. P. (1993) Treatment of mandibular angle fractures using two 2.4-mm dynamic compression plates. *J. Oral Maxillofac. Surg.*, 51: 969-73.
59. Gerbino, G., Tarello, F., Fasolis, M. and De Gionni, P. P. (1997) Rigid fixation with teeth in the line of mandibular fractures. *Int. J. Oral Maxillofac. Surg.*, 26: 182—6.
60. Gostishcev V.K. (2003) General surgery. The manual. p. 218. Moscow, GEOTAR-MED.
61. Gruss, J. S. (1995) Craniofacial osteotomies and rigid fixation in the correction of post-traumatic craniofacial deformity. *Scand. J. Plast. Reconstr. Surg.*, 27 (Suppl.): 83-95.

62. Iizuka, T. and Lindqvist, T. (1992) Rigid internal fixation of mandibular fractures. An analysis of 270 fractures treated using the AO/ASIF method. *Int. J. Oral Maxillofac. Surg.*, 21: 65-9.
63. Iizuka, T., Lindqvist, C, Hallikainen, D. and Paukku, P. (1991) Infection after rigid internal fixation of mandibular fractures: a clinical and radiological study. *J. Oral Maxillofac. Surg.*, 49: 585-93.
64. James, R. B., Fredrickson, C. and Kent J. N. (1981) Prospective study of mandibular fractures. *J. Oral Surg.*, 39: 275.
65. Jaques, B., Richter, M. and Arza, A. (1997) Treatment of mandibular fractures with rigid osteosynthesis using the AO system. *J. Oral Maxillofac. Surg.*, 55: 1402-7.
66. Joos, V., Meyer, U., Tkotz, T. and Weingart, D. (1999) Use of a mandibular fracture score to predict the development of complications. *J. Oral Maxillofac. Surg.*, 57: 2-5.
67. Kamboozia, A. H. and Punnia-Moorthy, A. (1993) The fate of teeth in mandibular fracture lines. A clinical and radiological follow-up. *Int. J. Oral Maxillofac. Surg.*, 22: 97-101.
68. Kuriakose, M. A., Fardy, M., Sirikumara, M. *et al.* (1996) A comparative review of 266 mandibular fractures with internal fixation using rigid (AO/ASIF) plates or mini-plates. *Br. J. Oral Surg.*, 34: 315-21.
69. Larkin, E. B., Dutton, G. N. and Heron, G. (1994) Impaired perception of moving objects after minor injuries to the eye and mid-face: the Pulfrich phenomenon. *Br. J. Oral Maxillofac. Surg.*, 32: 360-2.
- Leopard, P. J. (1971) Dural tears in maxillofacial injuries.
70. Nash, E. S. and Addy, M. (1980) The use of chlorhexidine gluconate mouthwashes in patients with intermaxillary fixation. *Br. J. Oral Surg.*, 17: 251.
71. Norman, J. E. (1982) Post-traumatic disorders of the jaw joint. *Annals Roy. Coll. Surg.*, 64: 29.
72. Ranta, R. and Ylipaavalnicmi, P. (1973) The effect of jaw fractures in children on the development of the permanent teeth and occlusion. *Proc. Finn. Dent. Soc.*: 69: 99.
73. Silk, D. B. A. (1980) Enteral nutrition. *Hospital Update*. 6: 761.
74. Wood, G. D. (1980) Assessment of function following fracture of the mandible. *Br. Dent. J.*, 149: 137.

