

**High State Educational Establishment of Ukraine  
« Ukrainian Medical Stomatological Academy»  
The department of surgical stomatology and  
maxillofacial surgery with plastic and reconstructive  
surgery of the heard and neck**

**M.G. SKIKEVYCH, D.S. AVETIKOV**

# **THE BASICS OF STOMATOLOGY**

**TEXT-BOOK FOR THE STUDENTS OF THE MEDICAL FACULTY OF THE III-IV LEVEL OF  
ACCREDITATION . ENGLISH FORM OF EDUCATION**

**POLTAVA -2012**

UDK: 616.31(075)-111

The manual is prepared by the docents of the Department of the surgical stomatology and maxillofacial surgery with plastic and reconstructive surgery of the head and neck, **Skikevich Margarita Georgievna**, Candidate of Medical Sciences, and **Avetikov David Solomonovich**, Doctor of Medical Sciences.

We would like to introduce this manual to all the students of the medical faculties of the higher educational institutes of the III – IV levels of accreditation.

The content of the manual co-insides with the program „**The Basics of Stomatology**” and qualifying description of the specialist.

A part of the training of doctors of general medicine consists of introduction of the basics of stomatology and maxillofacial surgery. There are situations in which a general practitioner would have to make a diagnosis and make decisions about first aid in the absence of the dentist. The following illnesses would present the major difficulty: caries, acute pulpitis, eruption teeth, abscess , phlegmons in maxillofacial regions . The traumatic injury of the maxillofacial region is one of the most complex areas according to the anatomy of the head and neck.

The material was presented in such a form and volume that it would be sufficient for the students of the general medicine as well as young stomatologists.

All critical comments would be highly appreciated by the authors.

Рекомендовано ЦМК з ВМО  
МОЗ України  
як підручник для студентів  
медичних факультетів вищих  
медичних навчальних

закладів

IV рівня акредитації  
(протокол № 1 від

27.12.2011)

Підручник підготовлений співробітниками кафедри хірургічної стоматології та щелепно-лицевої хірургії з пластичною та реконструктивною хірургією голови та шиї к. мед. н., доц.. Скікевич М.Г. та завідувачем кафедри д. мед. н., доц.. Аветіковим Д.С.

#### **Рецензенти:**

- завідувач кафедри терапевтичної стоматології Харківського національного медичного університету, д.мед.н., проф. Рябоконт Є.М.;
- завідувач кафедри хірургічної стоматології та щелепно-лицевої хірургії Харківського національного медичного університету, д.мед.н., проф. Рузин Г.П.

Запропонований підручник призначений для студентів медичних факультетів вищих навчальних закладів III – IV рівнів акредитації.

Зміст відповідає програмі „Основи стоматології” та освітньокваліфікаційній характеристиці спеціаліста (ОКХ). В задачах підготовки лікаря загально медичного профілю можливі ситуації, коли він не зможе скористатися консультацією стоматолога або щелепно-лицевого хірурга і буде змушений самостійно ставити діагноз та вирішувати питання надання екстреної стоматологічної допомоги. Це відноситься до запальних захворювань (карієс, гострий пульпіт, періодонтит, абсцеси, флегмони щелепно-лицевої локалізації), а також до достатньо актуального питання натеper – травматичних ушкоджень обличчя і щелеп.

Матеріалами підручника можуть користуватися студенти медичних та стоматологічних факультетів, лікарі-інтерни, магістранти та лікарі практичної охорони здоров'я.

Усі критичні зауваження автори приймуть з великою вдячністю.

## CONTENTS

|                                          |     |
|------------------------------------------|-----|
| Head and neck anatomy.....               | 1   |
| Tooth anatomy.....                       | 3   |
| Dental x-rays.....                       | 7   |
| Child Dental Health.....                 | 9   |
| Impacted tooth.....                      | 11  |
| Dental extraction.....                   | 13  |
| Mouth Disorders.....                     | 20  |
| Toothaches.....                          | 22  |
| Breath odor.....                         | 25  |
| Facial swelling.....                     | 28  |
| Dental cavities.....                     | 29  |
| Gingivitis.....                          | 33  |
| Periodontitis.....                       | 36  |
| Trench mouth (Vincent's stomatitis)..... | 37  |
| Mouth and Teeth.....                     | 40  |
| Tooth abscess.....                       | 42  |
| Bleeding gums.....                       | 43  |
| Gingivostomatitis.....                   | 45  |
| Gums – swollen.....                      | 49  |
| Herpetic stomatitis.....                 | 50  |
| Mouth ulcers.....                        | 52  |
| Osteomyelitis.....                       | 53  |
| Sinusitis.....                           | 55  |
| Leukoplakia.....                         | 60  |
| HIV infection.....                       | 62  |
| Oral thrush.....                         | 65  |
| Lichen planus.....                       | 67  |
| Mouth sores.....                         | 69  |
| Bruxism.....                             | 72  |
| Gum biopsy.....                          | 75  |
| Salivary Gland Disorders.....            | 76  |
| Salivary duct stones.....                | 77  |
| Salivary gland biopsy.....               | 78  |
| Sjogren's Syndrome.....                  | 80  |
| Salivary gland tumors.....               | 80  |
| Salivary gland infections.....           | 82  |
| Face pain.....                           | 85  |
| Herpes zoster.....                       | 86  |
| Peritonsillar abscess.....               | 89  |
| Phlegmon.....                            | 90  |
| Ludwig's angina.....                     | 103 |
| Cleft lip and palate.....                | 104 |
| Temporomandibular Joint Dysfunction..... | 106 |

|                                                                         |     |
|-------------------------------------------------------------------------|-----|
| Tongue Disorders.....                                                   | 109 |
| Glossitis.....                                                          | 110 |
| Tongue problems.....                                                    | 113 |
| Jaw Injuries and Disorders.....                                         | 118 |
| Micrognathia.....                                                       | 120 |
| Prognathism.....                                                        | 122 |
| Facial trauma.....                                                      | 123 |
| Broken or knocked out tooth.....                                        | 125 |
| Wounds.....                                                             | 126 |
| Head and face reconstruction.....                                       | 143 |
| Skin smoothing surgery.....                                             | 144 |
| Scars.....                                                              | 146 |
| Facial paralysis.....                                                   | 148 |
| Sore throat.....                                                        | 149 |
| Earache.....                                                            | 153 |
| Swollen lymph nodes.....                                                | 155 |
| Trigeminal neuralgia.....                                               | 158 |
| Shock.....                                                              | 160 |
| Tracheostomy.....                                                       | 161 |
| The organization of help to the oncological stomatological patient..... | 163 |
| Role of the dental practitioner in cancer prevention and diagnosis..... | 169 |
| References.....                                                         | 169 |

# Head and neck anatomy

**Head and neck anatomy** focuses on the structures of the head and neck of the human body, including the brain, bones, muscles, blood vessels, nerves, glands, nose, mouth, teeth, tongue, and throat. It is an area frequently studied in depth by surgeons, dentists, dental technicians, and speech language pathologists.

The skull (Fig.1) is anterior to the spinal column and is the bony structure that encases the brain. Its purpose is to protect the brain and allow attachments for the facial muscles. The two regions of the skull are the cranial and facial region. The cranial portion is the part of the skull that directly houses the brain and the facial portion includes the rest of the bones of the skull.

**Musculoskeletal system.** The head is positioned upon the superior portion of the vertebral column, attaching the skull upon C-1, (the atlas). The skeletal section of the head and neck forms the superior segment of the axial skeleton and comprises skull, hyoid bone, auditory ossicles, and cervical spine. The skull can be further subdivided into:

- (a) cranium, (8 bones: frontal, 2-parietal, occipital, 2-temporal, sphenoid, ethmoid), and
- (b) facial bones, (14 bones: 2-zygomatic, 2-maxillary, 2-palatine, 2-nasal, 2-lacrimal, vomer, 2-inferior conchae, mandible).

As the fetus develops, the facial bones usually form into pairs, and then fuse together. As the cranium fuses, sutures are formed that resemble stitching between bone plates.

**Circulatory system.** Blood circulates from the upper systemic loop originating at the aortic arch, and includes: the brachiocephalic artery, left common carotid and left subclavian artery. The head and neck are emptied of blood by the subclavian vein and jugular vein.

## Blood supply

The **brachiocephalic artery** or trunk is the first and largest artery that branches to form the right common carotid artery and the right subclavian artery (Fig.2). This artery provides blood to the right upper chest, right arm, neck, and head, through a branch called right vertebral artery. The right and left vertebral artery feed into the basilar artery and upward to the Posterior cerebral artery, which provides most of the brain with oxygenated blood. The posterior cerebral artery and the posterior communicating artery are within the **circle of Willis**.

The **left common carotid artery** divides to form the: internal carotid artery (ICA) and an external carotid artery (ECA). The ICA supplies the brain. The ECA supplies the neck and face.

The **left subclavian artery** and the **right subclavian artery**, one on each side of the body form the internal thoracic artery, the vertebral artery, the thyrocervical trunk, and the costocervical trunk. The subclavian becomes the axillary artery at the lateral border of the first rib. The **left subclavian artery** also provides blood to the left upper chest and left arm.

The **Blood-brain barrier** (BBB) is semi-permeable membrane that controls the capillary leak potential of the circulatory system. In most parts of the body, the smallest blood vessels, called capillaries, are lined with endothelial cells, which have small spaces between each individual cell so substances can move readily between the inside and the outside of the capillary. This is not the case in the brain. In the brain, the endothelial cells fit tightly together to create a tight junction and substances cannot pass out of the bloodstream.

Specialized glial cells called astrocytes form a tight junction or protective barrier around brain blood vessels and may be important in the development of the BBB. Astrocytes may be also be responsible for transporting ions (electrolytes) from the brain to the blood.

**Blood return.** Blood from the brain and neck flows from: (1) within the cranium via the internal jugular veins, a continuation of the sigmoid sinuses. The right and left external jugular veins drain from the parotid glands, facial muscles, scalp into the subclavian veins. The right and left vertebral veins drain the vertebrae and muscles into the right subclavian vein and into the superior vena cava, into the right atrium of the heart.

The **lymphatic system** drains the head and neck of excess interstitial fluid via lymph vessels or capillaries, equally into the right lymphatic duct and the thoracic duct.

Lymph nodes line the cervical spine and neck regions as well as along the face and jaw.

The tonsils also are lymphatic tissue and help mediate the ingestion of pathogens.

Tonsils in humans include, from superior to inferior: nasopharyngeal tonsils (also known as adenoids), palatine tonsils, and lingual tonsils.

Together this set of lymphatic tissue is called the tonsillar ring or Waldeyer's ring.

**Oral cavity.** The mouth, also called the oral cavity or buccal cavity, is the entranceway into the digestive system containing both primary and accessory organs of digestion.

The mouth is designed to support chewing, (mastication) and swallowing, (deglutition), and speech (phonation).

Two rows of teeth are supported by facial bones of the skull, the maxilla above and the mandible below.

Teeth are surrounded by gingiva, or gums, part of the periodontium, support tissue of oral cavity protection.

In addition to the teeth, other structures that aid chewing are the lips, cheeks, tongue, hard palate, soft palate, and floor of the mouth.

## Tooth anatomy

Humans normally (Fig.3) will produce two sets of teeth called primary dentition, or deciduous teeth, and secondary dentition, or permanent teeth.

A tooth is the toughest known substance in the body exceeding bones in density and strength. Tooth enamel lends great strength to the tooth structure. The formation of a developing tooth includes the process of dentin formation, and enamel formation. As the tooth breaks through the gum into the mouth, the process is called eruption. The formation of teeth begins in early fetal development and goes through six stages:

- (1) initiation stage, 6th - 7th week
- (2) bud stage, 8th wk
- (3) cap stage, 9th-10 wk
- (4) bell stage, 11th-12th wk
- (5) apposition
- (6) maturation stage

Tooth enamel is white initially but is susceptible to stains from coffee and cigarette usage. A tooth sits in a specialized socket called gomphosis. The tooth is held in location by a periodontal ligament, with the assistance of cementum.

The white visible part (Fig.4) of a tooth is called the **crow**n. The rounded upper projections of the back teeth are **cusps**. The hard white exterior covering of the tooth is the **enamel**. As the tooth tapers below the gumline, the **neck** is formed. Below the neck, holding the tooth into the bone, is the **root** of the tooth. The inner portions of the tooth consist of the dentin, a bonelike tissue, and the **pulp**. The pulp



is a soft tissue area containing the nerve and blood vessels to nourish and protect the tooth, located within the pulp cavity.

There are various tooth shapes for different jobs. For example, when chewing, the upper teeth work together with the lower teeth of the same shape to bite, chew, and tear food. The names of these teeth are:

- (1) Incisors, there are eight incisors located in the front of the mouth (four on the top and four on the bottom). They have sharp, chisel-shaped crowns that **cut** food.
- (2) Cuspids (or canine tooth), the four cuspids are next to each incisor. Cuspids have a pointed edge to **tear** food.
- (3) Premolars (or bicuspids), the four pairs of molars are located next to the cuspids. They **crush** and **tear** food.
- (4) Molars, there are twelve molars, in sets of three, at the back of the mouth. They have wide surfaces that help to **grind** food.

Adults have 32 permanent teeth, and children have 20 deciduous teeth.

The structure of the tooth includes dentin, pulp and other tissues, blood vessels and nerves imbedded in the bony jaw. Above the gum line, the tooth is protected by the hard enamel covering.

**Periodontium.** The periodontium includes all of the support membranes of the dental structures surround and support the teeth such as the gums and the attachment surfaces and membranes.

This includes epithelial tissues (epithelium), connective tissues, (ligaments and bone), muscle tissue and nervous tissue.

**Tongue.** The tongue is a specialized skeletal muscle that is specially adapted for the activities of speech, chewing, developing gustatory sense (taste) and swallowing.

It is attached to the hyoid bone.

Terms meaning tongue include "glosso" and "lingual."

**Mucosa.** The protective tissues of the oral cavity are continuous with the digestive tract are called mucosa or mucous membranes.

They line the oral, nasal, and external auditory meatus, (ear), providing lubrication and protection against pathogens.

This is a stratified squamous epithelium containing about three layers of cells.

The lips are also protected by specialized sensory cells called Meissner's corpuscles.

The cells of the inner oral cavity are called the buccal mucosa.

## Development of baby teeth

| UPPER           | ERUPTS BY | LOWER           | ERUPTS BY |
|-----------------|-----------|-----------------|-----------|
| Central incisor | 8-10 Mo   | Central incisor | 6-9 Mo    |
| Lateral incisor | 8-10 Mo   | Lateral incisor | 15-21 Mo  |
| Canine (Cuspid) | 16-20 Mo  | Canine (Cuspid) | 15-21 Mo  |
| First molar     | 15-21 Mo  | First molar     | 15-21 Mo  |
| Second molar    | 20-24 Mo  | Second molar    | 20-24 Mo  |

## Teething

Teething is the growth of teeth through the gums in the mouth of infants and young children (Fig.5).

Teething usually begins when a baby is between 6 and 8 months old. All 20 baby teeth should be in place by the time a child is 30 months old. Some children do not show any teeth until much later than 8 months, but this is usually normal.

- The two bottom front teeth (lower incisors) usually come in first.
- Next to grow in are usually the two top front teeth (upper incisors).
- Then the other incisors, lower and upper molars, canines, and finally the upper and lower lateral molars come in.

The signs of teething are:

- Acting cranky or irritable
- Biting or chewing on hard objects
- Drooling, which may often begin before teething starts
- Gum swelling and tenderness
- Refusing food
- Sleeping problems

Teething does NOT cause fever or diarrhea. If your child develops a fever or diarrhea and you are worried about it, talk to your health care provider.

Tips to ease your child's teething discomfort:

- Wipe your baby's face with a cloth to remove the drool and prevent a rash.
- Give your infant a cool object to chew on, such as a firm rubber teething ring or a cold apple. Avoid liquid-filled teething rings, or any plastic objects that might break.
- Gently rub the gums with a cool, wet washcloth, or (until the teeth are right near the surface) a clean finger. You may place the wet washcloth in the freezer first, but wash it before using it again.
- Feed your child cool, soft foods such as applesauce or yogurt (if your baby is eating solids).
- Use a bottle, if it seems to help, but only fill it with water. Formula, milk, or juice can all cause tooth decay.

You can buy the following medications and remedies at the drug store:

- Acetaminophen (Tylenol and others) or ibuprofen can help when your baby is very cranky or uncomfortable.
- Teething gels and preparations rubbed right on your baby's gums may help the pain for a short while. Be careful not to use too much.

## Natal teeth

### Alternative Names

Fetal teeth

Natal teeth are teeth that are already present at the time of birth. They are different from neonatal teeth, which grow in during the first 30 days after birth.

### Considerations

Natal teeth are relatively uncommon, appearing in about one in every 2,000 to 3,000 births. Although most natal teeth are isolated incidents, their presence may be associated with certain medical syndromes.

Natal teeth generally develop on the lower gum, where the central incisor teeth will appear. They have little root structure and are attached to the end of the gum by soft tissue and are often wobbly.

Natal teeth are usually not well formed, but they are firm enough that, because of their placement, they may cause irritation and injury to the infant's tongue when nursing. Natal teeth may also be uncomfortable for a nursing mother.

Frequently, natal teeth are removed shortly after birth while the newborn infant is still in the hospital, especially if the tooth is loose and the child runs a risk of aspiration, or "breathing in" the tooth.

### **When to Contact a Medical Professional**

Go to the doctor if an infant with natal teeth develops a sore tongue or mouth or other symptoms.

### **Causes**

Most of the time, natal teeth are not related to a medical condition. However, sometimes they may be associated with:

- Ellis-van Creveld syndrome
- Hallermann-Streiff syndrome
- Pierre Robin syndrome
- Soto syndrome

### **Home Care**

If the teeth are not removed, keep them clean by gently wiping the gums and teeth with a clean, damp cloth. Examine the infant's gums and tongue frequently to make sure the teeth are not causing injury.

### **What to Expect at Your Office Visit**

This finding is usually discovered by the health care provider during the initial examination of the infant, and often no further documentation is needed other than just to note that there were teeth present at birth.

Dental x-rays may be considered. If there are signs of any condition that can be associated with natal teeth, examination and testing for that condition will be performed.

## **Dental x-rays**

### **Alternative Names**

X-ray - teeth; Radiograph - dental; Bitewings; Periapical film; Panoramic film

Dental x-rays are a type of picture of the teeth and mouth. X-rays are a form of electromagnetic radiation, just like visible light. They are of higher energy, however, and can penetrate the body to form an image on film.

Structures that are dense (such as silver fillings or metal restoration) will block most of the photons and will appear white on developed film. Structures containing air will be black on film, and teeth, tissue, and fluid will appear as shades of gray.

### **How the Test is Performed**

The test is performed in the dentist's office. There are four types of x-rays:

- Bitewing
- Periapical
- Palatal (also called occlusal)
- Panoramic

The bitewing is when the patient bites on a paper tab and shows the crown portions of the top and bottom teeth together.

The periapical shows one or two complete teeth from crown to root.

A palatal or occlusal x-ray captures all the upper and lower teeth in one shot while the film rests on the biting surface of the teeth.

A panoramic x-ray requires a special machine that rotates around the head. The x-ray captures the entire jaws and teeth in one shot. It is used to plan treatment for dental implants, check for impacted wisdom teeth, and detect jaw problems. A panoramic x-ray is not good for detecting cavities, unless the decay is very advanced and deep.

In addition, many dentists are taking x-rays using digital technology. The image runs through a computer. The amount of radiation transmitted during the procedure is less than traditional methods.

### **How to Prepare for the Test**

There is no special preparation. Notify the dentist if you are pregnant.

### **How the Test Will Feel**

The x-ray itself causes no discomfort. Some people find that biting on the piece of film makes them gag. Slow, deep breathing through the nose usually relieves this feeling.

### **Why the Test is Performed**

Dental x-rays help diagnose disease and injury of the teeth and gums.

### **Normal Results**

The x-rays show a normal number, structure, and position of the teeth and jaw bones. There are no cavities or other problems(Fig.6).

### **What Abnormal Results Mean**

Dental x-rays may be used to identify the following:

- The number, size, and position of teeth
- Unemerged or impacted teeth
- The presence and extent of dental caries (cavities)
- Bone damage (such as from periodontitis)
- Abscessed teeth
- Fractured jaw
- Malocclusion of teeth
- Other abnormalities of the teeth and jaw bones

### **Risks**

There is very low radiation exposure. However, no one should receive more radiation than necessary. A lead apron can be used to cover the body and reduce radiation exposure. Pregnant women should not have x-rays taken unless absolutely necessary.

### **Considerations**

Dental x-rays can reveal dental cavities (tooth decay) before they are visible even to the dentist. Many dentists will take yearly bitewings to catch the early development of cavities.

Another imaging test, called cone beam computerized tomography (CBCT), may be used prior to dental surgery, especially when multiple implants are being placed. This test is usually done in a hospital or imaging center.

## **Child Dental Health**

Healthy teeth are important to your child's overall health. From the time your child is born, there are things you can do to promote healthy teeth. For babies, you should clean teeth with a soft, clean cloth or baby's toothbrush. Avoid putting the baby to bed with a bottle and check teeth regularly for spots or stains.

For all children, you should

- Brush teeth with a fluoride toothpaste
- Provide healthy foods and limit sweet snacks and drinks
- Provide low-fat milk and dairy products high in calcium

- Schedule regular dental check-ups

Forming good habits at a young age can help your child have healthy teeth for life.

## **Fluoride in diet**

### **Alternative Names**

Diet - fluoride

Fluoride occurs naturally in the body as calcium fluoride. Calcium fluoride is mostly found in the bones and teeth.

### **Function**

Small amounts of fluoride help reduce tooth decay. Fluoridation of tap water helps reduce cavities in children by 50 - 60%. Fluorides also help maintain bone structure. Low doses of fluoride salts may be used to treat conditions that cause faster-than-normal bone loss, such as menopause.

### **Food Sources**

Fluoridated water, and food prepared in fluoridated water, contains fluoride. Natural sodium fluoride is in the ocean, so most seafood contains fluoride. Tea and gelatin also contain fluoride.

### **Side Effects**

Fluoride deficiency may appear in the form of increased cavities, and weak bones and teeth. Fluoride supplementation is necessary to prevent cavities, especially in children, if tap water is not fluoridated. As an example, well water is not fluoridated.

Excess fluoride in the diet is extremely rare.

### **Recommendations**

The Food and Nutrition Board at the Institute of Medicine recommends the following dietary intake for fluoride:

#### **Infants**

- 0 - 6 months: 0.01 milligrams per day (mg/day)
- 7 - 12 months: 0.5 mg/day

#### **Children**

- 1 - 3 years: 0.7 mg/day
- 4 - 8 years: 1.0 mg/day
- 9 - 13 years: 2.0 mg/day

#### Adolescents and Adults

- Males age 14 to 18 years: 3.0 mg/day
- Males over 18 years: 4.0 mg/day
- Females over 14 years: 3.0 mg/day

The best way to get the daily requirement of essential vitamins is to eat a balanced diet that contains a variety of foods from the food guide pyramid.

Specific recommendations depend on age and gender (Fig.7). Ask your doctor which amount is best for you.

## Amelogenesis imperfecta

Amelogenesis imperfecta is a tooth development disorder in which the teeth are covered with thin, abnormally formed enamel.

**Causes.** Amelogenesis imperfecta is passed down through families as a dominant trait. That means you only need to get the abnormal gene from one parent in order for you to get the disease.

**Symptoms.** The enamel of the tooth is soft and thin. The teeth appear yellow and are easily damaged. Both baby teeth and permanent teeth are affected.

#### When to Contact a Medical Professional

Go to the dentist if you have symptoms of this condition.

#### Exams and Tests

A dentist can identify and diagnose the condition.

#### Treatment

The treatment depends on the severity of the problem. Full crowns will improve the appearance of the teeth and protect them from damage.

#### Outlook Prognosis

Treatment is often successful in protecting the teeth.

#### Possible Complications



The enamel is easily fractured and damaged, which affects the appearance of the teeth, especially if left untreated.

# Impacted tooth

## Alternative Names

Tooth - unemerged; Unemerged tooth; Dental impaction; Unerupted tooth

An impacted tooth is a tooth that fails to fully pass through the gums.

## Causes

Teeth start to pass through the gums (emerge) during infancy, and again when the primary (baby) teeth are replaced by the permanent teeth.

If a tooth fails to emerge, or emerges only partially, it is considered to be impacted. The most common teeth to become impacted are the wisdom teeth (the third set of molars). They are the last teeth to emerge, usually between the ages of 17 and 21.

An impacted tooth remains stuck in gum tissue or bone for various reasons. It may be that the area is just overcrowded and there's no room for the teeth to emerge. For example, the jaw may be too small to fit the wisdom teeth. Teeth may also become twisted, tilted, or displaced as they try to emerge, resulting in impacted teeth.

Impacted wisdom teeth are very common. They are often painless and cause no apparent trouble. However, some professionals believe an impacted tooth pushes on the next tooth, which pushes the next tooth, eventually causing a misalignment of the bite. A partially emerged tooth can trap food, plaque, and other debris in the soft tissue around it, leading to inflammation and tenderness of the gums and unpleasant mouth odor. This is called pericoronitis.

**Symptoms:** bad breath; difficulty opening the mouth (occasionally); pain or tenderness of the gums (gingiva) or jaw bone; prolonged headache or jaw ache; redness and swelling of the gums around the impacted tooth; swollen lymph nodes of the neck (occasionally); unpleasant taste when biting down on or near the area; visible gap where a tooth did not emerge.

## When to Contact a Medical Professional

Go to your dentist if there is an unemerged tooth (or partially emerged tooth) and pain in the gums or other symptoms have developed.

## Exams and Tests

Your dentist will look for swollen tissue over the area where a tooth has not emerged, or has only partially emerged. The impacted tooth may be pressing on nearby teeth. The gums around the area may show signs of infection such as redness, drainage, and tenderness. As gums swell over impacted wisdom teeth and then drain and tighten, it may feel like the tooth came in and then went back down again.

Dental x-rays confirm the presence of one or more teeth that have not emerged.

### **Treatment**

No treatment may be needed if the impacted tooth is not causing any problems.

Over-the-counter pain relievers may help if the impacted tooth causes discomfort. Warm salt water (one-half teaspoon of salt in one cup of water) or over-the-counter mouthwashes may be soothing to the gums.

Removal of the tooth (extraction) is the usual treatment for an impacted tooth. This is usually done in the dentist's office, but difficult cases may require an oral surgeon. Antibiotics may be prescribed before the extraction if the tooth is infected.

### **Outlook Prognosis**

Impacted teeth may cause no problems for some people and may never require treatment. Treatment is usually successful when it does cause symptoms.

It is often preferable to have wisdom teeth removed before age 30 due to the flexibility of bone, which will allow an easier removal and better healing. As a person ages, the bone becomes more rigid and complications can develop.

**Complications of an impacted tooth** include:

abscess of the tooth or gums; chronic discomfort in the mouth; infection; malocclusion of the teeth; plaque trapped between teeth and gums.

# Dental extraction

A **dental extraction** (also referred to as **exodontia**) is the removal (Fig.8) of a tooth from the mouth. Extractions are performed for a wide variety of reasons, including tooth decay that has destroyed enough tooth structure to render the tooth non-restorable. Extractions of impacted or problematic wisdom teeth are routinely performed, as are extractions of some permanent teeth to make space for orthodontic treatment.

## Reasons for tooth extraction

The most common reason for extraction is tooth damage due to breakage or decay (fig.9). There are additional reasons for tooth extraction:

- Severe tooth decay or infection (acute or chronic alveolar abscess). Despite the reduction in worldwide prevalence of dental caries, still it is the most common reason for extraction of (non-third molar) teeth with up to two thirds of extractions.
- Extra teeth which are blocking other teeth from coming in.
- Severe gum disease which may affect the supporting tissues and bone structures of teeth.
- In preparation for orthodontic treatment (braces)
- Teeth in the fracture line
- Fractured teeth
- Prosthetics; teeth detrimental to the fit or appearance of dentures
- Insufficient space for wisdom teeth (impacted third molars). Although many dentists remove asymptomatic impacted third molars, American as well as British Health Authorities recommended against this routine procedure, unless there are evidences for disease in the impacted tooth or the near environment. The American Public Health Association, for example, adopted a policy, *Opposition to Prophylactic Removal of Third Molars (Wisdom Teeth)* because of the large number of injuries resulting from unnecessary extractions.
- Cosmetic; teeth of poor appearance, unsuitable for restoration
- Receiving radiation to the head and neck may require extraction of teeth in the field of radiation.
- Deliberate, medically unnecessary, extraction as a particularly dreadful form of physical torture.
- It was once a common practice to remove the front teeth of institutionalized psychiatric patients who had a history of biting.

## Types of extraction

Extractions are often categorized as "simple" or "surgical".

**Simple extractions** are performed on teeth that are visible in the mouth, usually under local anaesthetic, and require only the use of instruments to elevate and/or grasp the visible portion of the tooth. Typically the tooth is lifted using an elevator, and using dental forceps, rocked back and forth until the Periodontal ligament has been sufficiently broken and the supporting alveolar bone has been adequately widened to make the tooth loose enough to remove. Typically, when teeth are removed with forceps, slow, steady pressure is applied with controlled force.

**Surgical extractions** involve the removal of teeth that cannot be easily (fig.10) accessed, either because they have broken under the gum line or because they have not erupted fully. Surgical extractions almost always require an incision(fig.11,12). In a surgical extraction the doctor may elevate the soft tissues covering the tooth and bone and may also remove some of the overlying and/or surrounding jawbone tissue with a drill or osteotome. Frequently, the tooth may be split into multiple pieces to facilitate its removal. Surgical extractions are usually performed under a general anaesthetic.

### **Post-extraction healing**

Following extraction of a tooth, a blood clot forms in the socket, usually within an hour. Bleeding is common in this first hour, but its likelihood decreases quickly as time passes, and is unusual after 24 hours. The raw open wound overlying the dental socket takes about 1 week to heal. Thereafter, the socket will gradually fill in with soft gum tissue over a period of about one to two months. Final closure of the socket with bony remodeling can take six months or more.

### **Partial eruption**

Sometimes the wisdom tooth (fig.13,14) fails to erupt completely through the gum bed and the gum at the back of the wisdom tooth extends over the biting surface, forming a soft tissue flap or lid around the tooth called an operculum. Teeth covered (fig.15) by an operculum can be difficult to clean with a toothbrush. Additional cleaning techniques can include using a needle-less plastic syringe to vigorously wash the tooth with moderately pressured water or to softly wash it with hydrogen peroxide.

However, debris and bacteria can easily accumulate under an operculum, which may cause pericoronitis, a common infection problem in young adults with partial impactions that is often exacerbated by occlusion with opposing third or second molars. Common symptoms include a swelling and redness of the gum around the eruption site, difficulty in opening the mouth, a bad odor or taste in the mouth, and pain in the general area which may also run down the entire lower jaw or possibly the neck. Untreated pericoronitis can progress to a much more severe infection.

If the operculum does not disappear, recommended treatment is extraction of the wisdom tooth. An alternative treatment involving removal of the operculum, called

operculectomy, has been advocated. There is a high risk of permanent or temporary numbness of the tongue due to damage of the nerve with this treatment and it is no longer recommended as a standard treatment in oral surgery.

Chronic inflammation in the gingival tissue of the partially erupted third-molar, i.e. chronic pericoronitis, may be the etiology for the development of paradental cyst, an inflammatory odontogenic cyst.

### **Complications after extractions of teeth:**

bleeding from the extraction socket; infections; dry socket; broken jaw; sinus perforation; sequestrii; retained root tips; osteonecrosis of the jaw (bone-death at site of extractions);osteoradio-necrosis (Osteonecrosis related to radiation therapy).

#### **1. Bleeding**

It is possible to bleed to death following the extraction of a tooth. But it almost never happens. The only patients that may still be in danger from excessive bleeding are those who are taking anticoagulant drugs (blood thinners) like Coumadin or Heparin for cardiovascular problems, or people with bleeding disorders like Hemophilia or related clotting cascade disorders . These patients should consult their physicians before having a tooth extracted. People taking aspirin and other non steroidal anti inflammatory drugs may experience prolonged bleeding times, but in my experience, these drugs have never presented a problem as long as the patient keeps the extraction site covered with gauze to stem the bleeding. The blood WILL clot eventually!

#### **2. Infection**

The mouth is alive with bacteria, especially in people with poor oral hygiene. Infection is a constant problem after extractions, and most dentists have developed a personal protocol on whether or not a particular patient needs preventive antibiotics. People who present at the office with swollen faces, teeth tender to light pressure, swollen gums or tongue, or bleeding and pus around a tooth are generally already infected. They should expect to be given prophylactic (preventive) antibiotics after an extraction.

Patients may develop infections after an extraction even if they were not infected before the extraction. This is a common complication and is due to the fact that the mouth is teeming with bacteria and cannot be sterilized prior to the extraction. (They are NOT due to any error on the part of the dentist!) The first sign of an infection after an extraction is often renewed bleeding after 48 hours. The bleeding is not generally severe, but it is an indication that the patient should return to the dentist's office for evaluation and possibly a prescription for antibiotics. Other signs of infection include renewed swelling around the

extraction site and surrounding parts of the face, as well as increased pain after 48 hours. **Signs of infection two days after an extraction should be attended to as soon as possible** (Fig.13,14).

Some dentists will give a patient an antibiotic and send them home for several days to allow the infection to clear before attempting the extraction. The reason for this is because the local anesthesia does not work as well in acid environments and it may take a lot of shots to get the patient numb. However, if the dentist gives enough anesthesia, it is possible to extract a tooth under such circumstances.

It is NOT necessary to take antibiotics after every extraction. A simple extraction in a clean, uninfected mouth generally does not require prophylactic antibiotics.

Whenever the extraction requires the cutting of any tissue it is generally a good idea to give prophylactic antibiotics, and the patient SHOULD fill the prescription and take the drug faithfully, or he may suffer an extended convalescence.

### 3. Dry Sockets

A **dry socket**, while not potentially life threatening like bleeding or infections, is one of the most painful, common, debilitating and dreaded post extraction problems encountered in dentistry. Patients often state that they felt fine for a day or two after the extraction, but then the extraction site began to become painful. They may also say they have a bad taste in their mouth. Dry sockets are much more common following the extraction of lower teeth than they are after extraction of upper teeth. They can happen after even the simplest of extractions. If you get a dry socket, it is not (necessarily) your fault. Nor is it the fault of the dentist. They are a quirk of nature. You may THINK you are going to die. You won't!

Patients who are more likely to get a dry socket are those who **smoke** during the first 48 hours after the extraction, women on **birth control pills**, and persons who tend to constantly **grind and clench** their teeth.

#### What is a dry socket?

A dry socket is a condition in which the blood clot that forms in the extraction site becomes detached from the walls of the socket, or dissolves away leaving the bare bone exposed to saliva and the foods you eat. The bone becomes inflamed due to bacteria and contaminants in the saliva, and this inflammation is persistent and painful. The socket begins to emanate a bad odor. The pain is "deep pain". That is, it comes from tissues buried deep in the body, and your brain has no experience of pain from these regions. When the brain receives pain signals through these unusual channels, it is unsure of the exact location of the pain, so it tells you that the pain is coming from areas on that side of your face and head that are far removed from the actual source. Pain like this is called referred pain. It seems to shoot up the side of the head, or makes your eye ache.

## Can a dry socket be prevented?

- Dry sockets can be prevented if the patient opts to spend more money on one of the three forms of **socket preservation**. Click on the toothless skeleton to read how the dentist can prevent dry sockets and keep your skeleton from looking like the one in the image.
- Studies have shown that in-office pre-operative and post-operative rinsing with 0.12% chlorhexidine (Peridex) reduces the incidence of dry sockets. It is a good idea for the patient to be given a prescription for a bottle of chlorhexidine to be used for rinsing three times a day for several days starting 24 hours after the extraction.
- Removing third molars within the ideal window of time when the roots are 1/2 to 2/3 developed, about age 17 for boys and 16 for girls, reduces the likelihood of dry socket.
- Treating the socket immediately post-operatively with a small amount of tetracycline on a piece of Gelfoam has been shown to reduce the likelihood of dry socket.
- Patient should maintain good oral hygiene and follow post-op instructions.

## How are dry sockets treated?

Left alone, dry sockets will always heal. It may take a month or more, and the pain is persistent for the entire period of healing. Antibiotics are not useful in curing a dry socket, and the usual pain medications are not very effective. It is better to go back to the dentist who extracted the tooth and let him or her "pack" the socket. This is a procedure done (usually) without anesthesia even though it can be painful. It does not take too long, and the pain relief is almost complete, beginning a few minutes after the socket is packed. The first packing will provide relief for 12 to 24 hours. As you return to the dentist and the old packing is removed, the socket is washed out and a new packing is placed. Each succeeding packing debrides (cleans) the socket and renews the pain relief. A second packing may last 24 to 48 hours, and succeeding packings may last longer still. Within three packings, or sometimes more depending on the severity of the dry socket, the wound begins to heal from the bottom up and can be left empty to heal without pain. Some unfortunate people seem to have more prolonged dry sockets, but they all heal eventually.

## 4. Broken Jaws

Yes, it does occasionally happen. The fracture of a lower jaw is unusual, principally because dentists who extract teeth routinely do not place great force on any instrument to remove a tooth. Teeth are generally "finessed out" with a minimum of pressure applied to the jaw through the surgical instruments. There are, however, some situations in which a dentist can look at the x-ray and see that the jawbone that surrounds the tooth is much more fragile than is usually the case,

and will usually warn the patient that fracture of the jaw is a possibility. People are not like cars, every one identical. Everyone is unique and presents unique circumstances under which the dentist must labor. **The chances that the removal of any given tooth will result in a fractured lower jaw run about the same for any dentist who attempts the extraction.** That particular patient is usually more prone than other people to a broken jaw due to **any** traumatic incident such as a traffic accident or a blow to the jaw during a sporting event. Unfortunate, but true, and a fact of life for any dentist who extracts teeth.

## 5. Sinus perforation

The image to the right is a detail from a panoramic film. The roots of the upper back teeth are always in close approximation to the maxillary sinus. Since everyone is built differently, the roots of the teeth may actually appear to be inside the sinus (fig.16). There is always a thin wall of bone between the root and the sinus, but it can be very thin indeed. Most of the time, the bone remains intact, but upon occasion, a piece of the bone separating the root from the sinus may break off and be removed with the tooth. This creates a direct connection between the sinus and the mouth! That means that you would be unable to suck on a straw, because air would rush into your mouth from your nose through the socket.

Sometimes a sinus perforation will go unnoticed by the dentist or the patient. If the perforation is small, the only symptom could be a nosebleed. If this happens, call the dentist so he can prescribe the proper drugs so that healing can proceed normally

When a sinus perforation occurs, the dentist will prescribe an antibiotic to prevent infection and a decongestant to keep the sinuses clear during healing. The patient bites on his gauze as is usual after any extraction, and a clot will form in the socket as usual. If nothing disturbs the clot, it will organize during healing and close the perforation. Dry sockets rarely happen after extraction of upper teeth unless the patient smokes.

It is **IMPERATIVE**, however that the patient do **NOTHING** that could disturb the clot.

Do not suck on anything for at least a week. This puts pressure on the clot and could dislodge it into the mouth.

Do not smoke...the longer you wait the better. This will dissolve the clot, or could even suck it out of the socket.

Do not blow up balloons or anything else. This puts pressure on the clot and could dislodge it into the sinus.

Avoid sneezing. This explosive event will definitely dislodge the clot.

In the case of very large perforations, or in case the clot dislodges and a perforation between the sinus and the mouth remains after healing, It may be necessary to



perform a further surgical procedure in order to draw a flap of gum tissue over the perforation to close it permanently.

6. **Sequestrii** (Broken bone fragments that come out weeks after the extraction, but are often mistaken for pieces of tooth.)

Extraction of a tooth requires that the bone surrounding it be expanded, or sometimes even fractured to allow the tooth to slip out of the socket. Most of the time, these fractures are of the type known as "greenstick" fractures which means they are only partial fractures immediately around the top of the socket leaving the bone fragments still attached to the main body of the bony structure beneath. In some instances, these greenstick fractures coalesce to release a bone fragment completely from the underlying bony structure. Even when this happens, the bone fragments tend to heal and reattach to the main body of the bone during healing.

In the oral cavity, however, the presence of oral bacteria, as well as noxious chemicals from the foods we eat and cigarettes we smoke can cause the healing to cease. This is what causes dry sockets. Bony fragments that do not heal properly often lose their blood supply and become "necrotic" (dead tissue). Thus, the body begins the process of ejecting them from the healing socket, a process known as sequestration. The process can be painful, and sometimes requires the dentist to reenter the socket to remove the **sequestrum**. When the sequestrum comes out on its own, the patient often mistakes this piece of bone for a piece of tooth that the dentist left in the socket.

Sequestrii are a normal complication of extractions. They are often unavoidable, and undetectable at the time of the extraction. They are not considered to be a mistake the dentist made. Once the sequestrum is gone, the healing resumes, the pain subsides and all is well.

7. **Retained roots** (Pieces of tooth left in the bone by the dentist)

A large majority of teeth are removed in one piece when they are extracted by the dentist. However, many do break leaving one or more fragments of varying size in the bone. Most of the time, these root fragments are easily "luxated" using a sharp instrument which is forced down between the root and the surrounding bone. On rare occasions, the root fragment may be too firmly attached to the bone (ankylosis), at too odd an angle, or too close to a vital structure like the sinuses or mandibular nerve to remove in this manner. **In most instances, it is NOT essential to remove every root fragment that is left in the bone!!** Retained root tips will generally simply heal in place and rarely cause a problem to the patient after healing. When confronted with this situation the dentist must weigh the relative benefits of removal of the root tip versus the complications that the removal will cause the patient. Often, the removal of the offending root fragment necessitates quite a bit of drilling of bone and heavy duty prying, not to mention quite a bit of time. This always results in a much greater degree of pain for the

patient during healing. It also increases the likelihood of a dry socket, which is a painful result that most people would rather do without. On the other hand, in most cases, leaving the root tip in place causes much less damage and discomfort to the patient.

In the relatively rare instances in which the root tip does cause a future problem, (usually years after the initial extraction) it is generally quite easy to remove at that time. This is because, in forming an abscess, the body has already "rejected" it, and has loosened it from the surrounding bone. The surgeon will have no difficulty locating and removing it at that time.

## 8. Osteonecrosis of the jawbone

**Osteonecrosis** of the jawbone (ONJ) is a disease resulting from the temporary or permanent loss of the blood supply to the bone. Without a blood supply, the bone dies (the term "osteo" means "bone"; the term "necrosis" means "death"). When this happens, the dead bone becomes exposed to the oral environment. Exposed necrotic bone is not an uncommon complication after extractions of teeth, even in healthy patients who have never had radiation therapy or bisphosphonate drug therapy. Simple cases involve only the bone immediately surrounding the extraction socket, and usually, the necrotic bone will heal over spontaneously with time. Unfortunately, more serious cases of ONJ happen to people who are taking bisphosphonates for osteoporosis or as part of a chemotherapeutic regime for some forms of cancer. Serious ONJ also happens to patients who have had radiation therapy to the head or neck for the treatment of cancers.

# Mouth Disorders

Your mouth is one of the most important parts of your body. Any problem that affects your mouth can make it hard to eat, drink or even smile.

Some common mouth problems include

- Cold sores - painful sores on the lips and around the mouth, caused by a virus
- Canker sores - painful sores in the mouth, caused by bacteria or viruses
- Thrush - a yeast infection that causes white patches in your mouth
- Leukoplakia - white patches of excess cell growth on the cheeks, gums or tongue, common in smokers
- Dry mouth - a lack of enough saliva, caused by some medicines and certain diseases
- Gum or tooth problems

Treatment for mouth disorders varies, depending on the problem. Keeping a clean mouth by brushing and flossing often is important.

# Dry Mouth

Some cancer treatments and medicines can cause dry mouth.

Symptoms you may have:

- Your saliva will be thick and stringy.
- You may have cuts or cracks in your lips or at the corners of your mouth.
- Your dentures may no longer fit well. This may cause sores on your gums.
- You will be thirsty.
- It may be hard to swallow and talk.
- You may lose your sense of taste.
- Your tongue and mouth may feel sore.

You may get mouth sores, mouth pain, cavities (dental caries), or gum disease.

## Take Care of Your Mouth

Brush your teeth and gums 2 or 3 times a day for 2 to 3 minutes each time. Use a toothbrush with soft bristles.

- When you brush, rinse your brush in hot water every 30 seconds to keep the bristles soft.
- Let your toothbrush air dry between brushings.
- Choose toothpaste with care.

If toothpaste makes your mouth sore, brush with a solution of 1 teaspoon of salt mixed with 4 cups of water. Pour a small amount into a clean cup to dip your toothbrush into each time you brush. Use toothpaste with fluoride.

Floss gently 1 time a day. Rinse your mouth 5 or 6 times a day. Use any of these solutions when you rinse:

- 1 teaspoon of salt in 4 cups of water
- 1 teaspoon of baking soda in 1 cup (8 ounces) of water
- ½ teaspoon salt and 2 tablespoons baking soda in 4 cups of water

Avoid rinses that have alcohol in them. You may use an antibacterial rinse 2 to 4 times a day for gum disease. Rinse for 1 to 2 minutes each time.

Do not eat foods or drinks that have a lot of sugar in them. They may cause tooth decay. Use lip care products to keep your lips from drying out and cracking. Sip water to ease mouth dryness.

Eating sugar-free candy or chewing sugar-free gum may also help.

Talk with your dentist about:

- Solutions to replace minerals in your teeth
- Saliva substitutes
- Drugs that help your salivary glands make more saliva

**Diet.** You need to eat enough protein and calories from other foods to keep your weight up. Tips to make eating easier:

- Choose foods that you like.
- Serve foods with gravy, broths, or sauces to make them easier to chew and swallow.
- Eat small meals, and eat more often.
- Cut your food into small pieces to make it easier to chew.
- Ask your doctor or dentist if artificial saliva might help you.

Drink at least 8 to 10 glasses of liquid each day (not including coffee, tea, or other drinks that have caffeine).

- Drink liquids with your meals.
- Sip cool drinks during the day.
- Keep a glass of water next to your bed at night. Drink when you get up to use the bathroom or other times you wake up.

Ask doctor about liquid food supplements. These can help you meet your energy needs.

Avoid alcoholic drinks. They will bother your throat. Also avoid foods that are very spicy, have a lot of acid or are very hot or cold.

If pills are hard to swallow, try crushing them with some ice cream or another soft food. Ask your doctor if it is okay to crush your pills. Some pills do not work if they are crushed.

## **Toothaches**

Toothache is pain in or around a tooth.

Seek medical care if:

- You have a severe toothache
- You have a toothache that lasts longer than a day or two
- You have fever, earache, or pain upon opening the mouth wide

The dentist is an appropriate person to see for most causes of toothaches. However, if the problem is referred pain from another location, you may need to see your primary health care provider.

The dentist will examine patient. The physical examination may include an examination of the mouth, teeth, gums, tongue, throat, ears, nose, and neck. You (patient) may need dental x-rays. The dentist may recommend other tests, depending on the suspected cause.

The dentist will ask questions about medical history and symptoms, including:

- When did the pain start?
- How severe is the pain?
- Where is the pain located?
  - Does it involve the jaw or ears?
  - Does it radiate to other parts of the body, such as the neck, shoulder, or arm?
- What makes it worse?
  - Is it worse after cold foods or liquids?
  - Is it worse after sweet foods or liquids?
  - Is it worse after chewing?
  - Is it worse after drinking?
  - Is it worse when you touch the area?
  - Is it worse after physical exertion?
- Does the pain wake you up at night?
- What makes it better?
  - Is it better after you use medications? (Which ones?)
  - Is it better after you use a heating pad?
  - Is it better after you rest?
- What other symptoms do you have?
  - Fever ?
  - Nausea?
  - Sweating?
  - Indigestion?
  - Chest pain?
  - Bleeding?
- What medications do you take?
- Have you been injured?
- When was the last dental checkup?
- Have you had previous dental problems?

**Considerations.** A toothache is generally the result of dental cavities (tooth decay) or sometimes an infection. Tooth decay is often caused by poor dental hygiene, although the tendency to get tooth decay is partly inherited.

Sometimes, pain that's felt in the tooth is actually due to pain in other parts of the body. This is called referred pain or radiating pain. For example, an earache may sometimes cause tooth pain.

**Causes:** abscessed tooth; earache; injury to the jaw or mouth; heart attack (can include jaw pain, neck pain, or toothache); sinusitis; tooth decay.

**Home Care.** Over-the-counter pain medications may be used while waiting to see the dentist or primary health care provider.

For toothaches caused by a tooth abscess, the dentist may recommend antibiotic therapy and other treatments, like root canal.

To prevent tooth decay, use good oral hygiene. A low sugar diet is recommended along with regular flossing, brushing with fluoride toothpaste, and regular professional cleaning. Sealants and fluoride applications by the dentist are important for preventing tooth decay.

Treatment may involve fillings, tooth removal, or a root canal, if the problem is severe. If there is a fever or swelling of the jaw, an antibiotic will usually be prescribed.

### **Taking Care of Your Teeth and Mouth**

No matter how old you are, you need to take care of your teeth and mouth. When your mouth is healthy, you can eat the foods you need for good nutrition. You will also feel better about smiling, talking, and laughing. Teeth are meant to last a lifetime. By taking good care of your teeth and gums, you can protect them for many years.

#### **Tooth Decay**

Teeth are covered in a hard, outer coating called enamel. Every day, a thin film of bacteria builds up on your teeth. Over time, the bacteria can cause holes in the enamel. These holes are called cavities. Brushing and flossing your teeth can protect you from decay, but once a cavity happens, a dentist has to fix it.

You can protect your teeth from decay by using fluoride toothpaste. If you have a lot of tooth decay, your dentist or dental hygienist may give you a fluoride treatment during an office visit. Or, the dentist may tell you to use a fluoride gel or mouth rinse at home.

#### **Gum Diseases**

Gum disease begins when plaque builds up along and under the gum line. This plaque causes infections that hurt the gum and bone that hold teeth in place. Sometimes gum disease makes your gums tender and more likely to bleed. This problem, called gingivitis, can often be fixed by daily brushing and flossing.

Other gum diseases need to be treated by a dentist. If not treated, these infections can ruin the bones, gums, and other tissues that support your teeth. Over time, your teeth may have to be removed.

### **To prevent gum disease:**

- Brush your teeth twice a day with fluoride toothpaste.
- Floss once a day.
- Visit your dentist regularly for a checkup and cleaning.
- Eat a well-balanced diet.
- Quit smoking. Smoking increases your risk for gum disease.

### **Cleaning Your Teeth and Gums**

There is a right way to brush and floss your teeth. Every day:

- Gently brush your teeth on all sides with a soft-bristle brush and fluoride toothpaste.
- Use small circular motions and short back-and-forth strokes.
- Take the time to brush carefully and gently along the gum line.
- Lightly brush your tongue to help keep your mouth clean.

### **How to Floss**

Hold floss as shown.

Use floss between upper teeth.

Use floss between lower teeth.

You also need to clean around your teeth with dental floss every day. Careful flossing will take off plaque and leftover food that a toothbrush can't reach. Be sure to rinse after you floss.

See your dentist if brushing or flossing causes your gums to bleed or hurts your mouth. If you have trouble flossing, a floss holder may help. Ask your dentist to show you the right way to floss.

People with arthritis or other conditions that limit hand motion may find it hard to hold a toothbrush. Some helpful ideas are:

- Slide a bicycle grip or foam tube over the handle of the toothbrush.
- Buy a toothbrush with a larger handle.
- Attach the toothbrush handle to your hand with a wide elastic band.

### **Dentures**

Sometimes, dentures (false teeth) are needed to replace badly damaged teeth.

Dentures may feel strange at first. In the beginning, your dentist may want to see you often to make sure the dentures fit. Over time, your mouth will change and

your dentures may need to be adjusted or replaced. Be sure to let your dentist handle these adjustments.

When you are learning to eat with dentures, it may be easier if you:

- Start with soft, non-sticky food.
- Cut your food into small pieces.
- Chew slowly using both sides of your mouth.

Be careful when wearing dentures because they may make it harder for you to feel hot foods and liquids. Also, you may not notice things like bones in your mouth.

Keep your dentures clean and free from food that can cause stains, bad breath, or swollen gums. Brush them every day with a denture care product. Take your dentures out of your mouth at night and put them in water or a denture cleansing liquid. Partial dentures are used to fill in one or more missing teeth. Take care of them in the same way as dentures.

## Oral Cancer

Oral cancer most often happens in people over age 40. Treatment works best before the disease spreads. Pain is not usually an early symptom of the disease. A dental check-up is a good time for your dentist to look for signs of oral cancer. Even if you have lost all your natural teeth, you should still see your dentist for regular oral cancer exams.

You can lower your risk of getting oral cancer in a few ways:

- Do not use tobacco products – cigarettes, chewing tobacco, snuff, pipes, or cigars.
- If you drink alcohol, do so only in moderation.
- Use lip balm with sunscreen.

Finding Low Cost Dental Care

## Breath odor

Breath odor is the scent of the air you breathe out of your mouth. Unpleasant, distinctive, or offensive breath odor is commonly called bad breath.

### When to Contact a Medical Professional

- Breath odor persists and there is not an obvious cause (such as smoking or eating odor-causing foods).
- You have breath odor and signs of a respiratory infection, such as fever, cough, or face pain with discharge from the nose

Doctor will take a medical history and perform a physical examination.



Doctor give the following medical history questions:

- Is there a specific odor?
- Is there a fishy smell?
- Does the breath smell like ammonia or urine?
- Does the breath smell like fruit or is there a sweet-chemical smell?
- Does the breath smell like feces?
- Does the breath smell like alcohol?
- Have you recently eaten a spicy meal, garlic, cabbage, or other "odorous" food?
- Do you take vitamin supplements?
- Do you smoke?
- Does good oral hygiene improve the odor?
- What home care measures have you tried? How effective are they?
- Is there a recent sore throat, sinus infection, tooth abscess, or other illness?
- What other symptoms do you have?

**Considerations.** Some disorders will produce specific, characteristic odors to the breath.

Bad breath related to poor oral hygiene is most common and caused by release of sulphur compounds by bacteria in the mouth.

A fruity odor to the breath occurs as the body attempts to get rid of excess acetone through the breathing. This is a sign of ketoacidosis, which may occur in diabetes. It is a potentially life-threatening condition.

Breath that smells like feces can occur with prolonged vomiting, especially when there is a bowel obstruction. It may also occur temporarily if a person has a tube placed through the nose or mouth to the stomach to drain the stomach contents (nasogastric tube) in place.

The breath may have an ammonia-like odor (also described as urine-like or "fishy") in people with chronic kidney failure.

If previously normal breath turns into halitosis, **causes** could include:

- Abscessed tooth
- Alcoholism
- Cavities
- Dentures
- Drugs
  - Paraldehyde
  - Triamterene and inhaled anesthetics
  - Insulin - injection
- Food or beverages consumed (such as cabbage, garlic, raw onions, or coffee)

- Foreign body in the nose (usually in children)
  - Often (but not always) there is a white, yellowish, or bloody discharge from one nostril
- Gum disease (gingivitis, gingivostomatitis)
- Impacted tooth
- Lung infection
- Poor dental hygiene
- Sinusitis
- Throat infection
- Tobacco smoking
- Vitamin supplements (especially in large doses)

**Diseases that may be associated with breath odor** (not presented in order of likelihood - some are extremely unlikely):

- acute necrotizing ulcerative gingivitis;
- acute necrotizing ulcerative mucositis;
- acute renal failure;
- bowel obstruction (can cause breath to smell like feces);
- bronchiectasis;
- chronic renal failure (can cause breath to smell like ammonia);
- diabetes (fruity or sweet chemical smell with ketoacidosis);
- esophageal cancer;
- gastric carcinoma;
- gastrojejunal fistula (fruity-smelling breath);
- hepatic encephalopathy;
- diabetic ketoacidosis;
- lung abscess;
- ozena, or atrophic rhinitis;
- periodontal disease;
- Zenker's diverticulum.

**Home Care.** Fresh parsley or a strong mint are often effective ways to fight temporary bad breath. Avoid smoking. Otherwise, follow prescribed therapy to treat the underlying cause.

The physical examination will include a thorough examination of the mouth and the nose. A throat culture may be taken if you have a sore throat or mouth sores.

In rare cases, diagnostic tests that may be performed include:

- Blood tests to screen for diabetes or kidney failure
- Endoscopy (EGD)
- X-ray of the abdomen
- X-ray of the chest

Antibiotics may be prescribed for some conditions. For an object in the nose, the doctor will use an instrument to remove it.

# Facial swelling

## Alternative Names

Puffy face; Swelling of the face; Moon face; Facial edema

Facial swelling is the build-up of fluid in the tissues of the face. Swelling may also affect the neck and upper arms.

**Call the doctor** if you have:

- Sudden, painful, or severe facial swelling
- Facial swelling that lasts a while, particularly if it is getting worse over time
- Difficulty breathing
- Fever, tenderness, or redness, which suggests infection

## What to Expect at Office Visit

Emergency treatment is needed if facial swelling is caused by burns or if you have breathing problems.

The health care team will ask questions about your medical and personal history to determine treatment or if any medical tests are needed. Questions may include:

- How long has the facial swelling lasted?
- When did it begin?
- What makes it worse?
- What makes it better?
- Have you come into contact with something you might be allergic to?
- What medications are you taking?
- Have you recently injured your face?
- Have you had a recent medical test or surgery?
- What other symptoms do you have? For example:
  - Facial pain
  - Sneezing
  - Difficulty breathing
  - Hives or rash
  - Eye redness
  - Fever

**Considerations.** If the facial swelling is mild, it may be hard to detect. To assist the health care provider in diagnosing the cause, it is important to note the following:

- Pain, and where it hurts
- How long the swelling has lasted
- What makes it better or worse
- If you have other symptoms

**Causes:** allergic reaction (such as allergic rhinitis, hay fever, or a bee sting); angioedema; blood transfusion reaction; cellulitis; conjunctivitis (inflammation of the eye); drug reactions, including those due to aspirin, penicillin, sulfa, glucocorticoids, and others; head, nose, or jaw surgery; injury or trauma to the face (such as a burn); malnutrition (when severe); obesity; salivary gland disorders; sinusitis; sty with swelling around the infected eye; tooth abscess.

**Home Care.** Apply cold compresses to reduce swelling from an injury. Raise the head of the bed (or use extra pillows) to help reduce facial swelling.

## Dental cavities

### Alternative Names

Caries; Tooth decay; Cavities – tooth

### Development of a Caries Lesion

Dental Caries is a disease in which minerals of the tooth are dissolved into surrounding bacterial plaques and to saliva (fig.17). A caries process going on for some time may result in a Caries Lesion. It is sometimes called White Spot Lesions, Initial Caries or Incipient Caries. If the process is not halted, the enamel surface may break, resulting in a Cavity.

**Dental caries** is a progressive condition characterized by demineralization and destruction of enamel and dentin.

A major factor in the causation of dental caries is plaque, a film that develops on the surface of teeth, made up largely of bacteria. Some of these bacteria, in particular *Streptococcus mutans*, efficiently metabolize carbohydrates from sugars in the diet to produce lactic and other acids, which demineralize the tooth surface. [Duckworth, 1993]

**Caries sites.** Caries is a process that attacks enamel, cementum and dentine, gradually destroying the tooth. The enamel is gradually broken down underneath the still-intact surface until the surface collapses and an open cavity is formed.

## **The role of pH in tooth decay**

pH is a measure of the acidity or alkalinity of a solution where 1 is highly acidic and 14 is highly alkaline. If the plaque pH falls below about 5.5 (e.g. when plaque bacteria produce acid), the tooth enamel begins to dissolve (demineralize). Persistent acid conditions from plaque metabolism will lead to the formation of a carious lesion. Under normal oral conditions closer to pH 7 (neutral), such as periods between meals, enamel tends to re-acquire mineral ions (remineralize) and minor carious lesions may be repaired.

Tooth decay occurs in five stages: [Collins, 1992; Clarkson, 1991]

1. Acid from plaque dissolves some of the hydroxyapatite mineral out of the surface of the enamel. Demineralization can then extend down towards the enamel-dentine junction whilst the surface remains intact. At this time, the appearance of the lesion resembles a white spot. The 'white spot' lesion can undergo several changes. It may become a 'brown spot' lesion, an arrested lesion, or a partially remineralized lesion. It may occasionally even disappear as a 'caries reversal'.
2. However, it may also progress to a cavity. As the decay spreads through the enamel, it gradually leaves the surface less well supported. Eventually, the enamel caves in, leaving a break in the surface.
3. If the lesion is left untreated, the decay may enter the dentin.
4. If it remains untreated, the decay may continue to spread inwards, down the dentinal tubules, until it reaches the pulp.
5. If the decay spreads down into the pulp, an apical abscess may form, which can be extremely painful.

**Call the dentist** if you have a toothache.

Make an appointment with your dentist for a routine cleaning and examination if you have not had one in the last 6 months to 1 year.

**Causes.** Tooth decay is one of the most common of all disorders, second only to the common cold. It usually occurs in children and young adults but can affect any person. It is a common cause of tooth loss in younger people.

Bacteria are normally present in the mouth. The bacteria convert all foods -- especially sugar and starch -- into acids. Bacteria, acid, food debris, and saliva combine in the mouth to form a sticky substance called plaque that adheres to the teeth. It is most prominent on the back molars, just above the gum line on all teeth, and at the edges of fillings. Plaque that is not removed from the teeth mineralizes

into tartar. Plaque and tartar irritate the gums, resulting in gingivitis and ultimately periodontitis.

Plaque begins to build up on teeth within 20 minutes after eating (the time when most bacterial activity occurs). If this plaque is not removed thoroughly and routinely, tooth decay will not only begin, but flourish.

The acids in plaque dissolve the enamel surface of the tooth and create holes in the tooth (cavities). Cavities (Fig.17) are usually painless until they grow very large and affect nerves or cause a tooth fracture. If left untreated, a tooth abscess can develop. Untreated tooth decay also destroys the internal structures of the tooth (pulp) and ultimately causes the loss of the tooth.

Carbohydrates (sugars and starches) increase the risk of tooth decay. Sticky foods are more harmful than nonsticky foods because they remain on the surface of the teeth. Frequent snacking increases the time that acids are in contact with the surface of the tooth.

**Symptoms.** There may be no symptoms. If symptoms occur, they may include:

- Tooth pain or achy feeling, particularly after sweet, hot, or cold foods and drinks
- Visible pits or holes in the teeth

**Exams and Tests.** Most cavities are discovered in the early stages during routine checkups. The surface of the tooth may be soft when probed with a sharp instrument. Pain may not be present until the advanced stages of tooth decay. Dental x-rays may show some cavities before they are visible to the eye.

**Treatment** can help prevent tooth damage from leading to cavities.

Treatment may involve: fillings, crowns, root canals.

When a **tooth is badly injured**, or when you struggle with an extremely **deep tooth decay**, you might need to undergo a **root canal treatment**, because the pulp of the tooth is much damaged.

Imagine the pulp of the tooth as a collection of tissues which can be found right at the center of a tooth.

If the exterior of a tooth is being broken or chipped for example, different microorganisms and bacteria will find an entrance gate through there.

Thus, the pulp of the tooth can easily get infected, and this can easily bring about the tooth abscess (when pus is enclosed within the tissues of the jaw).

The tooth abscess can be extremely painful, a “pulsating” feeling from within. Some other symptoms of a tooth abscess include a bitter taste in the mouth, bad breath condition, and swollen lymph nodes that can also be extremely painful.

Patients struggling with tooth abscess can barely drink or eat because of the sharp, intermittent feelings of pain.

Quite a few decades ago, people who were struggling with bad teeth were prescribed a few antibiotics, and they were also told to rinse their mouth frequently with a mixture of water and salt. In those days, dental extraction was the only way to fix such a problem, and doctors could not actually save the tooth.

However, since technology, science and medicine have made huge leaps forward, today they can save even a very badly damaged tooth through a root canal treatment.

For such a treatment, the dentist will start by making an opening in the posterior of the badly damaged tooth. Next, the affected pulp is going to be removed, and the area will be thoroughly cleansed and disinfected.

In case more visits to the dentist are needed, the doctor will place a temporary filling. In the last stages of the root canal treatment the area will be filled permanently using tapered rubber material. Then, the tooth is going to be covered with a dental crown, and thus the damaged tooth is saved from extraction.

Dentists fill teeth by removing the decayed tooth material with a drill and replacing it with a material such as silver alloy, gold, porcelain, or composite resin. Porcelain and composite resin more closely match the natural tooth appearance, and may be preferred for front teeth. Many dentists consider silver amalgam (alloy) and gold to be stronger, and these materials are often used on back teeth. There is a trend to use high strength composite resin in the back teeth as well.

Crowns or "caps" are used if tooth decay is extensive and there is limited tooth structure, which may cause weakened teeth. Large fillings and weak teeth increase the risk of the tooth breaking. The decayed or weakened area is removed and repaired. A crown is fitted over the remainder of the tooth. Crowns are often made of gold, porcelain, or porcelain attached to metal.

A root canal is recommended if the nerve in a tooth dies from decay or injury. The center of the tooth, including the nerve and blood vessel tissue (pulp), is removed along with decayed portions of the tooth. The roots are filled with a sealing material. The tooth is filled, and a crown may be placed over the tooth if needed.

## **Outlook Prognosis**

Treatment often saves the tooth. Early treatment is less painful and less expensive than treatment of extensive decay.

You may need numbing medicine (lidocaine), nitrous oxide (laughing gas), or other prescription medications to relieve pain during or after drilling or dental work.

Nitrous oxide with Novocaine may be preferred if you are afraid of dental treatments.

**Possible Complications:** discomfort or pain; fractured tooth; inability to bite down on tooth; tooth abscess; tooth sensitivity.

**Prevention.** Oral hygiene is necessary to prevent cavities. This consists of regular professional cleaning (every 6 months), brushing at least twice a day, and flossing at least daily. X-rays may be taken yearly to detect possible cavity development in high risk areas of the mouth.

Chewy, sticky foods (such as dried fruit or candy) are best if eaten as part of a meal rather than as a snack. If possible, brush the teeth or rinse the mouth with water after eating these foods. Minimize snacking, which creates a constant supply of acid in the mouth. Avoid constant sipping of sugary drinks or frequent sucking on candy and mints.

Dental sealants can prevent some cavities. Sealants are thin plastic-like coatings applied to the chewing surfaces of the molars. This coating prevents the accumulation of plaque in the deep grooves on these vulnerable surfaces. Sealants are usually applied on the teeth of children, shortly after the molars erupt. Older people may also benefit from the use of tooth sealants.

Fluoride is often recommended to protect against dental caries. It has been demonstrated that people who ingest fluoride in their drinking water or by fluoride supplements have fewer dental caries. Fluoride ingested when the teeth are developing is incorporated into the structure of the enamel and protects it against the action of acids.

Topical fluoride is also recommended to protect the surface of the teeth. This may include a fluoride toothpaste or mouthwash. Many dentists include application of topical fluoride solutions (applied to a localized area of the teeth) as part of routine visits.

## Gingivitis

Gingivitis is inflammation of the gums (gingiva).



Bacteria in plaque around the teeth release enzymes (collagenases) that can damage and erode the gum tissues. The infected gums swell, bleed easily, recede, and loosen from the teeth. Tooth loss is caused more frequently by gum disease than tooth decay.

**Go to the dentist** if symptoms of gingivitis are present, especially if you have not had a routine cleaning and examination in the last 6 months.

### **What is Periodontal disease?**

In order to understand gum disease, you must first understand the way the teeth and supporting structures are built (fig.19). The part of the tooth you can see in your mouth is called the **crow**n of the tooth. It is held in the mouth by the root which is embedded in your jaw bone. It is attached to the bone by way of a thin "stocking" called the **periodontal ligament**. The bone is, of course covered by the gums which are called the **gingiva**. The gingiva attach to the teeth slightly below the highest level they reach on the tooth.

The topmost part of the gingiva is called the **gingival crest**, and the inside of the little pocket between the gingival crest and the bottom of the pocket is called the gingival **sulcus**. All the bony and soft tissue that supports the tooth is called the periodontium and when this organ becomes sick, we say the patient has Periodontal disease.

**Causes.** Gingivitis is a form of periodontal disease. Periodontal disease involves inflammation and infection that destroys the tissues that support the teeth, including the gums, the periodontal ligaments, and the tooth sockets (alveolar bone).

Gingivitis is due to the long-term effects of plaque deposits. Plaque is a sticky material made of bacteria, mucus, and food debris that develops on the exposed parts of the teeth. It is a major cause of tooth decay. If you do not remove plaque, it turns into a hard deposit called tartar that becomes trapped at the base of the tooth. Plaque and tartar irritate and inflame the gums. Bacteria and the toxins they produce cause the gums to become infected, swollen, and tender.

Injury to the gums from any cause, including overly vigorous brushing or flossing of the teeth, can cause gingivitis.

The following raise your risk for developing gingivitis:

- General illness
- Poor dental hygiene
- Pregnancy (hormonal changes increase the sensitivity of the gums)
- Uncontrolled diabetes

Misaligned teeth, rough edges of fillings, and ill-fitting or unclean mouth appliances (such as braces, dentures, bridges, and crowns) can irritate the gums and increase the risk of gingivitis.

Medications such as phenytoin and birth control pills, and heavy metals such as lead and bismuth are also associated with gingivitis.

Many people have gingivitis to a varying degree. It usually develops during puberty or early adulthood due to hormonal changes and may persist or recur frequently, depending on the health of your teeth and gums.

**Symptoms:** bleeding gums (blood on toothbrush even with gentle brushing of the teeth); bright red or red-purple appearance to gums; gums that are tender when touched, but otherwise painless; mouth sores; swollen gums; shiny appearance to gums.

### **Exams and Tests**

The dentist will examine mouth and teeth and look for soft, swollen, red-purple gums. Deposits of plaque and tartar may be seen at the base of the teeth. The gums are usually painless or mildly tender.

No further testing is usually necessary, although dental x-rays and dental bone measurements may be done to determine whether the inflammation has spread to the supporting structures of the teeth.

### **Treatment**

The goal is to reduce inflammation. The teeth are cleaned thoroughly by the dentist or dental hygienist. This may involve various instruments or devices to loosen and remove deposits from the teeth.

Careful oral hygiene is necessary after professional tooth cleaning. The dentist or hygienist will show you how to brush and floss. Professional tooth cleaning in addition to brushing and flossing may be recommended twice per year or more frequently for severe cases. Antibacterial mouth rinses or other aids may be recommended in addition to frequent, careful, tooth brushing and flossing.

Repair of misaligned teeth or replacement of dental and orthodontic appliances may be recommended. Any other related illnesses or conditions should be treated.

### **Outlook Prognosis**

The removal of plaque from inflamed gums may be uncomfortable. Bleeding and tenderness of the gums should lessen within 1 or 2 weeks after professional cleaning and careful oral hygiene. Warm salt water or antibacterial rinses can

reduce the puffiness. Over-the-counter anti-inflammatory medications will ease any discomfort from a rigorous cleaning.

Healthy gums are pink and firm in appearance. Strict oral hygiene must be maintained for your whole life or gingivitis will recur.

**Possible Complications:** recurrence of gingivitis; periodontitis; infection or abscess of the gingiva or the jaw bones; trench mouth.

## **Prevention**

Good oral hygiene is the best prevention against gingivitis because it removes the plaque that causes the disorder. The teeth should be brushed at least twice daily and flossed gently at least once per day. For people who are prone to gingivitis, brushing and flossing may be recommended after every meal and at bedtime. Consult the dentist or dental hygienist for instructions on proper brushing and flossing techniques.

Special appliances or tools may be recommended by the dentist for use by people who are particularly prone to plaque deposits. The use of supplements does not replace thorough brushing and flossing. Appliances and tools may include special toothpicks, toothbrushes, water irrigation, or other devices.

Antiplaque or antitartar toothpastes or mouth rinses may be recommended by the dentist or dental hygienist.

Regular professional tooth cleaning is important to remove plaque that may develop even with careful brushing and flossing. Many dentists recommend having the teeth professionally cleaned at least every 6 months.

# **Periodontitis**

Classification of apical periodontitis (I.G.Lucomsky, 1960)

1. Acute apical periodontitis
  - serous periodontitis
  - purulent periodontitis
2. Chronic apical periodontitis
  - fibrotic periodontitis
  - granulomatous periodontitis
  - granulating periodontitis
3. Intensified periodontitis

**Acute serous apical periodontitis.** Face frequently symmetric, rare there is an edema of soft tissues in area of localization of inflammation. Regional lymph nodes are swelled, painful.

A casual tooth, as a rule, has a carious cavity, filling or intact, easy mobile. The pulp chamber frequently is not unsealed, probing of carious cavity and pulp chamber is painless, percussion of tooth is sickly. After releasing of the root canals from content and opening of the apex opening in the root canals it is possible to define a serous exudate, at the presence of which moist paper points testify. Beginning of exudate drainage from the root canals coincides with pain weakening. Transitional fold and gum, as a rule, hyperemic, swelled, painful in area of causal tooth; in the initial stage of inflammation of hyperemia and edema of transitional fold not observed. The general state of patient frequently is not changed.

Acute periodontitis (periodontitis acuta) depending on the nature of fluid shared by many authors in acute serous and acute purulent. I should say that such a distinction on the basis of a subjective data is not always possible. In addition, the transition from serous purulent inflammation is very fast and depends on several conditions, primarily on the condition of the patient.

Chronic periodontitis is divided based on the nature and extent of damage to periodontal tissues. Distinguish chronic fibrotic periodontitis (periodontitis chronica fibrosa), chronic granulating (periodontitis chronica granulans) and chronic granulomatous periodontitis, or granuloma (periodontitis chronica granulomatosa s. granuloma).

Chronic periodontitis in response to various adverse conditions (influenza, chill, etc.) may exacerbate the inflammatory process. The clinical course of the aggravated chronic periodontitis although it has many features in common with acute periodontitis, but also possesses its distinctive features. This form of asplenia has not only the elimination of acute inflammatory events, such as acute periodontitis, but also those destructive disturbances that are characteristic of some form of chronic periodontitis. On this basis, should be distinguished in the classification and chronic periodontitis in the acute stage (periodontitis chronica exacerbata).

**Possible Complications:** infection or abscess of the soft tissue (facial cellulitis); infection of the jaw bones (osteomyelitis); return of periodontitis; tooth abscess (fig.20); tooth loss; tooth flaring or shifting; trench mouth.

**Prevention.** Good oral hygiene is the best means of prevention. This includes thorough tooth brushing and flossing, and regular professional dental cleaning. The

prevention and treatment of gingivitis reduces the risk of development of periodontitis.

# Trench mouth (Vincent's stomatitis)

## Alternative Names

Vincent's stomatitis; Acute necrotizing ulcerative gingivitis

Trench mouth is a painful bacterial infection that involves swelling (inflammation) and ulcers in the gums (gingiva).

## When to Contact a Medical Professional

Call the dentist if you have symptoms of trench mouth, or if fever or other new symptoms develop.

**Causes.** Trench mouth is a painful form of gum swelling (gingivitis). The term "trench mouth" comes from World War I, when the disorder was common among soldiers.

The mouth normally contains a balance of different bacteria. Trench mouth occurs when there are too many normal mouth bacteria. The gums become infected and develop painful ulcers. Viruses may be involved in allowing the bacteria to grow too much.

**Risks** include the following: emotional stress; poor oral hygiene; poor nutrition; smoking; throat, tooth, or mouth infections.

This disorder is rare. When it does occur, trench mouth most often affects persons ages 15 - 35.

**Symptoms:** bad breath; crater-like ulcers between the teeth; fever; foul taste in the mouth; gums appear reddened and swollen; grayish film on the gums; painful gums; profuse gum bleeding in response to any pressure or irritation.

Symptoms often begin suddenly.

## Exams and Tests

The health care provider will look at your mouth for signs of trench mouth:

- Crater-like ulcers filled with plaque and food debris
- Destruction of gum tissue around the teeth
- Inflamed gums

There may be a gray film caused by broken down (decomposed) gum tissue. Occasionally, there may be fever and swollen lymph nodes of the head and neck.

Dental x-rays or x-rays of the face may be done to determine how severe the infection is and how much tissue has been destroyed.

This disease may also be tested for by a throat swab culture.

## **Treatment**

The goals of treatment are to cure the infection and relieve symptoms. Your health care provider may prescribe antibiotics if you have a fever.

Good oral hygiene is vital to the treatment of trench mouth. Brush and floss your teeth thoroughly as often as possible, at least twice a day and preferably after each meal and at bedtime.

Salt water rinses (1/2 teaspoon of salt in 1 cup of water) may soothe sore gums. Hydrogen peroxide, used to rinse the gums, is often recommended to remove dead or dying gum tissue.

Over-the-counter pain relievers (analgesics) may reduce your discomfort. Soothing rinses or coating agents may reduce pain, especially before eating. You may apply lidocaine to the gums for severe pain.

You may be asked to visit a dentist or dental hygienist to have your teeth professionally cleaned and to have the plaque removed, once your gums feel less tender. You may need frequent dental cleaning and examinations until the disorder is cleared.

To prevent the condition from coming back, your health care provider may give you instructions on how to:

- Maintain good general health, including proper nutrition and exercise
- Maintain good oral hygiene
- Reduce stress
- Stop smoking

Avoid irritants, including smoking and hot or spicy foods.

## **Outlook Prognosis**

The infection usually responds to treatment. The disorder can be quite painful until it is treated. If trench mouth is untreated or treatment is delayed, the infection can spread to the cheeks, lips, or jawbone and destroy these tissues.

**Possible Complications:** dehydration, loss of teeth; pain, periodontitis, spread of infection.

**Preventive measures** include: good general health; good nutrition; good oral hygiene, including thorough tooth brushing and flossing; learning ways to cope with stress; regular professional dental cleaning and examination; stopping smoking.

## Dental care for adult

### Ask your dentist:

- What toothbrush you should use, and where your problem areas are located.
- How to properly floss your teeth. Overly vigorous or improper flossing may injure the gums.
- Whether you should use any special appliances or tools, such as water irrigation or electric toothbrushes. These may sometimes help supplement (but not replace) brushing and flossing.
- Whether you could benefit from particular toothpastes or mouth rinses. In some cases, over-the-counter pastes and rinses may be doing you more harm than good, depending on your condition.

Tooth decay and gum disease are largely caused by plaque, a sticky combination of bacteria and food. Plaque begins to accumulate on teeth within 20 minutes after eating. If this plaque is not removed thoroughly each day, tooth decay will flourish. Over time, plaque will harden into tartar.

Plaque and tartar lead to a number of problems:

- Cavities -- holes that damage the structure of teeth
- Gingivitis -- swollen, inflamed, bleeding gums
- Periodontitis -- destruction of the ligaments and bone that support the teeth, often leading to tooth loss
- Bad breath (halitosis)
- Abscesses, pain, inability to use teeth
- A variety of health problems outside the mouth, from preterm labor to heart disease

Healthy teeth are clean and have no cavities. Healthy gums are pink and firm. To maintain healthy teeth and gums, follow these steps:

- Brush your teeth at least twice daily, preferably after every meal and at bedtime.
- Floss at least once per day.

- Schedule an appointment with a dentist for a routine cleaning and examination. Many dentists recommend having the teeth professionally cleaned every 6 months.
- Keep dentures, retainers, and other appliances clean. This includes regular brushing and may include soaking them in a cleansing solution.

Regular teeth cleaning by a dentist removes plaque that may develop even with careful brushing and flossing, especially in areas that are difficult for you to reach on your own. Professional cleaning includes scaling and polishing. This uses various instruments or devices to loosen and remove deposits from the teeth. Routine examination may include dental x-rays.

## **Mouth and Teeth: How to Keep Them Healthy**

Taking good care of your mouth and teeth throughout your whole life can help prevent problems as you get older. Taking care of your teeth means brushing and flossing every day and seeing the dentist regularly.

### **Infants and children**

The first set of teeth is already almost completely formed at birth. At first these teeth are "hiding" under the gums. These teeth are important, because after they come in, they let your baby chew food, make a nice smile and talk well. Your baby's first set of teeth also holds the space where permanent teeth will eventually be. They help permanent teeth grow in straight.

You can care for your baby's teeth by following these suggestions:

- Clean the new teeth every day. When the teeth first come in, clean them by rubbing them gently with a clean wet washcloth. When the teeth are bigger, use a child's toothbrush.
- Children under 2 years of age shouldn't use toothpaste. Instead, use water to brush your child's teeth.
- Don't let your baby go to sleep with a bottle. This can leave milk or juice sitting on the teeth and cause cavities that are known as "baby-bottle tooth decay."
- Encourage older children to eat low-sugar snacks, such as fruits, cheese and vegetables. Avoid giving your child sticky, chewy candy.
- Teach your children how to brush their teeth and the importance of keeping their teeth clean.
- Take your children to the dentist regularly. The American Dental Association recommends that children see their dentist starting at 1 year of age.



**Teens.** Taking good care of your mouth and teeth will help you have pleasant breath, a nice smile and fewer cavities. Here are some simple things you can do:

- Brush your teeth at least twice a day with a fluoride toothpaste.
- Floss your teeth at least once a day.
- Don't smoke or chew tobacco, which can stain your teeth, give you bad breath and cause cancer.
- Wear the right protective headgear while playing contact sports.
- See your dentist every year for regular check-ups and cleanings.

**Adults.** Continuing good mouth and tooth care as an adult can help you avoid tooth loss, painful gums or other problems. Here are some helpful things you can do:

- Brush your teeth at least twice a day with a fluoride toothpaste.
- Floss your teeth at least once a day.
- Don't smoke or chew tobacco.
- Ask your doctor if your medicines have side effects that might damage your teeth. (For example, some medicines may cause you to have a dry mouth.)
- Look inside your mouth regularly for sores that don't heal, irritated gums or other changes.
- See your dentist regularly.

If you have any problems with your teeth or concerns about your mouth, see your doctor or dentist right away

**Root canal.** A root canal is a dental procedure to remove dead or dying nerve tissue and bacteria from inside a tooth.

### **Description**

A dentist will use a needle to place numbing medicine (anesthetic) around the bad tooth. You may feel a slight prick when the needle is being inserted.

Next, your dentist uses a tiny drill to remove the top part of your tooth and expose the pulp. Pulp is made up of nerves, blood vessels, and connective tissue. It is found inside the tooth and runs to the jaw bone. Pulp supplies blood to a tooth and allows you to feel sensations such as temperature.

The infected pulp is removed with special tools called files. The canals (tiny pathways inside the tooth) are cleaned. Medicines may be placed into the area to make sure all the germs are gone and prevent further infection.

The cleaned tooth area is sealed with a soft, temporary material. Once the tooth is filled, a permanent crown may be placed on top.

You may be given antibiotics to treat and prevent infection.

### **Why the Procedure is Performed**

A root canal is done if you have an infection that affects the nerve in the root of a tooth. Generally, there is pain and swelling in the area. The infection can be the result of a tooth crack, cavity, or injury.

A root canal can save your tooth. Without treatment, the tooth may become so damaged that it must be removed.

## **Tooth abscess**

A tooth abscess is a collection of infected material (pus) resulting from a bacterial infection in the center of a tooth.

**Causes.** A tooth abscess is a complication of tooth decay. It may also result from trauma to the tooth, such as when a tooth is broken or chipped. Openings in the tooth enamel allow bacteria to infect the center of the tooth (the pulp). Infection may spread out from the root of the tooth and to the bones supporting the tooth.

Infection results in a collection of pus (dead tissue, live and dead bacteria, white blood cells) and swelling of the tissues within the tooth. This causes a painful toothache. If the pulp of the tooth dies, the toothache may stop, unless an abscess develops. This is especially true if the infection remains active and continues to spread and destroy tissue.

**Symptoms.** The main symptom is a severe toothache. The pain is continuous and may be described as gnawing, sharp, shooting, or throbbing.

Other symptoms may include: bitter taste in the mouth; breath odor; general discomfort, uneasiness, or ill feeling; fever; pain when chewing; sensitivity of the teeth to hot or cold; swollen glands of the neck; swollen area of the upper or lower jaw -- a very serious symptom.

### **Exams and Tests**

The patient will feel pain when the dentist taps the tooth. Biting or closing the mouth tightly also increases the pain. The gums may be swollen and red and may drain thick material.

**Treatment.** The goals of treatment are to cure the infection, save the tooth, and prevent complications.

Antibiotics may be given to fight the infection. Warm salt-water rinses may be soothing. Over-the-counter pain relievers may relieve the toothache and fever.

Do NOT place aspirin directly over the tooth or gums, because this increases irritation of the tissues and can result in mouth ulcers.

A root canal may be recommended in an attempt to save the tooth.

If there is a severe infection, the tooth may be removed or surgery may be needed to drain the abscess. Some people may need to be admitted to the hospital.

### **Outlook Prognosis**

Untreated abscesses may get worse and can lead to life-threatening complications.

Prompt treatment usually cures the infection. The tooth can usually be saved in many cases.

### **Possible Complications**

- Loss of the tooth
- Mediastinitis
- Sepsis
- Spread (Fig.21) of infection to soft tissue (facial cellulitis, Ludwig's angina)
- Spread of infection to the jaw bone (osteomyelitis of the jaw)
- Spread of infection to other areas of the body resulting in brain abscess, endocarditis, pneumonia, or other complications

## **Bleeding gums**

### **Alternative Names**

Gums - bleeding

Bleeding gums can be a sign that you are at risk for, or already have, gum disease. However, persistent gum bleeding may be due to serious medical conditions such as leukemia and bleeding and platelet disorders.

### **When to Contact a Medical Professional**

Consult if:

- The bleeding is severe or long term (chronic)
- Your gums continue to bleed even after treatment
- You have other unexplained symptoms with the bleeding

Dentist will examine teeth and gums, and ask questions such as:

- Are the gums bleeding a large amount?

- Did the bleeding begin recently?
- Do the gums bleed frequently or only occasionally?
- Have you had gum problems before?
- How often do you brush?
- How often do you floss?
- Do you use a soft- or hard-bristle toothbrush?
- How vigorously do you brush?
- What other home care aids do you use (toothpicks or other)?
- When was the last time you had your teeth cleaned at the dentist?
- Have you changed your diet?
- Do you eat adequate amounts of fruits and vegetables?
- Do you take supplemental vitamins?
- Do you have a high carbohydrate diet (pasta)?
- What medications do you take? Do you take seizure medicines, blood thinners (such as Coumadin, heparin), or aspirin?
- Are you pregnant?
- Have you changed mouthwash or toothpaste recently?
- What other symptoms do you have? (for example, sore throat)

**Considerations.** It is important to follow the instructions from your dentist in order to maintain healthy gums. Improper brushing and flossing technique may actually irritate or traumatize the gum tissue.

**Causes.** Bleeding gums are mainly due to inadequate plaque removal from the teeth at the gum line. This will lead to a condition called gingivitis, or inflamed gums.

If plaque is not removed through regular brushing and dental appointments, it will harden into what is known as tartar. Ultimately, this will lead to increased bleeding and a more advanced form of gum and jawbone disease known as periodontitis.

Other causes of bleeding gums include:

- Any bleeding disorder
- Brushing too hard
- Hormonal changes during pregnancy
- Idiopathic thrombocytopenic purpura
- Ill-fitting dentures
- Improper flossing
- Infection, which can be either tooth- or gum-related
- Leukemia
- Scurvy
- Use of blood thinners
- Vitamin K deficiency

**Home Care.** Visit the dentist at least once every 6 months for plaque removal. Follow your dentist's home care instructions.

You should brush your teeth gently with a soft-bristle toothbrush after every meal. The dentist may recommend rinsing with salt water or hydrogen peroxide and water. Avoid using commercial, alcohol-containing mouthwashes, which aggravate the problem.

Flossing teeth twice a day can prevent plaque from building up. Avoiding snacking between meals and reducing carbohydrates can also help. Follow a balanced, healthy diet.

Other tips:

- Avoid the use of tobacco, which aggravates bleeding gums.
- Control gum bleeding by applying pressure directly on the gums with a gauze pad soaked in ice water.
- If you have been diagnosed with a vitamin deficiency, take recommended vitamin supplements.
- Avoid aspirin unless your health care provider has recommended that you take it.
- If side effects of medication are irritating, ask your doctor to recommend another medication. Never change your medication without consulting your doctor.
- Use an oral irrigation device on the low setting to massage the gums.
- See your dentist if your dentures do not fit correctly or if they are causing sore spots in your gums.

Diagnostic tests that may be performed include:

- Blood studies such as a CBC or blood differential
- X-rays of the teeth and jawbone

## Gingivostomatitis

Gingivostomatitis is a viral or bacterial infection of the mouth and gums that leads to swelling and sores.

**Causes.** Gingivostomatitis is common, particularly among children. It may occur after infection with the herpes simplex virus type 1 (HSV-1), which also causes cold sores. See: Herpetic stomatitis

The condition may also occur after infection with a coxsackie virus. See: herpangina

It may occur in people with poor oral hygiene.

**Symptoms.** The **symptoms** can be mild or severe and may include:

bad breath; fever; general discomfort, uneasiness, or ill feeling (malaise); sores on the inside of the cheeks or gums; very sore mouth with no desire to eat.

**Exams and Tests.** An examination of the mouth shows small ulcers. These ulcers are similar to mouth ulcers caused by other conditions. Your health care provider may consider other conditions if there are signs of a cough, fever, or muscle aches.

Normally, no special tests are needed to diagnose gingivostomatitis. However, the doctor may take a small piece of tissue from the sore to check for a viral or bacterial infection. This is called a culture. A biopsy may occasionally be done to rule out other types of mouth ulcers.

**Treatment.** The goal is to reduce symptoms. Practice good oral hygiene. Even if there is bleeding and it is painful, thorough but gentle brushing of the gums is important to reduce the chances of additional infection from normal mouth bacteria.

Antibiotics may be required. The dentist may need to clean infected tissue (a process called debridement).

Medicated mouth rinses may be recommended to reduce pain. Salt water (one-half teaspoon of salt in one cup of water) or over-the-counter mouthwashes like hydrogen peroxide or Xylocaine may be soothing.

The diet should be well balanced and nutritious. Soft, bland (non-spicy) foods may reduce discomfort during eating.

**Outlook Prognosis.** Gingivostomatitis infections range from mild and slightly uncomfortable to severe and painful. The sores generally resolve in 2 or 3 weeks with or without treatment. Treatment may reduce discomfort and speed healing.

**Possible Complications.** Gingivostomatitis may disguise other, more serious mouth ulcers.

## **Tooth - abnormal colors**

### **Alternative Names**

Discolored teeth; Tooth discoloration; Tooth pigmentation

Abnormal tooth color is any color other than the white to yellowish-white of normal teeth.

**Ask a doctor if:**

- Teeth appear to be an abnormal color without cause
- Abnormal tooth color lasts even after practicing good oral hygiene

The dentist will examine the teeth and ask questions about the symptoms. Questions may include:

- Time pattern
  - Have the teeth been abnormally colored since they grew in, or did they change color over time?
  - When did you notice this problem?
  - Does it improve when good oral hygiene is maintained?
- Diet
  - What foods and drinks do you or your child usually consume?
  - Does the person drink coffee or tea?
  - How much milk and dairy products does the person drink?
- Medication history
  - What medications are currently being used?
  - What medications have been taken in the past (particularly, did the child ever take tetracycline)?
  - What medications did the mother take when pregnant?
- Health history and family history
  - Do other members of the family have teeth that are abnormally colored?
  - How has the general health been?
  - Was the child jaundiced as a baby?
- Fluoride exposure
  - Is the water fluoridated where you live or visit frequently?
  - Do you take fluoride supplements?
- Oral hygiene habits
  - Are there frequent problems with the teeth such as cavities or gum inflammation?
  - What are the dental habits?
  - How often are the teeth brushed and flossed?
  - What kind of toothpaste, mouthwash, or similar substances are used?
- What other symptoms are also present?

**Considerations.** Many different things can cause tooth discoloration. The change in color may affect the entire tooth, or just appear as spots or lines in the tooth enamel.

Your genes influence your tooth color. Other things that can affect tooth color include: congenital diseases; environmental factors; infections.

Inherited diseases may affect the thickness of enamel or the calcium or protein content of the enamel, which can cause color changes. Metabolic diseases may cause changes in tooth color and shape.

Drugs and medications either taken by the mother while pregnant or by the child during the time of tooth development can cause changes in both the color and hardness of the enamel.

### **Causes**

- Antibiotic tetracycline use before age 8
- Eating or drinking items that temporarily stain the teeth, such as tea or coffee
- Genetic defects that affect the tooth enamel, such as dentinogenesis and amelogenesis
- High fever at an age when teeth are forming
- Poor oral hygiene
- Porphyria
- Severe neonatal jaundice
- Too much fluoride from environmental sources (natural high water fluoride levels) or overuse of fluoride rinses, toothpaste, and fluoride supplements

**Home Care.** Good oral hygiene will help if the teeth are stained from a food or fluid, or if the abnormal color is the result of poor hygiene.

It is appropriate to consult your dentist for abnormally colored teeth. However, if the color seems to be related to a medical condition, your regular health care provider should also be consulted.

Testing may not be necessary in many cases. However, if the health care provider suspects the coloration may be related to a medical condition, testing may be needed to confirm the diagnosis. Dental x-rays may be taken.

## **Tooth - abnormal shape**

### **Alternative Names**



Hutchinson incisors; Abnormal tooth shape; Peg teeth; Mulberry teeth; Conical teeth

An abnormally shaped tooth is any tooth that has an irregular shape.

If the shape of child's teeth appears to be abnormal, consult a dentist or other health care provider.

The dentist will examine the mouth and teeth. You will be asked questions about your child's medical history and symptoms, such as:

- Does the child have any medical conditions that may cause abnormal tooth shape?
- At what age did the teeth appear?
- In what order did the teeth appear?
- Are there other tooth problems (color, spacing)?
- What other symptoms are also present?

**Considerations.** The appearance of normal teeth varies, especially the molars. Abnormally shaped teeth can result from many different conditions. Specific diseases can have a profound effect on tooth shape, tooth color, time of appearance, or absence of teeth.

**Causes:** congenital syphilis; cerebral palsy; ectodermal dysplasia, anhidrotic; incontinentia pigmenti achromians; cleidocranial dysostosis; Ehlers-Danlos syndrome; Ellis-van Creveld syndrome.

Diagnostic tests that may be performed may include dental x-rays.

## Gums - swollen

### Alternative Names

Swollen gums; Gingival swelling

Swollen gums are abnormally enlarged, bulging, or protruding.

### When to Contact a Medical Professional

- Swelling is severe, persistent, or is accompanied by other unexplained symptoms
- Discomfort is associated with swelling

## What to Expect at Office Visit

The dentist will examine mouth, teeth, and gums. You will be asked questions about medical history and symptoms, such as:

- Quality
  - Do your gums bleed?
- Time pattern
  - Did the swelling begin recently?
  - Are they always swollen?
  - Does the amount of swelling change?
  - Does it only occur occasionally?
  - Have you had gum problems before?
- Oral hygiene habits
  - How often do you brush?
  - How often do you floss?
  - How hard of a toothbrush is used?
  - How vigorously do you brush?
  - What are other habits (use of toothpicks or other)?
  - When was the last time you had the teeth professionally cleaned (at the dentist)?
- Eating habits
  - Have you changed your diet?
  - Do you eat adequate amounts of fruits and vegetables?
  - Do you take supplemental vitamins?
- Other
  - What medications do you take?
  - Are you pregnant?
  - Have you changed mouthwash or toothpaste recently?
  - What other symptoms do you have? For example, breath odor, sore throat, pain.

**Considerations.** Gum swelling is quite common and may involve one or many of the triangular-shaped bits of gum between nearby teeth. These sections are called papillae. Occasionally, the gums swell significantly, blocking the teeth completely.

**Causes:** gingivitis, infection by a virus or fungus; malnutrition, poorly fitting dentures; pregnancy, sensitivity to toothpaste or mouthwash; scurvy, side effect of a drug such as Dilantin or phenobarbital.

**Home Care.** Improve your nutrition if it is poor.

Avoid gum irritants such as commercial mouthwashes, alcohol, and tobacco. Change your toothpaste brand and avoid using mouthwashes if your swollen gums are caused by sensitivity to toothpaste or mouthwash.

Use good oral hygiene. See a periodontist or dentist at least every 6 months.

If your swollen gums are caused by a reaction to a drug, talk to your doctor about using a different type of medication. Never change medications without first talking to your doctor.

Tests may include blood studies such as a CBC or blood differential.

The patient will be taught proper mouth and gum care.

## Herpetic stomatitis

### Alternative Names

Stomatitis - herpetic

Herpetic stomatitis is a viral infection of the mouth that causes ulcers and inflammation. These mouth ulcers are not the same as canker sores, which are caused by a different virus.

### When to Contact a Medical Professional

**Go to your doctor** if your child develops a fever followed by a sore mouth, especially if they begin eating poorly (dehydration can develop rapidly in children).

**Causes.** Herpetic stomatitis is a contagious viral illness caused by *Herpes virus hominis* (also herpes simplex virus, HSV). It is seen mainly in young children. This condition is probably a child's first exposure to the herpes virus.

An adult member of the family may have a cold sore at the time the child develops herpetic stomatitis. More likely, no source for the infection will be discovered.

### Symptoms

- Blisters in the mouth, often on the tongue or cheeks
- Decrease in food intake, even if the patient is hungry
- Difficulty swallowing (dysphagia)
- Drooling
- Fever (often as high as 104 °Fahrenheit) may occur 1 - 2 days before blisters and ulcers appear
- Irritability
- Pain in mouth
- Swollen gums
- Ulcers in the mouth, often on the tongue or cheeks -- these form after the blisters pop

## Exams and Tests

Herpetic stomatitis is normally diagnosed based on its very typical appearance. Laboratory studies are seldom done. Sometimes viral culture and special stains can help with the diagnosis.

**Treatment.** Herpetic stomatitis can be treated with the acyclovir family of antiviral medications.

While the mouth is very sore, the child should be put on a mostly liquid diet of cool-to-cold, nonacidic drinks.

An oral topical anesthetic (viscous lidocaine) is available for severe pain, but it must be used with care because the anesthetic deadens all feeling. It may interfere with swallowing, and can possibly cause the child to burn the mouth or throat on hot liquids, or choke. In addition, there are rare reports of death from overdose or misuse of lidocaine.

**Outlook Prognosis.** The child should recover completely within 10 days without medical treatment. Oral acyclovir may speed up recovery.

**Possible Complications.** Herpetic keratoconjunctivitis, a secondary herpes infection in the eye, may develop. This is an emergency and can lead to blindness. Dehydration may develop if the child refuses to eat and drink enough because of a sore mouth.

**Prevention.** Approximately 90% of the population carries herpes simplex virus. It is difficult to prevent children from picking up the virus at some time during their childhood.

Children should strictly avoid close contact with people who have cold sores (for example, no kissing parents who have active cold sores). Children should also avoid other children with herpetic stomatitis. They should not share utensils, glasses, or food with actively infected people.

# Mouth ulcers

## Alternative Names

Oral ulcer; Stomatitis - ulcerative; Ulcer - mouth

Mouth ulcers are sores or open lesions in the mouth.

## When to Contact a Medical Professional

**Call the doctor** if your mouth ulcers don't go away after 3 weeks. Call for an appointment with your health care provider if mouth ulcers return frequently, or if new symptoms develop.

## **Causes**

Mouth ulcers are **caused** by many disorders. These include:

canker sores; gingivostomatitis; herpes simplex; leukoplakia, oral cancer; oral lichen planus; oral thrush.

The skin lesion of histoplasmosis may also appear as a mouth ulcer.

Canker sores are more common in young adults than in children or older adults.

**Symptoms:** open sores in the mouth; pain or discomfort in the mouth

The appearance and exact location of lesions varies with the specific disorder.

## **Exams and Tests**

A health care provider or dentist usually diagnoses the type of mouth ulcer, based on its appearance and location. Blood tests or a biopsy of the ulcer may be needed to confirm the cause.

## **Treatment**

The goal of treatment is to relieve symptoms. The cause, if known, should be treated.

Gentle, thorough oral hygiene may relieve some of the symptoms. Topical (rubbed on) antihistamines, antacids, corticosteroids, or other soothing preparations may be recommended for applying directly to the ulcer.

Avoid hot or spicy foods, which often increase the pain of mouth ulcers.

## **Outlook (Prognosis)**

The outcome varies depending on the cause of the ulcer. Many mouth ulcers are harmless (benign) and heal without treatment. Sometimes, mouth cancer first appears as an ulcer that won't heal.

## **Possible Complications**

- Cellulitis of the mouth, from secondary bacterial infection of ulcers
- Dental infections (tooth abscesses)
- Oral cancer

- Spread of contagious disorders to other people

**Prevention.** Good oral hygiene may help prevent some types of mouth ulcers, as well as some complications from mouth ulcers. Good oral hygiene includes brushing the teeth at least twice per day, flossing at least daily, and getting regular professional dental cleanings and examinations.

## Osteomyelitis

Osteomyelitis is an acute or chronic bone infection.

### When to Contact a Medical Professional

Call the doctor if:

- You develop symptoms of osteomyelitis
- You have osteomyelitis and the symptoms continue despite treatment

**Causes.** Bone infection can be caused by bacteria (more common) or fungi (less common).

- Infection may spread to a bone from infected skin, muscles, or tendons next to the bone, as in osteomyelitis that occurs under a chronic skin ulcer (sore).
- Chronic (fig.22) odontogenic process (caries and complications).
- The infection that causes osteomyelitis can also start in another part of the body and spread to the bone through the blood.
- A current or past injury may have made the affected bone more likely to develop the infection. A bone infection can also start after bone surgery, especially if the surgery is done after an injury or if metal rods or plates are placed in the bone.

In children, the long bones are usually affected. In adults, the feet, spine bones (vertebrae), and the hips (pelvis) are most commonly affected.

**Risk factors** are: diabetes, hemodialysis, injected drug use, poor blood supply, recent trauma.

People who have had their spleen removed are also at higher risk for osteomyelitis.

**Symptoms:** bone pain, disfunction, anaesthesia; fever; general discomfort, uneasiness, or ill-feeling (malaise); local swelling, redness, and warmth.

**Other symptoms** that may occur with this disease:

chills, excessive sweating; low back pain; swelling of the ankles, feet, and legs.

## **Exams and Tests**

A physical examination shows bone tenderness and possibly swelling and redness.

**Tests** may include:

blood cultures; bone biopsy (which is then cultured); bone scan; bone x-ray; complete blood count (CBC); C-reactive protein (CRP); erythrocyte sedimentation rate (ESR); MRI of the bone; needle aspiration of the area around affected bones.

## **Treatment**

The goal of treatment is to get rid of the infection and reduce damage to the bone and surrounding tissues.

Antibiotics are given to destroy the bacteria causing the infection. You may receive more than one antibiotic at a time. Often, the antibiotics are given through an IV (intravenously, meaning through a vein) rather than by mouth. Antibiotics are taken for at least 4 - 6 weeks, sometimes longer.

Surgery (fig.23) may be needed to remove dead bone tissue if you have an infection that does not go away. If there are metal plates near the infection, they may need to be removed. The open space left by the removed bone tissue may be filled with bone graft or packing material that promotes the growth of new bone tissue.

Infection of an orthopedic prosthesis, such as an artificial joint, may need surgery to remove the prosthesis and infected tissue around the area. A new prosthesis may be implanted in the same operation. More often, doctors wait to implant the prosthesis until the infection has gone away.

If you have diabetes, it will need to be well controlled. If there are problems with blood supply to the infected area, such as the foot, surgery to improve blood flow may be needed.

## **Outlook Prognosis**

With treatment, the outcome for acute osteomyelitis is usually good.

The outlook is worse for those with long-term (chronic) osteomyelitis, even with surgery. Amputation may be needed, especially in those with diabetes or poor blood circulation.

The outlook for those with an infection of an orthopedic prosthesis depends, in part, on:

- The patient's health

- The type of infection
- Whether the infected prosthesis can be safely removed

### **Possible Complications**

When the bone is infected, pus is produced in the bone, which may result in an abscess. The abscess steals the bone's blood supply. The lost blood supply can result in a complication called chronic osteomyelitis. This chronic infection can cause symptoms that come and go for years.

Other complications include:

- Need for amputation
- Reduced joint function
- Spread of infection to surrounding tissues or the bloodstream
- Sequestration of the bone- chronic phase

**Prevention.** Prompt and complete treatment of infections is helpful. People who are at high risk or who have a compromised immune system should see a health care provider promptly if they have signs of an infection anywhere in the body.

## **Sinusitis (Rhinosinusitis)**

### **Alternative Names**

Acute sinusitis; Sinus infection; Sinusitis - acute; Sinusitis - chronic; Rhinosinusitis

**What are sinuses?** Sinuses are paired air cavities/spaces (pockets) found in the cranial (head) bones. Sinuses are also referred to as "paranasal sinuses". They are connected to the nose on the facial part of the skull where air passes and mucus drains.

We have four paired sinus cavities. Each sinus cavity has an opening (ostium), which opens into the nasal passages for free exchange of air and mucus. The mucus linings have ciliated epithelium (cells with fine hairs) that moves dirty mucus from the sinus cavities which drains into the nasal passages.

Sinuses are often confused with sinusitis. Sinus cavities vary according to location in the facial bones of the skull - they can become inflamed individually or collectively.

When these sinuses become infected it is known as sinusitis.

**There are sinus cavities (fig.24):**



- **Ethmoid (between the eyes) sinuses.** These sinuses are located behind the bridge of the nose and at the "root" of the nose between the eyes. We are all born with ethmoid sinuses and as we grow, they also grow. When these cavities become inflamed, you have a condition called *ethmoiditis*.
- **Frontal (forehead) sinuses.** These sinus cavities are located above the eyes in the region of the forehead and only develop around seven years of age. When the frontal cavities become inflamed, you have a condition called *frontal sinusitis*.
- **Maxillary (cheekbones) sinuses.** These sinus cavities are found on either side of the nostrils in the cheek bones. They are present at birth and grow as we grow. Inflammation of maxillary cavities due to bacterial, viral and other irritants is called *antritis*.
- **Sphenoid (behind the eyes) sinuses.** These sinus cavities lie deeper in the skull behind the ethmoid sinuses and the eyes. We only develop sphenoid sinus cavities during adolescence. Inflammation of these cavities due to any irritant is called *sphenoiditis*.

Sinusitis refers to inflammation of the sinuses that occurs with a viral, bacterial, chronic infection of teeth or fungal infection.

#### **Call your doctor if:**

- Your symptoms last longer than 10 - 14 days or you have a cold that gets worse after 7 days
- You have a severe headache, unrelieved by over-the-counter pain medicine
- You have a fever, caries (cavity)
- You still have symptoms after taking all of your antibiotics properly
- You have any changes in your vision during a sinus infection

A green or yellow discharge does not necessarily indicate a sinus infection or the need for antibiotics.

**Causes.** The sinuses are air-filled spaces in the skull (behind the forehead, nasal bones, cheeks, and eyes) that are lined with mucus membranes. Healthy sinuses contain no bacteria or other germs. Usually, mucus is able to drain out and air is able to circulate.

When the sinus openings become blocked or too much mucus builds up, bacteria and other germs can grow more easily.

Sinusitis can occur from one of these conditions:

- Small hairs (cilia) in the sinuses, which help move mucus out, do not work properly due to some medical conditions.
- Colds and allergies may cause too much mucus to be made or block the opening of the sinuses.

- A deviated nasal septum, nasal bone spur, or nasal polyps may block the opening of the sinuses.
- Chronic tooth infection, complication during extraction –perforation of the sinus

Sinusitis can be:

- Acute -- symptoms last up to 4 weeks
- Sub-acute -- symptoms last 4 - 12 weeks
- Chronic -- symptoms last 3 months or longer

Acute sinusitis is usually caused by a bacterial infection in the sinuses that results from an upper respiratory tract infection. Chronic sinusitis refers to long-term swelling and inflammation of the sinuses that may be caused by bacteria or a fungus.

The following may increase your risk or your child's risk of developing sinusitis:

- Allergic rhinitis or hay fever
- Cystic fibrosis
- Day care
- Diseases that prevent the cilia from working properly, such as Kartagener syndrome and immotile cilia syndrome.
- Changes in altitude (flying or scuba diving)
- Large adenoids
- Smoking
- Tooth infections (rare)
- Weakened immune system from HIV or chemotherapy

**Symptoms.** The classic symptoms of acute sinusitis in adults usually follow a cold that does not improve, or one that worsens after 5 - 7 days of symptoms.

Symptoms include:

- Bad breath or loss of smell
- Cough, often worse at night
- Fatigue and generally not feeling well
- Fever
- Headache - pressure-like pain, pain behind the eyes, toothache, or facial tenderness
- Nasal congestion and discharge
- Sore throat and postnasal drip

Symptoms of chronic sinusitis are the same as those of acute sinusitis (fig.25), but tend to be milder and last longer than 12 weeks.

Symptoms of sinusitis in children include:

- Cold or respiratory illness that has been improving and then begins to get worse
- High fever, along with a darkened nasal discharge, for at least 3 days
- Nasal discharge, with or without a cough, that has been present for more than 10 days and is not improving

## **Exams and Tests**

The doctor will examine patient:

- Looking in the mouth, nose for signs of polyps, caries
- Shining a light against the sinus (transillumination) for signs of inflammation
- Tapping over a sinus area to find infection

Regular x-rays of the sinuses are not very accurate for diagnosing sinusitis.

Viewing the sinuses through a fiberoptic scope (called nasal endoscopy or rhinoscopy) may help diagnose sinusitis. This is usually done by doctors who specialize in ear, nose, and throat problems (ENTs).

However, these tests are not very sensitive at detecting sinusitis.

A CT scan of the sinuses may also be used to help diagnose sinusitis or to evaluate the anatomy of the sinuses to determine whether surgery will be beneficial. If sinusitis is thought to involve a tumor or fungal infection, an MRI of the sinuses may be necessary.

If you patient with chronic or recurrent sinusitis, other tests may include:

- Allergy testing
- Blood tests for HIV or other tests for poor immune function
- Ciliary function tests
- Nasal cytology
- Sweat chloride tests for cystic fibrosis

## **Treatment**

### **SELF CARE**

Try the following measures to help reduce congestion in your sinuses:

- Apply a warm, moist washcloth to your face several times a day.
- Drink plenty of fluids to thin the mucus.
- Inhale steam 2 - 4 times per day (for example, sitting in the bathroom with the shower running).

- Spray with nasal saline several times per day.
- Use a humidifier.

Be careful with over-the-counter spray nasal decongestants. They may help at first, but using them for more than 3 - 5 days can actually worsen nasal congestion.

Also, for sinus pain or pressure:

- Avoid flying when you are congested.
- Avoid temperature extremes, sudden changes in temperature, and bending forward with your head down.
- Try acetaminophen or ibuprofen.

## MEDICATIONS AND OTHER TREATMENTS

Antibiotics are usually not needed for acute sinusitis. Most of these infections go away on their own. Even when antibiotics do help, they may only slightly reduce the time you or your child is sick. Antibiotics may be prescribed sooner for:

- Children with nasal discharge, possibly with a cough, that is not getting better after 2 - 3 weeks
- Fever higher than 102.2° Fahrenheit (39° Celsius)
- Headache or pain in the face
- Severe swelling around the eyes

Acute sinusitis should be treated for 10 - 14 days. Chronic sinusitis should be treated for 3 - 4 weeks. Some people with chronic sinusitis may need special medicines to treat fungal infections.

At some point, your doctor will consider other prescription medications, further testing, or referral to an ear, nose, and throat (ENT) or allergy specialist.

Other treatments for sinusitis include:

- Allergy shots (immunotherapy) to help prevent the disease from returning
- Avoiding allergy triggers
- Nasal corticosteroid sprays and antihistamines to decrease swelling, especially if there are nasal polyps or allergies

Surgery to clean and drain the sinuses may also be necessary, especially in patients whose symptoms fail to go away after 3 months, despite medical treatment, or in patients who have more than two or three episodes of acute sinusitis each year. An ENT specialist (also known as an otolaryngologist) can perform this surgery.

Most fungal sinus infections require surgery. Surgical repair of a deviated septum or nasal polyps may prevent the condition from returning.

**Outlook Prognosis.** Sinus infections are usually curable with self-care measures and medical treatment. If you are having recurrent attacks, you should be checked for underlying causes such as nasal polyps or other problems, such as allergies.

**Possible Complications.** Although very rare, complications may include:

- Abscess, phlegmons
- Bone infection (osteomyelitis)
- Meningitis
- Skin infection around the eye (orbital cellulitis)

**Prevention.** The best way to prevent sinusitis is to avoid or quickly treat flus and colds:

- Eat plenty of fruits and vegetables, which are rich in antioxidants and other chemicals that could boost your immune system and help your body resist infection.
- Get an influenza vaccine each year.
- Reduce stress.
- Wash your hands often, particularly after shaking hands with others.

Other tips for preventing sinusitis:

- Avoid smoke and pollutants.
- Drink plenty of fluids to increase moisture in your body.
- Take decongestants during an upper respiratory infection.
- Treat allergies quickly and appropriately.
- Use a humidifier to increase moisture in your nose and sinuses.

## Leukoplakia

### Alternative Names

Hairy leukoplakia; Smoker's keratosis

Leukoplakia is a precancerous sore (lesion) that develops on the tongue or the inside of the cheek in response to chronic irritation. Occasionally, leukoplakia patches develop on the external female genitals.

**Go to the dentist** if you have any lesions resembling leukoplakia or hairy leukoplakia.

### Causes

Leukoplakia mainly affects the mucus membranes of the mouth (fig.26). It is caused by irritation. Sores usually develop on the tongue, but they may also appear on the insides of the cheek.

Irritation in the mouth may be caused by rough teeth or rough places on dentures, fillings, and crowns. It may also result from smoking or other tobacco use (smoker's keratosis).

Persons who smoke pipes are at high risk for developing this condition, as are those who hold chewing tobacco or snuff in their mouth for a long period of time.

Leukoplakia patches may develop on the external female genital area, but the cause is unknown.

Leukoplakia may become cancerous.

The disorder is most common in elderly persons.

"Hairy" leukoplakia of the mouth is an unusual form of leukoplakia that is seen mostly in HIV-positive people. It may be one of the first signs of HIV infection. It can also appear in other people whose immune system is not working well, such as after a bone marrow transplant. It is caused by the Epstein-Barr virus, but is not harmful by itself.

White patches usually appear on the tongue and sometimes on other places in the mouth. The condition may look like thrush, a type of Candida infection that is also linked to HIV and AIDS in adults.

## **Symptoms**

The most common symptoms of hairy leukoplakia are painless, fuzzy white patches on the side of the tongue.

The skin lesions tend to have the following characteristics:

- Location
  - Usually on the tongue
  - May be on the inside of the cheeks
  - In females, occasionally on the genitals
- Color
  - Usually white or gray
  - May be red (called erythroplakia, a condition that can lead to cancer)
- Texture
  - Thick
  - Slightly raised
  - Hardened surface

## **Exams and Tests**

The typical white patch of leukoplakia develops slowly, over weeks to months. The lesion may eventually become rough in texture, and may become sensitive to touch, heat, spicy foods, or other irritation.

A biopsy of the lesion confirms the diagnosis. An examination of the biopsy specimen may find changes that indicate oral cancer.

## **Treatment**

The goal of treatment is to get rid of the lesion. Removing the source of irritation is important and may cause the lesion to disappear.

- Treat dental causes such as rough teeth, irregular denture surface, or fillings as soon as possible.
- Stop smoking or using other tobacco products.
- Do not drink alcohol.

You may need surgery to remove the lesion. The lesion is usually removed in your health care provider's office using local anesthesia.

Leukoplakia on the vulva is treated in the same way as oral lesions.

## **Outlook Prognosis**

Leukoplakia is usually harmless. Lesions often clear up in a few weeks or months after the source of irritation is removed.

Oral hairy leukoplakia is often a sign of HIV infection and an increased likelihood of developing AIDS, but it is not harmful by itself.

## **Possible Complications:**

chronic discomfort ; infection of the lesion; oral cancer.

**Prevention.** Minimize or stop smoking or using other tobacco products. Do not drink alcohol, or limit your number of alcoholic drinks. Have rough teeth treated and dental appliances repaired promptly.

Safer sexual practices minimize the risk of contracting sexually-transmitted diseases, including HIV.

# HIV infection

## Alternative Names

Human immunodeficiency virus infection

(HIV) infection is a condition caused by the human immunodeficiency virus. The condition gradually destroys the immune system, which makes it harder for the body to fight infections.

**Call the doctor** if you have had a possible or actual exposure to AIDS or HIV infection.

## Causes

The human immunodeficiency virus (HIV) can be spread by the following:

- Through sexual contact -- including oral, vaginal, and anal sex
- Through blood -- via blood transfusions (now very rare in the U.S.) or needle sharing
- From mother to child -- a pregnant woman can transmit the virus to her fetus through their shared blood circulation, or a nursing mother can pass it to her baby in her breast milk

People who become infected with HIV may have no symptoms for up to 10 years, but they can still pass the infection to others. After being exposed to the virus, it usually takes about 3 months for the HIV ELISA blood test to change from HIV negative to HIV positive.

The disease is more common in urban areas, especially in inner cities.

## The classic definition of AIDS

1. Major signs :
  - Unexplained weight loss greater than 10% of body mass
  - Fever lasting longer than a month
  - Chronic diarrhea of longer than one month duration
2. Minor signs :
  - Persistent coughing
  - Itchy dermatitis (red, itchy skin, often with tiny pustules-pruritic dermatitis)
  - Recurrent **Shingles** (painful skin eruptions over the skin on one part of the body caused by the chickenpox virus, Herpes zoster.)
  - **Fungal infections** of the mouth and throat in younger persons not otherwise likely to get this disease.



- Chronic, severe, recurring (fig.27)**Herpes Simplex** (similar to shingles but not confined to one part of the body); warts (fig.28)
- **Lymphadenopathy** (generalized swelling of the lymph nodes, especially those of the

**Geographic tongue**-This condition is thought to be an oral form of psoriasis (a common skin condition), and is characterized by the disappearance of the **filiform papillae** from irregular patches on the top surface of the tongue. These patches then "heal" up and reoccur on another part of the tongue at a later date. One can see lesions in varying stages of healing over large expanses of the tongue. The cause of this condition is unknown. These patients often complain of pain when eating sharp foods. The condition can be treated with topical application of steroid gels or mouth rinses. In general, however, it is not treated. Geographic tongue is not a contagious condition. This condition might be seen more frequently in AIDS patients, however the presence of geographic tongue does NOT mean that the patient has AIDS. It may be more prevalent in persons with HIV because the virus attacks the immune system, and psoriasis is caused by a malfunction of the immune system.

### **Exams and Tests**

The HIV ELISA and HIV Western blot tests detect antibodies to the HIV virus in the blood. Both tests must be positive to confirm an HIV infection. Having these antibodies means you are infected with HIV.

- If the test is negative (no antibodies found) and you have risk factors for HIV infection, you should be retested in 3 months.
- If the HIV ELISA and HIV Western blot tests are positive, other blood tests can be done to determine how much HIV is in your bloodstream.

A complete blood count (CBC) and white blood cell differential may also show abnormalities.

A lower-than-normal CD4 cell count may be a sign that the virus is damaging your immune system.

**Treatment.** Doctors often recommend drug therapy for patients who are committed to taking all their medications and have a CD4 count below 500 cells/mm<sup>3</sup> (indicating their immune system is suppressed). Some people, including pregnant women and people with kidney or neurological problems related to HIV, may need treatment regardless of their CD4 count.

It is extremely important for people with HIV to take all doses of their medications, otherwise the virus may become resistant to the drugs. Therapy always involves a combination of antiviral drugs. Pregnant women with HIV infection are treated to reduce the chance of transmitting HIV to their babies.

People with HIV infection need to become educated about the disease and treatment so that they can be active participants in making decisions with their health care provider.

**Outlook Prognosis.** HIV is a chronic medical condition that can be treated, but not yet cured. There are effective ways to prevent complications and delay, but not always prevent, progression to AIDS.

Almost all people infected with HIV will develop AIDS if not treated. However, there is a small group of people who develop AIDS very slowly, or never at all. These patients are called long-term nonprogressors.

### **Possible Complications**

- Cancers
- Chronic wasting (weight loss) from HIV infection
- HIV dementia
- HIV lipodystrophy
- Opportunistic infections
  - Bacillary angiomatosis
  - Candidiasis
  - Cytomegalovirus infection
  - Cryptococcal infection
  - *Cryptosporidium* enterocolitis (or other protozoal infections)
  - *Mycobacterium avium* complex (MAC) infection
  - *Pneumocystis jiroveci* pneumonia (previously called *Pneumocystis carinii* pneumonia or PCP)
  - Salmonella infection in the bloodstream
  - Toxoplasmosis
  - Tuberculosis (in the lungs or spread throughout the body)
  - Viral infection of the brain (progressive multifocal leukoencephalopathy)

### **Prevention**

- Avoid injected illicit drugs. If you use injected drugs, avoid sharing needles or syringes. Always use new needles. (Boiling or cleaning them with alcohol does not guarantee that they're sterile and safe.)
- Avoid oral, vaginal, or anal contact with semen from HIV-infected people.
- Avoid unprotected anal intercourse, since it causes small tears in the rectal tissues, through which HIV in an infected partner's semen may enter directly into the other partner's blood.
- If you have sex with people who use injected drugs, always use protection.
- If you have sex with many people or with people who have multiple partners, always use protection.

- People with AIDS or who have had positive HIV antibody tests can pass the disease on to others. They should not donate blood, plasma, body organs, or sperm. They should not exchange genital fluids during sexual activity.
- Safer sex behaviors may reduce the risk of getting the infection. There is still a slight risk of getting the infection even if you practice "safe sex" by using condoms. Abstinence is the only sure way to prevent sexual transmission of the virus.
- Use protection when having sexual contact with people you know or suspect of being infected with HIV. Even better, use protection for ALL sexual contact.

## Oral thrush (Candidiasis – oral)

### Alternative Names

Candidiasis - oral; Oral thrush; Fungal infection - mouth; Candide - oral

Actinomycosis is a long-term (chronic) bacterial infection that commonly affects the face and neck.

Thrush is a yeast infection of the mucus membrane lining of the mouth and tongue.

### Call your doctor if:

- Infant has had lesions in the mouth consistent with thrush for at least 2 weeks.
- Infant is eating poorly due to the lesions.
- You are a teen or adult with lesions that are consistent with thrush.
- You have pain or difficulty swallowing.
- You have symptoms of thrush and you are HIV positive, receiving chemotherapy, or take medications to suppress your immune system.

**Causes.** Thrush is caused by forms of a fungus called *Candida*. A small amount of this fungus lives in your mouth most of the time. It is usually kept in check by your immune system and other types of germs that also normally live in your mouth.

However, when your immune system is weaker, the fungus can grow, leading to sores (lesions) in your mouth and on your tongue. The following can increase your chances of getting thrush:

- Taking steroid medications
- Having an HIV infection or AIDS
- Receiving chemotherapy for cancer or drugs to suppress your immune system following an organ transplant
- Being very old or very young

- Being in poor health

Thrush is commonly seen in infants. It is not considered abnormal in infants unless it lasts longer than a couple of weeks.

*Candida* can also cause yeast infections in the vagina.

People who have diabetes and had high blood sugar levels are more likely to get thrush in the mouth (oral thrush), because the extra sugar in your saliva acts like food for *Candida*.

Taking high doses of antibiotics or taking antibiotics for a long time also increases the risk of oral thrush. Antibiotics kill some of the healthy bacteria that help keep *Candida* from growing too much.

People with poorly fitting dentures are also more likely to get thrush.

**Symptoms.** Thrush appears as whitish, velvety lesions in the mouth and on the tongue. Underneath the whitish material, there is red tissue that may bleed easily. The lesions can slowly increase in number and size.

**Exams and Tests.** Your doctor or dentist can almost always diagnose thrush by looking at your mouth and tongue (fig. 29). These fungal lesions have a distinct appearance. If not entirely clear, one of the following tests may be performed to look for the *Candida* organisms:

- Microscopic examination of mouth scrapings
- Culture of mouth lesions

**Treatment.** For thrush in infants, treatment is often NOT necessary. It generally gets better on its own within 2 weeks.

If you develop a mild case of thrush after taking antibiotics, eating yogurt or taking over-the-counter acidophilus capsules can help.

Use a soft toothbrush and rinse your mouth with a diluted 3% hydrogen peroxide solution several times a day.

Good control of blood sugar levels in persons with diabetes may be all that is needed to clear a thrush infection.

Doctor may prescribe an antifungal mouthwash (nystatin) or lozenges (clotrimazole) to suck on if you have a severe case of thrush or a weakened immune system. These products are usually used for 5 - 10 days. If they don't work, other medication may be prescribed.

If the infection has spread throughout your body or you have HIV/AIDS, stronger medications may be used, such as fluconazole (Diflucan) or ketoconazole (Nizoral).

**Outlook Prognosis.** Thrush in infants may be painful, but is rarely serious. Because of discomfort, it can interfere with eating. If it does not resolve on its own within 2 weeks, call your pediatrician.

In adults, thrush that occurs in the mouth can be cured. However, the long-term outlook is dependent on your immune status and the cause of the immune deficit.

**Possible Complications.** If you have a weakened immune system (for example, if you are HIV-positive or receiving chemotherapy), *Candida* can spread throughout your body, causing infection in your esophagus (esophagitis), brain (meningitis), heart (endocarditis), joints (arthritis), or eyes (endophthalmitis).

**Prevention.** If you have frequent outbreaks of thrush, doctor may recommend taking antifungal medication on a regular basis to avoid recurrent infections.

If an infant with thrush is breastfeeding, talk to your doctor about ways to prevent future infections, such as an antifungal medication. Sterilize or discard any pacifiers. For bottle-fed babies with thrush, discard the nipples and buy new ones as the baby's mouth begins to clear.

To prevent spread of HIV infection, follow safe sex practices and universal precautions when working with blood products.

## Lichen planus

Lichen planus is a disease in which there is an itchy rash on the skin or in the mouth.

**Call your doctor if:**

- Your symptoms continue
- The skin or mouth lesions change in appearance
- The condition continues or worsens even with treatment
- Your dentist recommends adjusting your medications or treating conditions that trigger the disorder

**Causes.** The exact cause of lichen planus is unknown. However, it is likely to be related to an allergic or immune reaction.

Risks include:

- Exposure to medications, dyes, and other chemical substances (including gold, antibiotics, arsenic, iodides, chloroquine, quinacrine, quinide, phenothiazines, and diuretics)
- Disorders such as hepatitis C

Lichen planus generally affects middle-aged adults. It is less common in children.

### **Symptoms of mouth lesions:**

tender or painful (mild cases may have no discomfort); located on the sides of the tongue or the inside of the cheek; sometimes located on the gums; area of blue-white spots or "pimples"; lines of lesions that form a lacy-looking network; gradual increase in size of the affected area; lesions sometimes form painful ulcers.

**Skin lesions:** usually located on the inner wrist, legs, torso, or genitals; itchy; even on both sides (symmetrical); single lesion or clusters of lesions, often at sites of skin injury; papule 2 - 4 cm in size; papules clustered into a large, flat-topped lesion; lesions have distinct, sharp borders; possibly covered with fine white streaks or scratch marks called Wickham's striae; shiny or scaly appearance; dark colored -reddish-purple (skin) or gray-white (mouth); possibility of developing blisters or ulcers.

Other symptoms include: dry mouth; hair loss; metallic taste in the mouth; ridges in the nails (nail abnormalities).

### **Exams and Tests**

The health care provider may make the diagnosis based on the appearance of the skin or mouth lesions.

A skin lesion biopsy or biopsy of a mouth lesion can confirm the diagnosis. Blood tests may be done to rule out hepatitis.

**Treatment.** The goal of treatment is to reduce your symptoms and speed healing of the skin lesions. If symptoms are mild, you may not need treatment. Treatments may include:

- Antihistamines
- Immune-suppressing medications, such as cyclosporine (in severe cases)
- Lidocaine mouthwashes -- to numb the area and make eating more comfortable (for mouth lesions)
- Topical corticosteroids (such as clobetasol) or oral corticosteroids (such as prednisone) -- to reduce swelling and suppress immune responses. Corticosteroids may be injected right into a lesion.
- Topical retinoic acid cream (a form of vitamin A) and other ointments or creams -- to reduce itching and swelling and aid healing

- Topical immune-suppressing medications, such as tacrolimus and pimecrolimus -- but lesions must be watched carefully for signs of cancer
- Dressings may be placed over topical medications to protect the skin from scratching.
- Ultraviolet light therapy may be helpful in some cases.
- Oral retinoids (acitretin)

**Outlook Prognosis.** Lichen planus is usually not harmful and may get better with treatment. It usually clears up within 18 months.

However it may last for weeks to months, and may come and go for years. It usually clears up within 18 months.

If lichen planus is caused by a medication, the rash should go away once the medicine is stopped.

**Possible Complications.** Mouth ulcers that are there for a long time may develop into oral cancer.

## Mouth sores (Aphthous stomatitis)

### Alternative Names

Aphthous stomatitis

Different types of sores can appear anywhere in the mouth, including the inner cheeks, gums, tongue, lips, or palate.

### Call your doctor if:

- The sore begins soon after you start a new medication
- You have large white patches on the roof of your mouth or your tongue (this may be thrush or another type of infection)
- Your mouth sore lasts longer than 2 weeks
- You have a weakened immune system (for example, from HIV or cancer)
- You have other symptoms like fever, skin rash, drooling, or difficulty swallowing

### What to Expect at Your Office Visit

Doctor will perform a physical examination, focusing on your mouth and tongue. Medical history questions may include the following:

- Are the sores on your lips, gums, tongue, lining of your cheeks, or elsewhere?
- Are the sores open ulcers?

- Are there large, white patches on the roof of the mouth or on your tongue?
- How long have you had the mouth sores? More than 2 weeks?
- Have you ever had sores of this type before?
- What medications do you take?
- Do you have other symptoms like fever, sore throat, or breath odor?

**Causes.** Most mouth sores are cold sores (also called fever blisters), canker sores, or other irritation caused by:

- A sharp or broken tooth or poorly fitting dentures
- Biting your cheek, tongue, or lip
- Burning your mouth from hot food or drinks
- Braces
- Chewing tobacco

Cold sores are caused by the herpes simplex virus and are very contagious. Usually, you will have tenderness, tingling, or burning before the actual sore appears. Cold sores usually begin as blisters and then crust over.

The herpes virus can live in your body for years. It only appears as a mouth sore when something triggers it, such as:

- Another illness, especially if there is a fever
- Hormone changes (such as menstruation)
- Stress
- Sun exposure

Canker sores are NOT contagious. They can appear as a single pale or yellow ulcer with a red outer ring, or as a cluster of these sores. The cause of canker sores is not clear, but may be related to:

- A virus
- A temporary weakness in your immune system (for example, from the cold or flu)
- Hormone changes
- Irritation
- Stress
- Low levels of vitamin B12 or folate

For unknown reasons, women seem to get canker sores more often than men. This may be related to hormone changes.

Less commonly, mouth sores can be a sign of an illness, tumor, or reaction to a medication. Such illnesses can be grouped into several broad categories:

- Autoimmune disorders (including systemic lupus erythematosus)



- Bleeding disorders
- Cancer
- Infection (such as hand-foot-mouth disease)
- Weakened immune system -- for example, if you have AIDS or are taking medication after a transplant

Drugs that may cause mouth sores include:

aspirin, barbiturates (used for insomnia), chemotherapy drugs for cancer, gold (used for rheumatoid arthritis), penicillin, streptomycin, sulfonamides.

## **Home Care**

Mouth sores usually go away in 10 to 14 days, even if you don't do anything. They sometimes last up to 6 weeks. The following steps can make you feel better:

- Avoid hot beverages and foods, spicy and salty foods, and citrus.
- Gargle with cool water or eat popsicles. This is helpful if you have a mouth burn.
- Take pain relievers like acetaminophen.

For canker sores:

- Rinse with salt water.
- Apply a thin paste of baking soda and water.
- Mix 1 part hydrogen peroxide with 1 part water and apply this mixture to the sores using a cotton swab.
- For more severe cases, treatments include fluocinonide gel (Lidex), anti-inflammatory amlexanox paste (Aphthasol), or chlorhexidine gluconate (Peridex) mouthwash.

Nonprescription medications, such as Orabase, can protect a sore inside the lip and on the gums. Blistex or Campho-Phenique may provide some relief of canker sores and fever blisters, especially if applied when the sore first appears.

To help cold sores or fever blisters, you can also apply ice to the sore.

Doctor may recommend antiviral medications for herpes sores of the mouth. Some experts believe they make the blisters go away sooner, while others claim that these drugs make no difference.

Treatment may depend on the cause of the mouth sore.

- A topical anesthetic (applied to the skin) such as lidocaine or xylocaine may be used to relieve pain (but should be avoided in children).

- An antifungal medication may be prescribed for oral thrush (a yeast infection).
- An antiviral medication may be prescribed for herpes sores (although some experts don't believe medication will make the sores go away sooner)
- Anti-inflammatory medications may be prescribed for severe or persistent canker sores.

**Prevention.** You can reduce your chance of getting common mouth sores by:

- Avoiding very hot foods or beverages
- Reducing stress and practicing relaxation techniques like yoga or meditation

You can avoid irritation by:

- Chewing slowly
- Using a soft-bristle toothbrush
- Visiting your dentist right away if you have a sharp or broken tooth or misfitting dentures

If you seem to get canker sores often, talk to your doctor about taking folate and vitamin B12 to prevent outbreaks.

To prevent the spread of herpes sores, do not kiss or have oral sex with someone who has a cold sore or fever blister. Do not participate in these activities when you have an active cold sore. Do not share razors, lip balm, toothbrushes, or lipsticks.

To prevent cancerous mouth sores:

- Do not smoke or use tobacco.
- Limit alcohol to two drinks per day.
- Wear a wide-brimmed hat to shade your lips. Wear a lip balm with SPF 15 at all times.

## **Bruxism**

### **Alternative Names**

Teeth grinding and clenching

Bruxism is when you clench (tightly hold your top and bottom teeth together) or grind (slide your teeth back and forth over each other) your teeth.

**Causes.** People can clench and grind without being aware of it during both the day and night, although sleep-related bruxism is often the bigger problem because it is harder to control.

The cause of bruxism is not completely agreed upon, but daily stress may be the trigger in many people. Some people probably clench their teeth and never feel symptoms. Whether or not bruxism causes pain and other problems may be a complicated mix of factors:

- How much stress you are under
- How long and tightly you clench and grind
- Whether your teeth are misaligned
- Your posture
- Your ability to relax
- Your diet
- Your sleeping habits

Each person is probably different.

**Symptoms.** Clenching the teeth puts pressure on the muscles, tissues, and other structures around your jaw. The symptoms can cause temporomandibular joint problems (TMJ).

Grinding can wear down your teeth. Grinding can be noisy enough at night to bother sleeping partners. Symptoms include:

anxiety, stress, and tension; depression, earache (due in part because the structures of the temporomandibular joint are very close to the ear canal, and because you can feel pain in a different location than its source; this is called referred pain); eating disorders; headache; hot, cold, or sweet sensitivity in the teeth; insomnia; sore or painful jaw.

### **When to Contact a Medical Professional**

There is no recognized TMJ specialty in dentistry. See a dentist immediately if you are having trouble eating or opening your mouth. Keep in mind that a wide variety of possible conditions can cause TMJ symptoms, from arthritis to whiplash injuries. Therefore, see your dentist for a full evaluation if self-care measures do not help within several weeks.

Grinding and clenching does not fall clearly into one medical disciplines. For a massage-based approach, look for a massage therapist trained in trigger point therapy, neuromuscular therapy, or clinical massage.

Dentists who have more experience in evaluating and treating TMJ disorders will typically take x-rays and prescribe a mouth guard. Surgery is now considered a last resort for TMJ.

**Exams and Tests.** An examination can rule out other disorders that may cause similar jaw pain or ear pain, including:

dental disorders; ear disorders such as ear infections; problems with the temporomandibular joint (TMJ).

You may have a history of significant stress and tension.

**Treatment.** The goals of treatment are to reduce pain, prevent permanent damage to the teeth, and reduce clenching as much as possible.

- To help relieve pain, there are many self-care steps you can take at home. For example: Apply ice or wet heat to sore jaw muscles. Either can have a beneficial effect.
- Avoid eating hard foods like nuts, candies, steak.
- Drink plenty of water every day.
- Get plenty of sleep.
- Learn physical therapy stretching exercises to help restore a normal balance to the action of the muscles and joints on each side of the head.
- Massage the muscles of the neck, shoulders, and face. Search carefully for small, painful nodules called trigger points that can cause pain throughout the head and face.
- Relax your face and jaw muscles throughout the day. The goal is to make facial relaxation a habit.
- Try to reduce your daily stress and learn relaxation techniques.

To prevent damage to the teeth, mouth guards or appliances (splints) have been used since the 1930s to treat teeth grinding, clenching, and TMJ disorders. A splint may help protect the teeth from the pressure of clenching.

A splint may also help reduce clenching, but some people find that it makes their clenching worse. In others, the symptoms go away as long as they use the splint, but pain returns when they stop or the splint loses its effectiveness over time.

There are many different types of splints. Some fit over the top teeth, some on the bottom. They may be designed to keep your jaw in a more relaxed position or provide some other function. If one type doesn't work, another may.

For example, a splint called the NTI-tss fits over just the front teeth. The idea is to keep all of your back teeth (molars) completely separated, under the theory that most clenching is done on these back teeth. With the NTI, the only contact is between the splint and a bottom front tooth.

As a next phase after splint therapy, orthodontic adjustment of the bite pattern may help some people. Surgery should be considered a last resort.

Finally, there have been many approaches to try to help people unlearn their clenching behaviors. These are more successful for daytime clenching, since nighttime clenching cannot be consciously stopped.

In some people, just relaxing and modifying daytime behavior is enough to reduce nighttime bruxism. Methods to directly modify nighttime clenching have not been well studied. They include biofeedback devices, self-hypnosis, and other alternative therapies.

**Outlook Prognosis.** Bruxism is not a dangerous disorder. However, it can cause permanent damage to the teeth and uncomfortable jaw pain, headaches, or ear pain.

**Possible Complications:** depression, eating disorders, insomnia, increased dental or TMJ problems.

Nightly grinding can awaken roommates and sleeping partners.

**Prevention.** Stress reduction and anxiety management may reduce bruxism in people prone to the condition.

## Gum biopsy

### Alternative Names

Biopsy - gingiva (gums)

A gum biopsy is a surgery in which a small piece of gingival (gum) tissue is removed for examination.

### How the Test is Performed

A painkiller is sprayed into the mouth in the area of the abnormal gum tissue. In some cases, a numbing injection may be used. A small piece of the gum tissue that appears abnormal is removed and checked for problems in the laboratory.

### How to Prepare for the Test

There is no special preparation, although you may be told not to eat for a few hours before the biopsy.

### How the Test Will Feel

The topical anesthetic should numb the area during the procedure, although some tugging or pressure may be felt. If there is bleeding, the blood vessels may be sealed off with an electric current or laser. This is called electrocauterization. After the numbness wears off, the area may be sore for a few days.

### Why the Test is Performed

This test is done to determine the cause of abnormal gum tissue.

## **Normal Results**

This test is only performed when there is an abnormality.

Note: Normal value ranges may vary slightly among different laboratories. Talk to your doctor about the meaning of your specific test results.

## **What Abnormal Results Mean**

- Amyloid
- Noncancerous mouth sores (the specific cause can be determined in many cases)
- Oral cancer (for example, squamous cell carcinoma)
- Thrombotic thrombocytopenic purpura (TTP)

**Risks:** bleeding from the biopsy site; infection of the gums; soreness.

**Considerations.** Avoid brushing the biopsy area for 1 week.

# **Salivary Gland Disorders. Head and neck glands**

Your salivary glands make saliva - sometimes called spit - and empty it into your mouth through openings called ducts (fig.30). Saliva makes your food moist, which helps you chew and swallow. It helps you digest your food. It also cleans your mouth and contains antibodies that can kill germs.

Problems with salivary glands can cause the glands to become irritated and swollen. This causes symptoms such as

- Bad taste in the mouth
- Difficulty opening your mouth
- Dry mouth
- Pain in the face or mouth
- Swelling of the face or neck

Causes of salivary gland problems include infections, obstruction or cancer. Problems can also be due to other disorders, such as mumps or Sjogren's syndrome.

## **Drooling (Salivation)**

Drooling is saliva flowing outside the mouth.

## **Call your doctor if:**

- The cause of the drooling has not been diagnosed.
- There is concern about aspiration.
- Your child has a fever, difficulty breathing, or holds his or her head in a strange position.

## **What to Expect at Office Visit**

The doctor will do a physical examination and ask questions about the symptoms, including:

- Is there a history of any other diseases?
- Has the person had a bite or sting?
- Has the person had an injury?
- What medications is the person taking?
- What other symptoms are present (such as fever, sore throat, facial droop)?

Drooling is generally caused by: problems keeping saliva in the mouth; problems with swallowing; too much saliva production.

Some people with drooling problems are at increased risk of breathing saliva, food, or fluids into the lungs. This may cause harm if there is a problem with the body's normal reflexes (such as gagging and coughing).

Drooling caused by nervous system (neurologic) problems can often be managed with drugs that block the action of the chemical messenger acetylcholine (anticholinergic drugs). In severe cases, people can reduce drooling by injecting botulism toxin, getting high-energy x-rays (radiation) to the glands in the mouth that make saliva (salivary glands), and other methods.

**Causes.** Some drooling in infants and toddlers is normal and is not usually a sign of a disease or other problem. It may occur with teething. Drooling in infants and young children may get worse with upper respiratory infections and nasal allergies.

Drooling that occurs with fever or trouble swallowing may be a sign of a more serious disease, including:

mononucleosis, peritonsillar abscess, retropharyngeal abscess, strep throat, tonsillitis.

Sudden drooling may occur with poisoning (especially by pesticides) or a reaction to snake or insect venom.

Other things that can cause drooling:

- Certain medications
- Nervous system (neurological) problems

**Home Care.** Care for drooling due to teething includes good oral hygiene. Popsicles or other cold objects (such as frozen bagels) may be helpful. Take care to avoid choking when a child uses any of these objects.

The tests performed depend on the symptoms that occur with the drooling.

## Salivary duct stones (Sialolithiasis)

### Alternative Names

Sialolithiasis

Salivary duct stones are crystallized minerals in the ducts that drain the salivary glands. Salivary duct stones are a type of salivary gland disorder.

### Causes

Saliva (spit) is produced by the salivary glands in the mouth. The chemicals in saliva can crystallize into a stone that can block the salivary ducts.

When saliva cannot exit a blocked duct, it backs up into the gland, causing pain and swelling of the gland.

Salivary stones most often affect the submandibular glands (at the back of the mouth on both sides of the jaw), but they can also affect the parotid glands (on the sides of the face).

**Symptoms:** difficulty opening the mouth or swallowing; dry mouth; pain in the face or mouth; swelling of the face or neck (can be dramatic when eating or drinking).

The symptoms are usually most noticeable when eating or drinking.

**Exams and Tests.** An examination of the head and neck by the health care provider or dentist shows one or more enlarged, tender salivary glands. The doctor may be able to feel the stone during examination.

X-rays, ultrasound, or CT scan of the face can confirm the diagnosis.

**Treatment.** The goal is to remove the stone. The doctor or dentist may be able to push the stone out of the duct. In some cases, the stone may need to be surgically cut out.



Most often, the stone can be flushed out by increasing the flow of saliva with sour candy or citrus (which stimulate the flow of saliva) combined with increased fluids and massage.

**Call your doctor** if you have symptoms of salivary duct stones.

**Outlook Prognosis.** Salivary duct stones are uncomfortable, but not dangerous. The stone is usually removed with only minimal discomfort.

If the person has repeated stones or infections, the affected salivary gland may need to be surgically removed.

**Possible Complications:** discomfort, increased risk of salivary gland infections; recurrence (coming back) of stones.

## Salivary gland biopsy

### Alternative Names

Biopsy - salivary gland

Salivary gland biopsy is the removal of a small piece of tissue or cells from a salivary gland for examination.

### How the Test is Performed

There are several pairs of salivary glands in different locations in the mouth: a major pair in front of the ears (parotid glands); two major pairs on the floor of the mouth; and several minor pairs within the lips, cheeks, and tongue.

One method of salivary gland biopsy is a needle biopsy. The skin over the gland is cleaned with rubbing alcohol. A local anesthetic may be injected, and a needle is inserted into the gland. A piece of tissue or cells are removed and placed on slides, which are sent to a laboratory for examination.

A biopsy can also be done to determine the type of tumor in a salivary gland lump and to determine if the gland and tumor need to be removed.

A biopsy of the glands in the lips or the parotid gland can also be performed to diagnose diseases such as Sjogren syndrome.

### How to Prepare for the Test

For a needle biopsy, there is no special preparation, although you may be asked not to drink or eat anything for a few hours beforehand. For surgical excision of a

tumor, preparation is like that for any major surgery, including fasting for 6 to 8 hours prior.

### **How the Test Will Feel**

During a needle biopsy, there may be some stinging or burning if a local anesthetic is injected. Insertion of the biopsy needle may cause pressure or mild discomfort which should only last for 1 or 2 minutes. Afterward, the area may feel tender or be bruised for a few days.

The biopsy for Sjogren syndrome will involve injection of the anesthetic in the lip or in the front of the ear and there will be stitches in the location(s) involved.

### **Why the Test is Performed**

This test is done to determine the cause of abnormal lumps or growths of the salivary glands and to diagnose Sjogren syndrome.

### **Normal Results**

There is normal salivary gland tissue anatomy with no abnormal growths or inclusions.

Note: Normal value ranges may vary slightly among different laboratories.

Talk to your patient about the meaning of this specific test results.

### **What Abnormal Results Mean**

- Salivary gland tumors
- Sjogren syndrome

**Risks:** allergic reaction to the anesthetic; bleeding, infection, injury to the facial or trigeminal nerve (rare); numbness of the lip.

## **Sjogren's Syndrome**

Sjogren's syndrome is a disease that causes dryness in your mouth and eyes. It can also lead to dryness in other places that need moisture, such as your nose, throat and skin. Most people who get Sjogren's syndrome are older than 40. Nine of 10 are women. Sjogren's syndrome is sometimes linked to rheumatic problems such as rheumatoid arthritis.

Sjogren's syndrome is an autoimmune disease. If you have an autoimmune disease, your immune system, which is supposed to fight disease, mistakenly attacks parts of your own body. In Sjogren's syndrome, your immune system attacks the glands

that make tears and saliva. It may also affect your joints, lungs, kidneys, blood vessels, digestive organs and nerves. The main symptoms are:

- Dry eyes
- Dry mouth

Treatment focuses on relieving symptoms.

## Salivary gland tumors

### Alternative Names

Tumor - salivary duct

Salivary gland tumors are abnormal cells growing in the ducts that drain the salivary glands.

**Causes.** The salivary glands are located around the mouth. They produce saliva, which moistens food to help with chewing and swallowing.

Saliva contains enzymes that begin the digestion process, and help cleanse the mouth by washing away bacteria and food particles. By keeping the mouth moist, saliva helps to keep dentures, retainers, or other orthodontic appliances in place.

There are three pairs of major salivary glands. The largest are the parotid glands, located in each cheek over the jaw in front of the ears. Two submandibular glands are at the back of the mouth on both sides of the jaw. Two sublingual glands are under the floor of the mouth. There are also thousands of minor salivary glands around the rest of the mouth.

All of the salivary glands empty saliva into the mouth through ducts that open at various locations in the mouth.

Salivary gland tumors are rare, especially in children. Swelling of the salivary glands is most commonly due to:

- Abdominal surgery
- Cirrhosis of the liver
- Infections
- Other cancers
- Salivary duct stones
- Salivary gland infections
- Sarcoidosis
- Sjogren syndrome

The most common type of salivary gland tumor is a slow-growing noncancerous (benign) tumor of the parotid gland that gradually increases the size of the gland. However, some of these tumors can be cancerous (malignant).

Malignant salivary gland tumors are usually carcinomas.

### **Symptoms**

- A firm, usually painless swelling in one of the salivary glands (in front of the ears, under the chin, or on the floor of the mouth); the size of the swelling gradually increases.
- Difficulty moving one side of the face, known as facial nerve palsy

**Exams and Tests.** An examination by a dentist shows a larger-than-normal salivary gland, usually one of the parotid glands.

Tests may include:

- X-rays of the salivary gland (called a sialogram or sialogram) to look for a tumor
- CT scan or MRI to confirm that there is a growth, and to see if the cancer has spread to lymph nodes in the neck
- Salivary gland biopsy or fine needle aspiration to determine whether the tumor is benign or malignant

**Treatment.** The recommended treatment is usually surgery to remove the affected salivary gland. If the tumor is benign, no other treatment is usually needed.

Radiation therapy or extensive surgery may be needed if the tumor is cancerous. Chemotherapy is sometimes used in patients who are considered high risk, or when the disease has spread beyond the salivary glands.

**Call the doctor if:**

- You have pain when eating or chewing
- You notice a lump in the mouth, under the jaw, or in the neck that does not go away in 2 - 3 weeks or is getting larger

**Outlook Prognosis.** Most salivary gland tumors are noncancerous and slow growing. Removing the tumor with surgery usually cures the condition. In rare cases, the tumor is cancerous and further treatment is needed.

### **Possible Complications**

- Cancerous tumors may cause further complications, including spread to other organs (metastasis).

- Rarely, surgery to remove the tumor can injure the nerve that controls movement of the face.

## Salivary gland infections (Parotitis; Sialadenitis)

Salivary gland infections are viral or bacterial infections of the saliva-producing glands.

There are three pairs of major salivary glands.

- The two largest are the parotid glands, one in each cheek over the jaw in front of the ears. Inflammation of one or more of these glands is called parotitis, or parotiditis.
- Two submandibular glands are at the back of the mouth on both sides of the jaw.
- Two sublingual glands are under the floor of the mouth.

All of the salivary glands empty saliva into the mouth through ducts that open at various locations in the mouth.

**Causes.** Salivary gland infections are somewhat common.

Viral infections such as mumps often affect the salivary glands (mumps most often causes parotiditis). This type of infection is now considerably rare in children because of the MMR vaccine.

Bacterial infections usually result from obstruction (such as salivary duct stones) or poor oral hygiene. They can be seen in people who are dehydrated and hospitalized.

**Symptoms:** abnormal tastes, foul tastes; decreased ability to open the mouth; dry mouth; fever, mouth or facial pain, especially when eating; redness over the side of the face or the upper neck; swelling of the face (particularly in front of the ears, below the jaw, or on the floor of the mouth).

### Exams and Tests

An examination by the health care provider or dentist shows enlarged salivary glands. Pus may drain into the mouth. The gland may be painful, particularly with bacterial infections. Viral infections such as mumps may cause painless swelling of the glands. A CT scan or ultrasound may be done if the doctor suspects an abscess.

### Treatment

In some cases, no treatment is necessary.

If there is pus or a fever, or if the infection is known or thought to be bacterial, antibiotics may be prescribed. Antibiotics are not effective against viral infections.

If there is an abscess, surgical drainage or aspiration may be done.

Good oral hygiene, with thorough tooth brushing and flossing at least twice per day, may aid healing and help prevent an infection from spreading. If you are a smoker, stop smoking as it helps in recovery.

Warm salt water rinses (1/2 teaspoon of salt in one cup of water) may be soothing and keep the mouth moist.

Drink lots of water and use sugar-free lemon drops to increase the flow of saliva and reduce swelling. Massaging the gland with heat may help.

**Call your doctor** if you have symptoms of a salivary gland infection.

Call the doctor if you've been diagnosed with a salivary gland infection and symptoms worsen, particularly if fever increases, or there is breathing or swallowing difficulty (these may be emergency symptoms).

**Outlook Prognosis.** Most salivary gland infections go away on their own or are cured with treatment. Complications are not common, but they may occur.

**Possible Complications:** abscess of salivary gland; localized spread of bacterial infection (cellulitis, Ludwig's angina); recurrence of infection.

**Prevention.** In many cases, salivary gland infections cannot be prevented. Good oral hygiene may prevent some cases of bacterial infection.

## Salivary Gland Cancer

Your salivary glands make saliva - sometimes called spit - and empty it into your mouth through openings called ducts. Saliva makes your food moist, which helps you chew and swallow. It helps you digest your food. It also cleans your mouth and contains antibodies that can kill germs.

Salivary gland cancer is a rare disease in which cancer cells form in the tissues of the salivary glands. It may not cause any symptoms, or you could notice:

- A lump in your ear, cheek, jaw, lip, or inside the mouth
- Fluid draining from your ear
- Trouble swallowing or opening the mouth widely
- Numbness, weakness, or pain in your face

Treatment can include surgery, radiation therapy, and/or chemotherapy.

## Sialogram (Sialography)

A sialogram is an x-ray of the salivary ducts and glands.

The salivary glands are located on each side of the face and send saliva into the mouth.

### **How the Test is Performed**

The test is performed in a hospital radiology department or in the health care provider's office by an x-ray technician. You may be given a sedative before the procedure.

You will be asked to lie on your back on the x-ray table. An x-ray is taken before the contrast material is injected to ensure that no stones are present to stop the contrast material from entering the ducts.

A catheter (a small flexible tube) will be inserted through your mouth and into the duct of the salivary gland. A contrast medium is then injected into the duct so that the duct will show up on the x-ray. X-rays will be taken from a number of positions.

You may be given lemon juice by mouth to help stimulate the production of saliva. Pictures are repeated to examine the drainage of the saliva into the mouth.

### **How to Prepare for the Test**

Inform your doctor if you are:

- Pregnant
- Allergic to x-ray contrast material or any iodine substance
- Allergic to any drugs

You must sign a consent form. You will need to rinse your mouth with an antiseptic (germ-killing) solution before the procedure.

### **How the Test Will Feel**

There is some discomfort or pressure when the contrast material is injected into the ducts. The contrast material may taste unpleasant.

**Why the Test is Performed.** A sialogram may be done when your doctor thinks you might have a disorder of the salivary ducts or glands.

**What Abnormal Results Mean.** Abnormal results may suggest:

- Narrowing of the salivary ducts
- Salivary gland infection or inflammation
- Salivary duct stones
- Salivary duct tumor

**Risks.** There is low radiation exposure. X-rays are monitored and regulated to provide the minimum amount of radiation exposure needed to produce the image. Most experts feel that the risk is low compared with the benefits. Pregnant women and children are more sensitive to the risks of x-rays.

## Face pain

Face pain may be dull and throbbing or an intense, stabbing discomfort in one or both sides of the face or forehead.

### Considerations

Pain that starts in the face may be caused by a nerve disorder, an injury, or an infection in a structure of the face. Face pain may also begin elsewhere in the body.

Sometimes face pain occurs for no known reason.

### When to Contact a Medical Professional

- Face pain is accompanied by chest, shoulder, neck, or arm pain. This could mean a heart attack.
- Pain is throbbing, worse on one side of the face, and aggravated by eating. Call a dentist.
- Pain is persistent, unexplained, or accompanied by other unexplained symptoms. Call your doctor.

### What to Expect at Office Visit

In emergency situations (such as a possible heart attack), you will first be stabilized. For tooth problems, expect a referral to a dentist.

Following questions for your patient:

- What part of your face is in pain?
- Is the pain on both sides?
- If the pain is only on one side, which side is it on?
- Is the pain over a sinus (forehead, cheekbones)?
- Did the pain begin suddenly?
- Is face pain occurring repeatedly (is it recurrent)?



- How long have the episodes of face pain lasted (for how many months)?
- How long does each episode of pain last (how many seconds)?
- Is the pain worse when speaking, chewing, or swallowing?
- Does the pain develop when touching a specific part of the face (trigger point)?
- Did face pain occur before the start of a brain or nervous system problem (weakness, speech loss)?
- What other symptoms do you have?

### **Causes:**

- abscessed tooth (continuous throbbing pain on one side of the lower face aggravated by eating or touching);
- cluster headache;
- herpes zoster (shingles) or herpes simplex (cold sores) infection;
- injury to the face;
- migraine,
- myofascial pain syndrome;
- sinusitis or sinus infection (dull pain and tenderness around the eyes and cheekbones that worsens when bending forward);
- tic douloureux;
- temporomandibular joint dysfunction syndrome.

**Home Care.** Follow the treatment prescribed for the cause of the pain.

Painkillers may provide temporary relief. If the pain is severe or persistent, call your primary health care provider or dentist.

Diagnostic tests that may be performed include:

- Dental x-rays (if a tooth problem is suspected)
- ECG (if heart problems are suspected)
- Tonometry (if glaucoma is suspected)
- X-rays of the sinuses

Neurological tests will be performed if nerve damage is suspected.

## **Shingles (Herpes zoster)**

Shingles (herpes zoster) is a painful, blistering skin rash due to the varicella-zoster virus, the virus that causes chickenpox.

**Causes.** After you get chickenpox, the virus remains inactive (becomes dormant) in certain nerves in the body. Shingles occurs after the virus becomes active again in these nerves years later.

The reason the virus suddenly become active again is not clear. Often only one attack occurs.

Shingles may develop in any age group, but you are more likely to develop the condition if:

- You are older than 60
- You had chickenpox before age 1
- Your immune system is weakened by medications or disease

If an adult or child has direct contact with the shingles rash on someone and has not had chickenpox as a child or a chickenpox vaccine, they can develop chickenpox, rather than shingles.

**Symptoms.** The first symptom is usually one-sided pain, tingling, or burning. The pain and burning may be severe and is usually present before any rash appears.

Red patches on the skin, followed by small blisters, form in most people.

- The blisters break, forming small ulcers that begin to dry and form crusts. The crusts fall off in 2 to 3 weeks. Scarring is rare.
- The rash usually involves a narrow area from the spine around to the front of the belly area or chest.
- The rash may involve face, eyes, mouth, and ears.

**Additional symptoms** may include:

abdominal pain; chills, difficulty moving some of the muscles in the face; drooping eyelid (ptosis); fever and chills; general ill-feeling; genital lesions; headache, hearing loss; joint pain; loss of eye motion; swollen glands (lymph nodes); taste problems; vision problems.

You may also have pain, muscle weakness, and a rash involving different parts of your face if shingles affects a nerve in your face.

**Call your doctor** if you have symptoms of shingles, particularly if you have a weakened immune system or if your symptoms persist or worsen. Shingles that affects the eye may lead to permanent blindness if you do not receive emergency medical care.

**Exams and Tests.** Doctor can make the diagnosis by looking at patient`s skin and asking questions about medical history.

Tests are rarely needed, but may include taking a skin sample to see if the skin is infected with the virus that causes shingles.

Blood tests may show an increase in white blood cells and antibodies to the chickenpox virus but cannot confirm that the rash is due to shingles.

**Treatment.** Your doctor may prescribe a medicine that fights the virus, called an antiviral. The drug helps reduce pain and complications and shorten the course of the disease. Acyclovir, famciclovir, and valacyclovir may be used.

The medications should be started within 24 hours of feeling pain or burning, and preferably before the blisters appear. The drugs are usually given in pill form, in doses many times greater than those recommended for herpes simplex or genital herpes. Some people may need to receive the medicine through a vein (by IV).

Strong anti-inflammatory medicines called corticosteroids, such as prednisone, may be used to reduce swelling and the risk of continued pain. These drugs do not work in all patients.

Other medicines may include:

- Antihistamines to reduce itching (taken by mouth or applied to the skin)
- Pain medicines
- Zostrix, a cream containing capsaicin (an extract of pepper) that may reduce the risk of postherpetic neuralgia

Cool wet compresses can be used to reduce pain. Soothing baths and lotions, such as colloidal oatmeal bath, starch baths, or calamine lotion, may help to relieve itching and discomfort.

Resting in bed until the fever goes down is recommended.

The skin should be kept clean, and contaminated items should not be reused. Nondisposable items should be washed in boiling water or otherwise disinfected before reuse. The person may need to be isolated while lesions are oozing to prevent infecting other people who have never had chickenpox -- especially pregnant women.

**Outlook Prognosis.** Herpes zoster usually clears in 2 to 3 weeks and rarely recurs. If the virus affects the nerves that control movement (the motor nerves), you may have temporary or permanent weakness or paralysis.

### **Possible Complications.**

Sometimes, the pain in the area where the shingles occurred may last for months or years. This pain is called postherpetic neuralgia. It occurs when the nerves have been damaged after an outbreak of shingles. Pain ranges from mild to very severe pain. It is more likely to occur in people over 60 years.

Other complications may include:

- Another attack of shingles
- Blindness (if shingles occurs in the eye)
- Deafness
- Infection, including encephalitis or sepsis (blood infection) in persons with weakened immune systems
- Bacterial skin infections
- Ramsay Hunt syndrome if shingles affected the nerves in the face

**Prevention.** Avoid touching the rash and blisters of persons with shingles or chickenpox if you have never had chickenpox or the chickenpox vaccine.

A herpes zoster vaccine is available. It is different than the chickenpox vaccine. Older adults who receive the herpes zoster vaccine are less likely to have complications from shingles. Adults older than 60 should receive the herpes zoster vaccine as part of routine medical care.

## Peritonsillar abscess

Peritonsillar abscess is a collection of infected material in the area around the tonsils.

**Causes.** Peritonsillar abscess is a complication of tonsillitis. It is most often caused by a type of bacteria called *group A beta-hemolytic streptococcus*.

Peritonsillar abscess is usually a disease of older children, adolescents, and young adults. It has become uncommon with the use of antibiotics to treat tonsillitis.

**Symptoms.** One or both tonsils become infected. The infection may spread over the roof of the mouth (palate), and to the neck and chest, including the lungs. Swollen tissues may block the airway, which is a life-threatening medical emergency.

The abscess can break open (rupture) into the throat, infecting or further blocking the airway. **Symptoms** of peritonsillar abscess include:

chills, difficulty opening the mouth, and pain with opening the mouth; difficulty swallowing; drooling or inability to swallow saliva; facial swelling; fever, headache, muffled voice; sore throat (may be severe and is usually on one side); tender glands of the jaw and throat.

**Call your doctor** if you have had tonsillitis and you develop symptoms of peritonsillar abscess and difficulty breathing; difficulty swallowing; pain in the chest; persistent fever; symptoms that get worse.

**Exams and Tests.** An examination of the throat often shows swelling on one side and on the roof of the mouth.

The uvula in the back of the throat may be shifted away from the swelling. The neck and throat may be red and swollen on one or both sides.

The following tests may be done: aspiration of the abscess, CT scan.

**Treatment.** If the infection is caught early, you will be given antibiotics. More likely, if an abscess has developed, it will need to be drained with a needle or by cutting it open.

Sometimes, the abscess may be drained and the tonsils removed at the same time. You will be prescribed painkillers.

### **Outlook Prognosis**

Peritonsillar abscess usually goes away with treatment, although the infection may return in the future.

**Possible Complications:** airway obstruction; cellulitis of the jaw, neck, or chest; endocarditis (rare); fluid around the lungs (pleural effusion); inflammation around the heart (pericarditis); pneumonia.

**Prevention.** Quickly and completely treating tonsillitis, especially bacterial tonsillitis, may help prevent an abscess.

## **SPREAD OF ORAL INFECTIONS. Cellulitis ( Phlegmon )**

### **Infection spread via tissue spaces**

**Cellulitis ( Phlegmon )** Definition : Cellulitis is a diffuse inflammation of connective tissue with severe inflammation of dermal and subcutaneous layers of the skin . It is a spreading diffuse inflammatory process with formation of suppurative/purulent exudate or pus.

Cellulitis can be caused by normal skin flora or by exogenous bacteria

[ streptococcus and/or staphylococcus bacteria] .

Often occurs where the skin has previously been broken: cracks in the skin, cuts, blisters , burns , insect bites , surgical wounds , or sites of intravenous catheter insertion.

Skin on the face is most commonly affected by this infection, though cellulitis can occur on any part of the body.

The mainstay of therapy remains treatment with appropriate antibiotics, and recovery periods can be anything from 48 hours to six months.

**Introduction.** It appears as localized inflammation of the skin and is characterized by redness ( erythema ), swelling (edema), tenderness or pain, and warmth

Cellulitis can remain a superficial infection or spread into the soft tissues immediately below the skin that contain blood vessels, lymphatic vessels, and nerves.

It can also involve the underlying muscle or spread throughout the body via the lymphatic system and the bloodstream.

Cellulitis is unrelated (except etymologically) to cellulite, a cosmetic condition featuring dimpling of the skin.

**Risk:** Age is not generally considered a risk factor for cellulites, although some studies show slightly higher incidence in individuals over age 45.

Individuals who are immunodeficient as a result of genetic conditions, illness (e.g., HIV infection, cancer ), or immunosuppressive drugs (e.g., chemotherapy , corticosteroids, antirejection drugs in transplant recipients) are at increased risk of infections such as cellulitis.

Diabetes impairs the immune system and decreases blood circulation, increasing risk of infection.

Chronic skin conditions such as psoriasis, dermatitis , or eczema can create an opportunity for entry of infectious bacteria. Individuals who have recurrent fungal infections of the feet are greater risk for developing cellulitis.

Impaired peripheral circulation such as arterial insufficiency or venous stasis is also a risk factor.

Subcutaneous or intravenous drug injection, body piercing, and tattoos are all associated with higher risk for cellulitis.

Cellulitis may also occur as a complication of certain surgical procedures ( hip replacement, liposuction , breast surgery , vein surgery).

**Incidence and Prevalence.** Cellulitis can affect anyone of any age; cellulitis of the face is more common in children and adults over age 50 (Cunningham).

The actual incidence of cellulitis is unknown because cases are seldom reported.

The incidence of infection by methicillin-resistant *Staphylococcus aureus* (MRSA) and other antibiotic-resistant bacteria has increased dramatically in recent years (Mayo Clinic Staff). Infection by these organisms is much more serious.

### **History:**

The individual may complain of a red, hot, swollen, and tender area of skin.

Symptoms may also include fever or chills.

The individual may report a recent history of trauma or a bite at the affected site.

The individual who complains of redness and swelling of the eyelid may also report eye pain, impaired eye mobility, and visual changes.

### **Physical exam:**

The appearance of red, swollen, tender skin that is warm to the touch is usually sufficient for diagnosis.

The texture of the skin may resemble orange peel (peau d'orange) and be firm to the touch. Regional lymph nodes may be inflamed and swollen.

Adjacent skin may reveal red streaks characteristic of inflamed lymphatic vessels (lymphangitis).

If the lower leg is affected, symptoms (warmth, pain, and swelling) may mimic those of clot formation in leg veins (venous thrombosis).

Individuals with orbital cellulitis should undergo a thorough examination of the face, sinuses, teeth, mouth, and nasopharynx to identify the source of infection.

### **Tests:**

A complete blood count may be performed to determine the level of white blood cells, a sensitive marker of infection.

Cultures of pus or other drainage from the area of infection and/or blood cultures may be performed to identify the causative organism(s).

Often, the causative agent is not identified, or the report shows multiple skin organisms that may include normal flora.

Antibiotic sensitivity tests may be performed on the cultured organisms to aid in determining the most appropriate antibiotic therapy.

Individuals with orbital cellulitis may require imaging studies ( x-rays , CT , or MRI of the sinuses) to localize the source of infection.

### **Cellulitis: initial stage of infection**

Diffuse, reddened, soft or hard swelling that is tender to palpation.

Inflammatory response not yet forming a true abscess.

Microorganisms have just begun to overcome host defenses and spread beyond tissue planes.

### **True abscess formation**

As inflammatory response matures, may develop a focal accumulation of pus.

May have spontaneous drainage intraorally or extraorally.

### **Clinical Features**

Systemic features of infection such as increased body temperature (up to 38-40 °C), general fatigue, chills, sweatings, headache, loss of appetite).

Inflammatory signs - dolor (localized pain), calor (increase local tissue temperature), rubor (skin redness/hyperemia), tumor (either clear or non-clear bordered tissue swelling), functio laesa (diminish affected function).

### **Causes**

Cellulitis is caused by a type of bacteria entering the skin, usually by way of a cut, abrasion, or break in the skin. This break does not need to be visible. Group A Streptococcus and Staphylococcus are the most common of these bacteria, which are part of the normal flora of the skin but cause no actual infection while on the skin's outer surface.

Predisposing conditions for cellulitis include insect bites, blistering , animal bite, tattoos , pruritic (itchy) skin rash, recent surgery , athlete's foot , dry skin , eczema , injecting drugs (especially subcutaneous or intramuscular injection or where an attempted IV injection "misses" or blows the vein), pregnancy, diabetes and obesity, which can affect circulation, as well as burns and boils , though there is debate as to whether minor foot lesions contribute. Spider bites are also known to cause cellulitis.



Occurrences of cellulitis may also be associated with the rare condition Hidradenitis Suppurativa .

The photos shown here of Cellulitis are of mild cases and are not representative of earlier stages of the disease. Usually the itch and/or rash appears a little after it vanishes leaving only a small mark which is commonly ignored.

The appearance of the skin will assist a doctor in determining a diagnosis. A doctor may also suggest blood tests, a wound culture or other tests to help rule out a blood clot deep in the veins of the legs. Cellulitis in the lower leg is characterized by signs and symptoms that may be similar to those of a clot occurring deep in the veins, such as warmth, pain and swelling (inflammation).

This reddened skin or rash may signal a deeper, more serious infection of the inner layers of skin. Once below the skin, the bacteria can spread rapidly, entering the lymph nodes and the bloodstream and spreading throughout the body. This can result in flu like symptoms with a high temperature and sweating or feeling very cold with shaking as the sufferer cannot get warm.

In rare cases, the infection can spread to the deep layer of tissue called the fascial lining. Necrotizing fasciitis, also called by the media &quot;flesh-eating bacteria,&quot; is an example of a deep-layer infection. It represents an extreme medical emergency.

## **Histological features**

A microscopic section through an area of cellulitis shows a diffuse exudation of polymorphonuclear leukocyte and lymphocyte. With considerable serous fluid and fibrins causing separation of connective tissue and muscle fibres.

## **Treatment**

Treatment consists of resting the affected area, cutting away dead tissue, and antibiotics (either oral or intravenous).

Flucloxacillin or Dicloxacillin monotherapy (to cover staphylococcal infection) is often sufficient in mild cellulitis, but in more moderate cases, or where streptococcal infection is suspected, then this course is usually combined with oral phenoxymethylpenicillin or intravenous benzylpenicillin, or ampicillin / amoxicillin

Pain relief is also often prescribed, but excessive pain should always be investigated as it is a symptom of necrotising fasciitis.

As in other maladies characterized by wounds or tissue destruction, hyperbaric oxygen treatment can be a valuable adjunctive therapy, but is not widely available.

## **Prognosis**

Antibiotic therapy usually provides prompt and complete resolution of cellulitis. If left untreated, cellulitis can occasionally kill the tissue (gangrene), and/or the bacteria may enter the bloodstream (bacteremia) and multiply, causing a serious, systemic, life-threatening condition (sepsis).

## **Complications**

Cellulitis can progress to lymphangitis, abscess formation, or sepsis. Infection by additional species of bacteria (superinfection) may occur, complicating treatment. Infection can also spread to the layer of tissue enveloping muscles (fascia), causing a serious infection (necrotizing fasciitis) Cellulitis of the scalp may cause scarring, leading to hair loss (alopecia).

Orbital cellulitis may progress to blindness, cavernous sinus clots (thrombosis), or inflammation of all tissues of the eye (panophthalmitis).

Infection may spread from the orbit to the brain or tissues lining the brain and spinal cord (meninges).

Older individuals may develop a blood clot ( thrombophlebitis ) as a result of cellulitis in more superficial tissues.

**General Considerations. Common types of infection:**

Periapical, peridontal, postsurgical, pericoronal

May begin as well-delineated, self-limiting condition with potential to spread and result in a major fascial space infection.

Life-threatening sequelae can ensue:

Septicemia, cavernous sinus thrombosis, airway obstruction, mediastinitis

**Microbiology.** Odontogenic infections are multimicrobial:

- Gram (+) cocci, aerobic and anaerobic:
  - Streptococci and their anaerobic counterpart, peptostreptococci
  - Staphylococci, and their anaerobic counterpart, peptococci
- Gram (+) rods:
  - Lactobacillus, diphtheroids, Actinomyces
- Gram (-) rods:
  - Fusobacterium, Bacteroids, Eikenella, Psuedomonas (occasional)

**Host Factors.** Immunity against intraoral infection is composed of three sets of mechanisms:

- Humoral factors
- Cellular factors
- Local factors
- Decrease one of these mechanisms and it increases the potential for infection.

**Humoral Factors.**

Circulating immunoglobulins, along with complement, combine with microbes to form opsonins that promote phagocytosis by macrophages.

IgA prevents colonization of microbes on oral mucosal surfaces.

In presence of infection, histamine, serotonin, prostaglandins support vasodilation and increased vascular permeability. →inflammation

**Cellular factors.**

- Phagocytes engulf and kill microbes, removing them, preventing replication.
- Lymphocytes produce lymphokines and immunoglobulines (aids humoral).
- Lymphokines stimulate reproduction of other lymphocytes, and kills antigens.

## **Local Factors**

Specific factors leading to resistance:

Abundant vascular supply allowing humoral and cellular response.

Mechanical cleansing by salivary flow.

Secretory IgA contained within saliva.

High epithelial turnover and sloughing, taking with it adherent bacteria.

A variety of microflora normally preventing selection for a single organism by competing for nutrients or release of by-products.

## **Historical Features**

Slowly enlarging swelling with a dull ache or recurrent draining abscess that swells and drains spontaneously is not likely to require aggressive treatment within the hour – the patient’s immune response is effectively containing the spread of infection.

However, 24-hour painful swelling causing pain during swallowing or severe trismus needs aggressive and prompt treatment.

## **Historical Features, con’t.**

- Immediate treatment or referral is critical when patient’s immune system has not been containing the infection.
- Specific warning signs include:
  - Dyspnea (difficulty breathing)
  - Dysphagia (difficulty/pain with swallowing)
  - Severe trismus
  - Rapidly progressive swelling

## **Clinical Features**

- Inflammation is tissue response to injury or invasion by microorganisms that involves vasodilation, capillary permeability, mobilization of leukocytes, and phagocytosis.

- Cardinal signs of inflammation:
  - Red, hot, swelling, pain, with loss of function
- Other findings: regional lymphadenopathy , fever, elevated white blood cell count, tachycardia, tachypnea, dehydration, malaise.

Infection can spread via the blood, lymph and the tissue spaces. In dentistry, the most relevant tissue spaces are the:

- Pterygomandibular space
- Lateral pharyngeal space
- Retropharyngeal space
- Infratemporal fossa
- Buccal space
- Vestibular space
- Sublingual space
- Submandibular space
- Submental space

NOTE: many of these spaces run into each other, allowing infection to spread from one space to another.

For example, an infection from a wisdom tooth can spread to the pterygomandibular space and from there it can travel to the lateral pharyngeal space, then to the retropharyngeal space and even to the mediastinum.

Infection can also spread to the pterygomandibular space and lateral pharyngeal space from the infratemporal fossa.

### **Infection spread from maxillary teeth:**

infections from the maxillary teeth can spread to the maxillary sinus, the canine fossa, palatal space, infratemporal fossa, buccal space and vestibular space.

infection will spread to the buccal space if the infection's path is outside the attachment of the buccinator muscle, but will spread to the vestibular space if the infection's path is inside the attachment of the buccinator muscle.

infection can spread to the cavernous sinus from the infratemporal fossa and from the canine fossa. Infection in the cavernous sinus can lead to cavernous sinus thrombosis , which is potentially fatal.

### **Infection spread from mandibular teeth:**

infections from mandibular teeth can spread to the vestibular and buccal space in the same way as from the maxillary teeth.

infection can also spread to the pterygomandibular space, sublingual space, submandibular space and submental space.

the sublingual, submental and submandibular spaces can be referred collectively as the submandibular spaces.

sometimes when an infection spreads to the submandibular spaces a life threatening condition called Ludwig's angina occurs. Angina is latin for strangle therefore this angina is referring to the sensation of being strangled caused by the swelling of the neck region. Tracheotomy is sometimes necessary to maintain the airway.

## **Fascial Spaces**

Fascial planes offer anatomic highways for infection to spread superficial to deep planes

Antibiotic availability in fascial spaces is limited due to poor vascularity

Fascial spaces are contiguous and infection readily spreads from one space to another (open primary and secondary spaces)

## **Canine Space**

Location: between the levator anguli oris and the levator labii superioris muscles

Involvement primarily due to maxillary canine tooth infection

Long root allows erosion through the alveolar bone of the maxilla

Signs: obliteration of the nasolabial fold, superior extension can involve lower eyelid

## **Buccal Space**

Posterior maxillary teeth are source of most buccal space infections

Results when infection erodes through bone superior to attachment of buccinator muscle

Boundaries: lateral-Skin of the face, medial-Buccinator muscle, both a primary mandibular and maxillary space.

Most infections caused by posterior maxillary teeth.

## **Infratemporal space**

Infratemporal space is a potential space lying behind the maxilla.

Boundaries of infratemporal fossa: 1. Lateral: Bounded by Zygoma, the ramus of mandible, parotid gland and masseter muscle. 2. Medial: Bounded by superior constrictor muscle, Pharyngobasilar fascia, Pterygoid plates. 3. Anterior: The body of the maxilla lies anteriorly. 4. Superior: Greater wing of sphenoid. 5. Posterior: Auricular tubercle of the temporal bone, glenoid fossa and styloid process.

## **INFECTION OF INFRATEMPORAL SPACE**

- Infective complications can develop and present following the extraction of clinically non-infected teeth
- Infratemporal space infection is a rare complication of dental extraction
- The cardinal clinical signs of maxillary and mandibular neurosensory deficit may not be immediately apparent
- The diagnosis, as in this case, can only be confirmed using scanning imaging modalities (CT or MRI)

### **Clinical features :-**

- Severe trismus
- Bulging of temporalis muscle
- Swelling extraorally over the region of sigmoid notch and intraorally in tuberosity region.

## **Pterygomandibular space**

The space between the medial area of the mandible and the medial pterygoid muscle, a target area for administering local anesthesia to the inferior alveolar nerve.

### **Boundries of pterygomandibular space**

- Medially – medial pterygoid muscle
- Laterally – medial surface of ramus of mandible
- Superiorly – lateral pterygoid
- Posteriorly – deep lobe of parotid gland
- Inferiorly – attachment of medial pterygoid onto the mandible
- Anteriorly – pterygomandibular raphe

**Infection.** From lower third molar.

**Clinical features :** trismus, intraoral swelling in the medial aspect of ramus of mandible.

## **Retropharyngeal Space**

- Posteromedial to lateral pharyngeal space and anterior to the prevertebral space
- Anterior: superior pharyngeal constrictor muscle
- Posterior: alar layer of prevertebral fascia
- Extends from skull base superiorly to C7 to T1 inferiorly
- Retropharyngeal space infections can spread to mediastinum

**Other complications** of retropharyngeal space involvement:

airway obstruction, aspiration of pus in the event of spontaneous rupture, rupture can occur during endotracheal intubation.

**Parotid space.** A deep hollow on the side at the sides of the face flanking the posterior aspect of the ramus of the mandible with its attached muscles which is occupied by the parotid gland ; it is lined with fascial laminae (the parotid sheath ) derived from the investing layer of deep cervical fascia ; the structures bounding the space collectively constitute the parotid bed . Surgeons operating in the area take advantage of the fact that the anteroposterior dimensions of the parotid space increase with protrusion of the mandible .

### **Clinical features**

Facial swelling and progressive trismus are described.

Intraoral wound drainage and prolonged antibiotic therapy failed to control the resultant chronic cellulitis.

### **Submental space**

Infection can result directly due to infected mandibular incisor or indirectly from the submandibular space

Space located between the anterior bellies of the digastric muscle laterally, deeply by the mylohyoid muscle, and superiorly by the deep cervical fascia, the platysma muscle, the superficial cervical fascia, and the skin

Dependent drainage of this space is performed by placing a horizontal incision in the most dependent area of the swelling extraorally with a cosmetic scar being the result

### **Submandibular Space**

Boundaries:



- Superior-mylohyoid muscle and inferior border of the mandible
- Anteriorly-anterior belly of the digastric muscle
- Posteriorly-posterior belly of the digastric muscle
- Inferiorly-hyoid bone
- Superficially-platysma muscle and superficial layer of the deep cervical fascia
- Infected mandibular 2 nd and 3 rd molars cause submandibular space involvement since root apices lay below mylohyoid muscle

### **Sublingual Space**

Submandibular and sublingual spaces surgically distinct, but should be considered as surgical unit due to proximity and frequent dual involvement in odontogenic infections.

Boundaries: superior-oral mucosa, inferior-mylohyoid muscle, infected premolar and 1 st molar teeth frequently drain into this space due to their root apices existing superior to the mylohyoid muscle.

## **Masseteric Space**

Located between lateral aspect of the mandible and the masseter muscle

Involvement of this space generally occurs from buccal space primary involvement

Signs of involvement of the masseteric space include trismus and posterior-inferior face swelling

## **Zygomatocotemporal(Retrozygomatic)Space**

Boundaries : Ant. - maxilla, Zygomatic bone

Lat. - Insertion of Temporalis muscle

## **Zygomatocotemporal(Retrozygomatic)Space**

- Contents : Posterior superior alveolar nerve
- and vessels buccal fat pad

## **Oral tissue examination**

- Examine quality and consistency:
  - Soft to fluctuant (fluid filled) to hard (indurated)
- Color and temperature determine the presence and extent of infection
- Normal v abnormal tissue architecture:
  - Distortion of mucobuccal fold
  - Soft palate symmetric with uvula in midline (deviation -> involvement of lateral pharyngeal space)
  - Nasal tip, nasolabial fold, circumorbital areas
- 2. Examination, con't.
- Identify causative factors:
  - Tooth, root tip, foreign body, etc.
- Vital signs should be taken:
  - Temperatures > 101 to 102 °F accompanied by an elevated heart rate indicate systemic involvement of the infection and increased urgency of treatment.

## **Principles in Treatment of Oral Infections**

- Remove the cause.
- Establish drainage.
- Institute antibiotic therapy.
- Supportive care, including proper rest and nutrition.

## Antibiotic Therapy

- Removal of the cause, drainage, and supportive care more important than antibiotic therapy.
- Infections are cured by the patient's defenses, not antibiotics.
- Risks of allergy, toxicity, side effects, resistance and superinfection causing serious or potentially fatal consequences must be considered.

### Antibiotic therapy, con't.

- Oral infections are typically polymicrobial.
- Antibiotic effectiveness dependent upon adequate tissue (not serum) concentration for an appropriate amount of time.
- Antibiotics should be prescribed for at least one week – adequate tissue concentration achieved in 24-48 hours, with bacteriocidal activity occurring over the next 3-5 days.

### Antibiotic therapy, con't.

- Penicillin (bacteriocidal) drug of choice for treatment of odontogenic infections (5% incident of allergy).
- Clindamycin (bacteriocidal) 1 st line after penicillin; effective against anaerobes; stop taking at first sign of diarrhea.
- Cephalosporin (slightly broader spectrum and bacteriocidal); cautious use in penicillin-allergic patients - cross-sensitivity; if history of anaphylaxis to penicillin, do not use.

### Antibiotic therapy, con't.

- Erythromycin (bacteriostatic) good 2 nd line drug after penicillin; use enteric-coated to reduce GI upset.
- Metronidazole (bacteriocidal) excellent against anaerobes only.
- Augmentin (amoxicillin + clavulanic acid) kills penicillinase-producing bacteria that interferes with amoxicillin; expensive.

## Supportive Care

To ensure the patient's maximum immune response:

- Increase fluid intake (16 ounces/hour).
- Nutritional intake (soups, protein drinks, solids) with three meals/day.
- May need to see patient daily, until resolution has begun.
- If no improvement within 24- 48 hours, refer immediately to an oral and maxillofacial surgeon.

# Ludwig's angina (Submandibular space infection)

Ludwig's angina is a bacterial infection of the floor of the mouth.

## Causes

- The cause is usually an infection with Streptococcal bacteria, although other bacteria can cause the condition. Since the advent of antibiotics, Ludwig's angina has become a rare disease.
- The route of infection in most cases is from infected lower third molars or from pericoronitis, which is an infection of the gums surrounding the partially erupted lower third molars. Although the widespread involvement seen in Ludwig's is usually develops in immunocompromised persons, it can also develop in otherwise healthy individuals. Thus, it is very important to obtain dental consultation for lower-third molars at the first sign of any pain, bleeding from the gums, sensitivity to heat/cold or swelling at the angle of the jaw.
- Ludwig's angina is also associated with piercings of the lingual frenulum.

## Symptoms

- The symptoms include swelling, pain and raising of the tongue, swelling of the neck and the tissues of the submandibular and sublingual spaces, malaise, fever, dysphagia (difficulty swallowing) and, in severe cases, stridor or difficulty breathing.
- Swelling of the submandibular and/or sublingual spaces are distinctive in that they are hard and classically 'boardlike'. Important signs include the patient not being able to swallow his/her own saliva and the presence of audible stridor as these strongly suggest that airway compromise is imminent.

## Exams and Tests

An examination of the neck and head shows redness and swelling of the upper neck, under the chin. The swelling may reach to the floor of the mouth. The tongue may be swollen or out of place.

A CT scan of the neck may be recommended. Culture of fluid from the tissues may show bacteria.

## **When to Contact a Medical Professional**

Breathing difficulty is an emergency situation. Immediately go to the emergency room or call your doctor.

Call doctor if you have symptoms of this condition, or if symptoms do not improve after treatment.

## **Treatment**

If the swelling blocks the airway, emergency medical help is needed to maintain an open airway. This may involve placing a breathing tube through the mouth or nose and into the lungs, or surgery called a tracheostomy that creates an opening through the neck into the windpipe.

Antibiotics, usually penicillin or a penicillin-like medication, are given to fight the infection. They are usually given through a vein until symptoms go away. Antibiotics taken by mouth may be continued until tests show that the bacteria have gone away.

Dental treatment may be needed for tooth infections that cause Ludwig's angina.

Surgery may be needed to drain fluids that are causing the swelling.

## **Outlook Prognosis**

Ludwig's angina can be life threatening. However, it can be cured with proper protection of the airways and appropriate antibiotics.

## **Possible Complications:**

airway blockage; generalized infection (sepsis); septic shock.

**Prevention.** Regular visits to the dentist, and prompt treatment of mouth or tooth infections can prevent the conditions that increase the risk of developing Ludwig's angina.

# **Cleft lip and palate (Craniofacial defect).**

## **Infant hard and soft palates**

The roof of the mouth is comprised of the hard palate and the soft palate (fig.31). These structures separate the nasal cavity from the mouth.

Cleft lip repair and cleft palate repair are indicated (fig.32) for:

- Repair of physical deformity
- Nursing, feeding, or speech problems resulting from cleft lip or palate

While the baby is anesthetized and asleep (general anesthesia), the tissues around the defect are trimmed and sewn together (fig.33) with several layers of stitches (absorbable sutures). The skin is sewn together with very small, fine stitches (sutures) to make the scar as small as possible. In cleft palate repair, tissue from the back of the mouth (pharynx) may be taken to add tissue to the deficient soft palate (this is called a pharyngeal flap). Occasionally more than one surgery is required for complete palate closure.

**Aftercare.** Most babies heal without complications. The cosmetic result often depends on the severity of the deformity and is usually quite good.

Cleft lip and palate are birth defects that affect the upper lip and the roof of the mouth.

**Causes.** There are many causes for of cleft lip and palate. Problems with genes passed down from one or both parents, drugs, viruses, or other toxins can all cause such birth defects. Cleft lip and palate may occur along with other syndromes or birth defects.

A cleft lip and palate can affect the appearance of one's face, and may lead to problems with feeding and speech, as well as ear infections. Problems may range from a small notch in the lip to a complete groove that runs into the roof of the mouth and nose. These features may occur separately or together.

Risk factors include a family history of cleft lip or palate and other birth defect. About 1 out of 2,500 people have a cleft palate.

**Symptoms.** A child may have one or more of these conditions at birth.

A cleft lip may be just a small notch in the lip. It may also be a complete split in the lip that goes all the way to the base of the nose.

A cleft palate can be on one or both sides of the roof of the mouth. It may go the full length of the palate.

Other symptoms include:

misaligned teeth; change in nose shape (amount of distortion varies).

Problems that may be present because of a cleft lip or palate are:

- Failure to gain weight
- Feeding problems

- Flow of milk through nasal passages during feeding
- Misaligned teeth
- Poor growth
- Recurrent ear infections
- Speech difficulties

**Exams and Tests.** A physical examination of the mouth, nose, and palate confirms a cleft lip or cleft palate. Medical tests may be done to rule out other possible health conditions.

**When to Contact a Medical Professional.** Cleft lip and palate is usually diagnosed at birth. Follow the doctor recommendations for follow-up visits. Call the doctor if problems develop between visits.

**Treatment.** Surgery to close the cleft lip is often done at when the child is between 6 weeks and 9 months old. Surgery may be needed later in life the problem severely affects the nose area

A cleft palate is usually closed within the first year of life so that the child's speech normally develops. Sometimes a prosthetic device is temporarily used to close the palate so the baby can feed and grow until surgery can be done.

Continued follow-up may be needed with speech therapists and orthodontists.

**Outlook Prognosis.** Surgery to close the cleft lip is often done at when the child is between 6 weeks and 9 months old. Surgery may be needed later in life the problem severely affects the nose area

A cleft palate is usually closed within the first year of life so that the child's speech normally develops. Sometimes a prosthetic device is temporarily used to close the palate so the baby can feed and grow until surgery can be done.

Continued follow-up may be needed with speech therapists and orthodontists.

Although treatment may continue for several years and require several surgeries, most children with a cleft lip and palate can achieve normal appearance, speech, and eating. However, some people may have continued speech problems.

**Possible Complications:** dental cavities; displaced teeth; hearing loss; lip deformities; nasal deformities; recurrent ear infections; speech difficulties.

## **Temporomandibular Joint Dysfunction (Temporomandibular disorders, TMD)**

The temporomandibular joint (TMJ) connects your jaw to the side of your head. When it works well, it enables you to talk, chew and yawn. For people with TMJ dysfunction, problems with the joint and muscles around it may cause

- Pain that travels through the face, jaw or neck
- Stiff jaw muscles
- Limited movement or locking of the jaw
- Painful clicking or popping in the jaw
- A change in the way the upper and lower teeth fit together

Jaw pain may go away with little or no treatment. Treatment may include simple things you can do yourself, such as eating soft foods or applying ice packs. It may also include pain medicines or devices to insert in your mouth. In rare cases, you might need surgery.

Temporomandibular joint and muscle disorders (TMJ disorders) are problems or symptoms of the chewing muscles and joints that connect your lower jaw to your skull.

## **Causes**

There are two matching temporomandibular joints -- one on each side of your head, located just in front of your ears. The abbreviation "TMJ" literally refers to the joint but is often used to mean any disorders or symptoms of this region.

Many TMJ-related symptoms are caused by the effects of physical stress on the structures around the joint. These structures include:

- Cartilage disk at the joint
- Muscles of the jaw, face, and neck
- Nearby ligaments, blood vessels, and nerves
- Teeth

For many people with temporomandibular joint disorders, the cause is unknown. Some causes given for this condition are not well proven. These included:

- A bad bite or orthodontic braces
- Stress and tooth grinding. Many people with TMJ problems do not grind their teeth, and many who have been grinding their teeth for a long time do not have problems with their TMJ joint. For some people, the stress associated with this disorder may be caused by the pain as opposed to being the cause of the problem.

Poor posture can also be an important factor in TMJ symptoms. For example, holding the head forward while looking at a computer all day strains the muscles of the face and neck.



Other factors that might make TMJ symptoms worse are stress, poor diet, and lack of sleep.

Many people end up having "trigger points" -- contracted muscles in your jaw, head, and neck. Trigger points can refer pain to other areas, causing a headache, earache, or toothache.

Other possible causes of TMJ-related symptoms include arthritis, fractures, dislocations, and structural problems present since birth.

**Symptoms** associated with TMJ disorders may be:

- Biting or chewing difficulty or discomfort
- Clicking, popping, or grating sound when opening or closing the mouth
- Dull, aching pain in the face
- Earache
- Headache
- Jaw pain or tenderness of the jaw
- Reduced ability to open or close the mouth

**Exams and Tests.** You may need to see more than one medical specialist for your TMJ pain and symptoms, such as your primary care provider, a dentist, or an ear, nose, and throat (ENT) doctor, depending on your symptoms.

A thorough examination may involve:

- A dental examination to show if you have poor bite alignment
- Feeling the joint and connecting muscles for tenderness
- Pressing around the head for areas that are sensitive or painful
- Sliding the teeth from side to side
- Watching, feeling, and listening to the jaw open and shut
- X-rays to show abnormalities

Sometimes, the results of the physical exam may appear normal.

Doctor will also need to consider other conditions, such as infections, ear infections, neuralgias, or nerve-related problems and headaches, as the cause of your symptoms.

### **When to Contact a Medical Professional**

Doctor ask your if you are having trouble eating or opening your mouth. Keep in mind that a wide variety of possible conditions can cause TMJ symptoms, from arthritis to whiplash injuries. Experts who are specially trained in facial pain can help diagnose and treat TMJ.

**Treatment.** Simple, gentle therapies are usually recommended first.

- Learn how to gently stretch, relax, or massage the muscles around your jaw. Your doctor, dentist, or physical therapist can help you with these.
- Avoid actions that cause your symptoms, such as yawning, singing, and chewing gum.
- Try moist heat or cold packs on your face.
- Learn stress-reducing techniques.
- Exercising several times each week may help you increase your ability to handle pain.

Read as much as you can, as opinion varies widely on how to treat TMJ disorders. Get the opinions of several doctors. The good news is that most people eventually find something that helps.

Mouth or bite guards, also called splints or appliances, have been used since the 1930s to treat teeth grinding, clenching, and TMJ disorders.

- While many people have found them to be useful, the benefits vary widely. The guard may lose its effectiveness over time, or when you stop wearing it. Other people may feel worse pain when they wear one.
- There are different types of splints. Some fit over the top teeth, while others fit over the bottom teeth.
- Permanent use of these items is not recommended. You should also stop if they cause any changes in your bite.

Failure of more conservative treatments does not automatically mean you need more aggressive treatment. Be cautious about any nonreversible treatment method, such as orthodontics or surgery, that permanently changes your bite.

Reconstructive surgery of the jaw, or joint replacement, is rarely required. In fact, studies have shown that the results are often worse than before surgery.

### **Outlook Prognosis**

For many people, symptoms occur only sometimes and do not last long. They will go away in time with little or no treatment. Most cases can be successfully treated. Some cases of pain go away on their own without treatment. TMJ-related pain may return again in the future. If the cause is nighttime clenching, treatment can be very tricky because it is a sleeping behavior that is hard to control.

Mouth splints are a common treatment approach for teeth grinding. While some splints may silence the grinding by providing a flat, even surface, they may not be as effective at reducing pain or stopping clenching. Splints may be effective in the short-term but could become less effective over time. Some splints can also cause changes in your bite. This may cause a new problem.

## Possible Complications

- Chronic face pain
- Chronic headaches

**Prevention.** Many of the home-care steps to treat TMJ problems can prevent such problems in the first place:

- Avoid eating hard foods and chewing gum.
- Learn relaxation techniques to reduce overall stress and muscle tension.
- Maintain good posture, especially if you work all day at a computer. Pause often to change position, rest your hands and arms, and relieve stressed muscles.
- Use safety measures to reduce the risk of fractures and dislocations.

## Tongue Disorders

Your tongue helps you taste, swallow, and chew. You also use it to speak. Your tongue is made up of many muscles. The upper surface contains your taste buds.

Problems with the tongue include: pain, swelling, changes in color or texture; abnormal movement or difficulty moving the tongue; taste problems.

These problems can have many different causes. Treatment depends on the underlying problem.

### **Geographic tongue (Glossitis - benign migratory)**

Geographic tongue is a map-like appearance of your tongue due to irregular patches on its surface.

**Causes.** The specific cause of geographic tongue is unknown, although vitamin B deficiency may be involved. Other causes may include irritation from hot or spicy foods, or alcohol. The condition appears to be less common in smokers.

The pattern on the surface of the tongue may change very rapidly. This pattern change occurs when there is a loss of the tiny, finger-like projections, called papillae, on the tongue's surface. This makes areas of the tongue flat. These areas are said to be "denuded." Denuded areas may persist for more than a month.

### **Symptoms**

- Map-like appearance to the surface of the tongue
- Patches that change location from day to day
- Smooth, beefy red patches and lesions on the tongue
- Soreness and burning pain (in some cases)

**Exams and Tests.** Doctor will usually diagnose this condition based on an examination of your tongue. Tests are usually not necessary.

**Call your doctor** if the symptoms last longer than 10 days. Seek immediate medical help if:

- Breathing trouble occurs
- The tongue is severely swollen
- There are problems with speaking, chewing, or swallowing

There is no treatment.

**Outlook Prognosis.** Geographic tongue is a harmless condition, but it can be persistent and uncomfortable.

**Prevention.** Avoid irritating your tongue with hot or spicy food or alcohol if you are prone to this condition.

## Glossitis

### Alternative Names

Tongue inflammation; Tongue infection; Smooth tongue; Glossodynia; Burning tongue syndrome

Glossitis is a condition in which the tongue is swollen and changes color. Finger-like projections on the surface of the tongue (called papillae) are lost, causing the tongue to appear smooth.

**Causes.** Changes in the appearance of the tongue may be a primary condition (not due to another disease or event), or it may be a symptom of other disorders (a secondary condition).

Glossitis occurs when there is acute or chronic inflammation of the tongue.

- Causes include: Bacterial or viral infections (including oral herpes simplex)
- Mechanical irritation or injury from burns, rough edges of teeth or dental appliances, or other trauma
- Exposure to irritants such as tobacco, alcohol, hot foods, or spices
- Allergic reaction to toothpaste, mouthwash, breath fresheners, dyes in candy, plastic in dentures or retainers, or certain blood pressure medications (ACE inhibitors)
- Disorders such as iron deficiency anemia, pernicious anemia and other B-vitamin deficiencies, oral lichen planus, erythema multiform, aphthous ulcers, pemphigus vulgaris, syphilis, and others

- Yeast infection
- Dry mouth associated with connective tissue disorders, such as Sjogren syndrome

Occasionally, glossitis can be inherited.

## Symptoms

- Tongue swelling
- Smooth appearance to the tongue
- Tongue color usually dark "beefy" red
  - Pale, if caused by pernicious anemia
  - Fiery red, if caused by deficiency of B vitamins
- Sore and tender tongue
- Difficulty with chewing, swallowing, or speaking

**Exams and Tests.** An examination by a dentist shows a swollen tongue (or patches of swelling).

Finger-like projections on the surface of the tongue (called papillae) may be absent.

Your health care provider may ask detailed questions about your medical history and lifestyle to determine the possible source of tongue inflammation, if injury or other cause is not easily identified.

Blood tests may be done to rule out other medical conditions.

**Call for your doctor** if symptoms of glossitis persist for longer than 10 days.

Call your doctor if tongue swelling is severe or breathing, speaking, chewing, or swallowing is difficult.

Blockage of the airway is an emergency situation that requires immediate medical attention.

**Treatment.** The goal of treatment is to reduce inflammation. Treatment usually does not require hospitalization unless tongue swelling is severe.

Good oral hygiene is necessary, including thorough tooth brushing at least twice a day, and flossing at least once a day.

Antibiotics, antifungal medications, or other antimicrobials may be prescribed if the glossitis is due to an infection.

Dietary changes and supplements are used to treat anemia and nutritional deficiencies.

Avoid irritants (such as hot or spicy foods, alcohol, and tobacco) to reduce any tongue discomfort.

**Outlook Prognosis.** Glossitis usually responds well to treatment if the cause of inflammation is removed or treated. This disorder may be painless, or it may cause tongue and mouth discomfort. In some cases, glossitis may result in severe tongue swelling that blocks the airway.

**Possible Complications:** discomfort, airway blockage; difficulties with speaking, chewing, or swallowing.

**Prevention.** Good oral hygiene (thorough tooth brushing and flossing and regular professional cleaning and examination) may help prevent glossitis.

## Macroglossia

Macroglossia is a disorder in which the tongue is larger than normal.

Macroglossia is usually caused by an increase in the amount of tissue on the tongue, rather than by a growth, such as a tumor.

This condition can be seen in certain inherited or congenital (existing at birth) disorders, including:

- Acromegaly
- Beckwith-Wiedemann syndrome
- Congenital hypothyroidism
- Diabetes
- Down syndrome
- Lymphangioma/hemangioma
- Mucopolysaccharidoses
- Primary amyloidosis

Macroglossia is a congenital disorder (fig.34) where the tongue is larger than normal. It is enlarged because of an increase in the amount of tissue, not because of a tumor or growth. There is also a perceived macroglossia in Down syndrome possibly because the tongue frequently protrudes.

Macroglossia is a congenital disorder where the tongue is larger than normal (fig. 35). It is enlarged because of an increase in the amount of tissue, not because of a tumor or growth.

# Tongue problems

Tongue problems include pain, swelling, or a change in how the tongue looks.

## Considerations

The tongue is mainly composed of muscles. It is covered with a mucous membrane. Small bumps (papillae) cover the upper surface of the tongue. Between the papillae are the taste buds, which allow you to taste. The tongue moves food to help you chew and swallow.

The tongue also helps you form words.

There are many different reasons for changes in the tongue's function and appearance.

## DIFFICULTY MOVING THE TONGUE

Tongue movement problems are most often caused by nerve damage. However, problems moving the tongue may also be caused by ankyloglossia, a disorder where the band of tissue that attaches the tongue to the floor of the mouth is too short. Tongue movement disorders may result in speech difficulties or difficulty moving food during chewing and swallowing.

## TASTE ABNORMALITIES

Taste problems can be caused by damage to the taste buds, nerve problems, side effects of medications, an infection, or other condition. The tongue normally senses sweet, salty, sour, and bitter tastes. Other "tastes" are actually a function of the sense of smell.

## ENLARGEMENT OF THE TONGUE

Tongue swelling occurs with Down syndrome, acromegaly, myxedema, amyloidosis, rhabdomyoma, and other disorders. The tongue may get wider in persons who have no teeth and do not wear dentures.

## COLOR CHANGES

Color changes may occur with inflammation of the tongue (glossitis). Papillae are lost, causing the tongue to appear smooth. Geographic tongue is a patchy form of glossitis where the location of inflammation and the appearance of the tongue change from day to day.

## HAIRY TONGUE

Hairy tongue is a harmless condition in which the tongue looks hairy or furry. Its appearance can be worrisome. The disorder usually goes away with antibiotics.

## BLACK TONGUE

Sometimes the upper surface of the tongue turns black or brown in color. This is an unsightly condition but is not harmful.

## PAIN IN THE TONGUE

This may occur with glossitis and geographic tongue. Tongue pain may also occur in with diabetic neuropathy, oral cancer, mouth ulcers, and leukoplakia.

After menopause, some women have a sudden feeling that their tongue has been burned. This is called burning tongue syndrome or idiopathic glossopyrosis. There is no specific treatment for burning tongue syndrome.

### **Causes**

Minor infections or irritations are the most common cause of tongue soreness. Injury, such as biting the tongue, can cause painful sores. Heavy smoking will irritate the tongue and make it painful.

A viral ulcer, also called a canker sore, commonly appears on the tongue (or anywhere in the mouth) for no apparent reason. Some doctors believe that these ulcers are linked to emotional stress or fatigue, although this has not been proved.

### **Possible causes** of tongue pain include:

anemia, cancer, dentures that irritate the tongue; oral herpes (ulcers); neuralgia, referred pain from teeth and gums; referred pain from the heart.

### Possible causes of tongue tremor:

- Neurological disorder
- Overactive thyroid

### Possible causes of white tongue:

- Local irritation
- Smoking and alcohol use

### Possible causes of smooth tongue:

- Anemia
- Vitamin B-12 deficiency



Possible **causes** of red (ranging from pink to magenta) tongue:

folic acid and vitamin B-12 deficiency; pellagra, pernicious anemia; Plummer-Vinson syndrome; sprue.

Possible **causes** of tongue swelling:

acromegaly, allergic reaction to food or medicine; amyloidosis, angioedema, Beckwith syndrome; cancer of the tongue; congenital micrognathia; Down syndrome; hypothyroidism, infection, leukemia, lymphangioma, neurofibromatosis, pellagra, pernicious anemia; strep infection; tumor of the pituitary gland.

Possible **causes** of a hairy tongue:

AIDS, antibiotic therapy; drinking coffee; dyes in drugs and food; chronic medical conditions; overuse of mouthwashes containing oxidizing or astringent agents; radiation of the head and neck; tobacco use.

Possible cause of grooves in the tongue:

- Birth defect -- normally occurs in 10% of population

### **When to Contact a Medical Professional**

Make an appointment with your doctor if your tongue problem persists.

### **What to Expect at Your Office Visit**

The doctor will perform a physical examination, look closely at the tongue, and ask question such as:

- When did you first notice the problem?
- Have you had similar symptoms before?
- Do you have pain, swelling, breathing problems, or difficulty swallowing?
- Do you have a tongue tremor?
- What makes the problem worse? (Eating, drinking, swallowing, talking)
- Do you wear dentures?
- What have you tried that helps?
- Are there problems with the teeth, gums, lips, or throat?
- Does the tongue bleed?
- Do you have a rash or fever?
- Do you have allergies?
- Are there problems with speaking or moving the tongue?
- Have you noticed changes in taste?
- What medications do you take?

- Do you smoke cigarettes, cigars, or a pipe?
- Do you use alcohol excessively?

**Home Care.** Practice good oral hygiene for hairy tongue and black tongue. Be sure to eat a well-balanced diet.

Canker sores are caused by viruses and can't be cured by treatment. They must heal on their own.

Examine in clinic if you have a tongue problem caused by dentures.

Antihistamines can help relieve a swollen tongue caused by allergies. You should avoid the food or drug that causes the tongue swelling.

Blood tests may be done to confirm specific disorders, particularly systemic causes of tongue disorders. Biopsy of tongue lesions may be needed in some cases.

Treatment depends on the cause of the tongue problem.

- If nerve damage has caused a tongue movement problem, the underlying condition must be treated. Therapy may be needed to improve speech and swallowing ability.
- Ankyloglossia may not require treatment unless you have speech or swallowing difficulties. Surgery to release the tongue can relieve the problem.
- Medicine may be prescribed for mouth ulcers, leukoplakia, oral cancer, and other mouth sores.
- Anti-inflammatory medicines may be prescribed for glossitis and geographic tongue.

## **Black hairy tongue**

Alternative Names- Dark tongue

Black hairy tongue is produced when the papilla (finger-like projections from the surface of the tongue) fail to fall off as they normally do. As the length of the papilla increase, debris collects and bacteria grow, producing the characteristic dark "furry" appearance (fig.36).

## **Tongue biopsy**

A tongue biopsy is surgery to remove a piece of the tongue for examination under a microscope.

**How the Test is Performed**

A tongue biopsy can be done using a needle. After numbing the area, the health care provider gently sticks the needle into the tongue and removes a tiny piece of tissue.

Some types of tongue biopsies remove a thin slice of tissue. Others are done under general anesthesia (asleep and no pain) so that larger areas, such as lesion, growth, or other abnormal area of the tongue, may be removed and examined.

### **How to Prepare for the Test**

You may be told not to eat or drink anything for several hours before the test.

### **How the Test Will Feel**

A needle biopsy is often somewhat uncomfortable even with use of an anesthetic, because the tongue is quite sensitive. After the biopsy, the tongue can be tender or sore, and it may feel slightly swollen. There may be stitches or an open sore where the biopsy was done.

### **Why the Test is Performed**

The test is done to determine the cause of abnormal growths, lesions, or suspicious-appearing areas of the tongue.

### **Normal Results**

There is normal tongue tissue, with no abnormal inclusions or cellular changes.

Note: Normal value ranges may vary slightly among different laboratories. Talk to your doctor about the meaning of your specific test results.

### **What Abnormal Results Mean**

- Amyloidosis
- Tongue (oral) cancer

**Risks:** bleeding, infection, swelling of the tongue (can obstruct the airway and cause breathing difficulty).

Note: Complications are rare.

A surgeon will remove a section (fig.37) of the unusual area of skin on the tongue to analyse.

# Jaw Injuries and Disorders

## Alternative Names

Dislocated jaw; Fractured jaw; Broken jaw

Your jaw is a set of bones that holds your teeth. It consists of two main parts. The upper part is the maxilla. It doesn't move. The moveable lower part is called the mandible. You move it when you talk or chew. The two halves of the mandible meet at your chin. The joint where the mandible meets your skull is the temporomandibular joint.

Jaw problems include:

fractures , dislocations, temporomandibular joint dysfunction; osteonecrosis, which happens when your bones lose their blood supply; cancers.

Treatment of jaw problems depends on the cause.

A broken jaw is a break in the jaw bone. A dislocated jaw means the lower part of the jaw has moved out of its normal position at one or both joints where the jaw bone connects to the skull (temporomandibular joints).

## Considerations

A broken or dislocated jaw usually heals completely after treatment. However, the jaw may become dislocated again in the future.

Complications may include:

- Airway blockage
- Bleeding
- Breathing blood or food into the lungs
- Difficulty eating (temporary)
- Difficulty talking (temporary)
- Infection of the jaw or face
- Jaw joint (TMJ) pain and other problems
- Problems aligning the teeth

The most common **cause** of a broken or dislocated jaw is injury to the face. This may be due to:

assault, social trend; alcohol and drugs; industrial accident; motor vehicle accident, road traffic legislation; recreational or sports injury.

**Symptoms of a dislocated jaw** include:

- Bite that feels "off" or crooked
- Difficulty speaking
- Drooling because of inability to close the mouth
- Inability to close the mouth
- Jaw that may protrude forward
- Pain in the face or jaw, located in front of the ear on the affected side, and gets worse with movement
- Teeth that aren't normally aligned

**Symptoms of a fractured (broken) jaw** include:

- Bleeding from the mouth
- Difficulty opening the mouth widely
- Facial bruising
- Facial swelling
- Jaw stiffness
- Jaw tenderness or pain, worse with biting or chewing
- Loose or damaged teeth
- Lump or abnormal appearance of the cheek or jaw
- Numbness of the face (particularly the lower lip)
- Very limited movement of the jaw (with severe fracture)

**First Aid.** A broken or dislocated jaw requires immediate medical attention because of the risk of breathing problems or significant bleeding. Call your local emergency number (such as 911) or local hospital for further advice.

Hold the jaw gently in place with your hands while traveling to the emergency room. A bandage may also be wrapped over the top of the head and under the jaw. However, such a bandage should be easily removable in case you need to vomit.

If breathing problems or heavy bleeding occurs, or if there is severe facial swelling, a tube may be placed into your airways to help you breathe.

## DISLOCATED JAW

If the jaw is dislocated, the health care provider may be able to place it back into the correct position using the thumbs. Numbing medications (anesthetics) and muscle relaxants may be needed to relax the strong jaw muscles.

The jaw may need to be stabilized. This usually involves bandaging the jaw to keep the mouth from opening widely. In some cases, surgery may be needed to do this, particularly if repeated jaw dislocations occur.

After dislocating your jaw, you should not open your mouth widely for at least 6 weeks. Support your jaw with one or both hands when yawning and sneezing.

## FRACTURED JAW

Temporarily bandaging the jaw (around the top of the head) to prevent it from moving may help reduce pain.

The specific treatment for a fractured jaw depends on how badly the bone is broken. If you have a minor fracture, you may only need pain medicines and to follow a soft or liquid diet for a while.

Surgery is often needed for moderate to severe fractures. The jaw may be wired to the teeth of the opposite jaw to improve stability. Jaw wires are usually left in place for 6 - 8 weeks. Small rubber bands (elastics) are used to hold the teeth together. After a few weeks, some of the elastics are removed to allow motion and reduce joint stiffness.

If the jaw is wired, you can only drink liquids or eat very soft foods. Have blunt scissors readily available to cut the elastics in the event of vomiting or choking. If the wires must be cut, consult a health care provider promptly so they can be replaced.

### **When to Contact a Medical Professional**

A broken or dislocated jaw requires immediate medical attention. Emergency symptoms include difficulty breathing or heavy bleeding.

### **DO NOT attempt to correct the position of the jaw.**

**Prevention.** Safe practices in work, sports, and recreation, such as wearing a proper helmet when playing football, may prevent some accidental injuries to the face or jaw.

## Micrognathia

Micrognathia is a term that describes an abnormally small lower jaw.

### **Considerations**

In true micrognathia, the jaw is small enough to interfere with the infant's feeding. Infants with micrognathia may need special nipples in order to feed properly.

Micrognathia may be the only abnormality in a child. It often corrects itself during growth, especially at puberty when the jaw grows quite a bit. It also can be caused by certain inherited disorders and syndromes.

Micrognathia is one cause of abnormal alignment of the teeth. You can see this in the way the teeth close. Often there will not be enough room for the teeth to grow. Talk to an orthodontist when the child's adult teeth come in. At times, children can outgrow micrognathia, and it makes sense to wait to treat the condition until they are older.

### **Causes:**

- Pierre Robin syndrome
- Hallerman-Streiff syndrome
- Trisomy 13
- Trisomy 18
- XO syndrome (Turner syndrome)
- Progeria
- Treacher-Collins syndrome
- Smith-Lemli-Opitz syndrome
- Russell-Silver syndrome
- Seckel syndrome
- Cri du chat syndrome
- Marfan syndrome

### **Contact with your doctor if:**

- Your child seems to have a very small jaw
- Your child has trouble feeding properly

### **What to Expect at Your Visit**

The doctor will do a physical examination and may ask questions about the history of the problem, such as:

- When did you first notice that the jaw was small?
- How severe is it?
- Does the child have trouble eating?
- What other symptoms are present?

The physical examination will include a thorough check of the mouth.

The following **tests** may be performed: dental x-rays; skull x-rays.

If there are other symptoms that indicate an inherited condition, testing for that condition may be advised. The health care provider might recommend surgery or orthodontic devices.

**Home Care.** If micrognathia interferes with feeding, you'll need to use special feeding techniques and equipment. You can learn these techniques through special programs that are available at most hospitals.

# Prognathism

## Alternative Names-Extended chin

Prognathism is a descriptive term for a jaw (lower or upper) that protrudes forward beyond the plane of the face (fig. 38). Prognathism is an extension or bulging out (protrusion) of the lower jaw (mandible) that occurs when the shape of the face bones cause the teeth to be improperly lined up (misaligned).

## Considerations

Prognathism may cause malocclusion (misalignment of the biting surfaces of the upper and lower teeth), giving some people an angry, or fighter's, appearance. Prognathism may be a symptom of various syndromes or conditions.

**Causes.** An extended (protruding) jaw can be part of the normal facial shape a person is born with. It can also be caused by inherited conditions such as Crouzon syndrome or basal cell nevus syndrome. It may develop over time in children or adults as the result of conditions such as gigantism or acromegaly.

## When to Contact a Medical Professional

- There is difficulty talking, biting, or chewing related to the abnormal jaw alignment.
- You have concerns about jaw alignment

## What to Expect at Your Office Visit

The doctor will perform a physical examination and ask questions regarding the patient's medical history. Questions may include:

- Is there any family history of an unusual jaw shape?
- Is there difficulty talking, biting, or chewing?
- What other symptoms do you have?

Diagnostic tests may include:

skull x-ray; dental x-rays; imprints of the bite (a plaster mold is made of the teeth).

**Home Care.** It is appropriate to see a dentist or orthodontist to treat abnormal alignment of the jaw and teeth. However, your primary health care provider should



also be involved to check for any underlying medical disorders that can be associated with prognathism

# Craniofacial Abnormalities

Craniofacial is a medical term that relates to the bones of the skull and face. Craniofacial abnormalities are birth defects of the face or head. Some, like cleft lip and palate, are among the most common of all birth defects. Others are very rare. Most of them affect how a person's face or head looks. These conditions may also affect other parts of the body.

Treatment depends on the type of problem. Plastic and reconstructive surgery may help the person's appearance.

## Plastic and Cosmetic Surgery

Surgeons can reshape the appearance of body parts through cosmetic surgery. Some of the most common body parts people want to improve through surgery include

- Breasts: Increase or reduce the size of breasts or reshape sagging breasts
- Ears: Reduce the size of large ears or set protruding ears back closer to the head
- Eyes: Correct drooping upper eyelids or remove puffy bags below the eyes
- Face: Remove facial wrinkles, creases or acne scars
- Hair: Fill in balding areas with one's own hair
- Nose: Change the shape of the nose
- Tummy: Flatten the abdomen

### Normal anatomy

There are four major bones of the face (fig.39): the maxilla, the zygoma, the mandible, and the frontal bone of the cranium.

## Facial trauma (Maxillofacial injury)

### Alternative Names

Maxillofacial injury; Mid-face trauma; Facial injury; Le-Fort injuries

Facial trauma is any injury of the face and upper jaw bone (maxilla).

Blunt or penetrating trauma can **cause** injury to the area of the face that includes the upper jaw (maxilla). Common causes of injury to the face include:

automobile accidents; penetrating injuries; violence.

### Symptoms

- Changes in sensation and feeling over the face
- Deformed or uneven face or facial bones
- Difficulty breathing through the nose due to swelling and bleeding
- Double vision
- Missing teeth
- Swelling around the eyes that may cause vision problems

## **Exams and Tests**

The doctor will perform a physical exam, which may show:

- Bleeding from the nose, eyes, or mouth, or nasal blockage
- Breaks in the skin (lacerations)
- Bruising around the eyes or widening of the distance between the eyes, which may mean injury to the bones between the eye sockets

The following may suggest bone fractures:

- Abnormal sensations on the cheek and irregularities that can be felt
- An upper jaw that moves when the head is still

A CT scan of the head may be done.

## **Treatment**

Patients who cannot function normally or who have significant deformity will need surgery.

The goal of treatment is to:

- Control bleeding
- Create a clear airway
- Fix broken bone segments with titanium plates and screws
- Leave the fewest scars possible
- Rule out other injuries
- Treat the fracture

Treatment should be immediate, as long as the person is stable and there are no neck fractures or life-threatening injuries.

## **Outlook Prognosis**

Patients generally do very well with proper treatment. You will probably look different than you did before your injury. You may need to have more surgery 6 - 12 months later.

**General complications** include, but are not limited to:

bleeding, uneven face (asymmetry); infection, brain and nervous system (neurologic) complications; numbness or weakness.

**Prevention.** Wear seat belts and use protective head gear when appropriate. Avoid violent confrontations with other people.

## Broken or knocked out tooth

### Alternative Names

Teeth - broken; Tooth - knocked out

The dentist's term for a knocked out tooth is "avulsed."

### Considerations

A permanent tooth that is knocked out can sometimes be reimplanted. In most cases, only permanent, adult teeth are reimplanted into the mouth. Baby teeth are usually left out.

Immediately contact your dentist when a tooth is broken or knocked out. If you can find the tooth after the accident or injury, bring it with you when you seek medical help.

Tooth accidents are commonly **caused** by:

accidental falls; sports-related trauma; fighting; car accidents; biting on hard food.

### First Aid

Save any tooth that has been knocked out for possible reimplantation. Bring it to your dentist as soon as possible. The longer you wait, the less chance there is for successful reimplantation. Handle the tooth only by the crown (chewing edge).

Use one of the following options to transport the tooth:

1. Try to replace the tooth in the socket, to the level of adjacent teeth. Bite down gently on gauze or a wet tea bag to help keep it in place. The surrounding teeth can be used as anchors. Care must be taken not to swallow the tooth.
2. If the tooth cannot be replaced in the socket, place it in a container and cover with a small amount of whole milk or saliva. The tooth can also be carried between lower lip and lower gum or under the tongue.
3. A tooth-saving storage device (Save-a-Tooth, EMT Tooth Saver) may be available at your dentist's office. Such a kit contains a travel case and fluid solution. Consider buying one for your home first aid kit.

For additional first aid, follow these steps:

1. Apply a cold compress to the mouth and gums for pain.
2. Apply direct pressure, using gauze, to control bleeding.
3. Get dental help immediately. The sooner dental attention is received, the better the chances are for successful reimplantation.

Teeth that have been badly fractured may expose nerve tissue inside the tooth. In this case, immediate attention is needed to avoid infection, abscess, and pain.

Simple chips or fractures may be tended to on a nonemergency basis, but should still be fixed to avoid sharp edges that can cut the lips or tongue, and for cosmetic reasons.

### **DO NOT**

1. Do NOT handle the roots of the tooth. Handle only the chewing edge -- the crown portion of the tooth.
2. Do NOT scrape the root of the tooth to remove dirt.
3. Do NOT brush or clean the tooth with alcohol or peroxide.

### **When to Contact a Medical Professional**

See a dentist immediately if:

- A permanent tooth has been knocked out.
- A tooth has been partially fractured, and pain and swelling results.

In the case of simple tooth fractures, a nonemergency dental appointment can be made.

After a major accident, if you are not able to bring your upper and lower teeth together, the jaw may be broken. This requires immediate attention. You may call a dentist, but also seek help at a hospital.

### **Prevention**

- Wear a mouth guard when playing any contact sport.
- Avoid fights.
- Avoid hard foods, such as bones, stale bread, and tough bagels.
- Always wear a seatbelt.

## **WOUNDS**

**Wounds** (vulnus) are the mechanical damage of the organism, which occur from destroying the integrity of the covered tissues - skin or mucous membrane. During this damage there can be destroyed more deep tissues, inner organs (damage of the brain, liver, stomach, kidneys and others). The injury of the covered tissues separates the wound from other kinds of damage. For example the injury of the liver, which is caused by the dull trauma of the abdomen without destroying the skin, is the rupture and the damage during the stroke by a knife in the abdominal region-wound of the liver, because we observe the destroying of the skin.

### **The main features of the wounds**

The main clinical features of the wounds are pain, bleeding and hiatus. Their development depends on the localization of the wounds, mechanism of the damage, volume and deepness of the injury, and common condition of the patient.

#### **I. Pain (dolor)**

It caused by direct damage of the nerves in the wounds region, and in result if it's freezing during the development of the swelling. The pain can be localized not only in the place of damage but also it can be spread over the whole region of innervation.

The intensivity of pain syndrome in case of the wound by the next features is determined:

1. Localization of the wound.
2. Injuries of the big nerves trunks are present.
3. The character of the weapon and the frequency of causing and wound - the weapon is sharp and the damage of the receptor is less, and the pain is less.
4. Nerves - psychological condition of the organism. Pain feeling can be decreased when the patient is in the condition of effect, shock, alcohol or narcotic influence. Pain is not present during the operation with anesthesia, and during such a disease, like syringomyelia (the damage of the gray instances of the spinal cord).

Pain is the protective reaction of the organism, but long and intense pain causes exhaustion of the central nervous system.

## **II. Bleeding (haemorrhagia)**

Bleeding - the constant feature of the wound because of the damage of the tissue starts from skin and mucous tissues and it is accompanied by the disturbance of the integrity of vessels. The intensity of the bleeding can be different - from capillary to arterial bleeding.

It is determined by:

1. The presence of damage of big (or middle) vessels: arterial or vein ones. Localization of the wound. The most intensive bleeding is in injuring of the face, head, neck, manus -the tissue of these parts of the body has more blood than others.
2. The character of the weapon.
3. The condition of local and common hemodynamics. When the arterial pressure is decreasing or squeezing of the magistral vessel the intensity of the bleeding decreases.
4. The condition of the coagulation system.

## **III. Cleft (Hiatus)**

The hiatus of the wound is caused by the contraction of the elastic fibers of the skin. Expressivities divergention of the skin's borders of a wound first of all is determined by correlation of its axis to the Langergan's lines. These lines shoe the main direction of the rough skin structures situation. For example, for decreasing of the hiatus during the operation of the extremities the surgeons choose the longitudinal directions of the incisions. The special means of direction of the incision is in cosmetic and plastic surgery during closed skin defects. For big hiatus of the wound (incisions of the festering) the incision is made perpendicularly to the Langergan's line.

## **CLASSIFICATION OF THE WOUND**

1. Classification according to the origin

All the wounds are divided into two groups: operative and accidental.

Operative wounds are caused deliberately, with treatment or diagnostic aim, in special aseptic conditions, with minimal damage of the tissues, during the anesthesia, with thorough hemostasis and by joining with stitches of the incisive anatomical structures. In such condition the pain is not present in case of the operative wounds, the possibility of the bleeding is minimal, and the hiatus of the wound is removed at the end of the operation by applying stitches, it means that the main wound features are removed artificially.

The operative wounds heal by the primary tension.

All other kinds of wounds are accidental. The common thing of the wounds is that they are caused contrary to the will.

2. Classification according to character of tissue injure :

1. cut or incised wound (vulnus incisum);
2. stab or pierced wound (vulnus punctum);
3. contused wound (vulnus contusum);
4. lacerated wound (vulnus laceratum);
5. crushed wound (vulnus conqvassatum);
6. sabre or slash wound (vulnus caesum);
7. bite wound (vulnus morsum);
8. mixed wound (vulnus mixtum);
9. gunshot wound (vulnus sclopetarium).

### **1. Cut wound (Vulnus incisum)**

A sharp object causes these wounds. During the influence of the tissues the effort is concentrated on the concrete area, and this area has the high pressure, and this influence divides the tissue in the direction of sharp objects action. The surrounding tissues damage is not substantial. But the sharp object goes down to the internal organs and tissues. These wounds lead to a faint pain syndrome, big bleeding, and the hiatus depends on the correlation of the axis to the Langergon's lines. Cut wound is dangerous with the vessels damage; nervous damage if this



trauma does not have such complications the wound is going to heal by primary tension.

## **2. Stab wound (Vulnus punctum)**

Stab wound is caused by narrow and pointed object. The anatomical peculiarities are large depth and small area of the injured skin and mucous tissue.

The pain syndrome is slight, hiatus is absent, the external bleeding is absent, but hematoma can develop. Its special feature is damage of the inner vessels, nerves and organs. That's why this kind of wound has the difficult diagnostics. During the stab wound the injure can be simple or with serious complications of the liver, stomach and others - this condition can lead to death. This wound can lead to spreading of infection.

## **3. Contused wound (Vulnus consutum)**

A blunt object causes these wounds. Before the damaging of skin, the blunt object has to injure the soft deep tissues or organs (muscles, bones). Around the wound appears the wide zone of damage saturated with blood and destroying life activity (necrosis). Contused wound causes pain syndrome (big and injured zone), but the external bleeding is small (vessel's wall is damaged spreading a large area being thrombosed fast), but there can be hemorrhages. According to these complications contused wound heals by secondary tension.

## **4. Lacerated wound**

A blunt object causes these wounds but this object is directed under the acute angle to the skin. We can observe a big separation and sometimes to scalp of the skin. According to this separation skin can necrotize. Sometimes this kind of wounds can be caused by fractured parts of bones.

## **5. Crushed wound**

The mechanism of this damage is equal to the vulnus consutum and vulnus laceratum, but the degree of injury is maximal. These wounds seldom can lead to the incision of the skin, because the injured zone is very large. Crushed wound heals worse, and there can be infections.

## **6. Slash wound**

Slash wound caused by big and sharp object, that's why these wounds take the medium place between cut (incised) wound and contused wound. During this kind of wound the internal organs and bones are damaged very often. Such a wound may lead to spreading necrosis. Pain syndrome is very strong. Bleeding not severe, but massive diapedesis hemorrhages are present.

### **7. Bite wound**

The special features of this wound are bite by animals or man. Bite wound is more infected than other wounds. This wound may be complicated by acute infection, but the zone of damage is small. Some toxins may intoxicate the saliva (snake bite). Besides that, the bite wound may be contamination by tetanus.

### **8. Mixed wound**

These wounds may connect two and more kinds of wounds.

### **9. Gunshot wound**

a) This wound has three zones of damaging.

For all kinds of wounds is characteristic the presence of 2 zones of damage: wound canal and traumatic necrosis. The observation of gunshot wounds determined that they differ by a long period of healing. The main difference of gunshot wound is high speed of object (bullet, splinter). Common knowledge is that the energy of free moving object is equal  $mV^2/2$ . According to this the damage of the tissues is very strong. A sharp bullet more easily goes through the tissues but if the bullet loses stability, it starts to "rummage". In such case the bullet returns its energy to the tissues. During the penetration of the bullet into the tissues the area of increased pressure is formed which has the compressed tissues. This compression expands from the bullet. This is the phenomenon of "side stroke". According to this a temporary cavity is formed. This cavity may be pulsatile and the tissues with great speed contact relax, mutually displace. The pressure in the inner part of the cavity is 1000 atm, and the load on the wall of a vessel is  $120 \text{ kg/sm}^2$ . Such mechanism causes 3 zones of damage.

The zones of damage:

1. wound canal. In some cases there can be a bullet, or parts of necrotic tissue, blood and bacterias.
2. direct traumatic necrosis. Appears during the influence of kinetic energy. It consists of viable or unviable tissues, which are saturated with blood.
3. the zone of molecular contusion. It consists of tissues, which have malfunction of metabolism and of cellular structures. During the uncomfortable conditions, for example, the decreasing of perfusion, oxygenation, developing of the infection, the tissues devitalize (die). This zone is called "a stockpile of the following necrosis". This zone causes problems with treatment.

b) Complex anatomical character of damage

High kinetic energy causes not only presence of three zones, but also their complex anatomical character. What does it mean?

During the damage very often injure of some cavities of the organism is observed. Sometimes we can meet splinter fractures of the bones, and during injure of inner organs we can observe their rupture. Not always the wound canal is the direct line from the entrance to the exit aperture. It may look as indmeet line and may cause the damage of different organs.

c) High level of infection

Gunshot wound is very often complicated by the development of infection. High level of infection with the necrotic mass increases the risk of suppuration. And according to big damage of the muscle and small diameter of the entrance aperture, the access for the oxygen is very difficult, and this is the big evidence for the development of anaerobic infection.

d) Additional classification.

**According to the character of wound canal:**

1. A thorough damage - it has entrance and exit apertures (a bullet is out of the organism).
2. Blind injury - in has only entrance aperture (bullet is at the end of wound canal).

3. Tangential - the damage of superficial tissues, without the penetration to the cavities of the organism.

According to the factor of damage:

1. Small speed damage gunshot. The speed of the bullet is 600 m/s. The wound canal more often may be direct and blind. Such wound has, as a rule, a small entrance aperture and not big tissue damage.
2. High-speed damage. The speed of the bullet is 900 m/s and more. These wounds have small entrance aperture and wide, with defect of tissues, exit aperture. Wound canal winding, that's why we may observe the injury of many organs and tissues. More destroying effect may be caused by explosive shells.
3. Shot wounds. These wounds have many separate apertures, bleeding, the contusion of organs and tissues.

According to the zone of damage:

1. Wounds with a small zone of damage. These wounds have a small border of the incision and the necrotic zone is very small. The wounds with small zone have no complications, small hiatus.
2. The wounds with a large zone of damage. These wounds have insignificant hemorrhage, strong pain, long healing, and many complications.

Classification according to the level of infection

1. Aseptic.
2. Fresh infected.
3. Suppurative.

## **1. Aseptic wounds**

This wound is caused in the operative room with norms of aseptic. Such wound heals soon, and they do not have any complications.

But the operative wounds may be different: for example the operation of the vessels - infection is minimal and appendicitis a high level of infection.

According to the level of microbial contamination all operation are divided into four kinds:

- Aseptic operation (planned primary operation without the opening of cavity of inner organs).
- Conditionally aseptic - there may be infection in some cases.
- Operation with big danger of infection - conditionally infected.
- Very high level of infection - infective operations (purulent processes).

## **2. Fresh-infected wounds**

This is the wound, which was made outside of the operation or during 3 days from

the moment of damage. The level of infection in this wound is different and it depends on the kind of an object, conditions of damage. Fresh-infected wound have quantity of microorganisms not more than  $10^5$  per lg of tissue.

## **3. Suppurative wounds**

They are infected too. But they differ from fresh infected with the presence of infective process. This infection causes inflammatory reaction, necrosis, formation the suppuration, and general intoxication.

## **4. Classification according to the serious:**

There are simplex and complex wounds. Simplex wound is the damage of skin, skin and muscle.

Complex wound is the damage if inner organs, bones, magisterial vessels and ne trunks. For the diagnostics of the inner organs there are special symptoms. During damage of arterial vessels of the extremities -there absence of pulse, paleness, incr ing of the temperature in the region of bleeding. During Venous

stagnation - there extremities become cold and swollen, cyanosis. During the cut of nerve trunks -1 loss of sensitivity and moving function of the extremities.

### **5. Classification in dependence of the relation of the wounded defect to cavities if the body:**

There are penetrated and not penetrated wounds. Penetrated wounds -they ma connection between the cavity of the organism and environment. For this there sh be a damage of one of these membranes: hard membrane of the brain, parietal ph parietal peritoneum, and capsule of the joint.

Penetrated wounds are the most serious and dangerous. During the damage of rax there may be pneumothorax, hemothorax.

During the damage of the abdominal cavity it is necessary to exclude the injui parenchymatous organs, intra-abdominal bleeding. It is important to notice that du the penetrative injury there may be infection of the suppurative meningitis, empyen the chest, peritonitis, and suppurative arthritis. If the wound is not penetrative infection is not possible.

It is important to know what organs are injured in penetrative wound. That's such a patient has the operation: opening the cavity and making the revision of al gans and remove the injury.

### **6. Classification according to the region of saturation:**

There are wounds of neck, head and trunks, upper and lower extremities and sometimes wounds connect two parts of the body, they are called complex worry.

According to the number of injuries they determine single and plural (S.V.P.)

### **7. Combinative damages**

Besides the mechanical and other injures there can be combinative damages

### **CHARACTERISTICS OF WOUND PROCESS**

Wound process - this is the complex of successive changes, which take plac wound, and connective reactions of all organism.

Conditionally, we may divide this into general reactions of the organism and ing of the wound.

## **1. General reaction**

The complex of the biological reaction of the organism during the influence of damage we may observe like 2 successive stages.

1). During 1 -4 days from the moment of trauma there is observed the excitation of sympathetic nervous system, the elimination of the hormones of adrenal glands - insulin, ACTE, and glucocorticoids, into the blood. According to this the process of life activity becomes stronger: increase the main change process; decrease the mass of the body; increase the destruction of the proteins, lipids, and glycogen, decrease the penetration of cellular membrane.

In the cavity of a wound there is some quantity of microorganisms and destroy tissues, which dissolve and phagocytes. According to this, all process, which is present in the surrounding tissue of the wound, causes the general reaction in the whole organism. As a result, in the first period there is observed the increase of the body temperature, weakness, decrease the workability.

The analyses of blood notes the increase of the leucocytes quantity, sometimes - a small shift of leukocyte formula to the left. In analysis of urine may be proteins. During the general bleeding there is observed the decrease of hematocrit, quantity of erythrocytes, hemoglobin.

2). Starting from 4-5 days, the character of general reactions depends on parasympathetic nervous system. The main important components are mineral-corticoids, so-matotrophic hormone, aldosterone, and acetylcholine.

They observe the increase of the body mass, the normalization of proteins, the mobilizing of reparative abilities of the organism. In 4-5 days when the complications are absent; the intoxication, inflammation, pain are decreased. The analysis of blood and urine becomes normal.

## **2. Healing of the wound**

The reparation of the wound - the reparative process of damage tissue with resumption it's integrity and firmness.

For closing of the tissue defect there can be 3 main processes.

**The formation of the collagen** by fibroblasts. During the reparation of the wounds fibroblasts activates by macrophages. They proliferate and migrate to the place of injury, and connect with fibril structures through the fibronectin. In one time fibro plates synthesize the substance of extra cellular matrix. Collagens provide the liquidation of tissue defect and firmness of the stitch formation.

**Epithelization of the wounds** becomes under the influence of migration of the epithelial cells from the border of wound to its surface. The end epithelization of wound defect causes the barrier for microorganisms. But the migration from the border cannot close the defect, which does necessary in some cases to carry out a dermal plasty.

The decrease of the wound surface provides **effect of tissue tension** (the contraction of miofibroblasts).

### **Phases of wounds reparation**

Rufanov differ 2 phases: hydration and dehydration.

Girgolav determined 3 period of wounds reparation:

1. preparing period.
2. the period of regeneration.
3. the period of stitch formation.

In present time the most popular classification is (Cusin, 1977 year):

1. The phase of inflammation (1-5 day). It has period of vessel's changes and period o purifying of the wound from necrosis.
2. The phase of regeneration (6-14 day).
3. The phase of formation and stitch reorganization (begin from 15-th day).

#### **1) Inflammation phase**

##### ***Period of vessel's changes***

Trauma cause such destroys, which connects with microcirculatory vessels. Be sides the rupture of vessels there may be short time contraction and after that the dilata tion of micro-vessels. Biogenic amines, the system of complement cause the vasodilatetion and increasing of penetration of vessels. According to this the blood



stream becomes slower which makes the blood curdling harder and as a result the cellular and venous thrombosis takes place.

The increasing of perfusion provides to decreasing of oxygenation of tissues in the region of wound. Acidosis, destroys the protein's change and develops. During the destruction of cell proteins with destruction of cell free ions of  $K^+$  and  $H^+$ , which increases the osmotic pressure in tissues, makes the setback of the water, hydration of the tissue:

Prostaglandines cause vasodilatation, pyrogenic reaction and pain syndrome. Some changes of microcirculation provide to appearance of extra-vessel changes: exudation of the plasma and lymph, excretion and migration of leucocytes in wound's region.

According to this develops the edema and leucocytes infiltration of tissues, prepares the condition for clean of the wound.

### ***The period of the wound clean from necrotic tissues***

The most important components in the period are blood elements and enzymes. First days appear leucocytes surround the wound. 2-3 days appear lymphocytes at macrophages.

Neutrophilic leucocytes make phagocytation of the microorganism's necrotic mass, make the extra cellular proteolysis, and excrete the mediators of inflammation.

The main functions of macrophages - are excreting proteolytic ferments at phagocytosis of destructive by leucocytes necrotic tissues, take part in immune reactions.

## **2) Phase of regeneration**

Two main processes take place in a wound: wound's collagenisation, intensive growth of the blood and lymphatic vessels. In wound decrease the number of neutrophils, and increase the number of fibroblasts (cells of connective tissue which can synthesize the macromolecules of intracellular matrix). The main role of fibroblasts is synthesis of the components of connective tissues and formation of the collagens and elastic fibers. In this time the recanalisation and growth of blood

and lymphatic vessels wound region starts. The proliferation of capillaries becomes. Inflammatory process becomes less.

**3) Phase of formation and reorganization of the stitch** (15day - 6 month).

In this phase the synthetic activity of fibroblasts and other cells stops, and the *mz*

process led to strengthening of the stitch by the way of formation of the net by the he of elastic fibers, and appearance transferal between different bundles of collagen. Stein wounds recovered only 70-90% of the primary skin. The tissues with difficult structure have less possibility to regenerate. There can be stitch, but it cannot do the same function.

**The factors, which have influence on healing of the wound:**

- age of the patient;
- the condition of nutrition and body mass;
- the presence of secondary infection of the wound;
- the condition of blood circulation in zone of damage and organism in general;
- the presence of destroys of water-electrolytic balance;
- the immune status of the organism;
- chronic bypasses diseases;
- using anti-inflammatory medications.

The best reparative process has the child organism, it caused by presence in period of development anabolic processes. In such condition the reparation is shorter and is not so dangerous.

**Classical types of reparation:**

- reparation by primary tension;
- reparation by secondary tension;
- reparation under the crust.

1. Reparation by primary tension

"Sanatio per primam intentionem" is the most profitable heal of the wound. In such case stitch is thin and strong. Operation wounds have primary tension when the borders of wound connected. The quality of necrotic mass is small and small inflammation.

After the inflammation and clean from death cells in phase of regeneration between the walls of wound canal form the connection by connective tissue and by collagen and vessels. In this time becomes the growth of epithelial tissue from the borders of wound, and this is the barrier for microbial penetration.

Wounds, which have small diameter (1 cm), can repartee by "primary fibrinous commissure".

Primary tension has only uninfected wounds, or wounds with small infection.

According to this there is some aspects for primary tension:

- no infection in wound;
- connection the borders of wound;
- absence of the hematoma and other objects in wound;
- absence of the necrotic mass;
- good condition of the patient.

2. "Sanatio per secundam intentionem" - heals by suppuration by the help of granulate tissue. In this type of heals we can observe inflammation.

a. Conditions to heal by secondary tension:

- big quantity of microbes in wound;
- big defect of the skin;
- the presence of some objects or hematoma;
- the presence of necrotic mass;
- unfaourable condition of the patient.

b. The specialties of the inflammatory phase

The inflammation is stronger. Phagocytosis and lysis of devitalizative cells cause high concentration of toxins in surrounding tissue. This process cause bad microcirculation and increase the inflammation. This wound characterize by

invasion of microbes to surrounding tissues. On the border of this penetration is forms leukocytic accumulation.

After the cleaning of the wound starts second phase - this is phase of regeneration.

c. Structure and functions of the granulative tissue.

Granulative tissue - this is the special kind of connective tissue, which forms only during heal of the wound by second tension. In normal, granulative tissue does not develop without damage.

The formation of the granulative tissue.

During the regeneration by primary tension in second phase, wound process fills by granulative tissue.

The main component of the reparative process is the growth of the vessels. They go from deep to the surface and after that, make the land and go down to the fundus of the wound in this regions blood elements form, form fibroblasts, which give the growth of the connective tissue.

The islands of the granulative tissue appear in not clean wound (during the necrosis 2-3 day). The granulative tissue may form not only by the help of infection but also in clean wounds. It may happen in such case, when diastasis can be more than 1 sm., and when the capillaries do not go to the other side of the wound.

Components of the granulative tissue

The main components are 6 layers:

- Superficial leukocytic-necrotic layer. It consists of leucocytes, detritus and skinned cells. This layer is the whole period of reparation.
- Layer of the band vessels. Besides the vessels it consists of polyblasts. In this layer collagenic fibers may be formed.
- Layer of the vertical vessels. It is constructed from perivascular elements.
- Developing layer. This is the deepest part of the previous layer; this layer is characterized by polymorphism of the cells formation.

- Layer of the horizontal fibroblasts. It consists of monomorphic cellular elements, collagen fibers.

- Fibrous layer. It shows the process of granulative growing.

The means of granulative tissue:

1. Change the wound defect: the main plastic component.
2. This is the protection of the wound from microorganisms and some objects.
3. Sequestration and excretion of the necrotic mass.

During the normal process there develops not only granulative tissue but also starts the epithelization step by step, the granulative tissue transforms into rough connective tissue - scar forms.

#### Pathological granulation

During the influence of the "bad" factors, the process of granulation destroys. The granulation becomes pathological. Clinical symptoms are absence of the wound connection and appear the change of granulative tissue, which we observe. The wound becomes dim, acyanotic, sometimes cyanotic. It loses a turgor, becomes covered by a fur of a fibrin and pus.

The pathological granulation may be with formation of tubercles - hypertrophied granulations. They stop the granulation (S.V.Petrov).

#### Reparation under the crust

This reparation takes part during the small damage of the skin.

This process starts from the blood clotting, lymph clotting. Crust is the "biological bandage". Under the crust starts regeneration of the tissue (3-7 days). It's not necessary to cut crust if there is not inflammation.

But if under the crust there is necrotic mass, the operation is necessary.

"Crust is medial stage between primary and secondary tension".

#### **Call the doctor (for patient recommendation) if:**

- You see any of these changes around the incision:
  - More redness
  - More pain
  - Swelling

- Bleeding
- The wound is larger or deeper
- The wound looks dried out or dark
- The drainage coming from or around the incision:
  - Is increasing
  - Becomes thick, tan, green or yellow, or smells bad (pus)
- Your temperature is above 100 °F for more than 4 hours.

### **Removing the Old Dressing**

Doctor will tell patient how often to change your dressing. Be prepared before starting the dressing change:

- Clean your hands before touching the dressing.
- Make sure you have all the supplies you will need handy.
- Have a clean work surface for all of the equipment you will need.

Remove the old dressing:

- Carefully loosen the tape.
- Use a clean (not sterile) medical glove to grab the old dressing and pull it off.
- If the dressing sticks to the wound, get it wet and try again.
- Put the old dressing in a plastic bag and set it aside.
- Clean your hands *again* after you take off the old dressing.

### **Caring for the Wound**

You may use a gauze pad or soft cloth to clean the skin around your wound:

- Use a normal saline solution (salt water) or mild soapy water.
- Soak the gauze or cloth in the saline solution or soapy water, and gently dab or wipe the skin with it.
- Try to remove all drainage and any dried blood or other matter that may have built up on the skin.
- Do not use skin cleansers, alcohol, peroxide, iodine, or soaps with antibacterial chemicals. These can damage the wound tissue and slow your healing.

Doctor may also ask patient to irrigate, or wash out, your wound:

- Fill a syringe with salt water or soapy water, whichever your health care provider recommends.
- Hold the syringe 1 to 6 inches away from the wound, and spray hard enough into the wound to wash away drainage and discharge.
- Use a soft, dry cloth to carefully pat the wound dry.

Do not put any lotion, cream, or herbal remedies on or around your wound without asking your doctor first.

### **Putting on the New Dressing**

Place the clean dressing in the wound as your health care provider taught you to. You may be using a wet-to-dry dressing.

Clean your hands when you are finished.

Throw away all the old dressings and other used supplies in a waterproof plastic bag. Close it tightly, then double it before putting it in the trash.

Wash any soiled laundry from the dressing change separately from other laundry. Ask your doctor if you need to add bleach to the wash water.

Use a dressing only once. Never reuse it.

## **Stitches**

Stitches are primarily used if the cut is more than a quarter inch deep, is on the face, or reaches bone. Stitches (fig.40) help hold the wound together so it can heal properly. Stitches are removed between 3 to 14 days after they are put depending upon which area of the body was injured. Stitches on the face can be removed within 3 to 5 days but areas of high stress such as hands, elbows, and knees must stay in 10 to 14 days.

## **Laceration, puncture wound**

A laceration (fig.41 a) is a wound that is produced by the tearing of soft body tissue. This type of wound is often irregular and jagged. A laceration wound is often contaminated with bacteria and debris from whatever object caused the cut.

A puncture wound (fig.41 b) is usually caused by a sharp pointy object such as a nail, animal teeth, or a tack. This type of wound usually does not bleed excessively and can appear to close up. Puncture wounds are also prone to infection and should be treated appropriately.

## **Head and face reconstruction**

### **Alternative Names**

Craniofacial reconstruction; Orbital-craniofacial surgery

Head and face reconstruction is surgery to repair or reshape deformities of the head and face (craniofacial).

**Description.** Surgery for head and face deformities (craniofacial reconstruction) depends on the type and severity of deformity, and the condition of the patient.

In some cases, because surgical repairs involve the skull (cranium), brain, nerves, eyes, facial bones, and facial skin, a plastic surgeon (for skin and face) and a neurosurgeon (brain and nerves) work together. Head and neck surgeons may also perform craniofacial reconstruction operations.

The surgery is done while the patient is deep asleep and pain-free (under general anesthesia), and may take from 4 to more than 12 hours to complete. Some of the facial bones are cut and repositioned into a more normal facial structure.

Pieces of bone (bone grafts) may be taken from the pelvis, ribs, or skull to fill in the spaces where bones of the face and head have been moved. Small metal screws and plates may be used to hold the bones in place. The jaws may be wired together to hold the new bone positions in place.

If the surgery is expected to cause much swelling of the face, mouth, or neck, the airway can become blocked. If this is anticipated, the patient may have what is called a tracheotomy, in which a small hole is made in the neck, through which a tube (endotracheal tube) is placed in the airway (trachea). This allows the patient to breathe despite severe swelling of the face and upper airway that occurs after some operations and may last for weeks.

### **Why the Procedure is Performed**

Craniofacial reconstruction may be done if there are:

- Birth defects and deformities related to various conditions, including:
  - Apert syndrome
  - Cleft lip or palate
  - Craniosynostosis
  - Crouzon's disease
  - Hypertelorism (abnormally wide space between the eyes)
  - Treacher-Collins syndrome
- Deformities caused by surgery done to treat tumors
- Injuries to the head, face, or jaw
- Tumors

**Risks** for any anesthesia are: problems breathing; reactions to medications.

Risks for any surgery are: bleeding, infection.



Additional risks of surgery of the head and face are:

- Nerve (cranial nerve dysfunction) or brain damage
- Need for follow-up surgery, especially in growing children
- Partial or total loss of bone grafts
- Permanent scarring

### **After the Procedure**

Depending on the extent of surgery and the need to closely monitor the patient's breathing, the first 2 days after surgery may be spent in the intensive care unit. Without complications, most patients are able to leave the hospital within 1 week. Complete healing may take up to 6 weeks.

### **Outlook Prognosis**

Although not without risk, these surgeries usually result in a much more normal appearance.

Those who have suffered a traumatic injury often need to work through the psychological and emotional issues of the trauma itself and the change in their appearance. Both children and adults who have suffered a traumatic injury may suffer from posttraumatic stress disorder, depression, and anxiety disorders. Consulting a mental health professional or joining a support group can be helpful.

Likewise, parents of children with disfiguring craniofacial deformities often feel guilty or ashamed, especially when the deformities are due to a genetic condition. As younger children grow and become aware of their appearance, psychiatric symptoms may develop or worsen.

## **Skin smoothing surgery**

**Dermabrasion** is the removal of the top layers of the skin. It is a type of skin smoothing surgery.

**Description.** Dermabrasion is usually done while you are awake. The health care provider will apply a numbing medicine (local anesthesia) to the area of skin that will be worked on.

If you are having a complex procedure, you may be given medicines called sedatives to make you sleepy and less anxious, or you may receive general anesthesia, which allows you to sleep through surgery and not feel any pain during the procedure.

Dermabrasion uses a special device to gently and carefully "sand" the top surface of the skin down to normal, healthy skin. Petroleum jelly or antibiotic ointment is placed on the treated skin to reduce scab formation and scarring.

Dermabrasion may be helpful if you have:

- Age-related skin growths (seborrheic keratoses)
- Fine lines and wrinkles, such as around the mouth
- Precancerous growths (keratoses)
- Scars on the face due to acne, accidents, or previous surgery

Alternative treatments such as laser or chemical peels exist for many of these conditions. Always discuss your options with your health care provider.

Dermabrasion (fig.42) is usually done while you are awake. You will receive local anesthesia. This means the doctor will numb the area to be worked on.

A surgical instrument is used to gently and carefully "sand" the scar tissue off down to normal, healthy skin. The healing tissue is treated with ointments (such as petroleum jelly or antibiotic ointments) to reduce scab formation (crusting) and therefore reduce scar formation.

The skin may be treated with ointment and a wet or waxy dressing. After surgery, your skin will be quite red and swollen (fig.43). Eating and talking may be difficult. You may have some aching, tingling, or burning for a while after surgery. Your doctor can prescribe medicine to help control any pain.

Swelling usually goes away within 2 - 3 weeks. New skin starts to itch as it grows. If you had freckles, they may temporarily disappear.

If the treated skin remains red and swollen after healing has started, this may be a sign that abnormal scars are beginning to form. Talk to your doctor. Treatment may be available.

The new layer of skin will be a little swollen, sensitive, and bright pink for several weeks. Most patients can go back to normal activities in about 2 weeks. You should avoid any activity that could cause injury to the treated area. Avoid sports that involve balls, such as baseball, for 4 - 6 weeks.

Protect the skin from the sun for 6 - 12 months until your skin coloring has returned to normal.

**Risks** of dermabrasion include permanent skin coloring changes (either lighter, darker, or pinker). Excessive scars or keloids may also result.

The risks of any anesthesia include: reactions to medications,

infrequent but potentially severe heart or breathing problems.

The risks of any surgery include: bleeding, infection, scarring, skin discoloration.

## **Outlook Prognosis**

Doctors recommend that men who have this procedure avoid shaving for a while, and use an electric razor when they do begin shaving again.

The new layer of skin will be a little swollen, sensitive, and bright pink for several weeks. Most patients can go back to normal activities in about 2 weeks. You should avoid any activity that could cause injury to the treated area. Avoid sports that involve balls, such as baseball, for 4 - 6 weeks.

Keep your face out of chlorinated water (such as that used in pools) for at least 4 weeks.

Protect the skin from the sun for 6 - 12 months until your skin coloring has returned to normal. Hypo-allergenic makeup may be worn to hide any discoloring. When full color occurs, it should closely match the surrounding skin, making the procedure almost impossible to detect.

For about 3 weeks after surgery, your skin will turn red when you drink alcohol.

# **Scars**

## **Alternative Names**

Hypertrophic scar; Keloid scar; Scar – hypertrophic

A scar is a permanent patch of skin that grows over a wound. It forms when your body heals itself after a cut, scrape, burn or sore. You can also get scars from surgery that cuts through the skin, from infections like chickenpox, or skin conditions like acne. Scars are often thicker, as well as pinker, redder or shinier, than the rest of your skin.

How scar looks depends on:

- How big and deep your wound is
- Where it is
- How long it takes to heal
- Your age
- Your inherited tendency to scar

Scars usually fade over time but never go away completely. If the way a scar looks bothers you, various treatments might minimize it. These include surgical revision, dermabrasion, laser treatments, injections, chemical peels and creams.

Keloids (fig.44) are overgrowths of scar tissue that follow skin injuries. Keloids may appear after such minor trauma as ear piercing. Dark skinned individuals tend to form keloids more readily than lighter skinned individuals.

## **Keloid, pigmented**

Keloids are overgrowths of scar tissue that follow skin injuries. Keloids may appear after such minor trauma as ear piercing. Dark-skinned individuals tend to form keloids more readily than lighter skinned individuals. These patches of keloid have become darkly pigmented.

**Keloids.** Keloids are the excess growth of scar tissue at the site of a healed skin injury.

**Causes.** Keloids occur from such skin injuries as: acne, burns, chickenpox, ear piercing, minor scratches, surgical cuts, traumatic wounds, vaccination sites.

They are more common in people ages 10 to 20, and in African Americans, Asians, and Hispanics. Keloids often run in families. Keloidosis is a term used when many or repeated keloids occur.

### **Symptoms**

A skin lesion that is:

flesh-colored, red, or pink; located over the site of a wound or injury; lumpy (nodular) or ridged.

The lesion may itch while it is forming and growing.

### **Exams and Tests**

Diagnosis is based on the appearance of the skin or scar. A skin biopsy may be needed to rule out other skin growths (tumors).

### **Call doctor if:**

- You develop keloids and want to have them removed or reduced
- You develop new symptoms

### **Treatment**

Keloids often do not need treatment. They may be reduced in size by:

corticosteroid injections; freezing (cryotherapy); laser treatments; radiation, surgical removal.

### **Outlook Prognosis**

Keloids usually are not medically dangerous, but they may affect the appearance. In some cases, they may become smaller, flatter, and less noticeable over a period of several years.

Exposure to the sun during the first year after the keloid forms will cause the keloid to tan darker than the skin around it. This dark color may be permanent.

Removing the keloid may not be permanent. Surgical removal may cause a larger keloid scar.

### **Possible Complications**

- Cosmetic changes that affect the appearance
- Discomfort, tenderness of the keloid
- Irritation from rubbing on clothing or other forms of friction
- Limited mobility (if the keloids are extensive)
- Psychological distress if the keloid is large or disfiguring
- Return of the keloid

**Prevention.** You can prevent discoloration from sun exposure by covering the forming keloid with a patch or Band-Aid, and by using sunblock when spending time in the sun. Continue these extra protection measures for at least 6 months after injury or surgery for an adult, or up to 18 months for a child.

Imiquimod cream has recently been used to prevent keloids from forming after surgery, or to prevent keloids from returning after surgery to remove them.

## **Facial paralysis**

### **Alternative Names**

Paralysis of the face

Facial paralysis is the total loss of voluntary muscle movement of one side of the face.

### **Considerations**

About 75% of all adult facial paralysis cases are due to Bell's palsy, a condition in which the facial nerve becomes inflamed.

Stroke may cause facial paralysis. When stroke is the cause of facial paralysis, the person may still be able to close the eye on the affected side, as well as wrinkle the forehead. People with Bell's palsy cannot do either of these. With a stroke, other muscles on one side of the body may also be involved.

Facial paralysis due to a brain tumor generally develops slowly and causes headaches, seizures, or hearing loss.

In newborns, facial paralysis may result from birth trauma.

**Causes:** Bell's palsy; birth trauma (newborns); brain tumor; infection, Lyme disease; sarcoidosis, stroke.

**Call your doctor** if you have weakness or numbness in your face. Seek emergency medical help if you experience these symptoms along with a severe headache, seizure, or blindness.

### **What to Expect at Your Office Visit**

The doctor will perform a physical exam and ask you questions about your medical history and symptoms, including:

- Are both sides of the face affected?
- Have you recently been sick or injured?
- What other symptoms do you have? For example, drooling, excessive tears from one eye, headaches, seizures, vision problems, weakness, or paralysis.

**Home Care.** Treatment depends on the cause. Follow your health care provider's treatment recommendations. Sometimes steroids and acyclovir may be given depending on the cause.

If the eye cannot be fully closed, the cornea must be protected from drying out with prescription eye drops or gel.

Tests that may be done include:

blood tests, including blood sugar, CBC, ESR, Lyme test; CT scan of the head; electromyography; MRI of the head.

The doctor may refer you to a physical, speech, or occupational therapist. If facial paralysis from Bell's palsy persists for more than 6 - 12 months, plastic surgery may be recommended to improve eye closure and facial appearance.

# Sore throat

## Alternative Names

Throat - sore; Pain - throat

A sore throat is discomfort, pain, or scratchiness in the throat. A sore throat often makes it painful to swallow.

## Considerations

Sore throats are common. Most of the time the soreness is worse in the morning and improves as the day progresses.

Like colds, the vast majority of sore throats are caused by viral infections, such as a cold or flu. This means most sore throats will NOT respond to antibiotics. Many people have a mild sore throat at the beginning of every cold. When the nose or sinuses become infected, drainage can run down the back of the throat and irritate it, especially at night. Or, the throat itself can be infected.

Some viruses can cause specific types of sore throat. For example, Coxsackievirus sometimes causes blisters in the throat, especially in the late summer and early fall. Mononucleosis and the flu can also cause specific viral throat infections.

Strep throat is the most common bacterial cause of sore throat. Because strep throat can occasionally lead to rheumatic fever, antibiotics are given. Strep throat often includes a fever (greater than 101°F), white, draining patches on the throat, and swollen or tender lymph glands in the neck. Children may have a headache and stomach pain.

A sore throat is less likely to be strep throat if it is a minor part of a typical cold (with runny nose, stuffy ears, cough, and similar symptoms). Strep can NOT be accurately diagnosed by looking at the throat alone. It requires a laboratory test.

Sometimes breathing through the mouth will cause a sore throat in the absence of any infection. During the months of dry winter air, some people will wake up with a sore throat most mornings. This usually disappears after having something to drink.

A sore throat may also be caused by something stuck in the throat or allergies (allergic rhinitis).

With a sore throat, sometimes the tonsils or surrounding parts of the throat are inflamed. Either way, removing the tonsils to try to prevent future sore throats is not recommended for most children.

## Causes

- Breathing through the mouth (can cause drying and irritation of the throat)
- Common cold
- Endotracheal intubation (tube insertion)
- Flu
- Infectious mononucleosis
- Something stuck in the throat
- Surgery such as tonsillectomy and adenoidectomy
- Viral pharyngitis
- Parapharyngeal phlegmon.

A **peritonsillar abscess (PTA)** is a localized accumulation of pus in the peritonsillar tissues that forms as a result of suppurative tonsillitis (fig.45). Progressive inflammation and suppuration may extend to directly involve the soft palate, the lateral wall of the pharynx, and, occasionally, the base of the tongue.

The soft palate, which is erythematous and edematous, is displaced anteriorly. The patient has a "hot potato–sounding" voice.

Pus is aspirated through a wide-bore needle from the right peritonsillar abscess (fig.46). An additional incision will be made to drain any other pus pockets.

**Call the doctor** if there is:

- Excessive drooling in a young child
- Fever, especially 101°F or greater
- Pus in the back of the throat
- Red rash that feels rough, and increased redness in the skin folds
- Severe difficulty swallowing or breathing
- Tender or swollen lymph glands in the neck

## What to Expect at Office Visit

Doctor will perform a physical examination. He or she may want to know some details about the sore throat, such as:

- How long has the sore throat been present?
- Have other family members had recent sore throats?
- Is the pain increasing, staying the same, or decreasing?
- Are you able to swallow saliva, fluids, and food?
- Is there excessive drooling (in infants)?
- Are you hoarse?
- Is it worse at night? Are you able to sleep?



- Are you breathing through your mouth?
- Is the soreness better in the morning? Better with moist air or mist? Better with medication?
- What other symptoms are also present - noisy breathing, fever, wheezing, allergies, rash?
- Have you had a recent injury or surgery?
- Are there swollen lymph glands in your neck?
- Are there sores or pus in the back of your throat?
- Is there a sensation of gagging?
- What medications are you taking?
- What is your typical daily diet?

## **Home Care**

Most sore throats are soon over. In the meantime, the following remedies may help:

- Drink warm liquids. Honey or lemon tea is a time-tested remedy.
- Gargle several times a day with warm salt water (1/2 teaspoon of salt in 1 cup water).
- Cold liquids or popsicles help some sore throats.
- Sucking on hard candies or throat lozenges can be very soothing, because it increases saliva production. This is often as effective as more expensive remedies, but should not be used in young children because of the choking risk.
- Use a cool-mist vaporizer or humidifier to moisten and soothe a dry and painful throat.
- Try over-the-counter pain medications, such as acetaminophen. Do NOT give aspirin to children.

## **The following diagnostic tests may be performed:**

- Complete blood count
- Monospot test (to rule out mononucleosis)
- Throat culture and rapid strep test

## **Treatment**

Usually, treatment will be delayed until lab test results are known. Doctors will often begin treatment of a sore throat immediately if there is a family history of rheumatic fever, if the patient has scarlet fever, or if rheumatic fever is commonly occurring in the community at the time.

Antibiotics are usually NOT wise if the strep test or throat culture is negative, and they can have serious side effects.

When antibiotics are started, it is important to complete the entire course as directed, even after symptoms improve. Children can return to school or day care 24 hours after antibiotics are started.

For a sore throat caused by infectious mononucleosis, rest and home treatment is recommended.

For a sore throat caused by bacterial tonsillitis, antibiotic treatment may be recommended. Some tonsillitis is viral and will clear up without treatment (surgery is rarely necessary). Recurrent or persistent sore throats without bacterial infection may be due to allergies and require anti-allergy treatment.

**Prevention.** Clean your hands frequently, especially before eating. This is a powerful way to help prevent many sore throat infections. You might avoid some sore throats by reducing contact with people with sore throats, but often these people are contagious even before they have symptoms, so this approach is less effective.

Not too long ago, tonsils were commonly removed in an attempt to prevent sore throats. This is no longer recommended in most circumstances.

A cool mist vaporizer or humidifier can prevent some sore throats caused by breathing dry air with an open mouth.

## **Earache (Otalgia)**

### **Alternative Names**

Otalgia; Pain - ear

An earache can be a sharp, dull, or burning pain in one or both ears. The pain may be temporary or constant.

### **Considerations**

The symptoms of an ear infection may include:

ear pain, fever, fussiness, increased crying, irritability.

Many children will have temporary and minor hearing loss during, and right after, an ear infection. Permanent hearing loss is rare, but the risk increases with the number of infections.

### **Causes**

Ear pain in children is often caused by a buildup of fluid and pressure behind the eardrum, in the area called the middle ear. The middle ear is connected to the nasal passages by a short narrow tube, the Eustachian tube. The Eustachian tube allows normal fluids to drain out of the middle ear, and helps keep the pressure in your ear equalized.

A cold or allergy can block the Eustachian tube due to inflammation and the buildup of secretions. This is especially likely in small children, because their Eustachian tube is shorter and more horizontal. Closing of the Eustachian tube prevents the normal flow of fluid from the middle ear. The fluid begins to build up, which can cause stuffiness, pain, hearing loss, and an ear infection.

Ear pain in adults is less likely to be from an ear infection. What you perceive as ear pain may actually be coming from another location, such as your temporomandibular joint, your teeth, throat, or other location. This is called "referred" pain.

Causes of earache:

- Arthritis of the jaw
- Ear infection
  - Middle ear infection - acute
  - Middle ear infection - chronic
  - Outer ear (canal) infection - acute
  - Outer ear (canal) infection - chronic
  - Outer ear (canal) infection - malignant
- Ear injury from pressure changes (from high altitudes and other causes)
- Object stuck in the ear or severely impacted ear wax
- Ruptured or perforated eardrum
- Sinus infection
- Sore throat with referred pain to the ears
- Temporomandibular joint syndrome (TMJ)
- Tooth infection

Ear pain in a child or infant is not always from infection, however. Other causes include:

ear canal irritation from cotton-tipped swabs; soap or shampoo staying in the ear; water from bathing.

**Call doctor if:**

- Your child has a high fever or severe pain or seems sicker than is usual for an ear infection
- New symptoms appear, especially:
  - Dizziness

- Severe headache
- Swelling around the ear
- Weakness of the face muscles
- Severe pain suddenly stops; this may be a sign of a ruptured eardrum
- Symptoms (pain, fever, or irritability) get worse or do not improve within 24 - 48 hours

### **What to Expect at Office Visit**

The doctor will do a physical examination, which may include examination of the: ear, mastoid (bony part behind the ear), nose, throat.

Pain, tenderness, or redness of the mastoid often indicates a serious infection.

During the examination, the doctor will ask questions about the ear pain, such as:

- When did it begin?
- Is it getting better, worse, or staying the same?
- Is the pain constant?
- What other symptoms are present?
- Is there ear pressure?
- Is there drainage from the ear?
- Are there unusual ear noises?
- Is there a fever?
- Is there pain in the bone behind the ear?
- Is there hearing loss?

**Home Care.** The following steps may help an earache:

- A cold pack or cold wet wash cloth applied to the outer ear for 20 minutes may reduce pain.
- For children old enough to safely chew gum, chewing may help relieve the pain and pressure of an ear infection.
- If a child is uncomfortable lying down, resting in an upright position can help reduce pressure in the middle ear.
- Olive oil or over-the-counter ear drops are gentle and effective, as long as the eardrum has not ruptured. Prescription drops, such as Auralgan, are also effective for pain relief.
- Over-the-counter pain relievers, such as acetaminophen or ibuprofen, can provide relief for children and adults with an earache. (Do NOT give aspirin to children.)

You can relieve ear pain caused by rapidly descending from high altitudes by swallowing or chewing gum. Allowing infants to suck on a bottle while the plane is descending can help.

Because most ear infections improve within 24 hours of receiving medical care, health care providers are less likely to prescribe antibiotics immediately. Your doctor will often wait to see if symptoms continue or worsen.

If antibiotics are prescribed, it is important to take all of the prescribed antibiotics on schedule.

Children with persistent or recurring ear infections may need ear tubes inserted to help the middle ear begin working properly again. Inserting ear tubes is a simple and effective surgical procedure.

**Prevention.** The following steps can help prevent earaches:

- Avoid smoking near children. Smoking has been shown to cause millions of ear infections each year in children.
- Prevent outer ear infections by not putting objects in the ear, and drying the ear after bathing or swimming.
- Take steps to control allergies. In particular, avoid allergy triggers. Steroid nasal spray may help reduce ear infections. However, over-the-counter sedating antihistamines and decongestants do NOT prevent ear infections.

## Swollen lymph nodes

### Alternative Names

Swollen glands; Glands - swollen; Lymph nodes - swollen; Lymphadenopathy

A **lymph node** is a small ball or an oval-shaped organ of the immune system, distributed widely throughout the body including the armpit and stomach/gut and linked by lymphatic vessels. Lymph nodes are garrisons of B, T, and other immune cells. Lymph nodes are found all through the body, and act as filters or traps for foreign particles. They are important in the proper functioning of the immune system. They are packed tightly with the white blood cells called lymphocytes and macrophages.

Lymph nodes also have clinical significance (fig.47). They become inflamed or enlarged in various conditions, which may range from trivial, such as a throat infection, to life-threatening such as cancers. In the latter, the condition of lymph nodes is so significant that it is used for cancer staging, which decides the treatment to be employed, and for determining the prognosis.

Lymph nodes can also be diagnosed by biopsy whenever they are inflamed. Certain diseases affect lymph nodes with characteristic consistency and location.

### Lymph nodes of the head and neck

- Cervical lymph nodes
  - Anterior cervical: These nodes, both superficial and deep, lie above and beneath the sternocleidomastoid muscles. They drain the internal structures of the throat as well as part of the posterior pharynx, tonsils, and thyroid gland.
  - Posterior cervical: These nodes extend in a line posterior to the sternocleidomastoids but in front of the trapezius, from the level of the Mastoid portion of the temporal bone to the clavicle. They are frequently enlarged during upper respiratory tract infections.
- **Submandibular:** These nodes are located just below the angle of the mandible, along the underside of the jaw on either side. They drain the tonsillar and posterior pharyngeal region, including the structures in the floor of the mouth and the maxillary anterior, bicuspid and 1st and 2nd molars. They also drain all of the mandibular teeth except the central incisors.

Retropharyngeal: Drains lymph from the soft palate and the 3rd molars.

- **Submental:** These nodes are just below the chin. They drain the central incisors and midline of lower lip and tip of the tongue.
- Supraclavicular lymph nodes: These nodes are in the hollow above the clavicle, just lateral to where it joins the sternum. They drain a part of the thoracic cavity and abdomen. Virchow's node is a left supraclavicular lymph node that receives the lymph drainage from most of the body (especially the abdomen) via the thoracic duct and is thus an early site of metastasis for various malignancies.

The term "swollen glands" refers to enlargement of one or more lymph nodes.

In a child, a node is considered enlarged if it is more than 1 centimeter (0.4 inch) in diameter.

## Considerations

In maxillofacial areas where the lymph nodes can be felt (with the fingers) include:

neck (there is a chain of lymph nodes on either side of the front of the neck, both sides of the neck, and down each side of the back of the neck), under the jaw and chin, behind the ears, on the back of the head.

Lymph nodes can become swollen from infection, inflammatory conditions, an abscess, or cancer. Other causes of enlarged lymph nodes are rare. By far, the most common cause of swollen lymph nodes is infection.

When swelling appears suddenly and is painful, it is usually caused by injury or an infection. Enlargement that comes on gradually and painlessly may, in some cases, result from cancer or a tumor.

**Causes.** Infections that commonly cause swollen lymph nodes include:

abscessed or impacted tooth, ear infection, colds, flu, and other infections, gingivitis, mononucleosis, mouth sores, sexually transmitted diseases, tonsillitis, tuberculosis, skin infections

Immune or autoimmune disorders that can cause swollen lymph nodes include rheumatoid arthritis and HIV.

Cancers that can often cause swollen lymph nodes include leukemia, Hodgkin's disease, or non-Hodgkin's lymphoma. However, many other cancers may also cause this problem.

Which lymph nodes are swollen depends on the type of problem and the body parts involved. Identifying the location can help determine the possible cause.

Swollen lymph nodes may also be caused by some medications (such as phenytoin for seizures) or certain vaccinations (such as typhoid immunization).

**Call doctor if:**

- Your lymph nodes do not get smaller after several weeks or continue to get larger.
- They are red and tender.
- They feel hard, irregular, or fixed in place.
- You have fever, night sweats, or unexplained weight loss.
- Any node in a child is larger than 1 centimeter (a little less than 1/2 inch) in diameter.

### **What to Expect at Office Visit**

Doctor will perform a physical examination, checking all of your palpable lymph nodes for size, texture, warmth, tenderness, and other features.

Doctor may ask the following medical history questions:

- Which nodes are affected?
- Is the swelling the same on both sides?
- When did the swelling begin?
- How long has it lasted (how many months or weeks)?
- Did it begin suddenly or did it develop gradually?
- Is the swelling increasing in size?

- Are the number of nodes that are swollen increasing?
- Are any of the swollen nodes painful or tender when you gently press on them?
- Is the skin over or around the nodes red?
- Have you had any other symptoms?

**Home Care.** Soreness in lymph nodes usually disappears in a couple of days without treatment, but the nodes may not return to normal size for several weeks after the infection has cleared. Generally, if they are painful, it is because they swell rapidly in the early stages of fighting an infection.

**The following diagnostic tests may be performed:**

physical exam; blood tests, including liver function tests, kidney function tests, and CBC with differential; lymph node biopsy; chest x-ray; liver-spleen scan.

# Trigeminal neuralgia

## Alternative Names

Tic douloureux

Trigeminal neuralgia is a nerve disorder that causes a stabbing or electric-shock-like pain in parts of the face.

**Causes.** The pain of trigeminal neuralgia comes from the trigeminal nerve. This nerve carries pain, feeling, and other sensations from the brain to the skin of the face. It can affect part or all of the face, and the surface of the eye.

The condition usually affects older adults, but it may affect anyone at any age. Trigeminal neuralgia may be part of the normal aging process.

Trigeminal neuralgia may be caused by:

- Multiple sclerosis
- Pressure on the trigeminal nerve from a swollen blood vessel or tumor

Often, no specific cause is found.

Doctors are more likely to find a cause if the patient is younger than age 40.

## Symptoms

- Very painful, sharp electric-like spasms that usually last a few seconds or minutes, but can become constant



- Pain is usually only on one side of the face, often around the eye, cheek, and lower part of the face
- Pain may be triggered by touch or sounds
- Painful attacks of trigeminal neuralgia can be triggered by common, everyday activities, such as:

brushing teeth, chewing, drinking, eating, lightly touching the face; shaving.

## **Exams and Tests**

A neurologic examination is usually normal.

Tests that are done to look for the cause of the problem include:

blood tests; MRI of the head; trigeminal reflex testing.

## **Treatment**

Your primary care physician, a neurologist, or a pain specialist may be involved in your care.

Certain medicines sometimes help reduce pain and the rate of attacks. These medicines include:

- Anti-seizure drugs (carbamazepine, gabapentin, lamotrigine, phenytoin, valproate, and pregabalin)
- Muscle relaxants (baclofen, clonazepam)
- Tricyclic antidepressants (amitriptyline, nortriptyline, or carbamazepine)

Some patients may need surgery to relieve pressure on the nerve. Techniques include:

- Cutting or destroying part of the trigeminal nerve
- Stereotactic radiosurgery
- Surgery to remove a blood vessel or tumor that is putting pressure on the trigeminal nerve

**Outlook Prognosis.** The pain of trigeminal neuralgia comes from the trigeminal nerve. This nerve carries pain, feeling, and other sensations from the brain to the skin of the face. It can affect part or all of the face, and the surface of the eye.

The condition usually affects older adults, but it may affect anyone at any age. Trigeminal neuralgia may be part of the normal aging process.

Trigeminal neuralgia may be caused by:

- Multiple sclerosis
- Pressure on the trigeminal nerve from a swollen blood vessel or tumor

Often, no specific cause is found.

Doctors are more likely to find a cause if the patient is younger than age 40.

## Shock

Shock is a life-threatening condition that occurs when the body is not getting enough blood flow. This can damage multiple organs. Shock requires immediate medical treatment and can get worse very rapidly.

### Considerations

Major classes of shock include:

- Cardiogenic shock (associated with heart problems)
- Hypovolemic shock (caused by inadequate blood volume)
- Anaphylactic shock (caused by allergic reaction)
- Septic shock (associated with infections)
- Neurogenic shock (caused by damage to the nervous system)

Shock can be **caused** by any condition that reduces blood flow, including:

- Heart problems (such as heart attack or heart failure)
- Low blood volume (as with heavy bleeding or dehydration)
- Changes in blood vessels (as with infection or severe allergic reactions)
- Certain medications that significantly reduce heart function or blood pressure

Shock is often associated with heavy external or internal bleeding from a serious injury. Spinal injuries can also cause shock.

Toxic shock syndrome is an example of a type of shock from an infection.

**Symptoms.** A person in shock has extremely low blood pressure. Depending on the specific cause and type of shock, symptoms will include one or more of the following:

anxiety or agitation/restlessness, bluish lips and fingernails, chest pain, confusion, dizziness, lightheadedness, or faintness; pale, cool, clammy skin; low or no urine output; profuse sweating, moist skin; rapid but weak pulse; shallow breathing; unconsciousness.

### First Aid

- Call for immediate medical help.
- Check the person's airway, breathing, and circulation. If necessary, begin rescue breathing and CPR.
- Even if the person is able to breathe on his or her own, continue to check rate of breathing at least every 5 minutes until help arrives.
- If the person is conscious and does NOT have an injury to the head, leg, neck, or spine, place the person in the shock position. Lay the person on the back and elevate the legs about 12 inches. Do NOT elevate the head. If raising the legs will cause pain or potential harm, leave the person lying flat.
- Give appropriate first aid for any wounds, injuries, or illnesses.
- Keep the person warm and comfortable. Loosen tight clothing.

#### IF THE PERSON VOMITS OR DROOLS

- Turn the head to one side so he or she will not choke. Do this as long as there is no suspicion of spinal injury.
- If a spinal injury is suspected, "log roll" him or her instead. Keep the person's head, neck, and back in line, and roll him or her as a unit.

#### DO NOT

- Do NOT give the person anything by mouth, including anything to eat or drink.
- Do NOT move the person with a known or suspected spinal injury.
- Do NOT wait for milder shock symptoms to worsen before calling for emergency medical help.

**Prevention.** Learn ways to prevent heart disease, falls, injuries, dehydration, and other causes of shock. If you have a known allergy (for example, to insect bites or stings), carry an epinephrine pen. Your doctor will teach you how and when to use it.

Once someone is already in shock, the sooner shock is treated, the less damage there may be to the person's vital organs (such as the kidney, liver, and brain). Early first aid and emergency medical help can save a life.

## Tracheostomy

A tracheostomy is a surgical procedure to create an opening through the neck into the trachea (windpipe). A tube is usually placed through this opening to provide an airway and to remove secretions from the lungs. This tube is called a tracheostomy tube or trach tube (fig. 48).

**Description.** General anesthesia is used, unless the situation is critical. In that case, local anesthesia is injected into the area to reduce the discomfort caused by the procedure.

The neck is cleaned and draped. Surgical cuts are made to expose the tough cartilage rings that make up the outer wall of the trachea. The surgeon then creates an opening into the trachea and inserts a tracheostomy tube.

### **Why the Procedure is Performed**

A tracheostomy may be done if you have:

- A large object blocking the airway
- An inability to breathe on your own
- An inherited abnormality of the larynx or trachea
- Breathed in harmful material such as smoke, steam, or other toxic gases that swell and block the airway
- Cancer of the neck, which can affect breathing by pressing on the airway
- Paralysis of the muscles that affect swallowing
- Severe neck or mouth injuries
- Surgery around the voicebox (larynx) that prevents normal breathing and swallowing

The **risks** for any anesthesia are:

- Problems breathing
- Reactions to medications, including heart attack and stroke

The risks for any surgery are:

bleeding, infection; nerve injury, including paralysis.

Other risks include:

damage to the thyroid gland; erosion of the trachea (rare); puncture of the lung and lung collapse; scar tissue in the trachea that causes pain or trouble breathing.

### **After the Procedure**

If the tracheostomy is temporary, the tube will eventually be removed. Healing will occur quickly, leaving a minimal scar. Sometimes, a surgical procedure may be needed to close the site (stoma).

Occasionally a stricture, or tightening of the trachea may develop, which may affect breathing.

If the tracheostomy tube is permanent, the hole remains open.

## **Outlook Prognosis**

Most patients need 1 to 3 days to adapt to breathing through a tracheostomy tube. It will take some time to learn how to communicate with others. At first, it may be impossible for the patient to talk or make sounds.

After training and practice, most patients can learn to talk with a tracheostomy tube. Patients or family members learn how to take care of the tracheostomy during the hospital stay. Home-care service may also be available.

You should be able to go back to your normal lifestyle. When you are outside, you can wear a loose covering (a scarf or other protection) over the tracheostomy stoma (hole). Use safety precautions when you are exposed to water, aerosols, powder, or food particles.

The trachea, or windpipe, carries air from the larynx to the bronchi and lungs.

The indications for tracheostomy include (fig.49):

- prolonged intubation during the course of a critical illness
- subglottic stenosis from prior trauma
- obstruction from obesity for sleep apnea
- congenital (inherited) abnormality of the larynx or trachea
- severe neck or mouth injuries
- inhalation of corrosive material smoke or steam
- presence of a large foreign body that occludes the airway
- paralysis of the muscles that affect swallowing causing a danger of aspiration
- long term unconsciousness or coma

General anesthesia is used and the patient is deep asleep and pain-free. The neck is cleaned and draped. Incisions (Fig.49) are made to expose the tough cartilage rings that make up the outer wall of the trachea.

Most patients require 1 to 3 days to adapt to breathing through a tracheostomy tube. Communication will require adjustment. Initially, it may be impossible for the patient to talk or make sounds. After training and practice, most patients can learn to talk with a trach tube. Patients or parents learn how to take care of the tracheostomy during the hospital stay. Home-care service may also be available. Normal lifestyles are encouraged and most activities can be resumed. When outside a loose covering for the tracheostomy stoma (hole) (a scarf or other protection) is recommended. Other safety precautions regarding exposure to water, aerosols, powder or food particles must be adhered to.

After treatment of the underlying problem that necessitated the tracheostomy tube initially, the tube is easily removed, and the hole heals quickly, with only a small scar (fig.50).

## The organization of help to the oncological stomatological patient.

**Oncology** is the branch of medicine dealing with tumors (cancer). A medical professional who practices oncology is an *oncologist*. The term originates from the Greek "Ογκολογία" derived from *onkos* (όγκος), meaning bulk, mass, or tumor, and the suffix *-logy* (-λογία), meaning "study of" or "to talk about".

The oncology – science which studies the origin, development, prevalence of tumours, opportunities of their diagnostics, treatment and preventive measures.

Our focus will be on its branch - the oncological stomatology. It studies oncological problems or localization of tumours in maxillofacial area in stomatology. There is a set of tumour definitions in the medical literature. What is understood under this definition?

**Tumour** is the pathological overgrowth of tissues, which arises spontaneously and is characterized by structural polymorphism and functional independence, these properties being inherited during cell division.

The given definition does not describe the whole clinical and morphological picture of the tumour process. To solve this problem of the definition we can highlight **3 interconnected directions**:

1. Biological - experimental oncology. It studies reasons, patterns and mechanisms of growth of tumours.
2. Individual - clinical oncology. Studies reasons of occurrence, pathogenesis, clinical displays of tumour development, develops methods of diagnostics, treatment and preventive measures of concrete displays of tumours of various localizations.
3. Social - study of prevalence and character of tumours (epidemiology), reasons of their occurrence and development, sexual as well as age structure of patients, etc. Social and medical value of the problem of malignant new growths of maxillofacial area is caused by high occurrence of the disease and the subsequent death rate of the patients. It is the result of the untimely diagnostics and insufficient literacy about clinic of disease and medical tactics.

Nowadays the given service is presented by scientific research institutes, oncological clinics, oncological branches and the consulting rooms.

The oncological service of the country is headed by the Ministry of Health.

Problems of malignant formations cannot be solved by the efforts of the individual countries. International cooperation is of great importance. The basic international

organization is the International Anticarcinogenic Union. It organizes congresses that summarize scientific achievements in the field of oncology every four years. United Nations has the Oncological Department in the World Health Organization (WHO). The department has the scholarship fund for training of the highly skilled oncologists.

Oncological clinic is the basic link in the struggle against cancer.

**Main tasks of the department of the head and neck:**

Study of prevalence of formations on the head and/or neck;

The organization of preventive actions among the population;

The organization of general educational work on the given section;

Early diagnostics of the premalignant diseases and malignant formations of the head and neck;

Adequate treatment of tumours;

Prophylactic clinical examination of patients;

Rehabilitation of the patients;

Introduction of new methods of diagnostics and treatment of patients with tumours of the head and neck;

The analysis of the reasons of late diagnostics and untimely treatment of patients with tumours of the head and neck;

Training of doctors - stomatologists on the basis of oncological clinics.

Early detection of the malignant tumour is a prerequisite for its successful treatment.

**History of the patient** usually offers clues that may be suggestive of a malignant process:

- the living condition and habits;
- the area of living.

At its initial stages a tumour is unlikely to produce any complaints. As the suspicion of a malignancy is sometimes based only on a few indistinct symptoms, the meticulous questioning is mandatory. It is therefore necessary to inquire where there has been any minor change in the patient's well-being. Of great importance is what is referred to as the syndrome of minor symptoms and signs, i.e. the state of discomfort that may be indicative of the malignancy:

- fatigability without apparent cause and a reduction in working capability;
- rejection or unwillingness to eat certain foods;
- drowsiness;
- apathy to what used to be of interest;
- "a foreign body" sensation;
- abdominal discomfort rather than pain (e.g. a feeling of heaviness);
- lack of satisfaction after urination or defecation, ect.

Furthermore, a change in size, color or consistency of a pre-existing lesion (e.g. a birthmark) is not infrequently of a diagnostic value.

The earlier the diagnosis of the malignant tumour, the better the prognosis. As the patient with malignancy may first report to a physician of whatever speciality, the oncological alertness is important for each health care professional.

**The oncological alertness implies:**

1. Physician's knowledge of early and/or atypical symptoms and signs of malignancy and its complications.
2. Physician's knowledge of the clinical pictures of premalignant conditions and their treatment.
3. The timely referral of patients with supposedly malignant conditions to specialized medical centres.
4. The adequacy of the patient's examination by the physician who was the first to suspect the malignancy irrespective of their speciality.

Persistent progression of symptoms is often a hallmark of a malignant condition. The history of the disease is often short in duration; on the other hand, a long-standing chronic inflammation or benign tumour may precede a malignant process.

The **physical examination** is invariably based on routine methods:

- inspection;
- palpation;
- auscultation.

Premalignant conditions include diffuse and focal overgrowth of the epithelium of the skin and mucous membranes, which can be recognized through inspection and endoscopy.

The examples might be as follows:

- leukoplakia, or ``white spots``, i.e. vegetations of the epithelium covering mucous membranes, the changes being undetectable on palpation;
- certain benign cutaneous lesions (e.g. papillomas, polyps, birth marks);
- different forms of senile dyskeratosis.

**Pain** is not a characteristic feature of tumour, with the exception of tumours arising from blood vessels and neural tissues, which exert pressure on the tissues. Usually, the pain is related to the distention of the adjacent tissues, infiltration of the nerves or organ insufficiency.

Palpation is one of the major methods used in the physical examination as it provides the physician with vital information of the tumour. The palpation of the tumour is to be gentle and with appropriate pressure, the finger tips being used to feel first the intact adjacent tissue while approaching the tumour itself. It is sometimes performed with both hands, as is the case with feeling the lymph nodes, breast tumours.

The **size** of a tumour measures from millimetres to centimeters. The tumour shape is accounted for its nature. Nodularity of the surface and adherence to the neighbouring tissues, coupled with firm consistency, is characteristic of a



malignancy, in contrast to a benign overgrowth or a cyst which has smooth surface and is often round and mobile. It is noted that metastatic nodules on the surface of a malignant tumour are likely to be smooth.

The **consistency** of a tumour appreciably depends on its type:

- soft (normally implies a benign nature of the tumour, e.g. lipomas or polyps of mucous membranes; in some cases, however, this can be a finding of an undifferentiated tumour (e.g. sarcoma);
- hard (associated with an overgrowth of the connective tissue, e.g. fibroma);
- firm (firm consistency, together with elasticity without fluctuation, is typical of an encapsulated tumour filled with fluid);
- wooden-like without demarcation (carcinoma).

The **mobility** of a tumour can be either spontaneous (active) or induced (passive). Of special importance is the tumour motility in relationship to the skin or muscles.

The tumour can move spontaneously:

- when it originates from a mobile organ (in the cavity);
- on changing the body position;
- on swallowing ;
- on muscular contraction (muscle tumour).
- The physician has to evaluate the tumour's mobility. It is of particular significance in infiltrating immobile tumours, which most commonly appear malignant by nature.

It is noteworthy that in numerous cases it is the metastases that are identified first. Similarly, all the lymph nodes have to be thoroughly palpated. **Metastatic lymph nodes** differ from intact ones in that they are enlarged, round, firm and occasionally nodular and adhered to the surrounding tissues and other lymph nodes. However, unlike inflamed nodes, they commonly lack tenderness.

Oral and pharyngeal tumours have to be examined by way of palpation. The digital examination of these tumours yields additional information about their size, form, mobility and consistency.

To confirm the diagnosis of a malignant lesion or its metastases **special investigations** have to be performed:

1. Endoscopy.
2. Cytology (swabs, aspirates).
3. Histology (biopsy).
4. X-ray investigations.
5. Radioisotope methods (scanning, scintigraphy).
6. Ultrasonography.
7. Computerised axial tomography.
8. Laboratory tests (blood cell morphology, enzyme activity etc, as indicated).

The classification was suggested as an international one by the Committee on Tumour Nomenclature of the International Anticancer Union. According to this classification, there are **7 groups of tumours**, their total number exceeds 200:

- Epithelial tumours without specific localization (nonorganospecific).
- Tumours of endocrine and exocrine glands as well as epithelial integument (organspecific).
- Mesenchymal tumours.
- Tumours of melanin-forming tissue.
- Tumours of nervous system and brain membranes.
- Tumours of blood system.
- Teratomas.

According to their **clinico-morphological characteristics** the tumours are divided into 3 groups: benign, malignant, tumours with local destructive growth.

Metastases can be: lymphogenic, hematogenic, implantation(contact).

According to the clinical classification, the **4 stages of pathological overgrowth** are identified:

I stage-tumour is localized, occupies a limited area, does not infiltrate into the wall of the organ, metastases are absent.

II stage-tumour is of a big size, can infiltrate into the organ wall but does not spread beyond the organ, there can be solitary metastases to the regional lymph nodes.

III stage-tumour is of a big size with degeneration, infiltration into the hollow organ wall; multiple metastases to the regional lymph nodes are present.

IV stage-tumour with distant metastases to organs and lymph nodes and with infiltration of surrounding organs.

#### The TNMGP classification

| <b>Abbreviation</b> | <b>Stands for</b> | <b>Characteristics to be considered</b> | <b>Stages</b>                                                                                 |
|---------------------|-------------------|-----------------------------------------|-----------------------------------------------------------------------------------------------|
| <b>T</b>            | <b>Tumour</b>     | <b>Size of the primary tumour</b>       | <b>T1-T4</b>                                                                                  |
| <b>N</b>            | <b>Nodes</b>      | <b>Involvement of the lymph nodes</b>   | <b>NO-nodes are not palpable<br/>N1-metastases to the regional nodes<br/>N2-metastases to</b> |

|          |                    |                                                                                                    |                                                                                                                                                                                                                                                                              |
|----------|--------------------|----------------------------------------------------------------------------------------------------|------------------------------------------------------------------------------------------------------------------------------------------------------------------------------------------------------------------------------------------------------------------------------|
|          |                    |                                                                                                    | the second level nodes<br>N3-metastases to distant nodes                                                                                                                                                                                                                     |
| <b>M</b> | <b>Metastases</b>  | <b>Presence of organ metastases</b>                                                                | <b>M0-no metastases</b><br><b>M1-metastases present</b>                                                                                                                                                                                                                      |
| <b>G</b> | <b>Grade</b>       | <b>Tumour differentiation</b>                                                                      | <b>G1-low level of malignancy (highly differential tumour)</b><br><b>G2-moderate level of malignancy (low differentiated tumour)</b><br><b>G3-high level (undifferentiated tumour)</b>                                                                                       |
| <b>P</b> | <b>Penetration</b> | <b>Depth of the tumorous infiltration into the walls of a hollow organ (histological criteria)</b> | <b>P1-cancer infiltrating into the mucous membrane</b><br><b>P2-cancer infiltrating into the submucous layer</b><br><b>P3-cancer infiltrating into as deep as the serous layer</b><br><b>P4-cancer infiltrating into the serous layer or extending beyond the organ wall</b> |

### **Role of the dental practitioner in cancer prevention and diagnosis**

- **Prevention**

Actively discourage smoking and betel quid use Encourage moderation of alcohol intake Health promotion and education on oral carcinoma Provide check-ups for the edentulous and/or institutionalised elderly and other high risk non-attenders

- **Early diagnosis**

Be vigilant and suspicious Always examine mucosa as well as the teeth Monitor low-risk premalignant lesions Refer all high-risk lesions on discovery Perform biopsy appropriately

- After treatment

Manage simple denture problems after surgery

Alleviate the effects of post-irradiation dry mouth, e.g.

preventing caries

Monitor for recurrence, new premalignant lesions and second primary tumours

Monitor for cervical metastasis

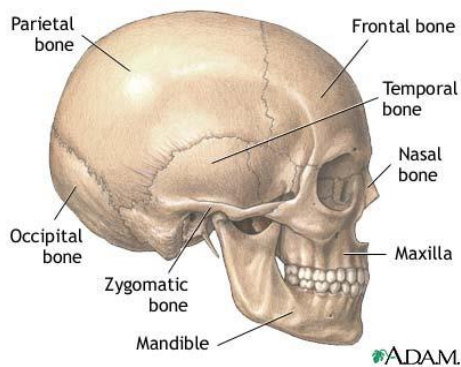
Maintain morale of and provide additional support to patients and their relatives.

## References

1. Ash, Major M. and Stanley J. Nelson. Wheeler's Dental Anatomy, Physiology, and Occlusion. 8th edition. 2003. p. 105. ISBN 0-7216-9382-2

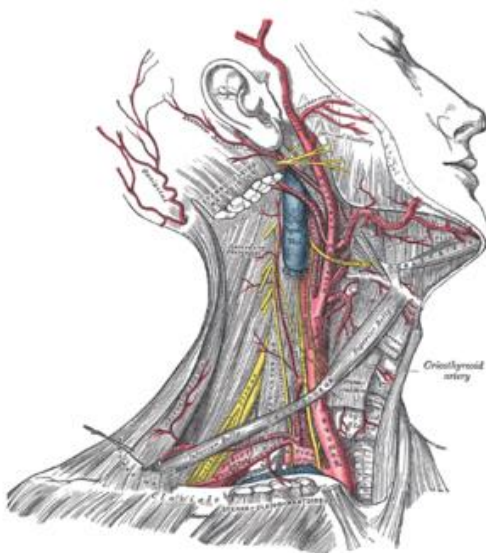
2. Esposito M (2006). "Impacted wisdom teeth". Clin Evid (15): 1868–70. PMID 16973068.
3. Gülicher, D.; Gerlach, K. L. (2001). "Sensory impairment of the lingual and inferior alveolar nerves following removal of impacted mandibular third molars". International journal of oral and maxillofacial surgery **30** (4): 306–312.
4. Johnson, Clarke. "Biology of the Human Dentition", 1998. Page accessed on January 24, 2007.
5. Hupp, James R. Contemporary Oral and Maxillofacial Surgery, 5th Edition. Mosby
6. Rozkovicova E., Markova M., Dolejsi J. (1999). "Studies on agenesis of third molars amongst populations of different origin". Sbornik Lekarsky **100** (2): 71–84. PMID 11220165.
7. Pinkham, Jimmy R. Pediatric Dentistry: Infancy Through Adolescence, 4th Edition. Mosby, 042005. 40.1.3 & 37.2.5.2
8. A. R. Ten Cate, Oral Histology: Development, Structure, and Function, 5th ed. (Saint Louis: Mosby-Year Book, 1998), p. 95. ISBN 0-8151-2952-1.
9. . "Wisdom tooth". Oxford English Dictionary. Oxford: Oxford University Press. 1989. ISBN 0-19-861186-2.
10. Zadik Y, Sandler V, Bechor R, Salehrabi R (August 2008). "Analysis of factors related to extraction of endodontically treated teeth". Oral Surg Oral Med Oral Pathol Oral Radiol Endod.

## ILLUSTRATIONS

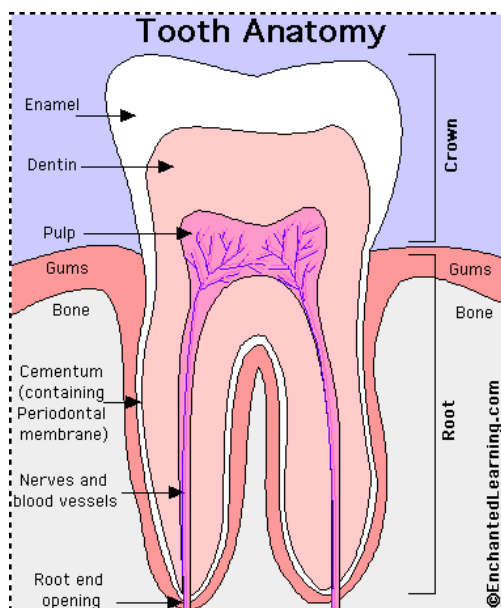


**Figure 1.** The skull

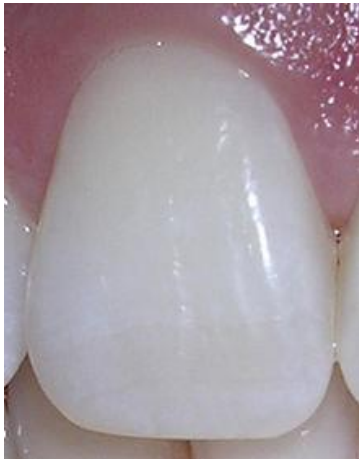The skull is the bony structure of the head and face. The cranium surrounds the brain with the temporal, frontal, parietal and occipital bones. The maxilla, or upper jaw, and the mandible, or lower jaw, support the facial features of nose, mouth and eyes.



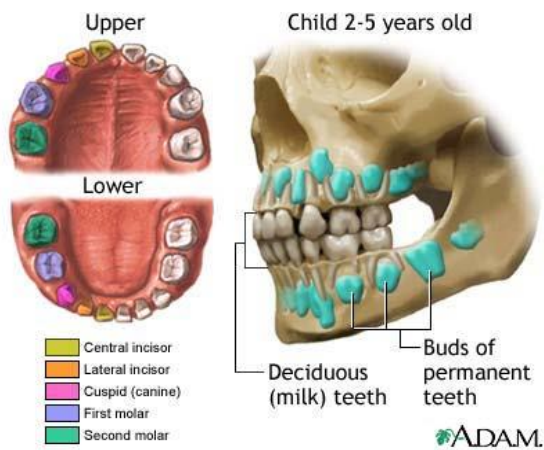
**Figure 2.** Blood system. Right side of neck dissection showing the brachiocephalic, right common carotid artery and its branches.



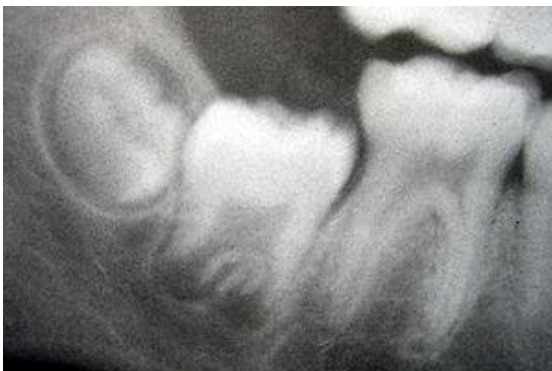**Figure 3.** Tooth anatomy.



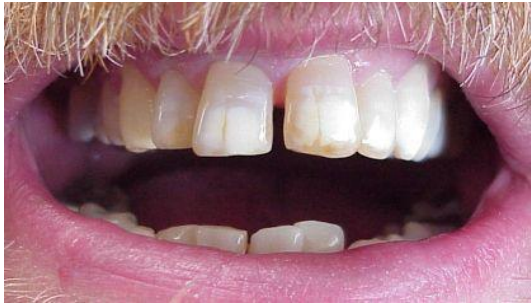**Figure 4.** Maxillary central incisor.



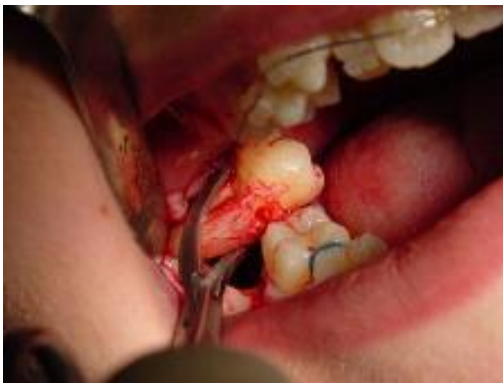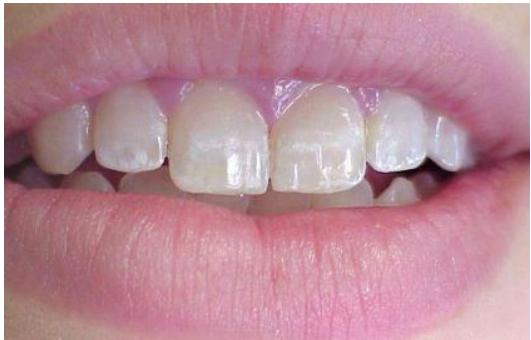**Figure 5.** Both baby teeth (deciduous or milk teeth) and permanent teeth have fairly well-defined times of eruption. The ages listed are the normal ages that a baby tooth emerges.



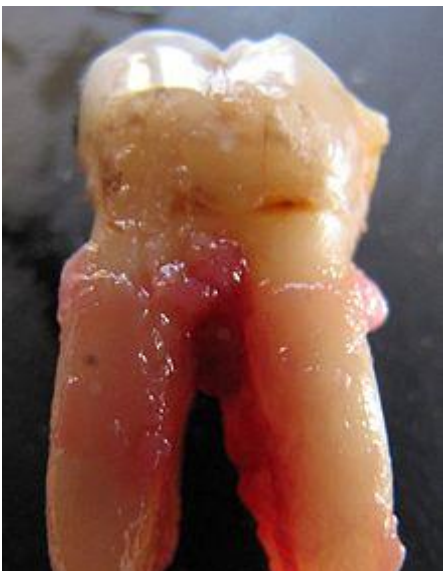**Figure 6.** Radiograph of lower right (from left to right) third, second, and first molars in different stages of development.



**Figure 7.** There is one problem associated with fluoride (a). This involves the appearance of the teeth if a child under the age of six receives **too much** fluoride while the teeth are forming (b).

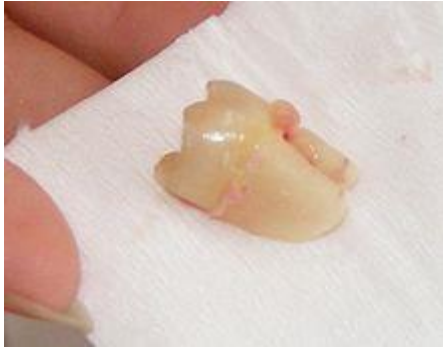

**Figure 8.** Surgical extraction of an impacted molar.

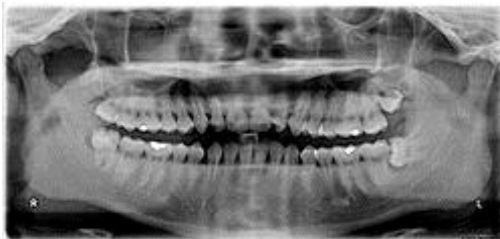

**Figure 9.** Extracted tooth .

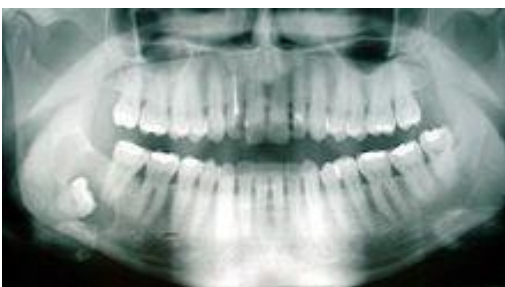



**Figure 10.** An extracted 3rd molar that was horizontally impacted.



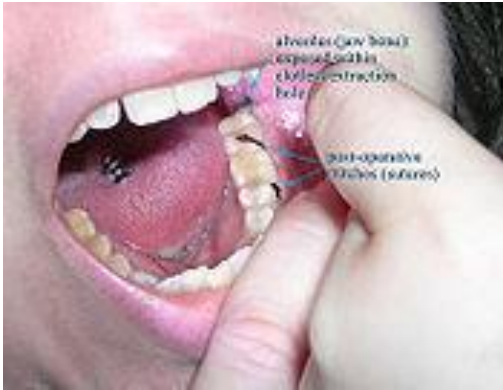**Figure 11.** The upper left (picture right) and upper right (picture left) wisdom teeth are distoangularly impacted. The lower left wisdom tooth is horizontally impacted. The lower right wisdom tooth is vertically impacted (unidentifiable in orthopantomogram).



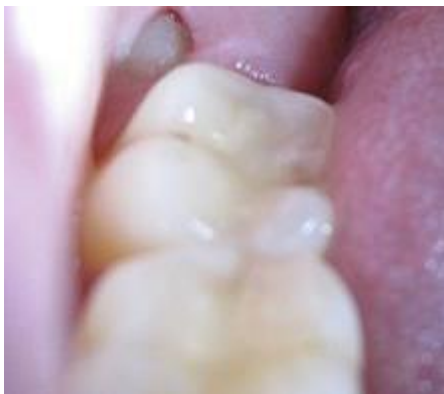**Figure 12.** Cyst around right lower wisdom tooth.



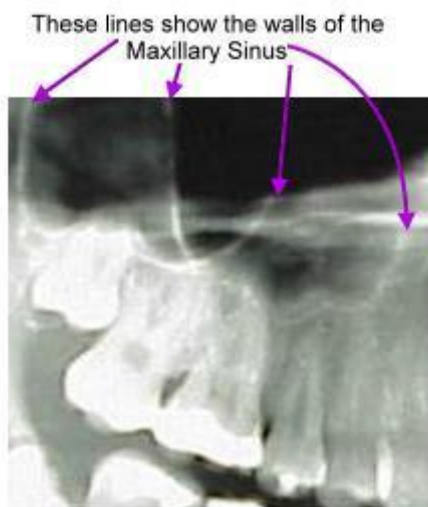**Figure 13.** Example of post-operative swelling following third molar (wisdom teeth) extractions.



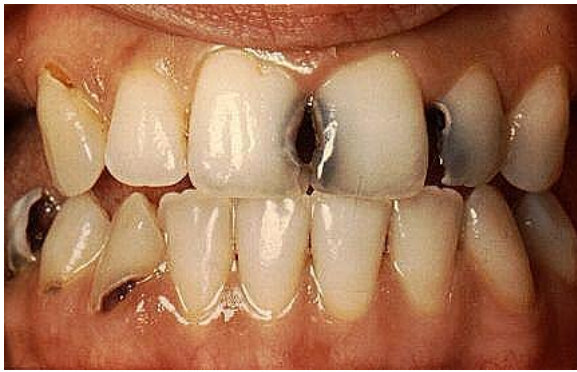**Figure 14.** Example of alveolar osteitis (dry socket) following lower third molar (wisdom tooth) extraction; six days post-surgery.



**Figure 15.** A wisdom tooth protrudes outwards from the gumline at the back of the lower teeth.



**Figure 16.** Sometimes a sinus perforation will go unnoticed.

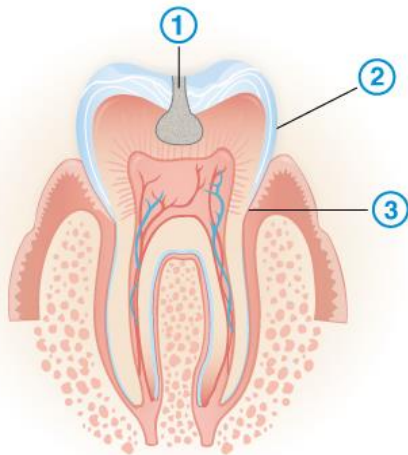


**Figure 17.** Cavities are holes, or structural damage, in the teeth (a,b):

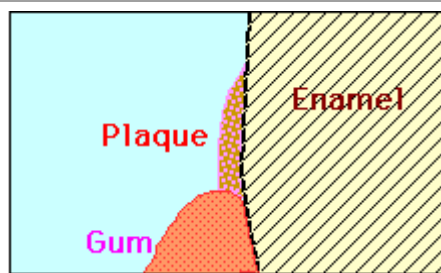
1. Pit-and-fissure caries develop initially in the fissures of the teeth, but can spread into the dentine, causing complete breakdown of the tooth.

2. Smooth-surface caries are most common on the interdental surfaces, but can occur on any smooth surface of the tooth.

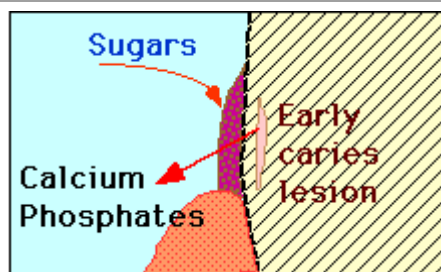
3. Root caries attacks the dentine directly, which becomes exposed as gingiva recede. Root decay is a widespread problem in adults and appears to be increasing. This may be because more and more adults are retaining their own teeth into old age. Also, investigation and treatment of periodontal disease exposes the root surface, making the root more susceptible to bacterial attack.



### The Process of Demineralization and Remineralization

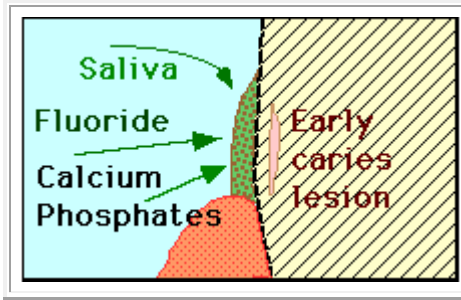


A detail of a tooth (to the right = enamel). It is covered by plaque, which consists mainly of bacteria. Plaque is often found close to the gum, in between teeth, in fissures and at other "hidden" sites.



#### **Demineralization:**

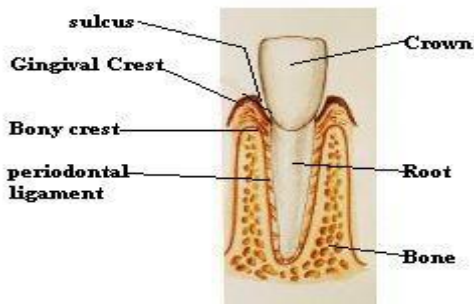
When sugar and other fermentable carbohydrates reaches the bacteria, they form acids which start to dissolve the enamel - an early caries lesion occurs due to loss of Calcium and Phosphates.



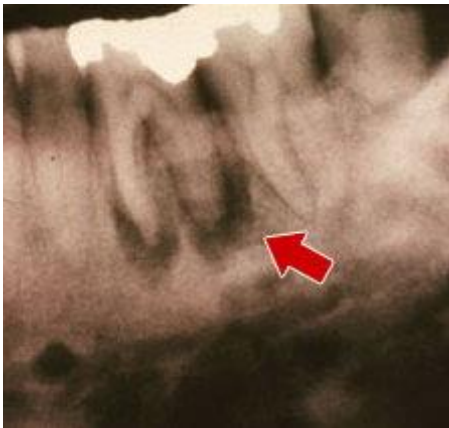**Remineralization:**

When sugar consumption has ceased, saliva can wash away sugars and buffer the acids. Calcium and Phosphates can again enter the tooth. The process is strongly facilitated by fluorides.

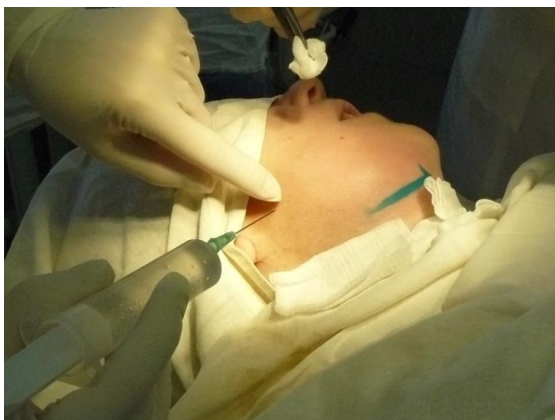**Figure 18.** The Process of Demineralization and Remineralization.



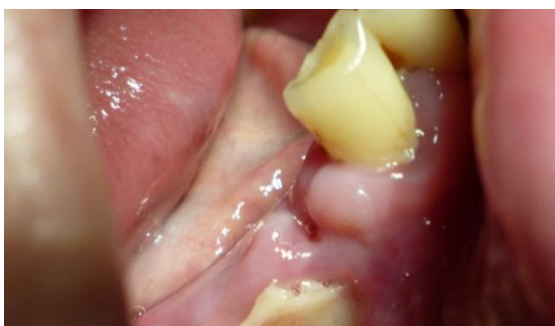**Figure 19.** The tooth and supporting structures.



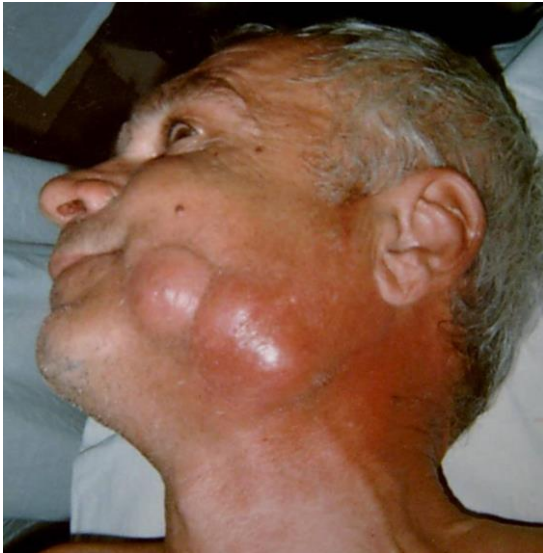**Figure 20.** Periodontitis is inflammation and infection around the apex of the tooth.



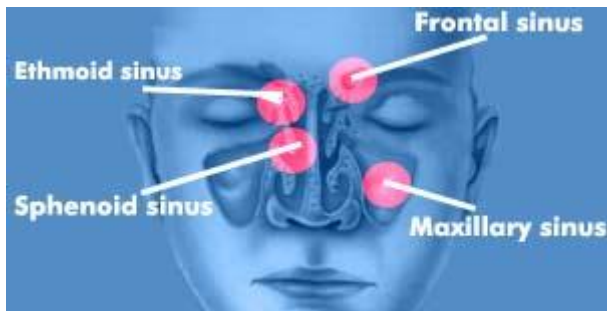
**Figure 21.** Facial phlegmon (cellulitis) in submandibular region.



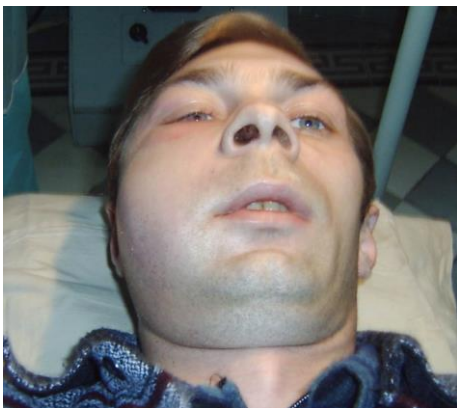**Figura 22.** Chronic form of odontogenic process of mandible. Sequestration.



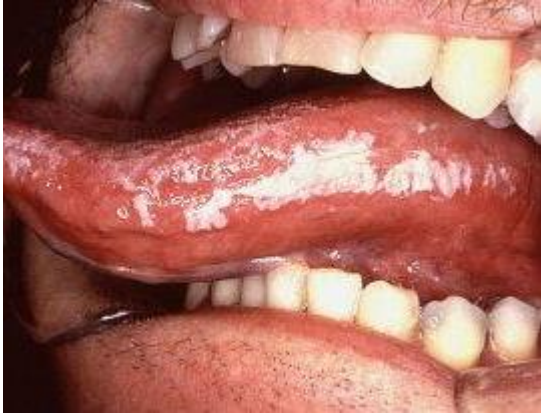**Figure 23.** Abscess - local swelling, redness. Before surgical treatment.



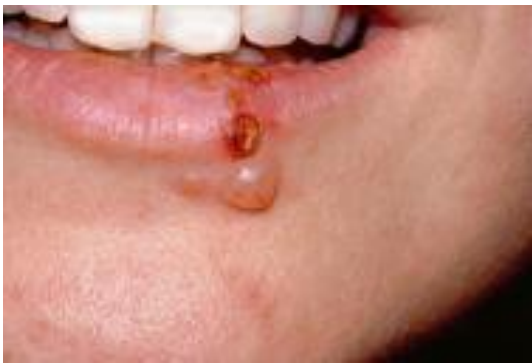**Figure 24.** Sinus cavities.



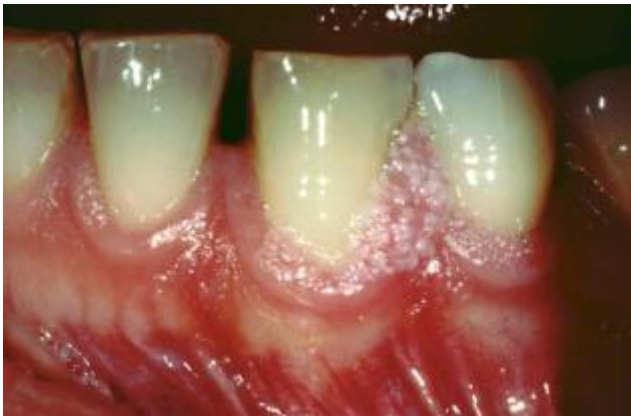**Figure 25.** Acute sinusitis.



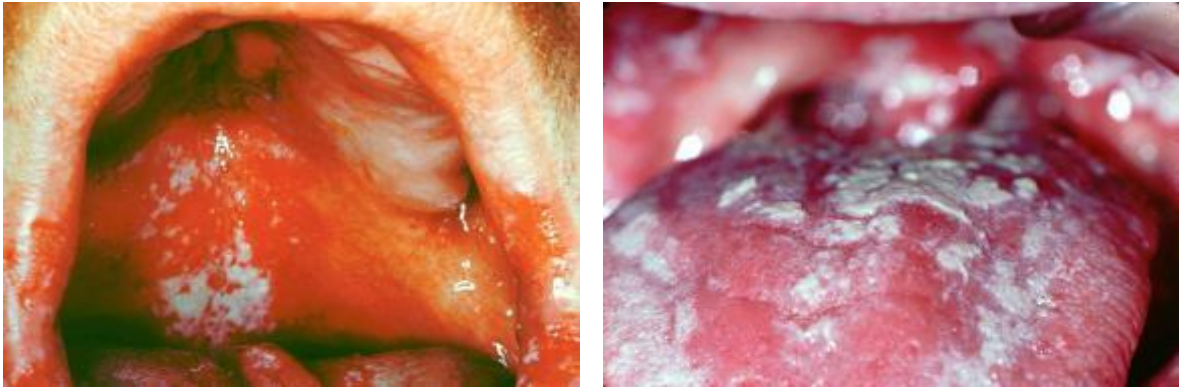
**Figure 26.** Fuzzy white patches on the side of the tongue.



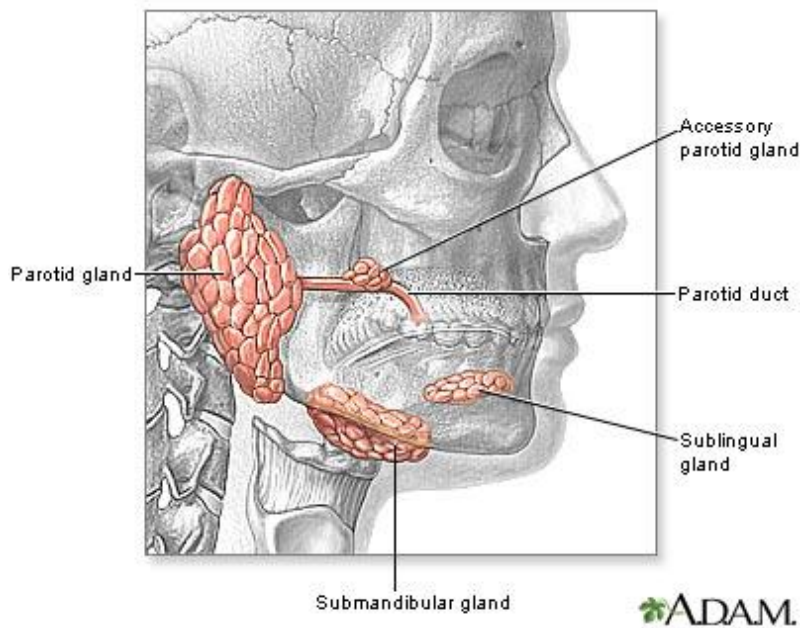
**Figure 27.** Herpes Simplex (the "cold sore" or "fever blister" virus).



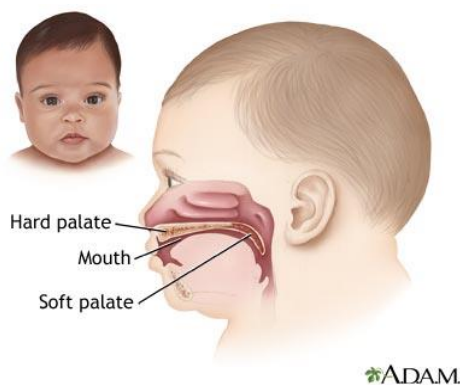
**Figure 28.** Human Papillomavirus lesions (warts).



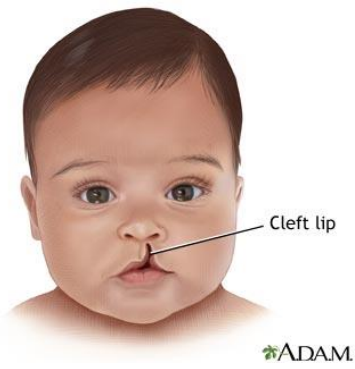
**Figure 29.** Candidiasis in different part in oral cavity (a,b).



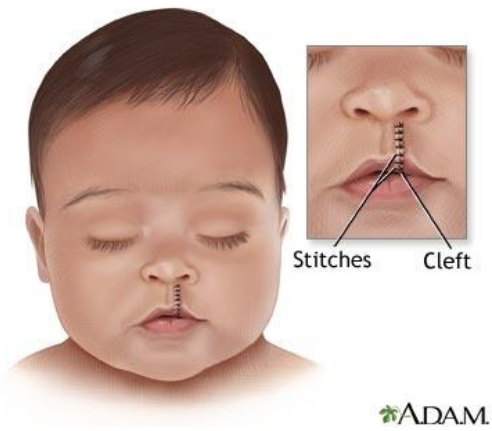
**Figure 30.** There are several pairs of salivary glands in different locations: a major pair in front of the ears (parotid glands); two major pair on the floor of the mouth (sublingual and submaxillary glands); and several minor pairs within the lips, cheeks, and tongue.



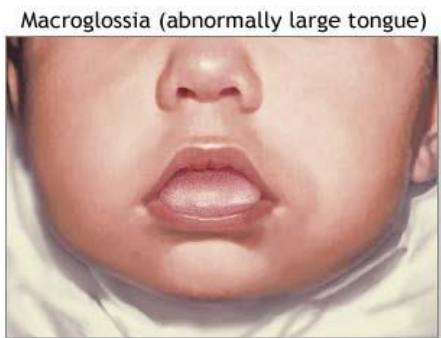**Figure 31.** Normal structure.



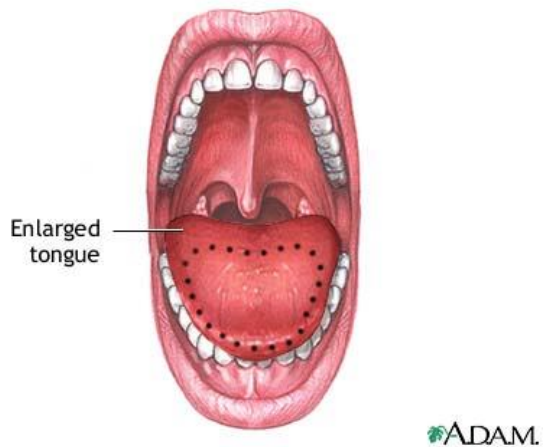
**Figure 32.** Cleft lip and palate.



**Figure 33.** After operation. Treatment.

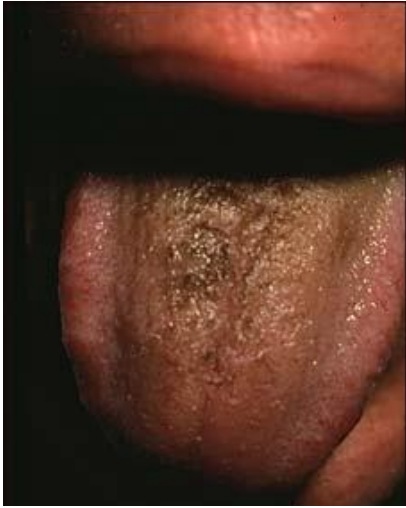

**Figure 34.** Macroglossia.

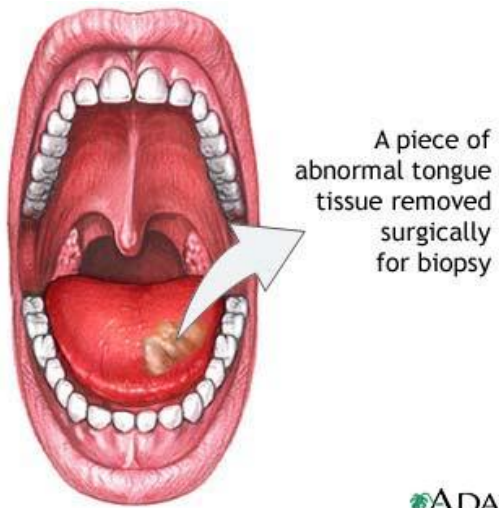


**Figure 35.** Plan of operative treatment.



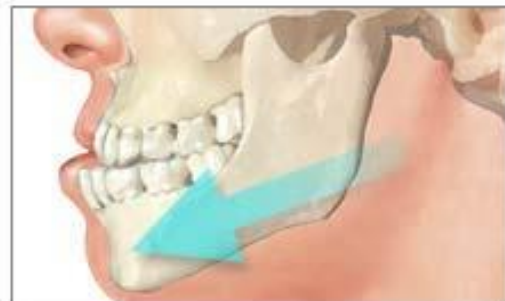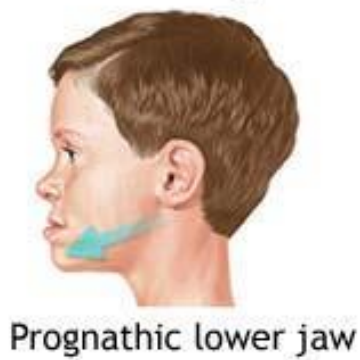

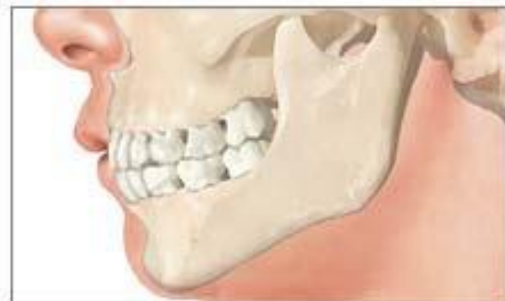
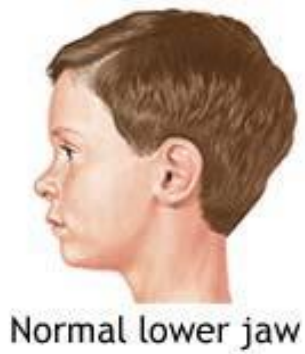**Figure 36.** Black hairy tongue.



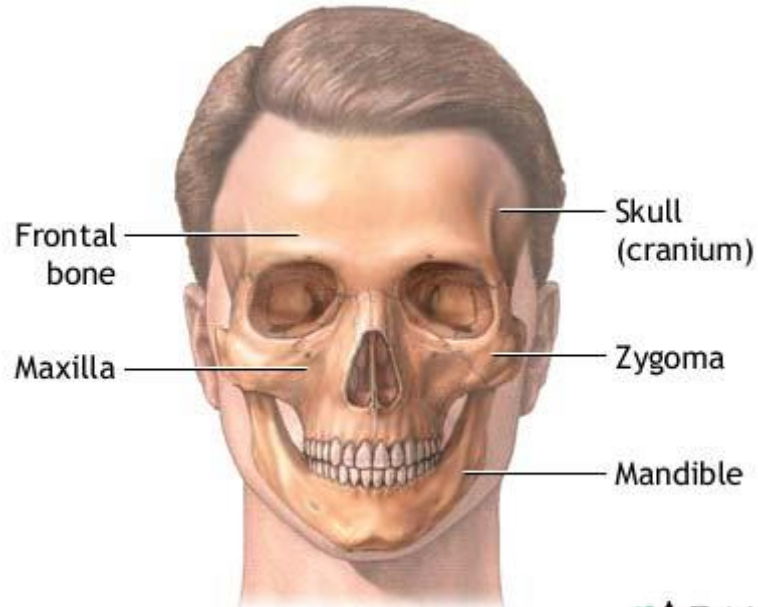
**Figure 37.** Biopsy.

ADAM.



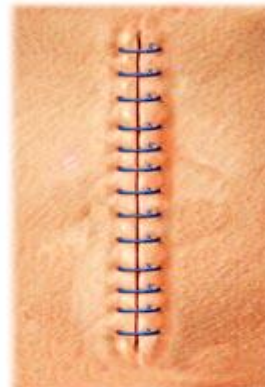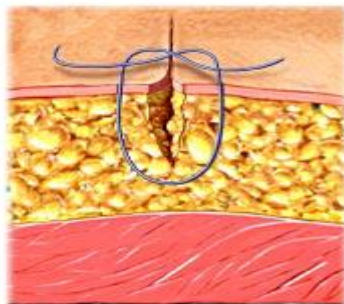
ADAM.

**Figure 38.** Prognathism.



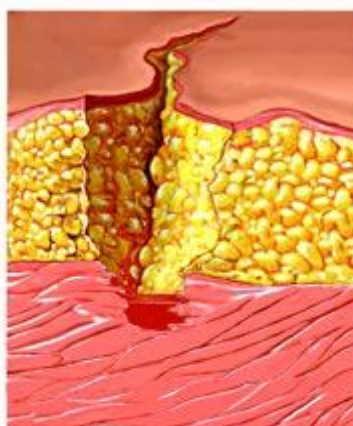
**Figure 39.** Skull.

Sutures aid healing by holding a wound together until the healing process is established

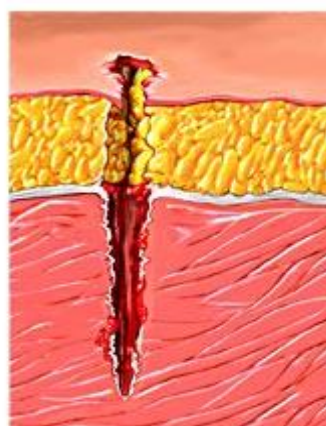

**Figure 40.** Stitches.

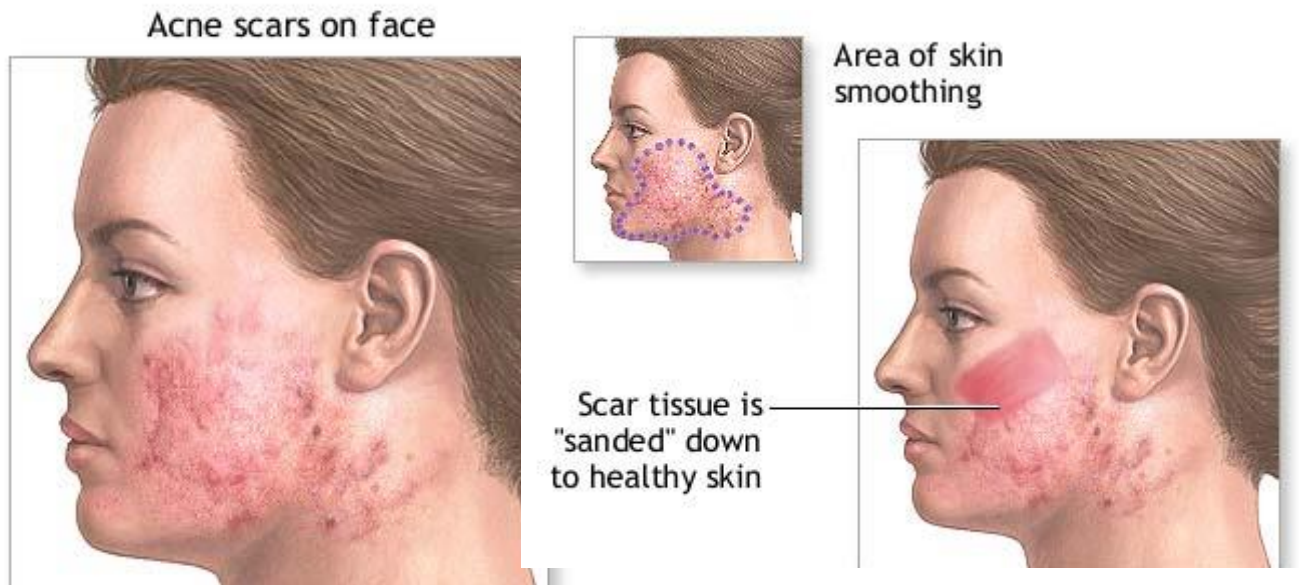
Laceration



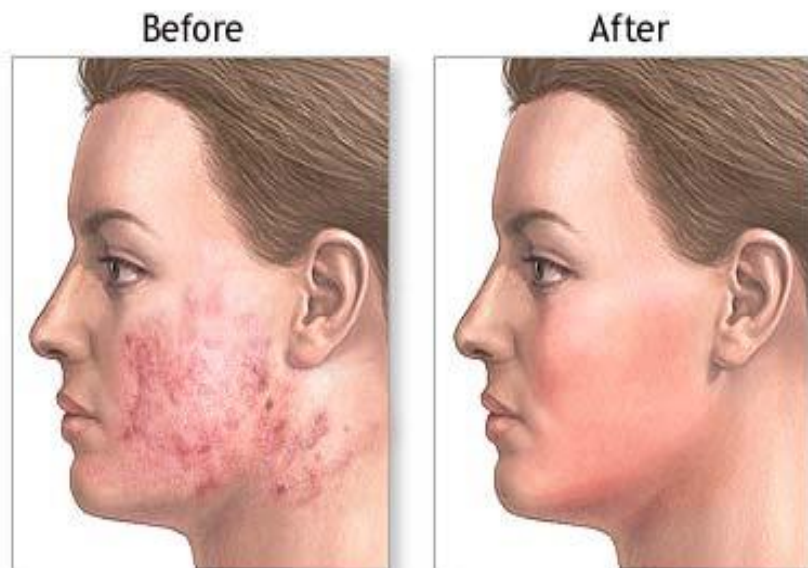Puncture wound



**Figure 41.** Laceration (a), puncture wound (b).



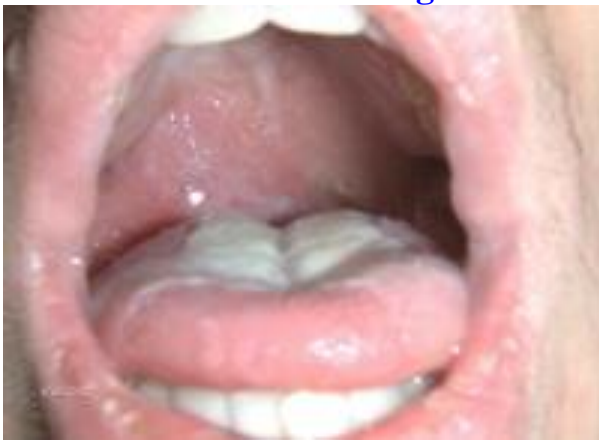**Figure 42.** Dermabrasion.



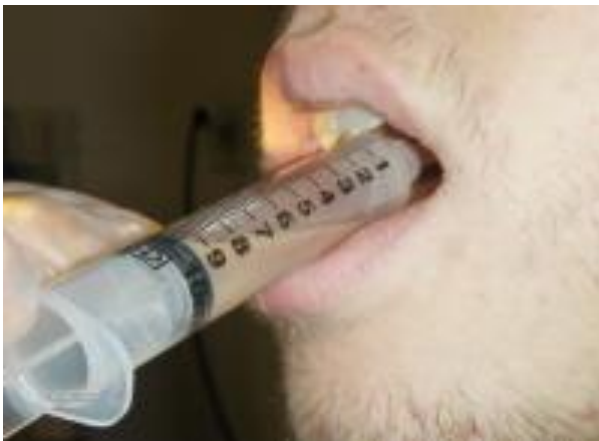**Figure 43.** After care.



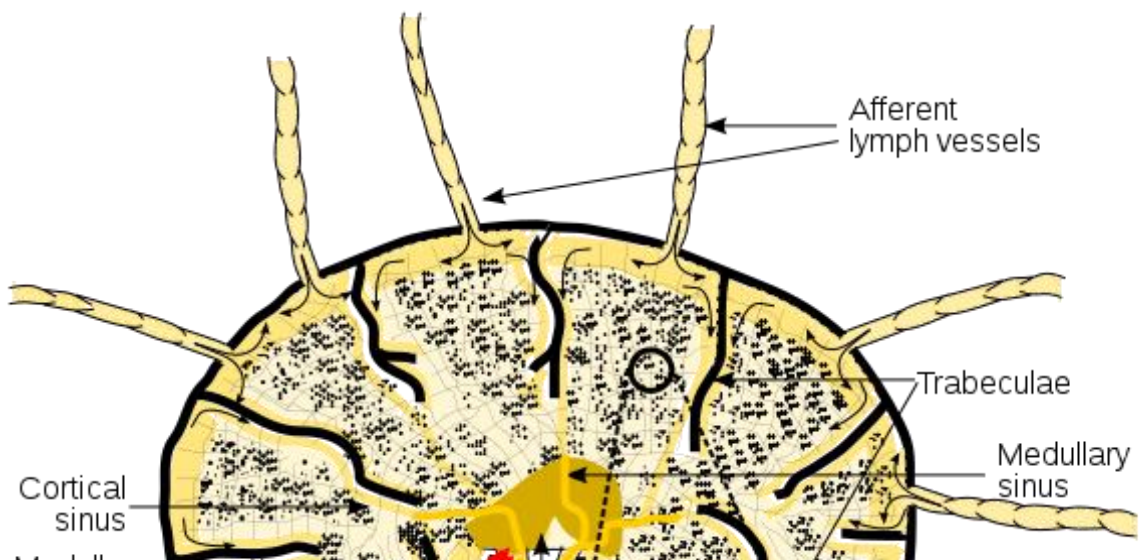
**Figure 44.** Keloid above the ear.



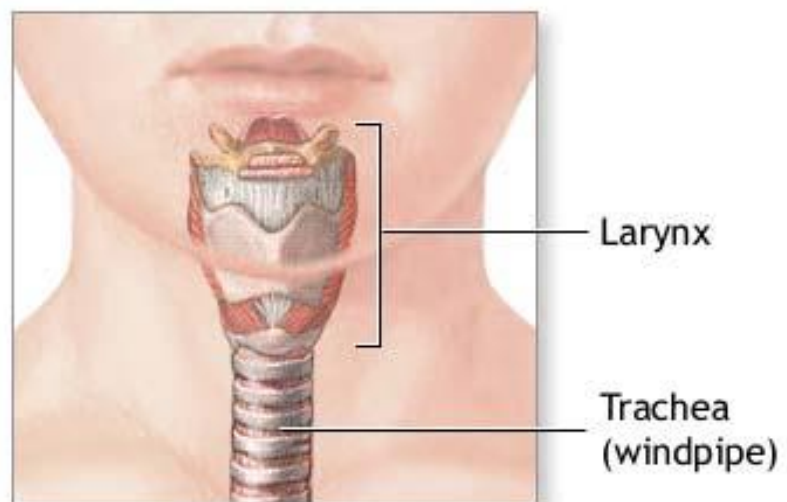
**Figure 45.** Right peritonsillar abscess.



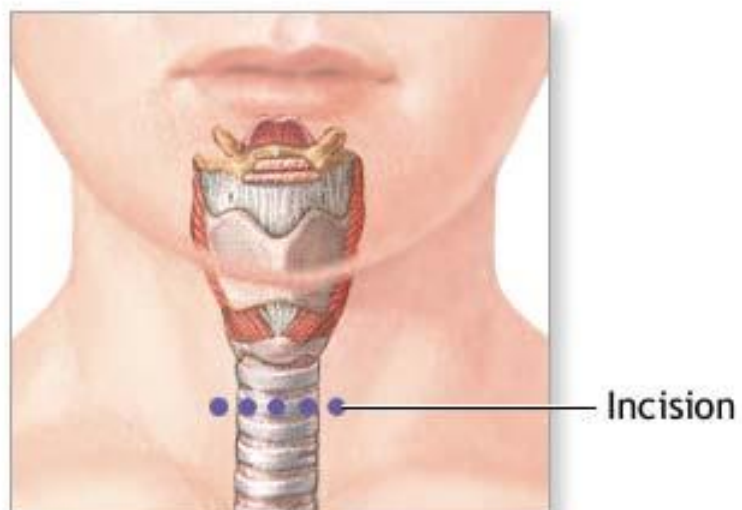
**Figure 46.** Right peritonsillar abscess.



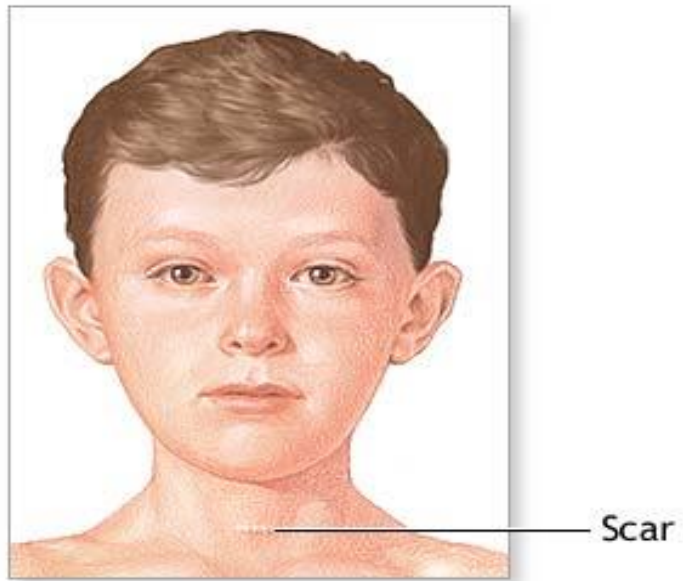
**Figure 47.** Structure of the lymph nodes.



**Figure 48.** Normal anatomy.



**Figure 49.** Incision.



**Figure 50.** After care.