

PRACA ORYGINALNA
ORIGINAL ARTICLE**OPTICAL DENSITY OF MANDIBLE IN ORTHODONTIC PATIENTS****GĘSTOŚĆ OPTYCZNA ZUCHWY U PACJENTÓW ORTODONTYCZNYCH****Vera D. Kuroedova, Evheniy E. Vyzhenko, Alexandra N. Makarova, Aleksey A. Stasiuk**

DEPARTMENT OF POST-GRADUATE EDUCATION OF ORTHODONTISTS, EDUCATIONAL AND SCIENTIFIC INSTITUTE OF POST-GRADUATE EDUCATION, HIGHER STATE EDUCATIONAL ESTABLISHMENT OF UKRAINE, UKRAINIAN MEDICAL STOMATOLOGICAL ACADEMY, POLTAVA, UKRAINE

ABSTRACT

Introduction: The given article is concerned with peculiarities of the change in the bone mineral density of the jaw bones in the dynamics of bone structure growth in the locomotor apparatus of orthodontic patients.

The aim of the paper is to carry out a comparative analysis of the mineral density of the bone tissue of the lower jaw (mandible) and the mineral density of the second cervical vertebra (C2) in patients with malocclusion.

Materials and methods: 37 computer tomograms of orthodontic patients were studied, which were divided into three age groups according to the periods of the formation of the dentoalveolar system. Measurement of bone density of (second cervical vertebra) C2 was performed in the sagittal projection along the middle of the height of the vertebra. In the mandible, measurements were made on axial sections in the vestibular and oral direction in the region of the alveolar process between the central incisors, between the canine and the first premolar at the mid-root level, in the region of the first molars below the bifurcation level, in the retromolar region and the region of the articular process.

Results: The greatest similarity in densitometric parameters of bone density is established between the second cervical vertebrae and the density of the joint head. The most dense site on the lower jaw is the alveolar process between the central incisors, which increases with age from 1274.71 ± 34.7 in group I to $1400.6 \pm 75, 56$ in the III group, these indicators are almost 2-2.5 times higher than the density of C2.

Conclusions: Mandible presents irregular density of bone based on optic densitometry in different areas. Maximal indices of bone density are established in the area of alveolar processes where the jaw is exposed to maximal occlusal loading.

KEY WORDS: mandible, densitometry, malocclusion

Wiad Lek 2018, 71, 6, 1161-1164

INTRODUCTION

The disturbance of metabolic processes of the bone tissue of the jaw bones due to general somatic pathology, effect of unfavorable environmental factors, concomitant complications from hard teeth and periodontal tissue, and many other etiological factors lead to the development of malocclusion [1, 2]. Thus, it has been proved that the shape and shape of the facial skeleton is influenced by the shape of the cervical spine [3, 4, 5]. Therefore, the problem of timely detection and research of risk factors for the occurrence of dental diseases is topical, including malocclusion in children and adolescents [6, 7].

X-ray studies of malocclusion during diagnosis play an important role for planning orthodontic treatment. Computed tomography (CT) is an informative and accessible method of objective patient research [8], which is used in orthodontic practice.

In connection with the total increase in osteopenic diseases and periodontal tissue diseases, CT is particularly relevant for the study of bone density. Recently, osteoporosis, as a systemic disease of the skeleton, tends to rejuvenate, as it increasingly occurs in childhood and adolescence and is characterized by a decrease in the mass of bone tissue and a disturbance of its microarchitectonics [9]. These changes

lead to retardation of the growth rate, abnormalities of the bone system, disturbance of posture, which, in turn, can lead to the development of malocclusion [10].

Normally, person with healthy periodontium, the optical density of bone tissue of the alveolar process is from 583.1 to 1429.75 units, depending on the location of the tooth [11].

Up to date there are individual works devoted to the peculiarities of the change in bone mineral density of the jaw bones in connection with the dynamics of bone structure growth in the locomotor apparatus of orthodontic patients.

THE AIM

The aim of the paper is to carry out a comparative analysis of the mineral density of the bone tissue of the lower jaw (mandible) and the mineral density of the second cervical vertebra (C2) in patients with malocclusion.

MATERIALS AND METHODS

37 computer tomograms of orthodontic patients were studied, which were divided into three age groups according to the periods of formation of the dentoalveolar system.

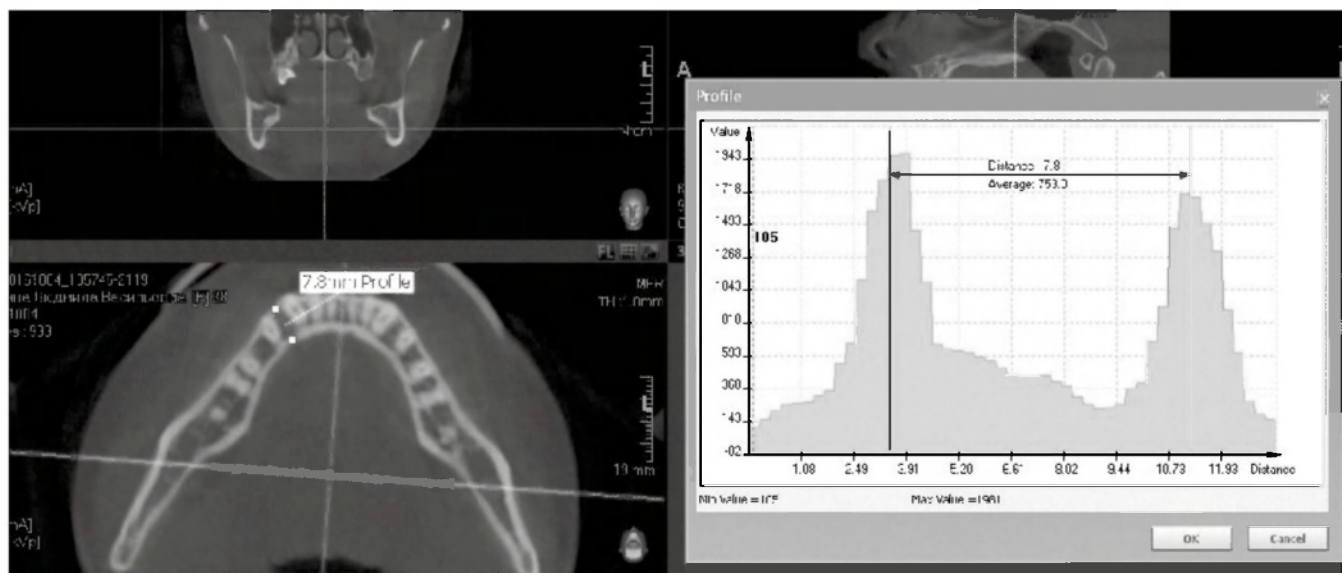


Fig. 1. Definition of bone density between 33 and 34 teeth.

The first group included 7 people aged from 6 to 12 years presents the period of the mixed occlusion (average age is 9.4 years), the second group contained 15 people (from 13 to 20 years) which is characterized by the completion of the period of formation of a permanent occlusion (average age 15, 1 years). The third group includes 15 patients aged 21-40 years (average age 26.6 years), which corresponds to the period of active functioning of the dentoalveolar system.

CT of jawbones was done on odontic computer tomograph «VATECH PAX-ZENITH 3D», the step of scanning was 1 mm, the duration of scanning was 15 sec. with general radiation exposure 50 mksv.

Each of the computer tomographs uses a number of application programs. In the Ez3D2009 program, bone density is measured using the “Profile - measuring bone density between two points” tool in Hounsfield units (HU).

When the tissue is thicker, x-ray will be absorbed and decreased, so the bone is white and air is black.

Measurement procedure: after the standard procedure of computed tomography and obtaining a reconstructed image on the screen of the monitor, one activate the panel tool “Profile” by clicking the mouse button. In the multi-plane reconstruction, one can perform a secant, then on the resulting histogram it should be determined the radiological density in the measured area. Borders of density were established on the histogram and it corresponds to compact bone with vestibular and oral sides (Fig. 1).

Cervical vertebrae C2, C3 and C4 are well shown on studied CT in the saggital area. So, measurement of density of bone C2, was done in the saggital projection through the height the vertebra. On the mandible, measurements were made on axial sections in the vestibular and oral direction in six areas: in the region of the alveolar process between the central incisors, between the canine and the first premolar at the mid-root level, in the region of the first molars below the bifurcation level, in the retromolar region and in the articular region of heads.

The values of the studied indicators were done to statistical processing using the methods of medical statistics using the program of statistical analysis of Microsoft Excel 2010, the version of Windows 7. In order to compare the indices, Student’s t-test was used, the differences were reliable at $p < 0.05$.

RESULTS AND DISCUSSION

Results of the measurement of the density of bone tissue of the mandible and C2 are presented in the table 1. To determine the average index of the density of bone tissue between 33-34 and 43-44 teeth, along the bifurcation of roots 36, 46, in retromolar area and in the area of articular head all indices were summarized, and accurate statistic difference between sides was not determined.

Based on results of our studies, C2 with age has a physiologically consistent tendency to increase densitometric indicators, as well as the entire bone skeleton of a person as a whole, which indicates an increase in the mineralization of the bone tissue of the child during adolescent period. Comparison of the average values of C2 in groups demonstrates an increase in bone density with an age of 6 to 40 years, from 501 ± 61.06 to 587.6 ± 48.81 , respectively [12].

Age dynamics of densitometric indices of the density is presented on the Fig. 2.

The positive dynamics of the increase in densitometric parameters from the I to III group was established in three studied areas of the mandible: in the bifurcation of the first molars, in the retromolar region and in the articular process.

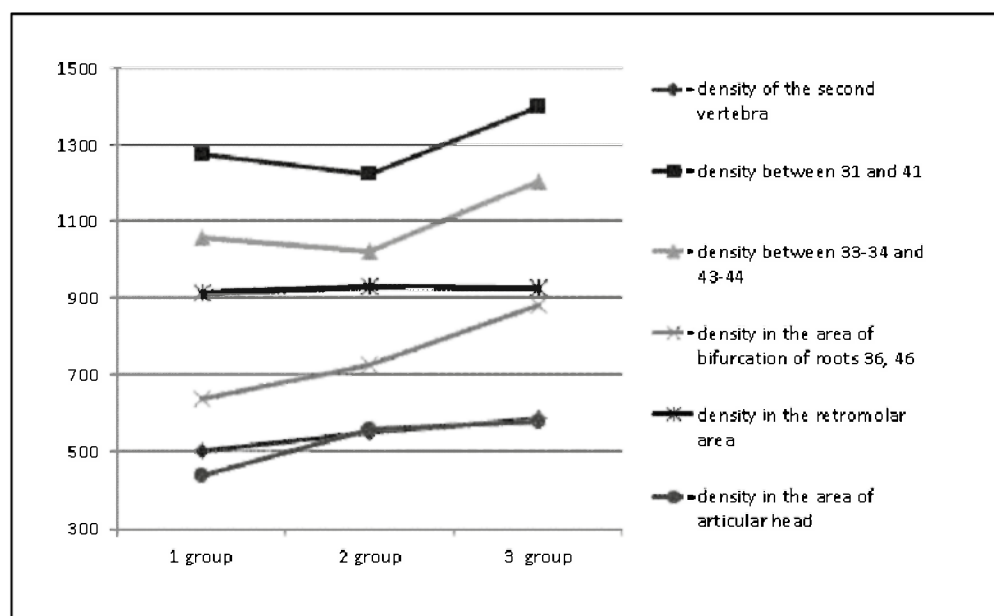
Densitometric indices in the bifurcation area of the first molars increase with age: in the first group they are 637.36 ± 33.93 , in the third one - 882.67 ± 53.9 , which is confirmed statistically ($p_{1-3} < 0.01$, $p_{2-3} < 0.05$).

Relatively stable area of the optical density on the lower jaw is the retromolar region. High indices in comparison with C2 ($p < 0.01$) are associated with dense compact plates

Table I. Density of bone tissue of the mandible and C2 (HU)

Measurement area group	I	II	III
C2	501±61,06 $p_{1-3}>0,05$	550,6±45,32 $p_{1-2}>0,05$	587,6±48,81 $p_{2-3}>0,05$
Between 31 and 41	1274,71±34,77 $p_1<0,01$ $p_{1-3}>0,05$	1223,87±76,16 $p_2<0,01$ $p_{1-2}>0,05$	1400,6±75,56 $p_3<0,01$ $p_{2-3}>0,05$
between 33-34 and 43-44	1056,14±96,22 $p_1<0,01$ $p_{1-3}>0,05$	1020,97±46,96 $p_2<0,01$ $p_{1-2}>0,05$	1204,17±54,8 $p_3<0,01$ $p_{2-3}<0,05$
Bifurcation of roots 36, 46	637,36±33,93 $p_1>0,05$ $p_{1-3}<0,01$	724,77±41,64 $p_2<0,01$ $p_{1-2}>0,05$	882,67±53,9 $p_3<0,01$ $p_{2-3}<0,05$
Retromolar area	914,36±54,09 $p_1<0,01$ $p_{1-3}>0,05$	931±50,46 $p_2<0,01$ $p_{1-2}>0,05$	923,17±43,16 $p_3<0,01$ $p_{2-3}>0,05$
Articular head	436,14±34,8 $p_1>0,05$ $p_{1-3}<0,01$	557,8±43,31 $p_2>0,05$ $p_{1-2}<0,05$	579,1±34,97 $p_3>0,05$ $p_{2-3}>0,05$

Note: p – statistical difference in bone density between C2 and the studied areas on the mandible (p_1 - I group, p_2 - II group, p_3 - III group)
 p_{1-2} – statistical difference in bone density of identical zones between the I and II groups; p_{2-3} – statistical difference of bone density of identical zones between the II and III groups; p_{1-3} – statistical difference of bone density of identical zones between the I and III groups.

**Fig. 2.** Age dynamics of densitometric indices in studied areas.

of the external and internal oblique lines in the region of the angle of the mandible.

For a practical orthodontist, the knowledge of the densitometric features of this area is especially important in the treatment of dentoalveolar abnormalities with the use of miniimplants.

The greatest similarity in densitometric parameters of bone density is established between C2 and the density of the articular head (in all three groups $p > 0,05$). When analyzing the age dynamics, a quantitative increase in the densitometric indices is observed in the direction of the increase between the I and II groups ($436.14 \pm 34.8 - 557.8 \pm 43.31$), which is confirmed by statistical data ($p_{1-2} < 0,05$).

The densest site on the lower jaw is the alveolar process between the central incisors, which increases with age from 1274.71 ± 34.7 in the first group to 1400.6 ± 75.56 in the third group, these indices are in 2-2.5 times exceed the density of C2 (Table I, Fig. 2).

The same dynamics, so the increase in bone density with age, can be determined when analyzing the parameters of the mandible between the canine and the first premolar: $1056.14 \pm 96.22 - 1204.17 \pm 54.8$ in groups I and III respectively (Table I). Statistically significant difference between the II and III groups was established ($p_{2-3} < 0,05$). These values are on average 50% greater than the bone density in zone C2.

Minor decrease in the indices in group II when studying the optical density in the areas between the central incisors and in the region between the canines and the first premolars at 30-50 HU are insignificant, and they are not confirmed statistically ($p > 0.05$), and do not influence the positive dynamics of densitometric growth as a whole in the investigated areas.

In general, the increase in bone density with age in the area of chewing teeth confirms the morphological and functional relationship between the occlusal loading and the structure of bone tissue in the development of the maxillofacial region of a person.

CONCLUSIONS

Densitometry of bone tissue is the most informative and accessible method of the investigation and can be applied for diagnostics of the bone tissue of jaws and evaluation of orthodontic treatment.

The tendency of mineral density of bone tissue in the examined areas of mandible and it is approved statistically.

Permanent and stable index of mineral density in all age groups is the index of the second cervical vertebra. Received data allow using these indices for comparative characteristics of the change of mineral density of the bone in the area of alveolar processes of the mandible in dynamics of orthodontic treatment.

Zone between central incisors and between canine and the first premolar is the densest area of the bone tissue on the mandible [12].

The articular head, which does not have anatomical contact with the teeth, has maximal similarity with the indices of the density of the cervical vertebra (C2) in the II and III age groups. These findings can be used for differential diagnosis of diseases of the temporomandibular joint. If the densitometric parameters of the joint and C2 are reduced, therefore, the pathological process is systemic disease. If the optical density is reduced only in the region of the articular head, the pathological process deals with local nature.

So, the mandible has irregular density of bone based on optical densitometry. Maximal indices of bone density were determined in the area of alveolar processes where the jaw is exposed to occlusal loading.

REFERENCES

1. Bezvushko E.V., Bodnaruk N.I. Faktory riska voznikoveniya kariiesa zubov u detey s patologiyey oporno-dvigatel'nogo apparata. *Novosti stomatologii*. 2015; 3: 82-86.
2. Smaglyuk L.V., Sheshukov D.V. Stan stomatologichnogo zdorov'ya u molodih lyudey v zalezhnosti vid yih konstitutsionalno-tipologichnih karakteristik budovi tila. *Visnik problem biologiyi i meditsini*. 2015; 2 (119): 222-225.

3. Karpova V.S., Polma L.V., Bugrovetskaya O.G. et al. Vzalmosvyaz postural'nogo disbalansa v sheynom otdele pozvonochnika s parametrami litsevoogo skeleta u patsientov s distalnoy okklyuziyey. *Ortodontiya*. 2013; 4 (64): 9-16.
4. Cericato G.O., Bittencourt M.A., Paranhos L.R. Validity of the assessment method of skeletal maturation by cervical vertebrae: a systematic review and meta-analysis. *Dentomaxillofac Radiol*. 2015; 44 (4). doi:10.59/dmfr.20140270.
5. Crawford B., Kim D.G., Moon E.S. et al. Cervical vertebral bone mineral density changes in adolescents during orthodontic treatment. *Am J Orthod Dentofacial Orthop*. 2014; 146 (2): 183-189.
6. Osipenko O.V., Vahlova I.V., Trifonova E.B. Klinicheskie i laboratornyie priznaki defitsita kaltsiya u podrostkov. *Voprosy sovremennoy pediatrii*. 2009; 4: 56-62.
7. Muñoz-Calvo M.T., Argente J. Nutritional and Puberal Disorders. *Endocr Dev*. 2016; 29: 153-173.
8. Shepltko V.I. Novi mozhlivosti komp'yuternoyi tomografii v antropometrichnih doslidzhennyah cherepa. *Svit meditsini ta biologiyi*. 2014; 2 (44): 203-208.
9. Maltsev S.V., Mansurova G.Sh. Sovremennyye aspekty osteoporoza u detey. *Prakticheskaya meditsina*. 2015; 7 (92): 15-21.
10. Tkachenko P.I., Korotich N.M., Lohmatova N.M. Poshirenist zuboschelepnyh anomaly i deformatsiy u ditey iz displastichnim skoliozom. *Ukrayinskiy stomatologichniy almanah*. 2012; 2: 63-65.
11. Bondarenko N.N., Balahontseva E.V. Izmerenie opticheskoy plotnosti kostnoy tkani alveolyarnogo otrostka chelyustey pri zabolevaniyah parodonta s pomoschyu trehmernoy kompyuternoy tomografii. *Kazanskiy meditsinskiy zhurnal*. 2012; 4: 660-662.
12. Kuroedova V.D., Vyzhenko E.E., Makarova A.N. et al. Optical density of upper jaw in patients with malocclusion. *Wiadomosci Lekarskie*. 2017; 5: 913-916.

Authors' contributions:

According to the order of the Authorship.

Conflict of interest:

The Authors declare no conflict of interest.

CORRESPONDING AUTHOR

Vera D. Kuroyedova

Higher state educational establishment,
Ukrainian medical stomatological academy,
Shevchenko str. 23, 36000, Poltava, Ukraine
tel: +380532609624
e-mail: polo_nnipo@ukr.net

Received: 20.03.2018

Accepted: 21.07.2018