

Strangulated bowel obstruction and torsion of Meckel's diverticulum: case report.

M. I. Kravtsiv, M. O. Dudchenko, D. M. Ivashchenko, R. A. Prykhidko

Higher State Educational Establishment of Ukraine "Ukrainian Medical Stomatological Academy", Poltava, Ukraine

Abstract.

Meckel's diverticulum is the congenital anomaly of gastrointestinal tract. The frequency of its occurrence is about 1 - 3%. There are various complications associated with diverticulum, including hemorrhage, intestinal obstruction, inflammation and perforation. Intestinal obstruction is the most common complication in adult. The Aim of the work is demonstration of the case of strangulated bowel obstruction combined with the torsion of Meckel's diverticulum. The female 27 years old was admitted to the surgical department urgently with nausea, vomiting, cramping abdominal pain. The obtained results of the examination were evaluated as acute small bowel obstruction. An emergency surgery was performed - exploratory laparotomy. It was detected: axial torsion of Meckel's diverticulum followed by gangrene, its topside was attached to the dorsal peritoneum by retained fibrous vitelline band. This diverticulum also formed a loop which caused strangulation of the small intestine. The correct diagnosis of Meckel's diverticulum before surgery is generally impossible, because complicated diverticulum imitates many other abdominal pathologies. The torsion of the Meckel's diverticulum is one of the rare complications. In our case, one patient encountered two complications of the Meckel's diverticulum: its torsion with gangrene and acute intestinal obstruction. Exploratory laparotomy is a mandatory procedure for the detection of complicated Meckel's diverticulum and correct treatment.

Keywords: *Meckel's diverticulum, bowel obstruction, torsion, exploratory laparotomy.*

Introduction

Meckel's diverticulum is the congenital anomaly of gastrointestinal tract, and it is represented by the residue of the vitelline or omphalomesenteric duct, which is believed to disappear at birth. Frequency of Meckel's diverticulum is about 1 - 3%; most cases are asymptomatic and are detected by chance during laparotomy or autopsy [1].

In most cases, the clinical symptoms of the diverticulum appear in early childhood. Most patients in whom the symptoms develop are younger than 10 years old. There are various complications associated with Meckel's diverticulum, including hemorrhage, intestinal obstruction, inflammation and perforation. Axial torsion with subsequent gangrene of the diverticulum is a rare complication mentioned before. Bleeding is the most common complication in children, while intestinal obstruction seems to be the most common complication in adults [2,3,4]. There are many mechanisms for the development of the small intestinal obstruction caused by the Meckel's diverticulum. It may be developed as a consequence of the invagination of the into the intestinal lumen, as a result of a swirling around the diverticulum joining with a navel; adhesions, congenital meso-diverticular bands, diverticulitis, obstruction by foreign bodies, inclusion of the diverticulum into a hernia, neoplasms; the formation of the adhesion is also possible which passes between the diverticulum and the base of the mesentery that forms the loop, where the part of the small intestine may enter and it causes its obstruction [5,6,7].

Since it is difficult to diagnose exactly before the operation, the decision whether to perform the operation is delayed, and there may appear serious complications.

The aim of this article is to demonstrate a case of strangulation intestinal obstruction associated with the torsion of Meckel's diverticulum determined in the clinic with the description of the tactics of surgical treatment in a particular patient.

Case Presentation

We managed to observe and perform the treatment of the patient in whom Meckel's diverticulum was complicated with the formation and progression of intestinal obstruction, in combination with torsion and necrosis of the diverticulum.

A woman of 27 years old was admitted to the surgical department of the 3rd Poltava city clinical hospital on November 3rd, 2017 in emergency with the diagnosis "Acute appendicitis? Partial intestinal obstruction".

At the moment of hospitalization, she complained of nausea and vomiting, weakness, episodes of acute, severe abdominal pain. From anamnesis: within 24 hours, the patient mentioned the appearance of abdominal pain without clear localization, accompanied by vomiting and nausea from time to time. The last 12 hours she marked the delay in gases and vapors. There were no operations on the abdominal cavity before. Objectively: skin was of normal color and its turgor was preserved, the tongue was dry, the pulse was 110 beats per minute, arterial pressure was 110/70 mm Hg. The temperature of the body was 36.5 °C,

the abdomen was moderately swollen, mild, painful and moderately tense in the hypogastric region and in both iliac regions, more in the right iliac region, during auscultation the intestinal sounds were hypoactive. When rectal examination, an empty rectal ampulla was detected, no tumors were found. Leukocytosis was $9,0 \times 10^9/l$, erythrocytes - $3,85 \times 10^{12}/l$, hemoglobin - 110 g/l, and hematocrit - 31,3%; liver and pancreatic enzymes were not elevated. On the plan X-ray examination of the abdominal cavity 2 levels of fluid with air above them in the small intestine were found. The results of the ultrasound examination of the abdominal cavity were as follows: the presence of fluid in the abdominal cavity, the loops of the small intestine expanded with fluid and gas, the pendulum-like movement of the chyme in the small intestine visualized. The obtained results of the examination were interpreted as acute intestinal obstruction.

After the preoperative preparation an urgent operation was performed under general anesthesia - exploratory laparotomy. Such pathological changes were found: up to 400 ml of serous-hemorrhagic exudate was dried, conglomerate of the small intestine loops over 130 cm long, clasped at its base by a loop-like structure, that loop was similar to a cord-like adhesion between the base of the mesentery and the part of the black colored intestine. Intestine loops were enlarged in diameter up to 5 cm with thickening of the wall up to 12 mm. The content of the small intestine was fluid and gaseous components. After separating the adhesion from the mesentery, the conglomerate of the small intestine loops smoothed out and after that it was found that the part of the black colored intestine was gangrene-altered Meckel's diverticulum at the distance of 70 cm from the ileocecal valve (Figure 1), torsion around its axis, the top of which was attached to the dorsal peritoneum. The diverticulum and its adhesion formed a loop that caused the strangulation of the small intestine.

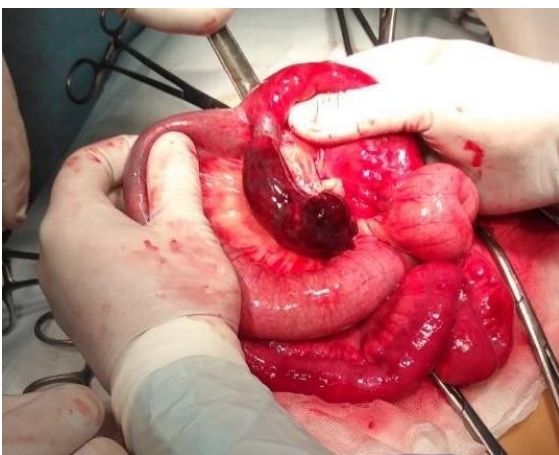


Figure 1.

The necrotic Meckel's diverticulum was resected, the intestine wall was sewn with a non absorbable thread 3-0 with two-row sutures in the cross-cut direction to the axis of the intestine. The nasointestinal decompression was performed by the tube to the ileocecal valve. The

peritoneum was carefully washed out and the pelvic drainage inserted.

Histological examination of the surgical material was as follows: edema, expressed inflammatory infiltration in all layers of the small intestine, spasm of vessels, centers of necrosis.

The postoperative period was going through without complications. The patient was discharged from the surgical department on the 9th day in a satisfactory condition for ambulatory treatment. The patient went through the examination in 2 months. She didn't have any complaints, the general condition was satisfactory.

Discussion

Meckel's diverticulum was first described by Fabricius Hildanus in 1598. Its name comes from German anatomist Johan Friedrich Meckel, who described the embryological and pathological features of the diverticulum in 1809. Meckel's diverticulum is the most common congenital anomaly of the gastrointestinal tract that occurs in 2% of the population. It occurs due to incomplete obliteration of the proximal part of the vitelline duct [8]. This is a real diverticulum and histologically all four intestinal layers are present in it. The diverticulum is usually within 100 cm from the ileocecal valve on the anti-mesenteric wall of the intestine.

The correct diagnosis of Meckel's diverticulum before the operation is generally not possible, since the complicated diverticulum imitates many other abdominal pathologies. The pain in most cases localized in the right lower quadrant of the abdominal cavity is a common symptom that occurs in the case of a Meckel's diverticulum torsion. The duration of the pain may change [9]. If the inflamed diverticulum undergoes gangrenous changes or perforation appears, the signs of peritonitis and sepsis may also be present. So, in such cases, the preliminary diagnosis of a complicated Meckel's diverticulum is usually absent. Appendicitis, obstruction of the small intestine, pancreatitis are only some of wrong preliminary diagnoses. Such clinical features of obstruction of the small intestine as constipation, spastic abdominal pain, vomiting and swelling of the abdominal cavity were observed in the patient. The intestinal obstruction is the most common complication in adult patients [2]. Ileus caused by the Meckel's diverticulum often has an acute course (strangulation, volvulus, obturation).

The torsion with the subsequent gangrene of Meckel's diverticulum is one of the rare complications. It occurs due to torsion around its axis [10], which is defined as the axial rotation of Meckel's diverticulum on its basis without the involvement of the attached loop of the ileum or its mesentery. It can lead to compression of its vessels and finally to the gangrene of the diverticulum. There are many factors associated with the axial torsion of Meckel's diverticulum, but the mechanisms which are on the bases on its isolated torsion are not investigated yet till the very end. Attaching the distal end of the diverticulum to the

umbilicus or to the ileal mesentery through the fibrous adhesion increases the chances of torsion of Meckel's diverticulum [11]. Another potential risk factor is the primary neoplasm that arise in the diverticulum, which is a very rare situation [12]. Anatomical characteristics such as the length and width of Meckel's diverticulum, as well as the diameter of its base, are important contributing factors which attract attention when discussing this problem. The risk of torsion increases with increasing the length, as well as with a narrow base of the diverticulum [13]. In our patient around the narrow base of the diverticulum there was an axial torsion. The length of the diverticulum was 9 cm and its top was attached to the dorsal peritoneum by means of adhesion.

In our case, the preliminary diagnosis was acute intestinal obstruction. Plain X-ray of the abdominal cavity and ultrasound were the additional methods of examination that made it possible to diagnose ileus, but they were completely uninformative according to the complicated Meckel's diverticulum.

The adhesion between the top of Meckel's diverticulum and base of the ileal mesentery formed a loop, and in the "window" formed by this, a conglomerate of the loops of the intestine got into. At the same time, the axial torsion of the diverticulum and the strangulation of the loops of the small intestine developed. One patient got two complications of the Meckel's diverticulum. In this situation only exploratory laparotomy allowed to diagnose correctly.

Conclusions

The exact pre-operative diagnosis was impossible because of the nonspecific nature of clinical and radiological findings. The abdominal radiography and sonography showed high diagnostic value for acute intestinal obstruction, although they were completely uninformative in reference to the discovery and torsion of the Meckel's diverticulum. Exploratory laparotomy was a mandatory procedure necessary for the detection of pathological lesions and for the correct treatment. The clinician should remember such a rare pathology in adults to reach the right diagnosis faster and avoid unnecessary complications.

References

1. Turgeon DK., Barnett JL. Meckel's diverticulum. *Am J Gastroenterol* 1990; 85:777-81.
2. Kaya O, Moran M, Özdemir F, Çetinküner S. A rare cause of intestinal obstruction: Meckel's diverticulitis. *Turk J Med Sci* 2008;38:277-9.
3. Dumper J, Mackenzie S, Mitchell P, Sutherland F, Quan ML, Mew D. Complications of Meckel's diverticula in adults. *Can J Surg* 2006;49:353-7.
4. Lihonenko OV, Ivanov RP, Lihonenko OO. Dyvertikul Mekkelia yak prychna hostroi spaikovoi neprokhidnosti kyshechnyka. *Klinichna khirurgiia* 2004;7:60. [In Ukrainian]
5. Park JJ, Wolff BG, Tollefson MK, Walsh EE, Larson DR. Ileus due to Meckel's diverticulum 354 Temmuz - July 2012 *Ulus Travma Acil Cerrahi Derg Meckel diverticulum: the Mayo Clinic experience with 1476 patients (1950-2002)*. *Ann Surg* 2005;241:529-33.
6. Tomikawa M, Taomoto J, Saku M, Takeshita M, Yoshida K, Sugimachi K. A loop formation of Meckel's diverticulum: a case with obstruction of the ileum. *Ulus Travma Acil Cerrahi Derg* 2003;9:134-6.

7. Sharma RK, Jain VK. Emergency surgery for Meckel's diverticulum. *World J Emerg Surg* 2008;3:27.
8. Limas C, Seretis K, Soultanidis C, Anagnostoulis S. Axial torsion and gangrene of a giant Meckel's diverticulum. *J Gastrointest Liver Dis.* 2006;15:67-68.
9. Mackey WC, Dineen P. A fifty years experience with Meckel's diverticulum. *Surg Gynecol Obstet.* 1983;156:56-64.
10. Guss DA, Hoyt DB. Axial volvulus of Meckel's diverticulum: a rare cause of acute abdominal pain. *Ann Emerg Med.* 1987;16:811-12.
11. Parab SV, Salve PG, Dahiphale A, Thakare R, Aiwale A. Axial Torsion of Meckel's Diverticulum: A Rare Case Report. *Journal of Clinical and Diagnostic Research: JCDR.* [Internet]. 2017 [cited 2018 Mar. 23];11(9):5-6. Available from: <https://www.ncbi.nlm.nih.gov/pmc/articles/PMC5713797> DOI:10.7860/JCDR/2017/28613.10580.
12. Almagro UA, Erickson L Jr. Fibroma in Meckel's diverticulum: a case associated with axial and ileal volvulus. *Am J Gastroenterol.* 1982;77:477-80.
13. Toshihiko W, Hirofumi O. Two cases of Meckel's diverticulum torsion. *Jpn J Gastroenterol Surg.* 2002;35:180-83.

Correspondence to:

Mykola Kravtsiv, PhD,

Associate Professor

4th Department of Surgery with Minimally Invasive Surgery

Higher State Educational Establishment of Ukraine "Ukrainian Medical Stomatological Academy".

Address: 23 Shevchenko Str., Poltava, Ukraine, 36011

tel.: +38 (0532) 60-20-51; +38 (067) 940-11-30

E-mail: kravtsiv@me.com