

A case report of a rare course of secondary chronic odontogenic osteomyelitis of the upper jaw in a young patient

Maksym Skrypnyk^{1^}, Margarita Skikevych^{2^}, Tatiana Petrushanko^{1^}

¹Department of Therapeutic Dentistry, Poltava State Medical University, Poltava, Ukraine; ²Department of Surgical Dentistry and Maxillofacial Surgery with Plastic and Reconstructive Surgery of Head and Neck, Poltava State Medical University, Poltava, Ukraine

Contributions: (I) Conception and design: M Skrypnyk, M Skikevych; (II) Administrative support: M Skikevych, T Petrushanko; (III) Provision of study materials or patients: M Skrypnyk, M Skikevych; (IV) Collection and assembly of data: M Skrypnyk, T Petrushanko; (V) Data analysis and interpretation: All authors; (VI) Manuscript writing: All authors; (VII) Final approval of manuscript: All authors.

Correspondence to: Maksym Skrypnyk. 2-21-19, Yushima, Bunkyo-ku, Tokyo, 113-0034 Japan. Email: maximskrypnyk97@gmail.com.

Background: Chronic jaw osteomyelitis is an inflammatory disease of the entire bone which results in jaw destruction and sequestrum formation, usually it's more common in the lower jaw. Only a few clinical cases have documented the development of chronic odontogenic osteomyelitis on the upper jaw that is why the clinical course of the disease is variable and not typical in different patients. A quite rare variant of chronic maxilla osteomyelitis manifestation in a healthy young individual that was undiagnosed for a long time is presented in this case report.

Case Description: This clinical case report demonstrates a secondary chronic odontogenic osteomyelitis of the upper jaw in a young male individual. A patient has complains of the presence of the hard formation in the vestibular alveolar bone of the right upper jaw, enlargement of the cervical lymph nodes on the right side, high body temperature. On examination the face asymmetry was observed, swelling of the soft tissues on the right side, cervical lymphadenitis on the right side and poor oral hygiene. A mucosal defect and exposed bone with a diameter of 1.5 cm was detected on the vestibular surface of alveolar bone, the oral mucosae around the defect was hyperaemic and swollen. Tooth 1.6 was dark in color with a large filling on the occlusal surface, painful percussion, class 1 mobility. Cone beam computed tomography was performed to diagnose changes in the bone and maxillary sinus. The treatment of a patient was significantly complicated because of financial factor. After 10 days of postoperative treatment complete wound healing was observed, with the occurrence of alveolar bone deformation.

Conclusions: A not typical clinical course for young age healthy individual of the upper jaw osteomyelitis is presented. Therefore, a disease was undiagnosed for a long time during the regular check-ups by general dentists. Taking in account a difficult financial status, young age, good health of a patient, an optimal treatment method of the upper jaw chronic osteomyelitis was provided, using minimal invasive and defect-oriented approaches of surgical treatment.

Keywords: Case report; chronic osteomyelitis; maxilla; upper jaw; inflammatory diseases

Received: 04 September 2022; Accepted: 10 February 2023.

doi: 10.21037/fomm-22-44

View this article at: <https://dx.doi.org/10.21037/fomm-22-44>

[^] ORCID: Maksym Skrypnyk, 0000-0002-9552-4098; Margarita Skikevych, 0000-0002-4401-2703; Tatiana Petrushanko, 0000-0002-1001-5404.

Introduction

Background

Osteomyelitis of the jaws is an infectious purulent-necrotic process, which develops in the bone and surrounding soft tissues caused by aggressive factors of a physical, chemical, or biological origin on the background of the previous one sensitisation and neurohumoral disturbances that precede the development of the disease. As osteomyelitis can be considered only a purulent inflammation of the bone with a significant necrotic component. Osteomyelitis is common in the mandible, which comprises almost 90% of all cases and mostly has an odontogenic infection (1). Osteomyelitis of the jaws can have odontogenic, traumatic, haematogenous and specific origin. The most common is odontogenic osteomyelitis of the lower jaw. Osteomyelitis of the jaws in the post-antibiotic era is rare but sometimes they occur, most frequently in the mandible, whose thick cortical bone derives its blood supply from the inferior alveolar artery. In contrast, the maxilla has thin cortices with multiple blood supply and is more resistant to osteomyelitis (2). Depending on the involvement of bone structures in the process, osteomyelitis can be localised, focal and diffuse. With localised osteomyelitis, the pathological process occurs within the periodontium of two or three teeth. In focal osteomyelitis, the bone of the alveolar process and body or ramus of the

mandibular is involved. Diffuse osteomyelitis is characterised by total damage of the entire jaw or half of it (3).

Rationale and knowledge gap

Chronic osteomyelitis of the upper jaw is very rare case in clinical practice. On search with diverse combination of the key words “upper jaw, jaw, maxilla, osteomyelitis” in the PubMed database only 5 single clinical cases were found since 1931 and most of them had toxic origin, triggered by heavy drugs usage (4). There are no large-scale studies dedicated to chronic maxilla odontogenic osteomyelitis, due to the small number of cases.

Objective

Clinical course of a quite rare variant of chronic maxilla osteomyelitis in a healthy young individual that was undiagnosed for a long period of time is demonstrated in this case report. That is why, we consider that this case is interesting from a clinical perspective.

We present the following clinical case in accordance with the CARE reporting checklist (available at <https://fomm.amegroups.com/article/view/10.21037/fomm-22-44/rc>).

Case presentation

All procedures performed in this study were in accordance with the ethical standards of the institutional and/or national research committee(s) and with the Helsinki Declaration (as revised in 2013). Written informed consent was obtained from the patient for publication of this case report and accompanying images. A copy of the written consent is available for review by the editorial office of this journal.

A 25-year-old male patient was hospitalised 04/02/2022 at the maxillofacial department of the Poltava Regional Hospital named after Sklifosovsky. He complained of the presence of the hard formation in the alveolar process of the right upper jaw, enlargement of cervical lymph nodes on the right side. According to the patient words the formation had appeared two years ago. It was preceded by acute purulent apical abscess of the right maxilla, for which a periostomy was performed and antibiotic therapy was prescribed. Previously, the patient had two regular check-ups in a private rural outpatient clinic about this formation. Both times, dentists said that this formation is not required any treatment. A patient did not have bad habits, any chronic systemic diseases and serious interventions in the past.

Highlight box

Key findings

- A quite rare clinical course of chronic maxilla osteomyelitis in a healthy young individual, which was undiagnosed for a long period of time is presented.

What is known and what is new?

- Odontogenic origin chronic osteomyelitis is not typical for maxilla that is why dentists are not familiar and cannot recognize the disease on early stages.
- Untypical manifestation of chronic odontogenic maxilla osteomyelitis in young healthy individual, with a formation of a massive sequestrum, relatively asymptomatic and with a blurred clinical course is presented in the manuscript.

What is the implication, and what should change now?

- Previous endodontic treatment, was ineffective and led to exacerbation, due to the huge sequester shape around tooth roots. Due to the financial challenging, the basic treatment was used that showed sufficient result. Diagnostic procedures should be more careful, doctors should examine not only the place of the patient's concern.

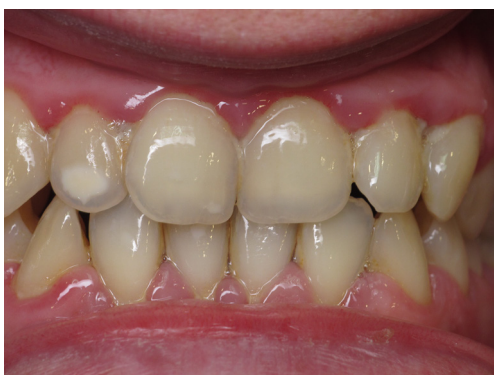

Figure 1 Oral cavity status of the patient.

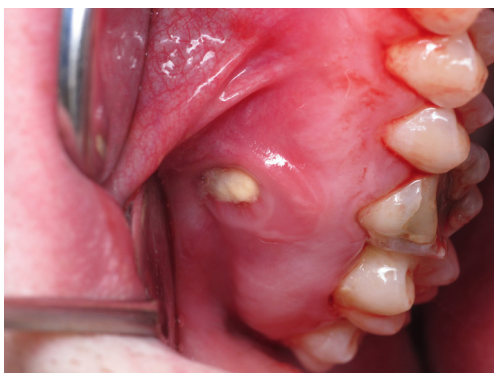

Figure 2 A mucosal defect and an exposed alveolar bone in the projection of tooth 1.6.

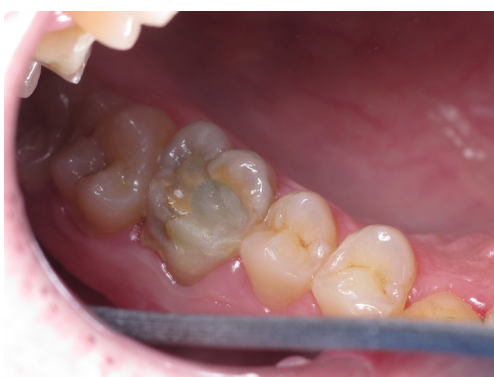

Figure 3 Occlusal surface of the tooth 1.6.

Complete blood tests were done, general examination of the neck, face and oral cavity was performed and cone-beam computed tomography of the upper and lower jaw were done. A patient has a low income and cannot afford

expensive treatment methods and diagnostic.

While the examination the face of a patient was asymmetrical—swelling of the soft tissues of the right cheek, the color of the skin was natural, cervical lymph nodes on the right side where enlarged and painful during the palpation. Body temperature 37.4 °C. Mouth opening was free. Poor oral hygiene was diagnosed. The gums were hyperaemic, swollen, bleeding heavily while probing, there were huge mineralized and non-mineralized dental deposits, approximal plaque index =7.1%, papilla bleeding index =2.6, Oral Hygiene Index-Simplified (OHI-S) =2, Decay-missing-filled index (DMFT) =8 (Figure 1). The back and base of the tongue were densely coated with white plaque, the fungiform papillae of the tongue were hyperaemic.

Preliminary diagnosis—odontogenic right-sided osteomyelitis of the right maxilla, causative tooth 1.6.

On the upper right alveolar bone in the projection of the roots of the tooth 1.6, a mucosal defect and exposed bone with a diameter of 1.5 cm was detected, the oral mucosae around the defect was hyperemic and swollen (Figure 2). Tooth 1.6 was dark in color with a large filling on the occlusal surface. A percussion of tooth 1.6 was painful (Figure 3). Tooth 1.6 had class 1 mobility according to the Miller's classification (5).

There were slight pro-inflammatory changes in the complete blood count analyses RBC $5.1 \times 10^{12}/L$, WBC $10.2 \times 10^9/L$, HGB =145 g/L, PLT $=280 \times 10^9/L$, Segmented neutrophils 69%, stab neutrophils 2%, lymphocytes 18,5%, monocytes 8%, eosinophils 2%, basophils 0.5%, ESR =16 mm/h.

The following data were determined on CT examination: in the tooth 1.6, a large-sized filling on the occlusal surface of the tooth 1.6, there were no signs of filling material in the root canals of tooth 1.6, in the area of the root apices of the tooth 1.6, a huge bone defect (11 mm × 8.1 mm) was observed in the coronal plane (Figure 4) and (7.8 mm × 4.6 mm) in the sagittal plane (Figure 5), discontinuation of the vestibular cortical lamina, defect of the maxillary sinus floor and alteration of the cancellous bone pattern around the roots of the tooth. Slight hypertrophy of the right maxilla sinus floor mucosa.

A treatment plan was designed:

- (I) Professional hygiene and oral cavity sanitation
- (II) Sequestrectomy with the tooth 1.6 extraction
- (III) Postsurgical care

Professional oral hygiene and filling of all carious cavities and replacement of unsatisfied fillings were performed one week before. Before the surgery atropine sulfate solution

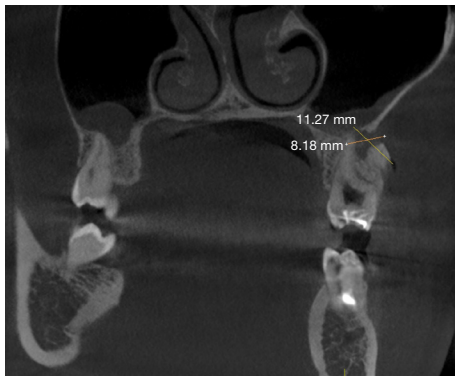


Figure 4 Tooth 1.6 on CT, coronal plane view, where a complete destruction of vestibular alveolar cortical lamina and a sequestered bone fragment are observed.

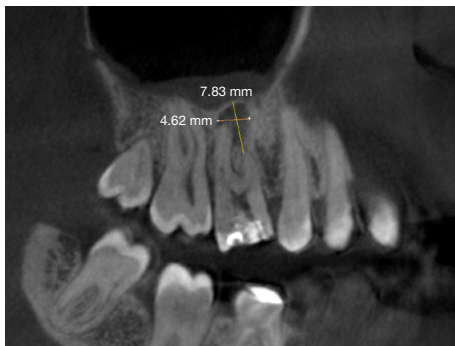


Figure 5 Tooth 1.6 on CT, sagittal plane view.

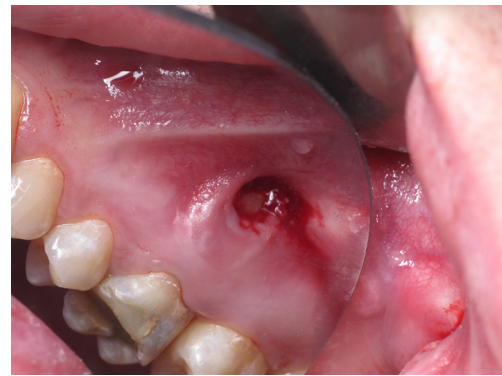


Figure 6 After the extraction of the sequester on the vestibular surface of alveolar bone.

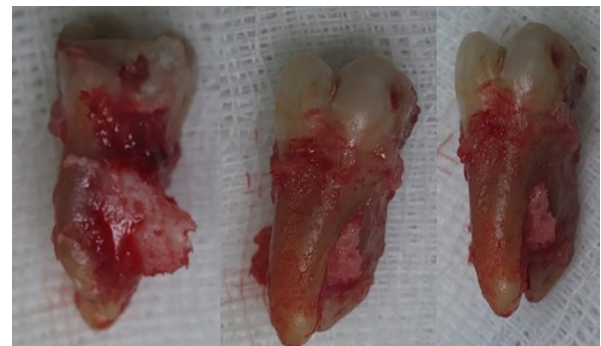

Figure 7 Tooth 1.6 after extraction with a huge sequester connected to the tooth.

0.05% 0.8 mL was administered intramuscularly to slow down the salivation. A sequestrectomy operation was performed with simultaneous flap surgery with soft tissues (*Figure 6*). Infraorbital, tuberal, and palatal anaesthesia with Ultracaine D-S 3.4 mL was performed. The mucous membrane around the bone defect was mobilized, and a sequestrectomy was performed directly. Tooth 1.6 was extracted with a huge sequester that sucked together with the tooth, alveolar bone after the extraction underwent a curettage to remove small sequesters (*Figure 7*). Clinically, the perforation between the maxillary sinus and oral cavity was not detected. The mucosal defect was sewn up with knotted sutures. The tooth socket was stitched with guided sutures. Haemostasis (*Figure 8*).

Dexalgin 2.0 mL was prescribed intramuscularly after the surgery. For systemic antimicrobial treatment we choose antibiotic Cifran CT (per os 1 pill 2 times a day for 5 days)

and for local antimicrobial therapy mouth rinse Angilex (4 times a day for 7 days).

To reduce pain and inflammation Nimesulide was prescribed (per os 2 times a day for 3 days). After the following treatment, the patients didn't have any complications or adverse effects. The defect recovered within 10 days after the surgery.

The treatment strategy was based on a patient payment capacity, he could not afford an expensive treatment such as bone graft augmentation. Therefore, a minimally invasive, defect-oriented approach was chosen in this clinical situation, taking to account young age, good health and satisfactory regenerative potential of a patient. Extracted tooth with bone sequestrum were sent for pathomorphological examination, which showed non-vital bone (empty osteocyte lacunae) and eroded outline with superficial lacunae, neutrophilic polymorphonuclear cells

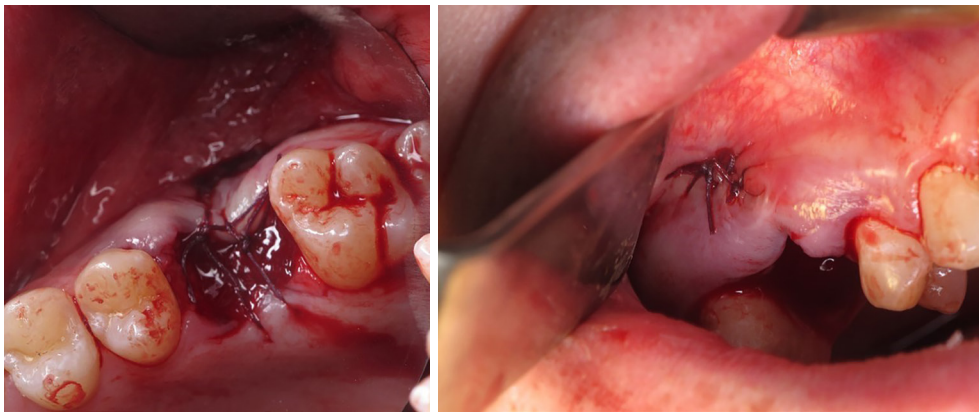


Figure 8 Tooth socket and mucosa defect after the tooth extraction and sutures placement.

and dense surface growth of bacteria. Pathomorphological diagnosis—chronic osteomyelitis.

The day after the treatment a patient had slight pain in the place of surgical intervention and assessed his state as normal. After 10 days of postoperative treatment complete wound healing was observed, with the occurrence of alveolar bone deformation. For four months after the treatment a patient did not have any complaints.

No unsatisfactory events were observed except a significant loss of the alveolar bone loss. Unfortunately, at the beginning of the war between Ukraine and Russia a connection with the patient was interrupted and we contact with him via phone only.

Discussion

Key Findings

In the presented case the disease was unrecognized for a long period. If clinicians were more familiar with variants of chronic odontogenic osteomyelitis manifestation, such an extensive lesion would not have occurred. A secondary chronic odontogenic osteomyelitis of the upper jaw was observed in 25 years old, healthy man what is not typical. In this study, the development of chronic odontogenic osteomyelitis preceded not effective treatment of acute apical abscess of the tooth 1.6, which was only periostotomy and antibiotic treatment, which transformed it into chronic osteomyelitis. Huge sequestrars were formed around the tooth from the vestibular alveolar bone and between and around the roots of the 1.6 tooth that were sucked firmly together, due to the long last inflammation, as we suggest. A conservative treatment, which is endodontic treatment, is

not effective in this clinical case, due to the huge sequester shape and formation of mature biofilm on the root surfaces.

Strengths and limitations

The limitation of the clinical case is the financial difficulties of the patient that unable usage of expensive diagnostic methods and treatment such as bone augmentation, that can improve treatment outcomes, such as bone regeneration, and prevent atrophy of alveolar bone. The strengths of the study is that a simple diagnostic methods and clinical thinking are crucial in a proper diagnostic. A doctor can provide sufficient treatment even using simple, empirically based treatment methods without expensive diagnostic tools and treatment methods. In the case report shown a rare variant of chronic maxilla osteomyelitis manifestation in a healthy young individual.

Comparison with similar researches

Nowadays, there is a trend for the decreasing of the prevalence of jaw osteomyelitis in developing countries, due to the successful prevention of basic dental diseases and antibiotic treatment. The prevalence rate of this disease was found to be predominantly among the older males than among females 41–50 years (6). As were mentioned above mostly osteomyelitis occurs in the lower jaw, due to the peculiarities of blood supply. Mostly cases of acute osteomyelitis are diagnosed. Only in a few cases, osteomyelitis of the upper jaw was diagnosed as a rare pathology and in each presented clinical case disease has diverse course, origin, symptomatic, volume of involving

bone, chosen treatment plan (2,3,6,7). Occurrence, type, severity and prognosis of chronic osteomyelitis depend on various factors, including the characteristics and virulence of the infecting pathogen, the physiological class of the host and the mechanism (source) of the infection (8). The manifestation of the chronic odontogenic osteomyelitis of the upper jaw is variable, in documented clinical cases the sequestration involves a huge volume of the upper jaw bone and has a non-odontogenic origin and occurs in immunocompromised patients only (9-11). The chronicity of the disease reflects the inability of the organism to remove a pathogen, may be due to the lack of treatment or inadequate treatment. Pathogenic microorganisms are located in the root canal system of the tooth, which is not always available for complete elimination by endodontic treatment, due to the complicated architecture of the root canal system (12,13). Not less important that microorganisms are embedded in the bone sequestrum that is inaccessible for immune cells, all of this requires doctor's intervention as fast as possible to stop the propagation of the disease (14).

Explanations of findings

In this clinical case, secondary chronic odontogenic osteomyelitis of the upper jaw was observed in 25 years old, healthy man what is not typical. The disease was caused by the chronic site of bacterial intoxication, which is tooth 1.6. Patients had blurred and relatively asymptomatic clinical course of disease that made it undiagnosed for a long time. Long time without proper treatment led to massive sequestrum formation and mucosae defect occurrence. In this clinical case we observed not advanced symptoms for osteomyelitis, which was caused by the anatomic site of the disease (upper jaw that has better system of blood supply) and young age of individual. Usually severity and involving bone volume by osteomyelitis depend on the systemic condition of the patient, which deteriorates the stream of the disease (diabetes mellitus, obesity, malnutrition, blood diseases, and medicines consumption) (15-18).

Implications and actions needed

General principles of osteomyelitis treatment were used, which is systemic antimicrobial therapy, surgical approach with incision and drainage, sequestrectomy. Patient's financial challenges restricted us in choosing of expensive treatment and diagnostic methods, that is why empirical based treatment approach was used. In jaw

osteomyelitis multiple species including Actinomyces, Fusobacterium, Parvimonas, Tannerella, Porphyromonas, and Staphylococcus, are synergistically involved (19). Therefore in successful treatment important is complete eradication of infection to restore local blood supply, which was compromised by the acute phase of infection and the necrotic bone-sequestras. The periosteum still contains the osteogenic potential for recovery. Also, biofilm that forms on the walls of root canals and in the lacunae of root cement should also be eradicated to prevent exacerbation of the disease. Even a usage of a simple treatment method led to sufficient clinical outcomes with a complete recovery.

Conclusions

During the regular dental check-up always important to examine not only teeth and gingiva, but also all other soft tissues such as the tongue, alveolar bone mucosae, floor of the oral cavity etc. where life-threatening inflammatory diseases and tumor processes can occur. The clinical case report presents an untypical course of chronic localised odontogenic osteomyelitis with a formation of a huge sequestrum in a young age individual that remained undiagnosed for a lot time. Even being limited to patient's material resources, that significantly restrict diagnostic and treatment methods, using clinical thinking, knowledge of aetiology and pathogenesis dentist can diagnose any disease and obtain a satisfactory result after the treatment.

Acknowledgments

Funding: None.

Footnote

Reporting Checklist: The authors have completed the CARE reporting checklist. Available at <https://fomm.amegroups.com/article/view/10.21037/fomm-22-44/rc>

Peer Review File: Available at <https://fomm.amegroups.com/article/view/10.21037/fomm-22-44/prf>

Conflicts of Interest: All authors have completed the ICMJE uniform disclosure form (available at <https://fomm.amegroups.com/article/view/10.21037/fomm-22-44/coif>). The authors have no conflicts of interest to declare.

Ethical Statement: The authors are accountable for all

aspects of the work in ensuring that questions related to the accuracy or integrity of any part of the work are appropriately investigated and resolved. All procedures performed in this study were in accordance with the ethical standards of the institutional and/or national research committee(s) and with the Helsinki Declaration (as revised in 2013). Written informed consent was obtained from the patient for publication of this case report and accompanying images. A copy of the written consent is available for review by the editorial office of this journal. The clinical case was approved for publishing by the ethics committee of Poltava State Medical University protocol No 203.

Open Access Statement: This is an Open Access article distributed in accordance with the Creative Commons Attribution-NonCommercial-NoDerivs 4.0 International License (CC BY-NC-ND 4.0), which permits the non-commercial replication and distribution of the article with the strict proviso that no changes or edits are made and the original work is properly cited (including links to both the formal publication through the relevant DOI and the license). See: <https://creativecommons.org/licenses/by-nc-nd/4.0/>.

References

- Andre CV, Khonsari RH, Ernenwein D, et al. Osteomyelitis of the jaws: A retrospective series of 40 patients. *J Stomatol Oral Maxillofac Surg* 2017;118:261-4.
- Rahpeyma A, Khajehahmadi S. A case series of uncommon causes of maxillary osteomyelitis: Understanding the pathology and recognizing the risks. *Trop Doct* 2022;52:125-30.
- Momodu II, Savaliya V. Osteomyelitis. In: StatPearls [Internet]. Treasure Island (FL): StatPearls Publishing; 2022 [cited 2022 Aug 26]. Available online: <http://www.ncbi.nlm.nih.gov/books/NBK532250/>
- National Library of Medicine, PubMed.gov, accessed 1 August 2022 Available online: <https://pubmed.ncbi.nlm.nih.gov/?term=upper+jaw%2C+jaw%2C+maxilla%2C+osteomyelitis&srt=pubdate>
- Wu CP, Tu YK, Lu SL, et al. Quantitative analysis of Miller mobility index for the diagnosis of moderate to severe periodontitis - A cross-sectional study. *J Dent Sci* 2018;13:43-7.
- Akshayaa L, Ramani P. Prevalence of Osteomyelitis in Jaws among the Patients Visiting Private Dental Hospital: An Institutional Study. *J Pharm Res Int* 2021;425-32.
- Said Ahmed WM, Elsherbini AM, Elsherbiny NM, et al. Maxillary Mucormycosis Osteomyelitis in Post COVID-19 Patients: A Series of Fourteen Cases. *Diagnostics (Basel)* 2021;11:2050.
- Panteli M, Giannoudis PV. Chronic osteomyelitis: what the surgeon needs to know. *EFORT Open Rev* 2016;1:128-35.
- Oliveira TI, de Carli ML, Ribeiro Junior NV, et al. Maxillary chronic osteomyelitis caused by domestic violence: a diagnostic challenge. *Case Rep Dent* 2014;2014:930169.
- Habib A, Sivaji N, Ashraf T. Maxillary Osteomyelitis: A Rare Entity. *Case Rep Otolaryngol* 2016;2016:9723806.
- Gupta V, Singh I, Goyal S, et al. Osteomyelitis of maxilla - a rare presentation: case report and review of literature. *Int J Otorhinolaryngol Head Neck Surg* 2017;3:771-6.
- Kostyrenko OP, Vynnyk NI, Koptev MM, et al. Dental crown biomineralization during its histogenesis. *Wiad Lek* 2020;73:2612-6.
- Kostyrenko OP, Vynnyk NI, Koptev MM, et al. Mineralization of teeth enamel after eruption. *Wiad Lek* 2021;74:1297-301.
- Odell EW, Cawson RA. Cawson's essentials of oral pathology and oral medicine. Ninth edition. Edinburgh: Elsevier; 2017.
- Beregova TV, Neporada KS, Skrypnyk M, et al. Efficacy of nanoceria for periodontal tissues alteration in glutamate-induced obese rats-multidisciplinary considerations for personalized dentistry and prevention. *EPMA J* 2017;8:43-9.
- Uddin A, Russell D, Game F, et al. The effectiveness of systemic antibiotics for osteomyelitis of the foot in adults with diabetes mellitus: a systematic review protocol. *J Foot Ankle Res* 2022;15:48.
- Aghahosseini F, Ghasemzadeh Hoseini E, et al. Actinomycotic Osteomyelitis of the Maxilla in a Patient on Phenytoin. *Front Dent* 2022;19:3.
- Skrypnyk M, Petrushanko T, Neporada K, et al. Colonization resistance of oral mucosa in individuals with diverse body mass index. *Journal of Stomatology* 2022;75:171-5.
- Wu S, Wu B, Liu Y, et al. Mini Review Therapeutic Strategies Targeting for Biofilm and Bone Infections. *Front Microbiol* 2022;13:936285.

doi: 10.21037/fomm-22-44

Cite this article as: Skrypnyk M, Skikevych M, Petrushanko T. A case report of a rare course of secondary chronic odontogenic osteomyelitis of the upper jaw in a young patient. *Front Oral Maxillofac Med* 2023.