

V.D. Kuroiedova, Ye. Ye. Vyzhenko, O.A. Stasiuk, Yu.K. Sokolohorska-Nykina, A.V. Petrova
 Poltava State Medical University, Poltava, Ukraine

CEPHALOMETRIC CHARACTERISTICS OF SKELETAL FORMS OF DISTAL BITE

e-mail: polo_nnipo@ukr.net

The article highlights the results of research on the differential diagnosis of skeletal forms in distal occlusion. Distal occlusion is the most common anomaly of the dental system after Angle class I occlusion pathologies and ranges from 38 % to 65 %. The clinical method was to examine patients with Angle class II dental anomalies. The radiological method consisted of the study of lateral cephalograms of patients with the software "AudaxCeph". Nine forms of prognostic distal occlusion have been identified based on cephalometric studies. Among all forms, the most common is maxillary prognathism 35.59 %. The values of cephalometric parameters required for the diagnosis of prognostic distal occlusion are essential for clarifying the form of dental anomaly and permit to detail skeletal forms.

Key words: dental anomaly, upper jaw, lower jaw, prognathism, distal occlusion.

В.Д. Куроедова, Є.Є. Виженко, О.А. Стасюк, Ю.К. Сокологорська-Никина, А.В. Петрова

ЦЕФАЛОМЕТРИЧНА ХАРАКТЕРИСТИКА СКЕЛЕТНИХ ФОРМ ДИСТАЛЬНОГО ПРИКУСУ

В статті висвітлені результати дослідження що до диференційної діагностики скелетних форм дистального прикусу. Дистальний прикус є найбільш розповсюдженою аномалією зубощелепної системи після патологій прикусу I класу за Angle та складає від 38 % до 65 %. Клінічний метод полягав в обстеженні пацієнтів із зубощелепними аномаліями II класу за Angle. Рентгенологічний метод складався з дослідження бокових цефалограм пацієнтів в програмі «AudaxCeph». На підставі проведених цефалометричних досліджень встановлено дев'ять форм прогнатичного дистального прикусу. Серед усіх форм найбільш поширеною є верхньощелепна прогнатія 35,59 %. Значення цефалометричних параметрів, необхідних для постановки діагнозу прогнатичний дистальний прикус, є основними для уточнення форми зубощелепної аномалії та дозволяють деталізувати скелетні форми.

Ключові слова: зубощелепна аномалія, верхня щелепа, нижня щелепа, прогнатія, дистальний прикус.

This study is a fragment of the research project "Optimization of treatment and diagnosis of dental anomalies at different ages", state registration No. 0118U004458.

Distal occlusion is the most common anomaly of the dental system after Engle class I occlusion pathologies. A number of authors believe that the prevalence of distal occlusion is from 38 % to 65 % [3, 4, 6]. At the same time, data from different authors on the prevalence of distal occlusion differ because there is no unified method of examination and criteria for the diagnosis of dental anomalies [1].

Distal occlusion is characterized by the distal ratio of molars and canines and the presence of the sagittal gap, the size of which depends on the severity of functional and aesthetic disorders. Also, prognostic distal occlusion is characterized by a wide variety of clinical forms, and may be complicated by occlusal pathology in other areas.

E. Engle (1889) identified two forms of distal occlusion: II1 and II2. The first form of distal occlusion (II1) is prognathic, when the upper front teeth are excessively tilted forward. The second form of distal occlusion (II2) is accompanied by oral tilt of the central incisors of the upper jaw – retrusion. This position of the incisors of the upper jaw prevents mesial displacement of the lower jaw and delays its growth. Maligin Yu.M. (1970) identified nine types of distal occlusion. Grigorieva L.P. (1995) distinguished four forms of prognostic neutral occlusion and five forms of prognostic distal occlusion. According to the classification of F.Ya. Khoroshilkina three main clinical forms of distal occlusion are distinguished: dentoalveolar form, gnatic (or skeletal) form and mixed (1999). The main forms of class II occlusion pathology are covered in the WHO classification (1989). These forms can be differentiated by an orthodontist with the help of telerradiograms of the head, only the details of the diagnosis will form the correct strategy of orthodontic treatment [9].

Skeletal form of distal occlusion can be formed due to impaired development of the mandible (micrognathia) or upper jaw (macrognathia), retroposition (retrognathia) of the mandible relative to the plane of the anterior cranial fossa or anteposition (prognathism) of the upper jaw, and in combinations of these forms.

The large number of cephalometric parameters by different authors on the one hand gives doctors a wide choice of different indices, and on the other hand complicates the choice of what is really needed in each case [8, 10].

The purpose of the study was to determine and systematize the cephalometric parameters required for the diagnosis of various clinical forms of distal occlusion, to improve the efficacy of diagnosis and orthodontic treatment.

Materials and methods. We examined 59 patients with various types of distal occlusion, including 25 men and 34 women. Prior to treatment, classical clinical and radiological methods were used. The clinical method was to examine patients with Engle's class II dental anomalies. The radiological method consisted of the study of lateral cephalograms in patients and cephalometric parameters by Steiner, Wits, Roth Jarabak in the "AudaxCeph" software (fig. 1). From them were selected those parameters that we consider important for the differential diagnosis of prognostic distal occlusion.

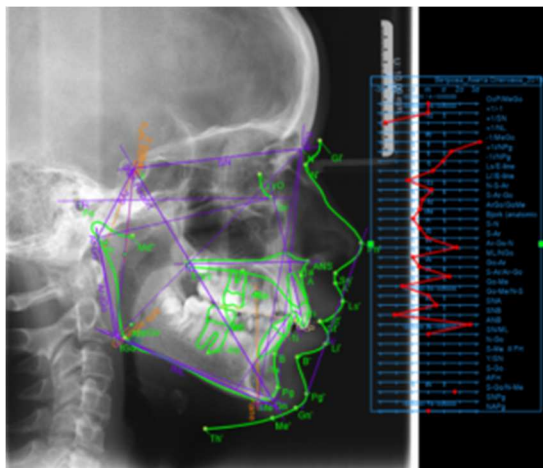


Fig. 1. Analysis of the teleradiogram in the AudaxCeph software, patient B., 15 years old, Engle's diagnosis II₁, mandibular micro- and retrognathia.

SNA ($N = 80 \pm 2^\circ$) - the angle relative to the skull base determines the sagittal position of the upper jaw, and more precisely, the anterior base. **SNPns** ($N = 38.5 \pm 2^\circ$) - the angle relative to the skull base characterizes the position of the posterior upper jaw in the sagittal direction. **SNB** ($N = 78 \pm 2^\circ$) - the angle relative to the base of the skull determines the anteroposterior position of the mandible (anterior base). **SNGo** ($N = 44.5 \pm 2^\circ$) - the angle relative to the skull base determines the position of the posterior base of the mandible. **ANB** ($N = 0 \pm 2^\circ$) is the angle that characterizes the sagittal ratio of the jaws, and more precisely - their bases, i.e. apical bases with each other. **Wits** ($N = 0 - 2$ mm) - the distance between the points AO and BO on the occlusal plane, which are projected from points A and B on the occlusal plane, respectively.

Ans-Pns (N men 56 ± 2 mm, women 52 ± 2 mm) - linear size of the upper jaw. **Go-Me** (N men 69 ± 3 mm, women 65 ± 3 mm) - linear size of the lower jaw. **S-N** (N men 73 ± 2 mm, women 68 ± 2 mm) - the length of the skull base. **Ans-Pns/S-N** ($N = 77 \pm 4\%$) - the ratio of the length of the base of the upper jaw to the length of the base of the skull and is calculated as a percentage. **Go-Me/S-N** ($N = 96 \pm 2\%$) - the ratio of the length of the base of the mandible to the length of the skull base.

The incisal angles give an additional characteristic of the tooth-alveolar forms of distal occlusion and affect the facial profile. **Ii** ($N = 130^\circ$) - inter-cutter angle formed by the intersection of the planes of the upper and lower cutters. inter-cutter angle formed by the intersection of the planes of the upper and lower cutters.

I/ML ($N = 90^\circ$) - the angle formed by the longitudinal axis of the lower incisor and the body of the mandible. **+ I/NL** ($N = 110^\circ$) - the angle formed by the longitudinal axis of the upper incisor and the base of the upper jaw.

Many author's methods of teleradiogram analysis are based only on the use of angular parameters for diagnosis. In this regard, the SNPns and SNGo angles are important not only for determining the sagittal position of the upper and lower jaws, but also for the differential diagnosis of upper jaw prognathism forms or mandibular retrognathia in combination with linear jaw size anomalies.

After all, an increase in the SNA angle can be associated not only with the anteposition of the upper jaw, but also with an increase in the linear size of its base. True prognathism can be spoken about only by increasing both angles (SNA and SNPns). With a normal value of the SNPns angle and increased SNA angle parameters and increased size (Ans-Pns/S-N), we should talk about the upper macro- and prognathism.

The same applies to the differential approach of the lower jaw - lower retrognathia, or in combination - lower micro- and retrognathia. To do this, you need to compare the angles SNGo, SNB and the size of the lower jaw Go-Me/S-N.

Statistical processing was performed in Windows 7, Microsoft Office Excel 2010.

Results of the study and their discussion. Based on the cephalometric studies, we can identify nine forms of prognostic distal occlusion (fig. 2).

Macrognathia of the upper jaw is characterized by an increase in the length of the upper jaw base relative to the norm ($ANS-PNS > N$), as well as relative to the length of the skull base ($ANS-PNS/S-N > N$). Optional features may include an increase in the SNA angle, the intermaxillary ANB angle, and an increase in the WITS parameter.

Micrognathia of the mandible is characterized by a decrease in the length of the mandible base relative to the norm ($Go-Me < N$), as well as the length of the skull base ($Go-Me/S-N < N$). Optional features may include a decrease in the SNB angle, an increase in the intermaxillary ANB angle, and an increase in the Wits parameter.

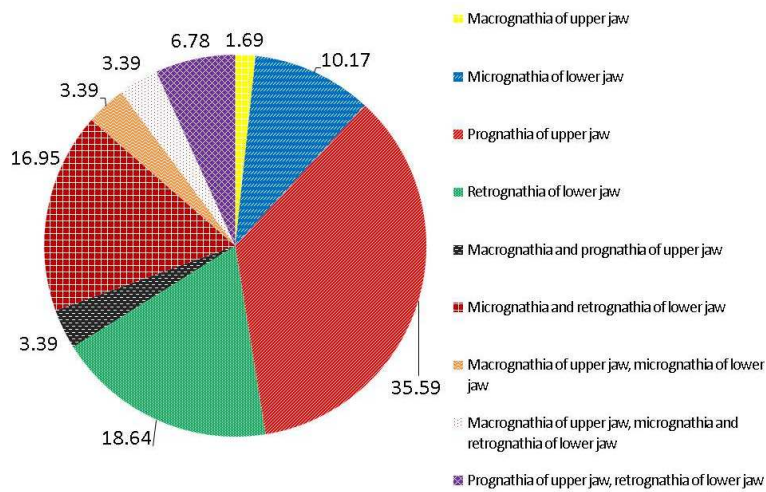


Fig. 2. The structure of the prognostic distal occlusion.

These forms of dental anomalies can be combined with each other. The most common combinations are: maxillary macro- and prognathism, mandibular micro- and retrognathia, maxillary macrognathia and mandibular micrognathia, maxillary macrognathia and mandibular micro- and retrognathia.

According to our studies, among all forms, the most common is maxillary prognathism 35.59% (21/59, 12 men and 9 women), which is characterized by increased angles $SNA=83.44\pm 0.58^\circ$ and $SNPns=39.14\pm 0.39^\circ$ and the normal length of the upper jaw $Ans-Pns=53.15\pm 0.76$ mm. The ratio of the length of the base of the upper jaw to the length of the base of the skull $Ans-Pns/S-N$ is $76.24\pm 0.55\%$. Optional features may be an increase in the intermaxillary angle ANB, in our case the average value is $5.8\pm 0.28^\circ$, as well as an increase in the parameter $Wits=3.95\pm 0.39$ mm. The decrease of the intercuter angle $Ii=128.68\pm 2.05^\circ$ due to protrusion of the mandibular incisors was established, the angle $-1/ML=98.59\pm 1.17^\circ$ was increased.

The second place among the forms of prognostic distal occlusion is associated with anomalies in the lower jaw position. Mandibular retrognathia was found in 11 patients (2 men and 9 women), which is 18.64%. It is characterized by an unchanged length of the mandible base $Go-Me = 65\pm 1.22$ mm, a decrease in the angles $SNB = 77.53\pm 0.66^\circ$ and $SNGo = 41.04\pm 0.56^\circ$. Additional features may be an increase in the intermaxillary angle ANB $5.64\pm 0.32^\circ$, as well as an increase in the Wits parameter 3.94 ± 0.42 mm. Among the incisor parameters, the protrusion of the lower incisors angle $-1/ML = 97.66\pm 1.13^\circ$ was also established.

Mandibular micrognathia in combination with retrognathia was found in 10 patients out of 59 – 16.95% (6 men and 4 women). Micrognathia is characterized by a decrease in the length of the mandible base relative to the norm ($Go-Me < N$), as well as the length of the skull base ($Go-Me/S-N < N$). Optional features may include a decrease in the SNB angle, an increase in the intermaxillary ANB angle, and an increase in the Wits parameter. The mean values in this group were $Go-Me = 65.63\pm 1.09$ mm, $Go-Me/SN = 94.07\pm 1.1\%$. Also reduced angles $SNB = 77.43\pm 0.59^\circ$ and $SNGo = 40.79\pm 0.5^\circ$, increased angle ANB $= 5.75\pm 0.28^\circ$. At the same time, the inter-cutter angle $Ii=128.84\pm 2.08^\circ$ decreased and the angle of inclination of the lower cutters increased $-1/ML = 98.39\pm 1.17^\circ$.

Isolated mandibular micrognathia was detected in 6 patients out of 59 – 10.17% (1 man and 5 women). The mean length of the mandible base was $Go-Me = 60\pm 1.53$ mm, the ratio to the length of the skull base $Go-Me/SN = 89.3\pm 1.6\%$ with a reduced angle $SNV = 75.36\pm 0.77^\circ$, increasing the intermaxillary angle ANB $= 4.95\pm 0.33^\circ$, as well as increasing the parameter $Wits = 3.79\pm 0.53$ mm. Of the indicators that characterize the position of the incisors, the largest deviation from the norm has an angle of $-1/ML = 97.16\pm 1.58^\circ$.

Next in the number of identified patients was the group with a combination of maxillary prognathism and mandibular retrognathia, only 4 men out of 59 (2 men and 2 women), which is 6.78%, with an increase in angles $SNA = 83.18\pm 0.63^\circ$, $SNPns = 39.18\pm 0.4^\circ$ and $ANB = 5.75\pm 0.3^\circ$, reduced angles $SNB = 77.27\pm 0.63^\circ$ and $SNGo = 40.7\pm 0.55^\circ$ at normal values of the sizes of the bases of the upper and lower jaws $Ans-Pns/SN = 75.93\pm 0.53\%$ and $Go-Me/SN = 94.3\pm 1.17\%$, respectively. The cutting angles $II = 128.65\pm 2.27^\circ$ and $+1/NL = 109.65\pm 1.43^\circ$ are within the norm, while the angle of inclination of the lower cutters $-1/ML = 97.16\pm 1.58^\circ$ is increased.

Maxillary prognathism is characterized by increased SNA and SNP angles and unchanged upper jaw base length ($ANS-PNS = N$). Optional signs may include an increase in the intermaxillary ANB angle, as well as an increase in the Wits parameter.

Mandibular retrognathia is characterized by unchanged length of the mandibular base ($Go-Me = N$), decreased SNB and SNGo angles. Optional signs may include an increase in the intermaxillary ANB angle, as well as an increase in the Wits parameter.

The same number of patients, 2 men (3.39 %), was found in groups with different forms of combinations, namely, maxillary macro- and prognathism (1 man and 1 woman), maxillary macro- and mandibular micrognathia (2 women) and maxillary macro- and prognathia, mandibular micro- and retrognathia (1 man and 1 woman).

In patients with macro- and prognathism of the upper jaw increased angles $SNA = 88.2 \pm 2.58^\circ$, $SNPns = 40.24 \pm 1.42^\circ$ and $ANB = 5.4 \pm 1.08^\circ$, as well as increased linear parameters $Ans-Pns = 57.39 \pm 1.12$ mm, $Ans-Pns/SN = 80.93 \pm 2.66$ %. Increased cutter angles $+1/NL = 114 \pm 1.75^\circ$, $-1/ML = 102.8 \pm 3.46^\circ$.

In patients with maxillary macrognathia and mandibular micrognathia, the linear dimensions of the upper jaw were increased: $Ans-Pns = 60.41 \pm 3.08$ mm, $Ans-Pns/SN = 80.02 \pm 1.89$ % mm, $Wits = 4.25 \pm 3.08$ mm and ANB angle $= 5.75 \pm 1.1^\circ$ and reduced dimensions of the lower jaw $Go-Me = 67.62 \pm 4.15$ mm in relation to the skull base $Go-Me/SN = 90.03 \pm 3.37$ % mm. Also increased the angle of inclination of the lower cutters $97.75 \pm 3.32^\circ$.

In maxillary macro- and mandibular micro- and retrognathia, along with the above features of the previous group, a reduced angle $SNGo = 37.98 \pm 1.25^\circ$ is characteristic.

1 patient only 1.69 % (female) was found with the form of maxillary macrognathia, An increase in the length of the upper jaw base relative to the norm $Ans-Pns = 64.7$ mm angles SNA , ANB .

According to Doroshenko SI et al. [1] antephas was found in 31.5 %, retrophas – in 26.3 %, maxillary macrognathia – in 42 %, mandibular micrognathia – in 26.3 %, and protrusion of the lower incisors was found in only 31 % of subjects. This difference in results can be explained by the fact that the study was performed in the WHO classification system and taking into account the tooth-alveolar forms of distal occlusion.

As for the position of the incisors, according to Hassan AH. [8] maxillary incisors are generally class II_2 prone, whereas in our studies, upper incisor protrusion was found in groups with maxillary prognathism and maxillary macro- and prognathism. In other cases, the angle of inclination was within the norm or in retrusion, but within the statistical error.

Other authors [8, 9, 10] performed their studies in the aspect of E. Engle classification. According to them, among all the studied parameters, the marker angles of skeletal forms are SNA , SNB and ANB . Whereas in our studies we used a much wider range of indices, both angular and linear.

The same view holds Krishna A. et al. [5], who emphasizes that such studies complement standard classifications that already exist, describe different forms in the system of one nosological unit.

Conclusions

1. According to the results of our study, 9 main skeletal forms of prognostic distal occlusion were identified.

2. Among all forms, prognathism of the upper jaw is the most common, 35.59 %.

3. Protrusion of the upper incisors is found only in patients with prognathism of the upper jaw and maxillary macro- and prognathism, while all forms are accompanied by an increase in the angle of inclination of the lower incisors, which is most likely compensatory.

4. Thus, in the course of this work it was found that the values of cephalometric parameters required for the diagnosis of prognostic distal occlusion are the main to clarify the form of dental anomaly and permit to detail the skeletal forms.

References

1. Doroshenko SI, Kulginiski EA, Radchenko AV, Storozhenko KV. *Differentsialnaya diagnostika prognaticheskikh form prikusa. Sovremennaya ortodontiya*. 2012; 02(28): 4–9 [in Russian]
2. Hassan AH. Cephalometric characteristics of Class II division 1 malocclusion in a Saudi population living in the western region. *The Saudi Dental Journal*. 2011; 23 (1): 23–27.
3. Joshia N, Hamdanb AM, Fakhouric WD. Skeletal Malocclusion: A Developmental Disorder With a Life-Long Morbidity. *J Clin Med Res*. 2014; 6(6): 399–408.
4. Krishna A., Babu LJ. Rush run on the classification system of class II malocclusion *Med. Res. Chronicles*. 2019; 6(5): 241–248.
5. Moreno Uribe LM, Howe SC, Kummet C, Vela KC, Dawson DV, Southard TE, et al. Phenotypic diversity in white adults with moderate to severe class II malocclusion. *Am J Orthod Dentofacial Orthop*. 2014; 145:305–16.
6. Perović T. The Influence of Class II Division 2 Malocclusions on the Harmony of the Human Face Profile. *Med Sci Monit*. 2017; 23: 5589–5598.
7. Santos RL, Ruellas ACO. Dentofacial characteristics of patients with Angle Class I and Class II malocclusions. *Dental Press J Orthod*. 2012; 17(2): 1–7.
8. Stasiuk OA, Vyzhenko YeYe, Makarova AN, Kuroyedova VD, Sokolohorska-Nykina YK. The evaluation of heads of temporomandibular joint (TMJ) position in patients with malocclusion. *The New Armenian Medical Journal*. 2020; 14 (1): 48–54.
9. Yoon SS, Chung C-H. Comparison of craniofacial growth of untreated Class I and class II girls from ages 9 to 18 years: a longitudinal study. *Am J Orthod Dentofacial Orthop*. 2015; 147: 190–6. doi.org/10.1016/j.ajodo.2014.10.023.
10. Zegan G, Dascălu CG, Golovcencu L, Anistoroaei D. Cephalometric features of class II Malocclusion. *International Journal of Medical Dentistry*. 2014; 4 (3): 222–228.